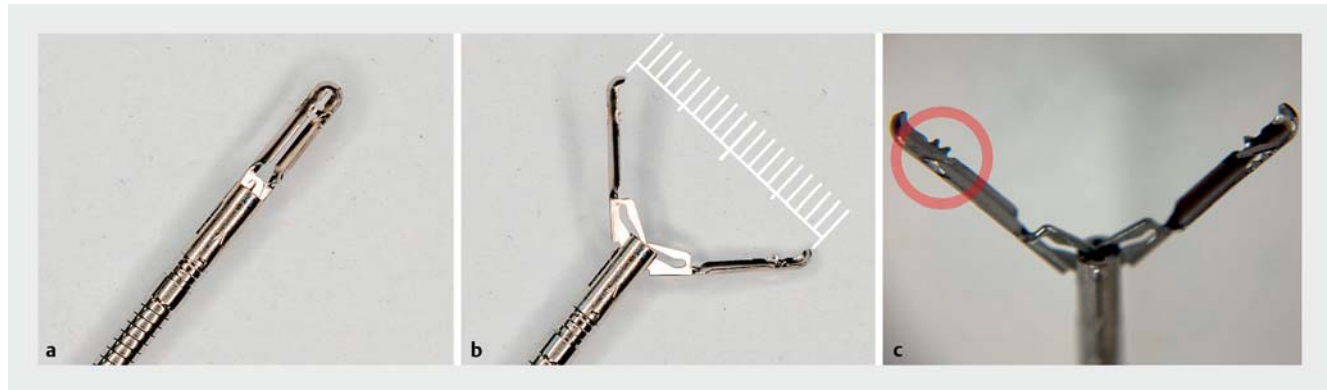


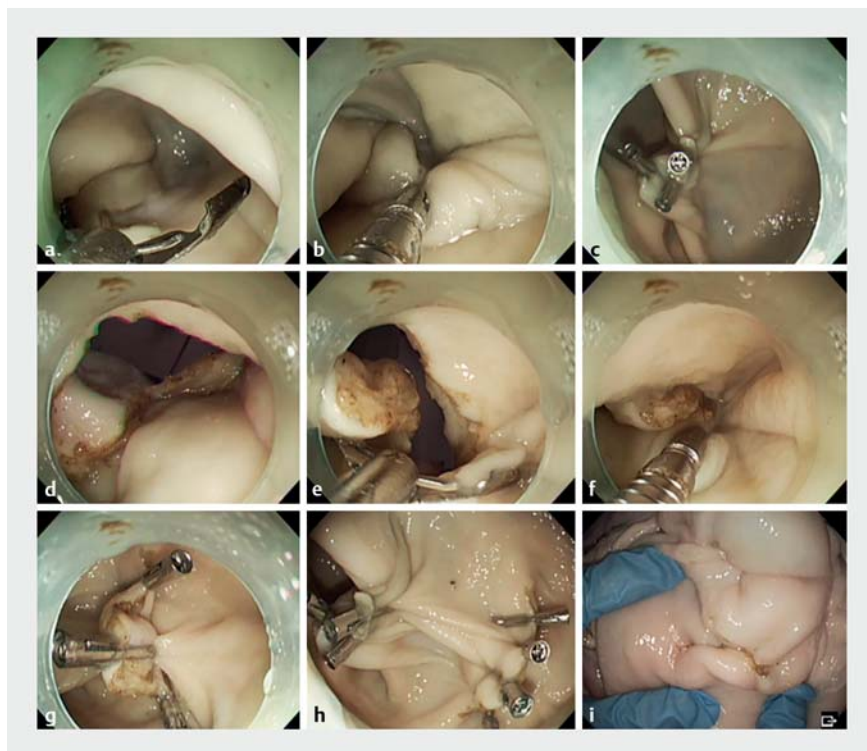Closure of full-thickness perforations in porcine stomach using 20-mm reopenable clips



► **Fig. 1** Photographs showing the 20-mm reopenable clip **a** in the closed position; **b** in the open position with the teeth opened to 20 mm; **c** with its small protrusions on the inside of the teeth (red circles) that help to prevent tissue slippage.

It is difficult to close perforations that are large and full thickness in the gastrointestinal tract using conventional clips. Closure methods using special devices, including the over-the-scope (OTS) clip (Ovesco, Tübingen, Germany), have therefore been devised [1–3]. However, the OTS clip cannot be regripped and cannot be used unless the endoscope is pulled out for the clip to be attached [4]. Therefore, a device that can reliably close a perforation under endoscopic visibility is desired. We introduce a reopenable clip, which has a large width of 20 mm, and demonstrate its ability to close large gastric perforations in a porcine model. The reopenable clip (LOCKADO hemostasis clip; 20 mm; Micro-Tech (Nanjing) Co., Ltd., Nanjing, China) has large teeth with an opening width of 20 mm (► **Fig. 1**). It is possible to regrip and reposition the reopenable clip after it is opened. The clip has small teeth on both sides that are distinct from the tips of the teeth to prevent the gripped tissue from slipping.

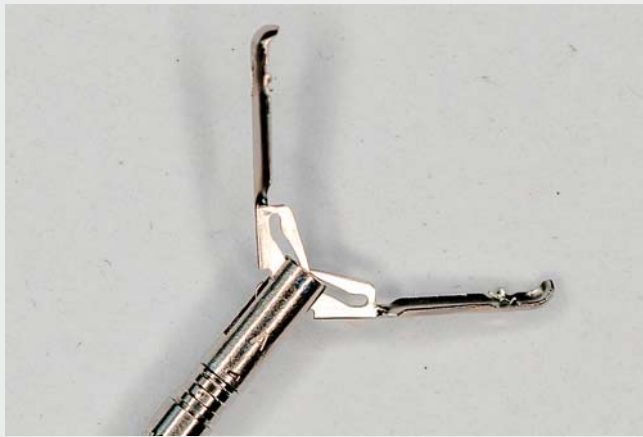A full-thickness perforation of approximately 15 mm was made in a porcine stomach (► **Fig. 2**; ► **Video 1**). The perforation was then gradually closed using 20-mm reopenable clips placed from one end of the perforation to the other. Three 20-mm reopenable clips were used to



► **Fig. 2** Images of full-layer perforation closure using 20-mm reopenable clips in a porcine model: **a–c** for a 15-mm full-thickness perforation; **d–g** for a 25-mm full-thickness perforation; **h, i** showing the closed perforation site including from the serosal side.

achieve complete closure. Because of the greater width of the clips, the muscles and mucosa were inverted toward the

stomach lumen, and no air leakage was observed outside the stomach. Next, a full-thickness perforation of 25 mm was



Video 1 Closure of two large full-thickness perforations of the stomach (15 mm and 25 mm) in a porcine model using 20-mm reopenable clips.

created. Similarly, the perforation was closed from one end to the other. The clips are repositionable, so they can be grasped and changed to the appropriate position as required. For this larger perforation, an additional 11-mm reopenable clip was added; as a result, the full-layer perforation was completely closed without any air leak.

The 20-mm reopenable clip has the potential to close large full-thickness perforations.

Endoscopy_UCTN_Code_TTT_1AQ_2AG

Competing interests

The authors declare that they have no conflict of interest.

The authors

Tatsuma Nomura^{1,2}, **Shinya Sugimoto**¹, **Haruka Nakamura**^{1,2}, **Jun Oyamada**¹, **Keiichi Ito**², **Akira Kamei**¹

1 Department of Gastroenterology, Ise Red Cross Hospital, Ise, Mie, Japan

2 Department of Gastroenterology, Mie Prefectural Shima Hospital, Shima, Mie, Japan

Corresponding author

Tatsuma Nomura, MD

Department of Gastroenterology, Ise Red Cross Hospital, 1-471-2 Funae, Ise, Mie, 516-8512, Japan
m06076tn@icloud.com

References

- [1] von Renteln D, Schmidt A, Vassiliou MC et al. Natural orifice transluminal endoscopic surgery gastrotomy closure with an over-the-endoscope clip: a randomized, controlled porcine study (with videos). *Gastrointest Endosc* 2009; 70: 732–739
- [2] Krutzenbichlet I, Dollhopf M, Diepolder H et al. Technical success, resection status, and procedural complication rate of colonoscopic full-wall resection: a pooled analysis from 7 hospitals of different care levels. *Surg Endosc* 2021; 35: 3339–3353
- [3] Manta R, Mangiafico S, Zullo A et al. First-line endoscopic treatment with over-the-scope clips in patients with either upper or lower gastrointestinal bleeding: a multicenter study. *Endosc Int Open* 2018; 6: E1317–E1321
- [4] Kobara H, Mori H, Nishiyama N et al. Over-the-scope clip system: A review of 1517 cases over 9 years. *J Gastroenterol Hepatol* 2019; 34: 22–30

Bibliography

Endoscopy 2023; 55: E86–E87

DOI 10.1055/a-1944-9175

ISSN 0013-726X

published online 10.10.2022

© 2022. The Author(s).

This is an open access article published by Thieme under the terms of the Creative Commons Attribution-NonDerivative-NonCommercial License, permitting copying and reproduction so long as the original work is given appropriate credit. Contents may not be used for commercial purposes, or adapted, remixed, transformed or built upon. (<https://creativecommons.org/licenses/by-nc-nd/4.0/>)

Georg Thieme Verlag KG, Rüdigerstraße 14, 70469 Stuttgart, Germany



ENDOSCOPY E-VIDEOS

<https://eref.thieme.de/e-videos>



Endoscopy E-Videos is an open access online section, reporting on interesting cases and new techniques in gastroenterological endoscopy. All papers include a high quality video and all contributions are freely accessible online. Processing charges apply (currently EUR 375), discounts and waivers acc. to HINARI are available.

This section has its own submission website at <https://mc.manuscriptcentral.com/e-videos>