

Treatment of primary hepatic neuroendocrine tumors with associating liver partition and portal vein ligation for staged hepatectomy (ALPPS)

A case report and literature review

Chao Qu, MM^{a,b}, Lin-lin Qu, MD, PhD^b, Cheng-zhan Zhu, MD, PhD^b, Zu-sen Wang, MD, PhD^b, Jingyu Cao, MD, PhD^{b,*}

Abstract

Rationale: Primary hepatic neuroendocrine tumors (PHNETs) are extremely rare and are difficult to diagnose preoperatively. We report a case of PHNET diagnosed preoperatively and successfully resected using associating liver partition and portal vein ligation for staged hepatectomy (ALPPS).

Patient concerns: A 72-year-old woman was admitted to our hospital for a hepatic mass, which was incidentally identified during a routine health checkup. The patient has no other obvious symptoms of discomfort.

Diagnoses: Physical examination revealed a palpable mass in the right upper quadrant of her abdomen. Dynamic contrast-enhanced abdominal computed tomography (CT) showed a low-density mass measuring 13 × 7 × 6 cm in both, the right and left hepatic lobes. ¹⁸F-fluorodesoxyglucose positron emission tomography (¹⁸F-FDG PET) and fused PET/CT showed increased uptake by the mass, which was indicative of a hepatic tumor.

Interventions: We use a novel ALPPS surgical procedure to safely and radically remove primary neuroendocrine tumors.

Outcomes: No postoperative bleeding and bile leakage were reported, and the patient recovered uneventfully. The patient was followed-up for a year without recurrence.

Lessons: PHNETs are rare tumors, and confirming the diagnosis using the best possible preoperative examination is important. An optimal treatment plan is selected based on the patient's condition to ensure a favorable prognosis. Tumors too large to undergo surgical removal can be resected using the ALPPS procedure, as described in this case report.

Abbreviations: AFP = alpha fetoprotein, ALPPS = associating liver partition and portal vein ligation for staged hepatectomy, CD = cluster of differentiation, CgA = chromogranin A, CK = cytokeratin, CT = computed tomography, HbsAg = hepatitis B surface antigen, HCV = hepatitis C virus, ICG = indocyaninegreen, NETs = neuroendocrine tumors, PET = positron emission tomography, PHNETs = primary hepatic neuroendocrine tumors, Syn = synaptophysin, TTF = thyroid transcription factor.

Keywords: associating liver partition and portal vein ligation for staged hepatectomy, primary hepatic neuroendocrine tumors, surgery treatment

Editor: N/A.

Ethics approval and consent to participate: All information about the patient in this manuscript follows the patient's right of informed consent and is fully authorized by the patient. The ethics involved in the manuscript has been reviewed by the Ethics Committee of the Affiliated Hospital of Qingdao University.

The authors have no funding and no conflicts of interest to disclose.

^a Medical College of Qingdao University, ^b Department of Hepatobiliary and Pancreatic Surgery, The Affiliated Hospital of Qingdao University, Qingdao City, Shandong Province, China.

* Correspondence: Jingyu Cao, Department of Hepatobiliary and Pancreatic Surgery, The Affiliated Hospital of Qingdao University, No. 16 Jiangsu Road, Qingdao City 266003, Shandong Province, China (e-mail: cjl7027@163.com).

Copyright © 2018 the Author(s). Published by Wolters Kluwer Health, Inc. This is an open access article distributed under the terms of the Creative Commons Attribution-Non Commercial License 4.0 (CCBY-NC), where it is permissible to download, share, remix, transform, and buildup the work provided it is properly cited. The work cannot be used commercially without permission from the journal.

Medicine (2018) 97:37(e12408)

Received: 18 May 2018 / Accepted: 24 August 2018

<http://dx.doi.org/10.1097/MD.00000000000012408>

1. Introduction

Neuroendocrine tumors (NETs) are an uncommon type of cancer originating in neuroectodermal cells that are widely distributed in the body. NETs commonly originate in the bronchopulmonary tree (30%) or the gastrointestinal tract (50%) and metastasize to the liver.^[1] Primary hepatic neuroendocrine tumors (PHNETs) are extremely rare (accounting for only 0.3% of all hepatic NETs)^[2] and are therefore difficult to diagnose preoperatively. PHNETs show slow growth without obvious early symptoms. Resection of PHNETs is difficult because they are usually detected only in the middle and late stages when the tumor has grown to a large size. We report a case of PHNET diagnosed preoperatively with successful resection using associating liver partition and portal vein ligation for staged hepatectomy (ALPPS).

2. Case presentation

A 72-year-old woman was admitted to our hospital for a hepatic mass, which was incidentally identified during a routine health checkup. The patient denied a history of jaundice, vomiting,

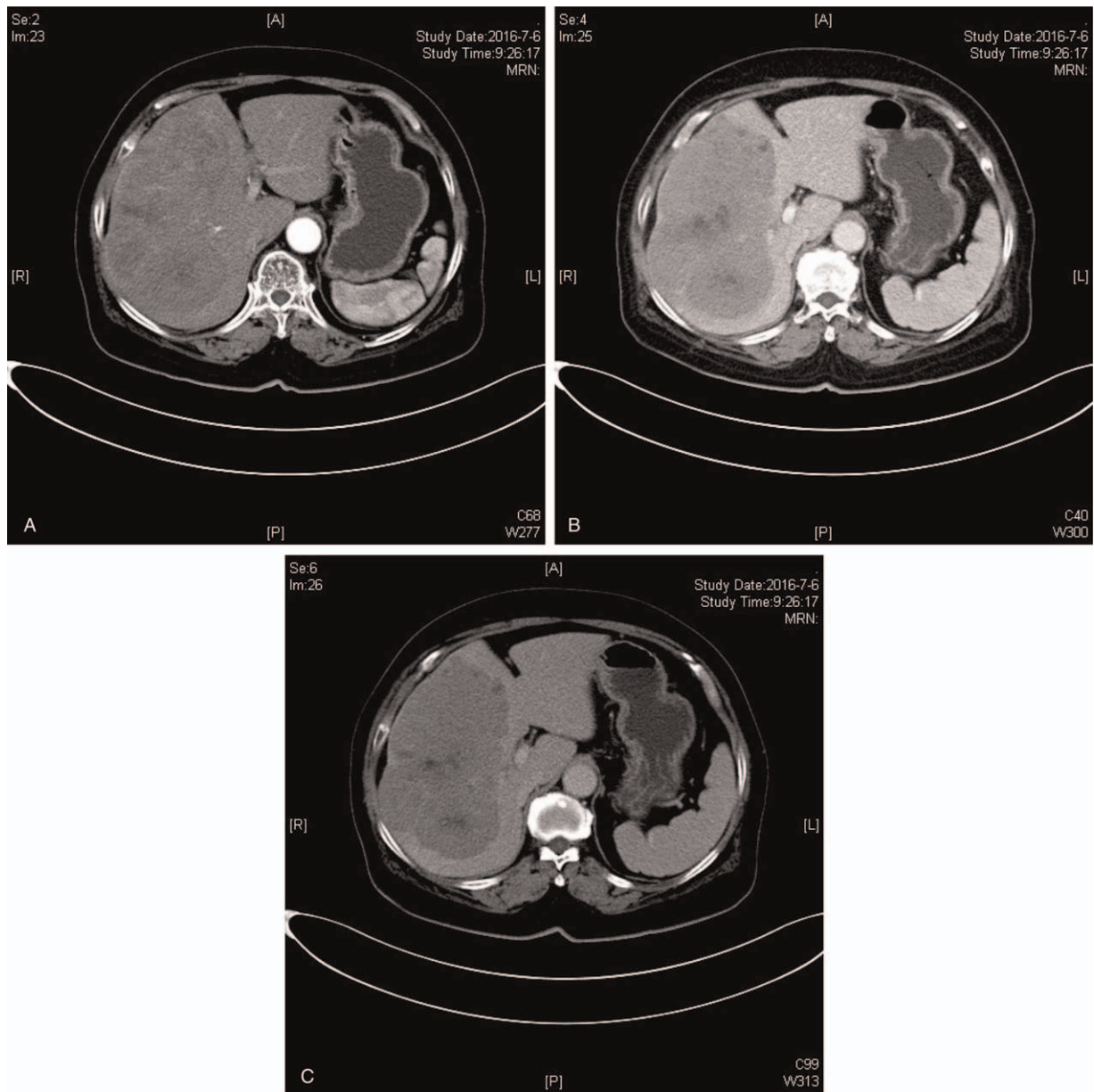


Figure 1. The giant soft tissue (13 × 7 × 6 cm) shadow in the right and left lobe, heterogeneous enhancement in the arterial phase (A). Enhancement decreased in venous phase, enhancement at the edge was lower than liver parenchyma (B). There were no enhancements at central of cystic part on 3 phases (A–C).

flushing, or diarrhea before admission. Physical examination revealed a palpable mass in the right upper quadrant of her abdomen. The mass showed a hard texture with an unclear boundary. Laboratory tests showed her blood chemistry was normal. The serum alpha fetoprotein (AFP) level was normal (5.37 ng/mL, reference range 0–7.2 ng/mL), and the hepatitis B virus surface antigen and the hepatitis C virus antibody were negative. Abdominal ultrasonography revealed a huge intrahepatic lesion, which was considered to be hepatic cancer. Dynamic contrast-enhanced abdominal computed tomography (CT) showed a low-density mass measuring 13 × 7 × 6 cm in both, the right and left hepatic lobes (Fig. 1). The mass showed heterogeneous enhancement in the arterial phase; however, a decrease in enhancement was observed in the venous phase with no enhancement in the central cystic portion on a triple-phase scan. ^{18}F -fluorodesoxyglucose positron emission tomography

(^{18}F -FDG PET) and fused PET/CT showed increased uptake by the mass, which was indicative of a hepatic tumor. Whole-body ^{18}F -FDG PET showed no abnormal activity except for the hepatic lesion. We performed a biopsy for a conclusive diagnosis. Histopathological examination showed a poorly differentiated malignant tumor. Immunohistochemical examination showed that the tumor was positive for cytokeratin (CK), synaptophysin (Syn), chromogranin A (CgA), cluster of differentiation (CD) 56, and thyroid transcription factor (TTF)-1 and negative for cytokeratin (CK) 7. The positive nuclei demonstrated the Ki-67 proliferation rate was 15%. Based on the World Health Organization 2010 classification, this patient was diagnosed with a NET (grade G2).

Based on CT findings, we originally planned to perform a right hepatic trilobectomy. The indocyanine green test performed for preoperative evaluation of hepatic function indicated acceptable

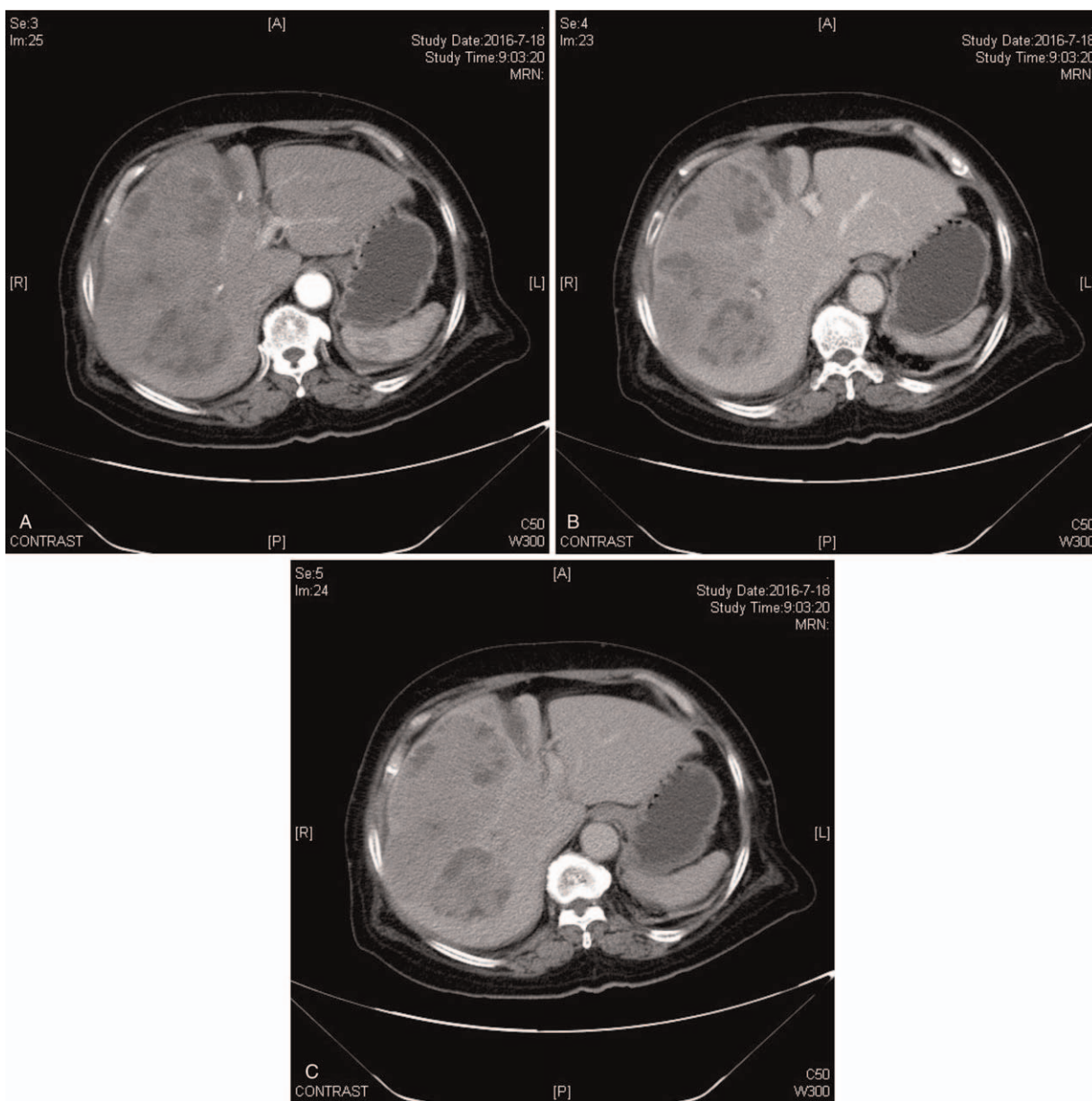


Figure 2. The branch of the right branch of the portal vein is blurred, and the gallbladder is not shown. The volume of the left hepatic lobe increased significantly a week postoperatively (A–C).

hepatic function, although the postoperative residual hepatic volume systematically evaluated using the Hisense Group CAS surgical plan was only 17.87% of the original hepatic volume. The postoperative residual hepatic tissue was insufficient to maintain normal physiological function. Therefore, we selected the surgically safe ALPPS procedure. The first stage of the operation performed laparoscopically included cholecystectomy, ligation of the right portal vein, and partial splitting of the hepatic tissue between segment IV and the left lateral hepatic lobe. No postoperative bleeding and/or bile leakage were reported, and the patient recovered uneventfully.

Contrast-enhanced CT showed the volume of the left hepatic lobe increased significantly a week postoperatively (Fig. 2). Remnant hepatic volume was 31% of the standard hepatic volume after evaluation by the Hisense Group CAS surgical plan. Right hepatic trisegmentectomy was performed (Fig. 3), and the

patient recovered uneventfully with regular follow-up as an outpatient for a year. Postoperative follow-up data are shown in Table 1. No tumors were identified in any other location during follow-up. The patient received Tegafur at a dose of 80 mg/day for 6 months postoperatively. Histopathological examination showed small cell carcinoma (13 × 7 × 6 cm) in the right hepatic lobe, and immunohistochemical examination showed the tumor was positive for CK, Syn, CgA, CD56, and TTF-1, and negative for hepatocyte, AFP, CK19, CD34, blood vessels, and p53. The positive of Ki-67 was 40%. Interstitial vascular tumor thrombus was not identified using CD31 and D2-40 stains (Fig. 4).

3. Discussion

PHNETs are extremely rare tumors and were first described by Edmondson in 1958.^[3] To date, only 150 cases have been

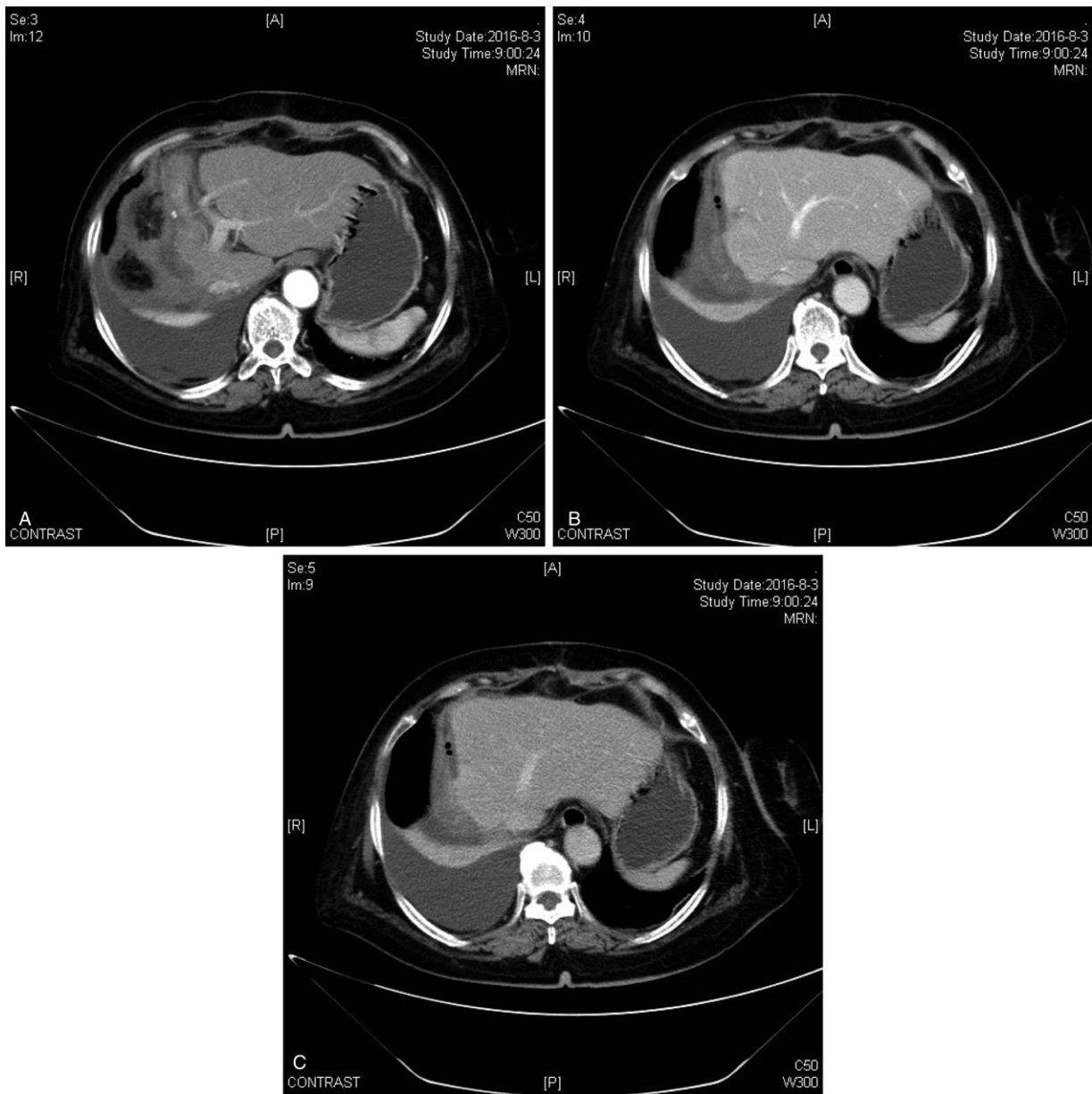


Figure 3. The right hepatic lobe and left lobe were partially absent, and the corresponding regional structure was disordered. No obvious abnormal density was observed in the residual liver. The gallbladder was not shown (A–C).

Table 1

Preoperative and postoperative and follow-up laboratory tests.

	ALT, μL	AST, μL	TBIL, $\mu\text{mol/L}$	Alb, g/L	GGT, μL
Normal reference values	9.0–50.0	15.0–40.0	3.0–22.0	40.0–55.0	10.0–60.0
Preoperative	27.2	39.1	18.1	35.1	111
After the first phase of surgery	83.1	147	21.3	33.8	102.5
Third days after the first stage of the operation	99.6	127.9	25.8	28.5	130.4
Second stage operation day	38.9	33	21.9	34.4	197.9
Third days after the second stage operation	109.8	198.2	49.4	26	125.5
Seventh days after the second stage operation	75.2	64.4	40.1	28.7	91.5
One month after surgery	34.2	25.5	27.5	31.1	164.1
One year after surgery	16	30	20.6	39.2	38

ALB=albumin, ALT=alanine aminotransferase, AST=aspartate aminotransferase, GGT=gamma-glutamyl transferase, TBIL=total bilirubin.

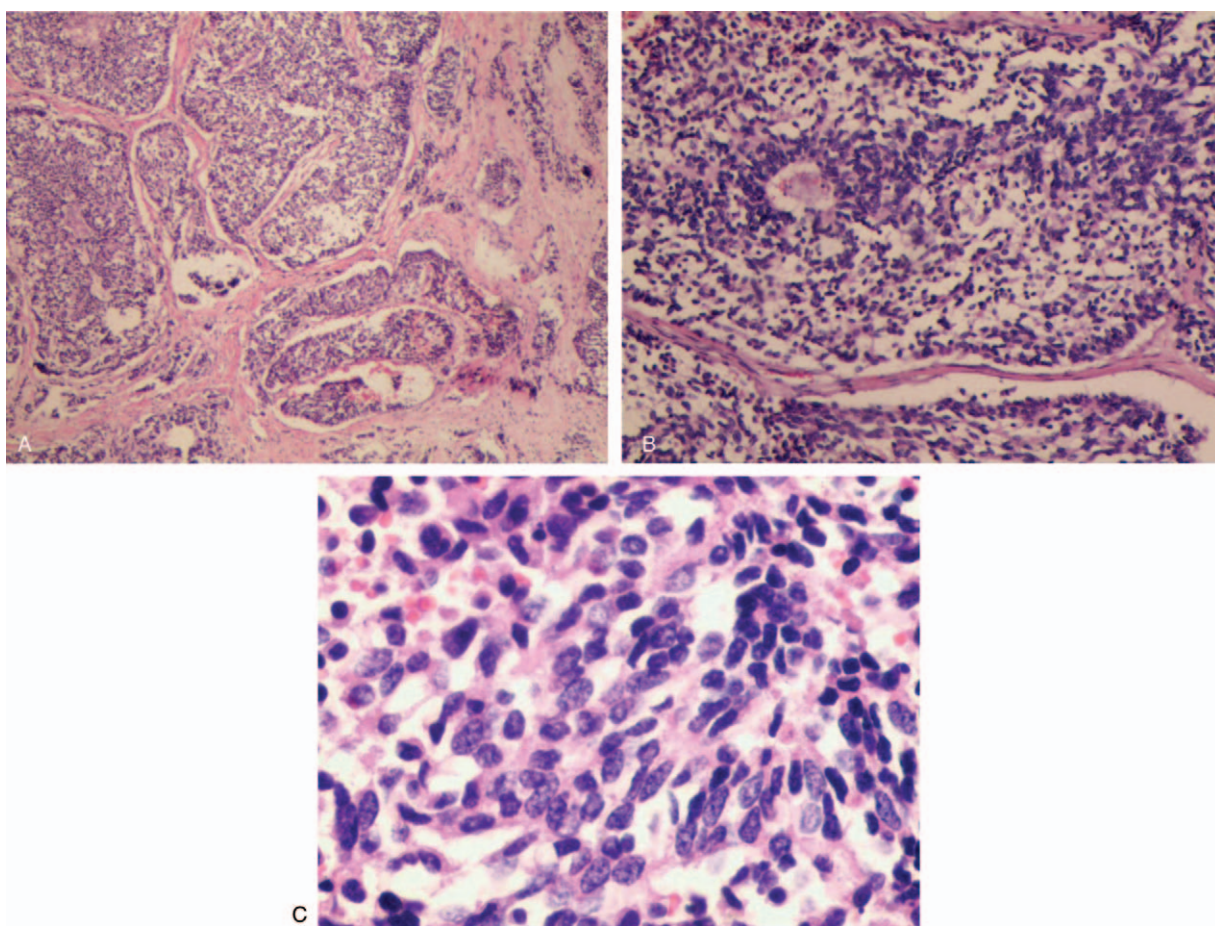


Figure 4. Microscopic appearance of the tumoral lesion in the resected liver specimen. The architectural pattern is trabecular and glandular. (H & E, $\times 40$) (A). Cells were nested, flaky or diffuse distribution, and visible small duct, like chrysanthemum-shaped structure. (H & E, $\times 100$) (B). The neoplasm consisted of large polygonal or columnar cells having an eosinophilic granular cytoplasm. Nuclei were oval or round with a regular, fine chromatin. Pseudoglandular lumina were present (H & E, $\times 400$) (C).

reported in the literature,^[4] and an accurate diagnosis is difficult before a biopsy or surgical resection is performed owing to the limited availability of data regarding PHNETs. Therefore, PHNETs are often indistinguishable preoperatively from other solid masses, particularly hepatocellular carcinoma. A few reports have indicated that PET/CT-guided biopsy and histopathological as well as immunohistochemical examinations^[5,6] are useful diagnostic modalities. Ma^[7] and Gorla^[8] have reported the diagnostic value of ^{18}F -FDG PET/CT and ^{68}Ga tetraazacyclododecane tetraacetic acid-DPhe1-Tyr3-octreotate PET/CT for PHNETs in their respective studies. We used ^{18}F -FDG PET/CT, biopsy, and histopathological, as well as immunohistochemical examinations for preoperative diagnosis. PET/CT results did not directly diagnose PHNETs, indicating that PET/CT is not a sensitive diagnostic indicator for PHNETs. However PET/CT could be useful to detect the original source of potential NETs to further determine whether the tumor is native to the liver. As was observed in our patient, PET/CT shows only the presence of a hepatic mass, which is valuable in diagnosing PHNETs. The diagnosis needs to be confirmed by histopathological examination, particularly for the diagnosis of PHNETs and metastatic NETs.

Histopathological examination of PHNETs shows a gray-yellow well-demarcated mass with multiple irregular hemorrhagic or cystic areas.^[9] Tumors range in size from 0.4 to 19 cm (mean

6.84 ± 4.29 cm).^[10] In our patient, the tumor measured $13 \times 7 \times 6$ cm and involved the right 3 lobes of the liver. Routine histopathological examination using hematoxylin-eosin stains shows an insular, nested, trabecular or mixed cellular growth pattern, although this is a nonspecific finding.^[11] Lv et al^[10] performed a retrospective study of the clinicopathological characteristics of 81 PHNETs and metastatic hepatic NETs and showed that patients with PHNETs demonstrated an aggressive clinical presentation. The hard texture of the tumor, multifocality of tumors, and the immunohistochemical expression of neuron-specific enolase and Syn were independent predictive factors. Syn-positivity observed using immunohistochemical evaluation in our patient concurs with the findings of the aforementioned study. PHNETs and metastatic hepatic NETs are often indistinguishable owing to similarities in imaging findings.^[12] Therefore, further imaging methods including CT, magnetic resonance imaging (MRI), and PET, among others are required for the accurate detection of extrahepatic lesions. For example, a recent report by Cha et al^[13] proposed a gadoteric acid-enhanced MRI to identify primary and metastatic NETs. In addition to imaging modalities, long-term follow-up remains an important strategy to avoid missing small extrahepatic lesions.^[14]

PHNETs differ from other NETs in their clinical presentation. PHNETs are typically slow-growing tumors that become clinically obvious only during the mid- or late-stages.^[15] In most

cases, they are discovered incidentally because they often present as an endocrinologically silent hepatic mass. Only 6.8% of PHNETs present as classical carcinoid syndrome with skin flushing, diarrhea, and abdominal pain.^[11] PHNETs are often discovered incidentally in patients who present with abdominal distention, vague pain, jaundice, and a palpable right upper quadrant mass. Owing to the atypical and vague clinical presentation, early detection of PHNETs is often difficult, which precludes radical resection because of the large tumor size. Therefore, transarterial chemoembolization (TACE), radiotherapy and chemotherapy are often useful treatment options. However, a study performed by Zi-Ming Zhao indicates that neither TACE nor liver protection appeared to significantly prolong the survival time in patients.^[16] No guidelines have been established for the management of PHNETs; however, surgical resection remains the primary treatment.^[17] Reportedly, the resectability rate is 70%, and the 5-year survival rate after hepatectomy is 78%.^[18] In our patient, the tumor covered right 3 lobes of the liver. We could not perform standard resection because the postoperative residual hepatic volume was too small to maintain physiological hepatic function. ALPPS serves as a safe surgical technique that ensures complete tumor resection and preserves functional integrity through compensatory residual hepatic hyperplasia. Postoperative chemotherapy is warranted in patients with histopathologically proven small cell tumors. Hepatic artery embolization and conservative treatment with somatostatin could be considered in patients with unresectable PHNETs.^[19]

4. Conclusion

Prompt and accurate diagnosis and treatment are necessary in patients with PHNETs. Whether it is possible to perform radical hepatectomy on patients has a significant impact on the prognosis of patients. In patients with well-preserved hepatic function but a tumor that is too large to be removed via a single-staged operation, the surgical procedure reported in this study could be useful.

Acknowledgments

Thanks to the following authors for their contributions to the completion of this manuscript: JC designed the study; CQ and LQ analyzed the data and wrote the paper; CZ and ZW were responsible for collecting data and following-up the patient's prognosis.

Author contributions

Resources: Jingyu Cao, Zuseng Wang.

Writing – original draft: Chao Qu.

Writing – review & editing: Lin-lin Qu, Chengzhan Zhu, Jingyu Cao.

References

- [1] Fenoglio LM, Severini S, Ferrigno D, et al. Primary hepatic carcinoid: a case report and literature review. *World J Gastroenterol* 2009;15:2418–22.
- [2] Camargo ES, Viveiros MDM, Correa Neto IJF, et al. Primary hepatic carcinoid tumor: case report and literature review. *Einstein (Sao Paulo, Brazil)* 2014;12:505–8.
- [3] Edmondson HA. *Tumors of the Liver and Intrahepatic Bile Ducts*. 1958; Armed Forces Institute of Pathology, Washington, DC:216, Vol. section 7, fasc. 25.
- [4] Li W, Zhuang B, Wang Z, et al. Case report of contrast-enhanced ultrasound features of primary hepatic neuroendocrine tumor. *Medicine* 2016;95:e3450.
- [5] Skagias L, Vasou O, Ntinis A, et al. Primary hepatic neuroendocrine tumor with exophytic growth report of a case with diagnosis by fine needle aspiration biopsy. *Acta Cytol* 2010;54:202–4.
- [6] Gorla AK, Basher RK, Kaman L, et al. 68Ga-DOTATATE PET/CT in primary hepatic neuroendocrine tumor. *Clin Nucl Med* 2017;42:118–20.
- [7] Ma G, Li J, Xu B, et al. 18F-FDG PET/CT in primary hepatic neuroendocrine tumors. *Clin Nucl Med* 2018;43:192–4.
- [8] Pilichowska M, Kimura N, Ouchi A, et al. Primary hepatic carcinoid and neuroendocrine carcinoma: clinicopathological and immunohistochemical study of five cases. *Pathol Int* 1999;49:318–24.
- [9] Shetty PK, Baliga SV, Balaiah K, et al. Primary hepatic neuroendocrine tumor: an unusual cystic presentation. *Indian J Pathol Microbiol* 2010;53:760–2.
- [10] Lv Y, Huang C, Xu H, et al. Clinicopathological characteristics of the primary and metastatic hepatic neuroendocrine tumors and the relevant prognosis-related factors: a retrospective study of 81 cases in a single Chinese center. *J Cancer* 2018;9:479–87.
- [11] Song JE, Kim BS, Lee CH. Primary hepatic neuroendocrine tumor: a case report and literature review. *World J Clin Cases* 2016;4:243–7.
- [12] Baek S, Yoon J, Kim K. Primary hepatic neuroendocrine tumor: gadoxetic acid (Gd-EOB-DTPA)-enhanced magnetic resonance imaging. *Acta Radiol Short Rep* 2013;2:2047981613482897.
- [13] Dong IC, Kang TW, Jang KM, et al. Hepatic neuroendocrine tumors: gadoxetic acid-enhanced magnetic resonance imaging findings with an emphasis on differentiation between primary and secondary tumors. *Abdominal Radiology* 2018;1–9.
- [14] Landen S, Elens M, Vrancken C, et al. Giant hepatic carcinoid: a rare tumor with a favorable prognosis. *Case Rep Surg* 2014;2014:1–4.
- [15] Jia C, Zhang Y, Xu J, et al. Experience in primary hepatic neuroendocrine tumor. *Turkish J Gastroenterol* 2012;23:546–51.
- [16] Zhao ZM, Wang J, Uguowuo UC, et al. Primary hepatic neuroendocrine carcinoma: report of two cases and literature review. *BMC Clin Pathol* 2018;18:3.
- [17] Iwao M, Nakamura M, Enjoji M, et al. Primary hepatic carcinoid tumor: case report and review of 53 cases. *Med Sci Monit* 2001;7:746–50.
- [18] Knox CD, Anderson CD, Lamps LW, et al. Long-term survival after resection for primary hepatic carcinoid tumor. *Ann Surg Oncol* 2003;10:1171–5.
- [19] Krishnamurthy SC, Dutta V, Pai SA, et al. Primary carcinoid tumor of the liver: report of four resected cases including one with gastrin production. *J Surg Oncol* 1996;62:218–21.