

Primary Cutaneous Mucormycosis in a Trauma Patient with Morel-Lavallée Lesion

Karan Singla, Tanvir Samra, Nidhi Bhatia

Department of Anesthesia, Postgraduate Institute of Medical Education and Research, Chandigarh, India

Abstract

Mucormycosis is an aggressive fungal infection caused by zygomycetes from the order of *Mucorales*. Immunocompromised patients or patients with comorbidities are susceptible to this infection. There are many forms of mucormycosis such as rhino-orbito-cerebral, cutaneous, gastrointestinal, and pulmonary. Cutaneous mucormycosis is rare in trauma patients with no comorbidities. Morel-Lavallée lesions are rare degloving injuries in trauma patients. We report a case of cutaneous mucormycosis in a trauma patient with the Morel-Lavallée lesions.

Keywords: Amphotericin B, Morel-Lavallée lesions, primary cutaneous mucormycosis

INTRODUCTION

Mucormycosis is an aggressive fungal infection caused by zygomycetes.^[1,2] Immunosuppression or coexistence of multiple comorbidities such as diabetes mellitus, renal or hepatic dysfunction, deferoxamine therapy, chemotherapy, hematological malignancies, long-term steroids therapy, infectious diseases, such as HIV, tuberculosis, and extensive burns, increase susceptibility to this infection.^[3-6] Cutaneous mucormycosis is rare in trauma patients, and the clinical spectrum varies from mild chronic infection to severe multisystem involvement. The Morel-Lavallée lesions are rare post-traumatic degloving injuries deep to the subcutaneous plane and contain hemolymph and necrotic fat. We report a case of cutaneous mucormycosis in a young female with polytrauma secondary to extensive necrosis of Morel-Lavallée lesions.

CASE REPORT

A 22-year-old female patient was referred to our trauma center after a few days of admission in a private hospital following a railway accident. Surgical procedures performed during admission in the private hospital were a below-knee amputation and interlocking nail in the bilateral femur. She was being managed conservatively for open book pelvic bone fracture and extensive Morel-Lavallée lesions over the left flank. The patient was conscious and oriented with stable hemodynamic parameters on arrival to the trauma center; heart rate of 90/min,

blood pressure of 110/70 mm Hg, and respiratory rate of 20/min. During her hospitalization despite regular dressing and the use of iv antibiotics injection meropenem and injection vancomycin, she developed features of sepsis.^[7] Surgical debridement of the Morel-Lavallée lesion was planned on day 5 of admission under general anesthesia. The extensive necrotic area extending from left 12th rib to left thigh was debrided which left the pelvic bone exposed [Figure 1]. Intraoperatively, the patient developed hypotension and required inotropic support. The patient was shifted to the Intensive Care Unit (ICU) where she was managed for persistent hypotension requiring higher inotropic support, high-grade fever (41°C), and rising total leukocyte count (30,000/ml). On the postoperative day 3, black foul smelling necrotic areas were seen on the surface of the wound over the left flank with cottony bread mold lesions on the edges of the lesion. Immediate surgical debridement was planned. Intraoperative finding included extensive muscle necrosis in areas where peritoneum was breached, and bowel was exposed [Figure 2]. Tissue for fungal culture and sensitivity was sent. Histopathological examination showed the presence of nonseptate irregular hyphae of class zygomycetes.

Address for correspondence: Dr. Tanvir Samra,
Department of Anesthesia, Postgraduate Institute of Medical
Education and Research, Sector 12-A, Chandigarh - 160 012, India.
E-mail: drtanvirsamra@yahoo.in

Access this article online

Quick Response Code:



Website:
www.ijccm.org

DOI:
10.4103/ijccm.IJCCM_343_17

This is an open access journal, and articles are distributed under the terms of the Creative Commons Attribution-NonCommercial-ShareAlike 4.0 License, which allows others to remix, tweak, and build upon the work non-commercially, as long as appropriate credit is given and the new creations are licensed under the identical terms.

For reprints contact: reprints@medknow.com

How to cite this article: Singla K, Samra T, Bhatia N. Primary cutaneous mucormycosis in a trauma patient with Morel-Lavallée lesion. Indian J Crit Care Med 2018;22:375-7.

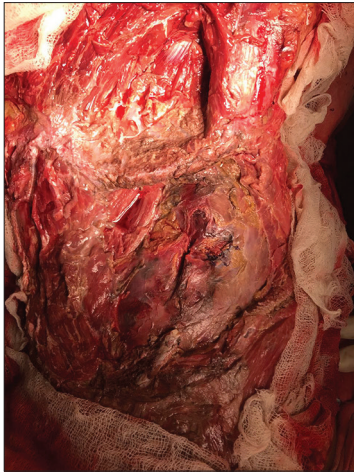

Figure 1: Intra-operative photograph of the left flank showing granulation tissue over the abdominal muscles following surgical debridement on the Intensive Care Unit day 1

A provisional diagnosis of mucormycosis was made, and liposomal amphotericin B (5mg/kg) was immediately started for fungal sepsis. Later, the fungal culture grew strains of *Rhizopus oryzae*, thus confirming the presence of invasive mucormycosis. However, the patient died on day 6 of ICU admission of severe septic shock.

DISCUSSION

Cutaneous mucormycosis has been rarely documented in trauma patients and members of genus *Rhizopus* are most commonly implicated.^[8] Contamination of the traumatized tissue with soil is the most likely mode of entry of *Rhizopus*. In open wounds, it has a cottony, bread mold appearance.^[8,9] The most fatal form is phycomycotic gangrenous cellulitis which characteristically appears as a central blackened necrotic eschar surrounded by reddish-purple soft-tissue induration.^[10]

Diagnosis of cutaneous mucormycosis is made by culture or biopsy. A potassium hydroxide preparation of the biopsy reveals nonseptate, thick-walled hyphae with right angle branching. Hyphae can also be seen on tissue sections on hematoxylin-eosin and Gomori's methenamine silver stain.^[11] Hallmark of mucormycosis is a vascular invasion with thrombosis of vessels and necrosis of surrounding tissue.^[12]

The most common form of mucormycosis is rhino-orbito-cerebral mucormycosis (44%–49%) followed by cutaneous mucormycosis (10%–19%), pulmonary mucormycosis (10%–11%), disseminated mucormycosis (6%–11%), gastrointestinal (2%–11%), and other rare forms.^[13–15] Although commonly associated with immunocompromised conditions, cutaneous mucormycosis is reported to occur in patients with no underlying immune deficiency. Local predisposing factors such as trauma, burns, and needle-stick play a major role.^[16,17] In the 1970s, there was a large outbreak of cutaneous mucormycosis secondary to use of infected Elastoplast bandages.^[11,12,18] Aggressive surgical debridement remains

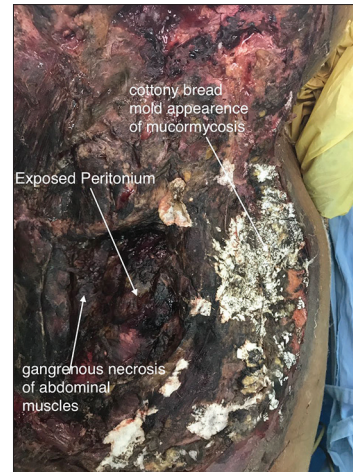


Figure 2: Intra-operative photograph of the left flank showing extensive gangrenous necrosis, exposed peritoneum, and colonies of mucormycosis on the Intensive Care Unit day 3

the cornerstone of management, amputation of the affected limb may also be required.^[12,19] Intravenous (IV) amphotericin B (1 to 1.5 mg/kg/day) is the anti-fungal of choice, and the liposomal preparation is advised if the patient develops renal toxicity.^[20] Ketoconazole, itraconazole, and fluconazole have no sensitivity to Mucorales.^[21] Posaconazole has shown good *in vitro* sensitivity against *Rhizopus*, *mucor*, and other zygomycetes.^[22] Hyperbaric oxygen therapy has been reported to be beneficial.^[23]

Prognosis of post-traumatic mucormycosis is poor. Cocanour *et al.* have reported 30% mortality.^[8] However, in the largest case series, mortality from disseminated mucormycosis was found to be 83%.^[24] More recently mortality rates between 26% and 43% have been reported.^[25,26] The patient had extensive cutaneous mucormycosis over the trunk reaching up to the peritoneum with bowel segment exposed and thus could not be saved.

CONCLUSION

We conclude that post-traumatic mucormycosis is a rare and underdiagnosed condition. Key to successful treatment is a high index of suspicion, aggressive debridement, early amputation, and administration of IV amphotericin B.

Declaration of patient consent

The authors certify that they have obtained all appropriate patient consent forms. In the form the patient(s) has/have given his/her/their consent for his/her/their images and other clinical information to be reported in the journal. The patients understand that their names and initials will not be published and due efforts will be made to conceal their identity, but anonymity cannot be guaranteed.

Financial support and sponsorship

Nil.

Conflicts of interest

There are no conflicts of interest.

REFERENCES

- Holtom PD, Obuch AB, Ahlmann ER, Shepherd LE, Patzakis MJ. Mucormycosis of the tibia: A case report and review of the literature. *Clin Orthop Relat Res* 2000;381:222-8.
- Kwon-Chung J, Bennett JE. Mucormycosis. In: *Medical mycology*. Philadelphia, Pa: Lea & Febiger; 1992. p. 524-59.
- Ribes JA, Vanover-Sams CL, Baker J. Zygomycetes in human disease. *Clin Microbiol Rev* 2000;13:236-301.
- Prabhu RM, Patel R. Mucormycosis and entomophthoromycosis: A review of the clinical manifestations, diagnostic and treatment. *Clin Microbiol Infect* 2004;10:31-47.
- Weinberg JM, Baxt RD, Egan CL, Rook AH, Atillasoy ES, Ragsdale BD. Mucormycosis in a patient with acquired immunodeficiency syndrome. *Arch Dermatol* 1997;133:249-51.
- Carpenter CF, Subramanian AK. Images in clinical medicine. Cutaneous zygomycosis (mucormycosis). *N Engl J Med* 1999;34:1891.
- Singer M, Deutschman CS, Seymour CW, Shankar-Hari M, Annane D, Bauer M *et al.* The third International Consensus Definition of septic shock (Sepsis-3). *JAMA* 2016;315:801-810.
- Cocanour CS, Miller-Crotchet P, Lawrence Reed R, Johnson OC, Fisher RP. Mucormycosis in trauma patients. *J trauma* 1992;32:3-5.
- Meyer RD, Armstrong D. Mucormycosis-changing states. *CRC Crit Rev Clin Lab Sci.* 1973;4:421.
- Bruck HM, Nash G, Foley FD, Pruitt BA Jr. Opportunistic fungal infection of the burn wound with phycomycetes and aspergillus. *Arch Surg* 1971;102:476-82.
- Everett ED, Pearson S, Rogers W. rhizopus surgical wound infection associated with elasticized adhesive tape dressing. *Arch surg* 1979;114:738-9.
- Dennis JE, Rhodes KH, Cooney DR. Nosocomial Rhizopus infection (zygomycosis) in children. *J Pediatr* 1980;96:824-8.
- Sugar AM. Agents of mucormycosis and related species. In: Mandell GI, Bennett JE, Dolin R, Mandell, Douglas and Bennett's Principles and practice of infectious diseases. 6th ed. Philadelphia: Elsevier; 2006.
- Chakrabarti A, Kumar P, Padhe AA, Chatha L, Singh SK, Das A *et al.* Primary cutaneous zygomycosis due to *Saksenea vasiformis* and *Apophysomyces elegans*. *Clin Infect Dis* 1997;24:580-3.
- Kordy FN, Al-Mohsen IZ, Hashem F, Almodovar E, Al Hajjar S, Walsh TJ. Successful treatment of a child with posttraumatic necrotizing fasciitis caused by *Apophysomyces elegans*: case report and review of literature. *Pediatr Infect Dis J* 2004;23:877-9.
- Adam RD, Hunter G, DiTomasso J, Comerci G. Mucormycosis: Emerging prominence of cutaneous infection. *Clin Infect Dis* 1994;19:67-76.
- George Petrikkos, Anna Skiada, Olivier Lortholary, Emmanuel Roilides, Thomas J. Walsh, Dimitrios P. Kontoyiannis; *Epidemiology and Clinical Manifestations of Mucormycosis, Clinical Infectious Diseases, Volume 54, Issue suppl_1, 1 February 2012, p. S23-S34.*
- Keys RF, Halderson AM, Rhodes KH. Nosocomial outbreak of rhizopus infections associated with Elastoplast dressings-Minnesota. *MMWR* 1978;27:33-4.
- Kobayashi M, Hiruma M, Matsushita A, Kawai M, Ogawa H, Udagawa Set. Cutaneous zygomycosis: A case report and review of Japanese reports. *Mycoses* 2001;44:311-5.
- Okhuysen PC, Rex JH, Kapusta M, Fife C. Successful treatment of extensive post traumatic soft tissue and renal infection due to *Apophysomyces elegans*. *Clin Infect Dis* 1994;19:329-31.
- Seguin P, Musellec H, Le Gall F, Chevrier S, Le bouquin V, Malledant Y. Post traumatic course complicated by cutaneous infection with *Absidia corymbifera*. *Eur J Clin Microbiol Infect Dis* 1999;18:737-9.
- Tobon AM, Arango M, Fernandez D, Restrepo A. Mucormycosis(zygomycosis) in a heart- kidney transplant recipient. Recovery after posaconazole. *Clin Infect Dis* 2003;36:1488-91.
- McAllister TA, Stark JM. Inhibitory effects of hyperbaric oxygen in bacteria and fungi. *Lancet* 1963;2:1040.
- Roden MM, Zaoutis TE, Buchanan WL, Knudsen TA, Sarkisova TA, Schaufele RL, *et al.* Epidemiology and outcome of zygomycosis: A review of 929 reported cases. *Clin Infect Dis* 2005;41:634-53.
- Skiada A, Rigopoulos D, Larios G, Petrikkos G, Katsambas A. Global epidemiology of cutaneous zygomycosis. *Clin Dermatol* 2012;30:628-32.
- Skiada A, Petrikkos G. Cutaneous zygomycosis. *Clin Microbiol Infect* 2009;15:41-5.