

Biochemical Evidence for the Antitumor Potential of *Garcinia mangostana* Linn. On Diethylnitrosamine-Induced Hepatic Carcinoma

V. Vishnu Priya, Mallika Jainu¹, Surapaneni Krishna Mohan²

Department of Biochemistry, Saveetha Dental College and Hospital, Saveetha University, Velappanchavadi, ¹Department of Biochemistry, Biogen Care Research Center, Chennai, Tamil Nadu, India, ²Department of Biochemistry, College of Medicine, Texila American University, Guyana, South America

Submitted: 26-05-2017

Revised: 04-07-2017

Published: 10-04-2018

ABSTRACT

Background: *Garcinia mangostana* is extensively used in most of the Indian herbal pharmaceuticals and nutraceuticals. **Objective:** The objective of this study was to elucidate the underlying biochemical protective mechanism of *G. Mangostana* Linn. fruit extract (GME) in deterioration of diethylnitrosamine (DEN)-induced hepatic carcinoma (HCC) in rats.

Materials and Methods: The cancer was induced using DEN to the experimental rats and treated with GME (200, 400, and 600 mg/kg) to find its anticancer property. The cancer biomarkers such as alpha-fetoprotein (AFP), carcinoembryonic antigen (CEA), hepatic hydroxyl proline, total tissue protein, and tumor necrosis factor-alpha levels were measured using ELISA. The vascular endothelial growth factor expressions were also seen in liver tissues using immunohistochemistry. **Results:** In addition, there was a significant increase in serum AFP, CEA, hepatic hydroxylproline, and total tissue protein levels in HCC group versus the negative control group. In contrast, the groups with HCC subjected to either high or low dose of GME elicited significant reduction of AFP, CEA, hepatic hydroxylproline, and increase in total protein in serum compared to the untreated HCC rats. Interestingly, treatment with GME elicited marked improvement in the liver histological feature and downregulation of tumor necrosis factor-alpha levels in HCC groups. GME extract may have chemopreventive benefits by reducing the tumor promoting growth factor levels in HCC-induced group.

Conclusion: To sum up, all findings on curative groups had proved clearly that the GME has anticarcinogenic effect on the development of liver cancer induced by DEN in rats.

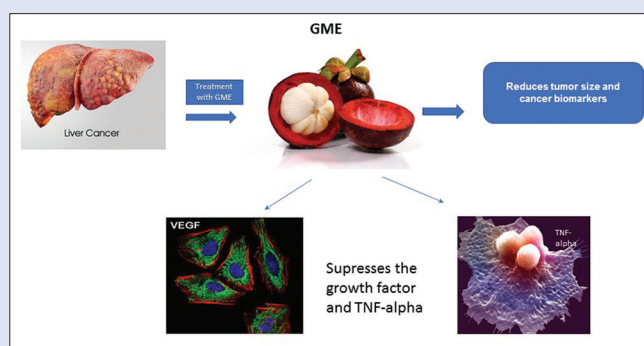
Key words: Cancer markers, diethylnitrosamine, *Garcinia mangostana*,

tumor necrosis factor-alpha, vascular endothelial growth factor

SUMMARY

- Garcinia mangostana* Linn. (GME) may have chemopreventive property by reducing the tumor promoting growth factor and tumor necrosis factor-alpha levels in diethylnitrosamine (DEN)-induced hepatic cancer

- The suppression in the levels of cancer biomarkers by GME due to the presence of anticancer phytoconstituents
- The histological studies proved the effective dose of GME against DEN-induced experimental hepatic cancer.



Abbreviations used: TNF- α : Tumor necrosis factor-alpha, PBS: Phosphate buffered saline, ROS: Reactive oxygen species, DNA: Deoxyribonucleic acid, GSH: Glutathione, VEGF: Vascular endothelial growth factor.

Access this article online

Website: www.phcog.com

Quick Response Code:



Correspondence:

Dr. Mallika Jainu,
Department of Biochemistry, Biogen Care
Research Center, 32/285, Royapettah High
Road, Chennai - 600 014, Tamil Nadu, India.
E-mail: mallikajain@gmail.com
DOI: 10.4103/pm.pm_213_17

INTRODUCTION

Carcinogenesis is a multistage process, by which a normal cell is transformed into a cancerous cell. Transformation involves initiation from typically deoxyribonucleic acid (DNA) damaging agents, promotion during which cell proliferation is increased and progression involving additional genetic alterations.^[1] Diethylnitrosamine (DEN), a hepatocarcinogen, is known to cause perturbations in the nuclear enzymes involved in deoxyribonucleic acid (DNA) repair/replication and is normally used as a carcinogen to induce liver cancer in animal models.^[2] DEN has been shown to be metabolized to its active ethyl radical metabolite, and the reactive product interacts with DNA causing mutation, which would lead to carcinogenesis.^[3,4] Experimental, clinical, and epidemiological studies have provided evidence supporting the role of reactive oxygen species in the etiology of cancer. DEN has been suggested to cause oxidative stress and cellular injury due to the enhanced formation of free radicals.^[5]

Natural products once served humankind of as the source of all drugs and higher plants provided most of these therapeutic agents. The World Health Organization (WHO) estimates that 80% of the people in the developing countries of the world rely on traditional medicine for their health care and about 85% of the traditional medicine involves the use of plant extracts. Drug discovery from medicinal

This is an open access journal, and articles are distributed under the terms of the Creative Commons Attribution-NonCommercial-ShareAlike 4.0 License, which allows others to remix, tweak, and build upon the work non-commercially, as long as appropriate credit is given and the new creations are licensed under the identical terms.

For reprints contact: reprints@medknow.com

Cite this article as: Priya VV, Jainu M, Mohan SK. Biochemical evidence for the antitumor potential of *Garcinia mangostana* Linn. On diethylnitrosamine-induced hepatic carcinoma. *Phcog Mag* 2018;14:186-90.

plants has played an important role in the treatment of cancer and indeed most new applications of plant secondary metabolites and their derivatives over the last half century have been applied toward combating cancer.^[6] Mangosteen, *Garcinia mangostana* L. (*Clusiaceae*), is a tree fairly widespread in Southeast Asian countries, known for its medicinal properties. The edible fruit of this plant is considered to be one of the best of all tropical fruits. The fruit hulls have been in use in Thai folk medicine for the treatment of skin infections, wounds, and diarrhea.^[7] Phytochemical studies have shown that these plant species are rich in a variety of prenylated xanthenes,^[8] and the constituents have demonstrated a number of bioactivities.

Xanthenes and its derivatives have been reported to have neuroprotective activity,^[9] antiulcer,^[10] antioxidant activities,^[11] antimalarial,^[12] antimicrobial,^[13] cytoprotective activity,^[14] and anticancer.^[15] Studies have been conducted to examine the anticancer properties of the extracts or xanthenes obtained from the fruit hulls of this plant species against colon preneoplastic lesions,^[16] human leukemia (HL60, K562, NB4, U937, and P3HR1),^[14] hepatoma carcinoma (HCC36, TONG, HA22T, Hep 3B, HEpG2, and SK-HEp-1), lung (NCI-Hut 125, CH27-LC-1, H2981, and Calu-1), and gastric carcinomas (AZ521, NUGC-3, KATO-III, and AGS) and human breast cancer SKBR3 cells. The autofluorescence and Fourier transform-infrared spectral investigation on DEN-induced hepatocellular carcinoma treated with pericarp extract of *Garcinia mangostana* Linn. (GME) was evident in rats.^[17]

The present study was designed with the aim to determine the chemopreventive effect of pericarp extract of GME which was evaluated in experimental model of DEN-induced hepatocellular carcinoma in rats. An in-depth study was conducted using the carcinogen to enlighten the hepatoprotective effect of pericarp extract of GME in combating the toxins mediated in the biomedical alterations in rats.

MATERIALS AND METHODS

Test drug and chemicals

G. mangostana pericarp extracts powder was obtained from Avesthagen Company, California, USA, as a compliment and was applied for the present investigation. All other chemicals used were of analytical grade.

Animals

Specific and pathogen-free Wistar strain rats were chosen for this study. They were obtained and acclimatized to the laboratory environment. They were housed in polypropylene cages with stainless steel grid covers and bedding material used is paddy or wheat husk. They were groomed in a controlled environment with feed and drinking water provided in polypropylene bottles. Experimental protocols were approved by the Institutional Animal Ethics Committee (IAEC), which follows the guidelines of Committee for the purpose of control and supervision of experiment on Animals and the Guide for the Care and Use of Laboratory Animals. The IAEC approval number for this study was Biochem: 005/2008 and 01/003/10.

Test compound and dose administration levels

Anticarcinogenic test is performed in accordance to the guidelines of WHO 2000 and the Organization of Economic Co-operation and Development (OECD) guideline for testing of chemicals (OECD, 2001). As the toxicity of the compound GME was determined in earlier studies, the drug dose was chosen accordingly.^[18] Six groups of 6 rats each were used for the study. Group I-Normal rats received distilled water (1 ml/kg bwt); Group II-Rats induced with DEN (0.01% DEN through drinking water up to 16 weeks); Group III, IV, and V-Rats induced with DEN (0.01% DEN through drinking water up to 16 weeks and

cotreated with *G. mangostana* extract (200, 400, and 600 mg/kg wt); and Group VI-Rats treated with *G. mangostana* extract (400 mg/kg wt) alone. Food and water were accessible *ad libitum*. Animals were sacrificed after 16 weeks, and livers were dissected and then excised samples of lobes for histological analysis.

Histological examination

After the fixation of the second portion of the liver tissue in formal saline (10%) for 24 h, the tissue were subjected to dehydration using absolute 70% ethyl alcohol followed by embedding in paraffin wax at 56°C. After that, the wax tissue blocks were sectioned by sliding microtome and then prepared for the histological slide examination under the light electric microscope (Olympus Cx21 with attached digital camera) after staining with hematoxylin and eosin stain.

Biochemical analyses

Serum alpha-fetoprotein (AFP) was determined by ELISA using kit purchased from Glory Science Co., Ltd., (USA), according to the manufacturer's instructions provided with AFP assay kit. Serum carcinoembryonic antigen (CEA) was quantified by ELISA using kit purchased from Glory Science Co., Ltd (USA), according to the manufacturer's instructions provided with CEA assay kit. The total protein content of each serum sample was determined using the modified Lowry protein assay; the result was expressed in mg/g.

Determination of vascular endothelial growth factor

Deparaffinized sections were incubated with anti-vascular endothelial growth factor (VEGF) antibody (Santa Cruz Biotechnology, Santa Cruz, CA, USA) overnight at 4°C. After washing with PBS, the sections were incubated with multilink swine immunoglobulin followed by washing with PBS and incubation with avidin-biotin-peroxidase complex. Then placed in 0.02% 3,3'-diaminobenzidine (DAB) and 0.3% nickel ammonium sulfate in 50 mM Tris-HCl buffer (pH 7.4). The color was developed by immersing in the DAB solution containing 0.005% H₂O₂ and examined using light microscope.

Estimation of tumor necrosis factor-alpha

Serum samples were collected and stored at -80°C. Highly specific quantitative "sandwich" ELISA kits for mouse TNF- α were purchased from Pierce Biotechnology, USA. In brief, plates were coated with anti-human TNF- α in PBS (pH 7.3), and nonspecific binding was blocked with 1% bovine serum albumin. Samples and reconstituted TNF- α standard in concentrations ranging from 15 to 1000 pg/ml were added to the wells. Biotinylated polyclonal TNF- α was used as the detection antibody, followed by addition of streptavidin-HRP in dilution buffer. Color was developed using TMB as substrate and OD was taken at 450 nm.

Statistical analysis

The results were expressed as mean \pm standard error of mean. Statistical significance was determined by one-way analysis of variance and *post hoc* least-significant difference test. $P < 0.05$ was considered statistically significant.

RESULTS

Effect of *Garcinia mangostana* Linn. on Tumor markers

The significant ($*P < 0.001$) increase in AFP, CEA, and hydroxylproline levels were evaluated in DEN-administered rats (Group II) which

indicates liver damage and preneoplastic lesion when compared with those in control rats (Group I), in which it was not detected. The total protein was decreased in DEN-administered rats compared with those in control rats (Group I). All the above adverse effects of DEN were gradually suppressed in GME-treated rats according to low-to-high dose. GME alone treated rats showed no detection of AFP and CEA levels as in control rats and the protein levels were significantly increased when compared to control rats [Figure 1].

Effect of *Garcinia mangostana* Linn. on histological observation

The appearance of liver in control group [Figure 2a] showed normal architecture. The DEN-administered rats [Figure 2b] revealed liver damage with big tumor nodules. Interestingly, a mild reduction in proliferation of hepatic cells in GME (200 mg/kg bw) [Figure 2c]-treated rats when compared to DEN-administered rats, whereas 400 mg/kg bw GME-treated rats [Figure 2d] showed reduction of proliferated cells and normal central vein and shrunken nucleus is seen and 600 mg/kg bwt GME-treated rats [Figure 2e] showed very much reduced pathological alterations in hepatic cellular architecture. GME alone treated rats showed normal hepatocytes with no pathological changes [Figure 2f].

Effect of *Garcinia mangostana* Linn. on vascular endothelial growth factor expression

The VEGF protein expression was weak in the intact normal liver tissue. DEN induction markedly increased its expression by more than threefold when compared with the normal hepatic tissue. DEN and GME (400 mg/kg bwt) cotreated liver tissue decreased the VEGF protein expression when compared with the respective DEN control group [Figure 3].

Effect of *Garcinia mangostana* Linn. on tumor necrosis factor-alpha

The levels of anti-inflammatory cytokine TNF- α in DEN-induced rats on administration of GME are presented in Figure 4. Compared with the normal group, the serum levels of TNF- α was significantly ($*P < 0.001$) increased in the DEN-induced group. Administration with GME (400 mg/kg bwt) could reduce the levels of TNF- α even after the induction of DEN.

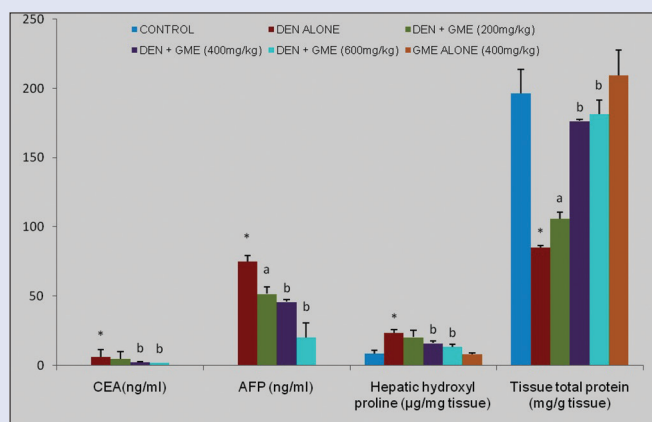


Figure 1: Effect of various doses of *Garcinia mangostana* Linn. on cancer biomarkers in experimental rats. The cancer biomarkers were measured by ELISA technique. Data represent the means \pm standard error of mean, $n = 6$. $*P < 0.001$, statistically significant as compared with control rats and $^bP < 0.01$ and $^aP < 0.05$, statistically significant as compared with diethylnitrosamine-treated rats

DISCUSSION

In recent times, there is an increased risk of malignancy because of environmental pollution such as exposure to genotoxic and carcinogenic chemicals. This has created awareness to prevent the harmful effect of these chemical agents. This has led to the development of several preventive agents. These agents significantly reduce tumor incidence, delay tumor onset and also have minimal long-term toxicity.

Several investigations have provided convincing evidence that N-nitrosamines cause a wide range of tumors in all animal species. These compounds are considered to be effective health hazards to human. Exposure of human to preformed N-nitrosamines occurs through the diet, in certain occupational settings and also due to the use of tobacco products, cosmetics, pharmaceutical products, and agricultural chemicals.^[19]

AFP, a tumor-associated fetal protein, has long been employed as a serum fetal tumor marker to monitor disease progression.^[20] In this study, there was increase in serum AFP and CEA levels on DEN induction associated with increase in tumor growth. The decrease in tumor markers after GME administration might be due to decrease in the production rate of tumors.^[21] CEA levels can be elevated in about half of patients with small cell lung cancer and other malignant melanomas.^[22] Hepatic hydroxyl proline content of HCC rats was found to be significantly higher than that

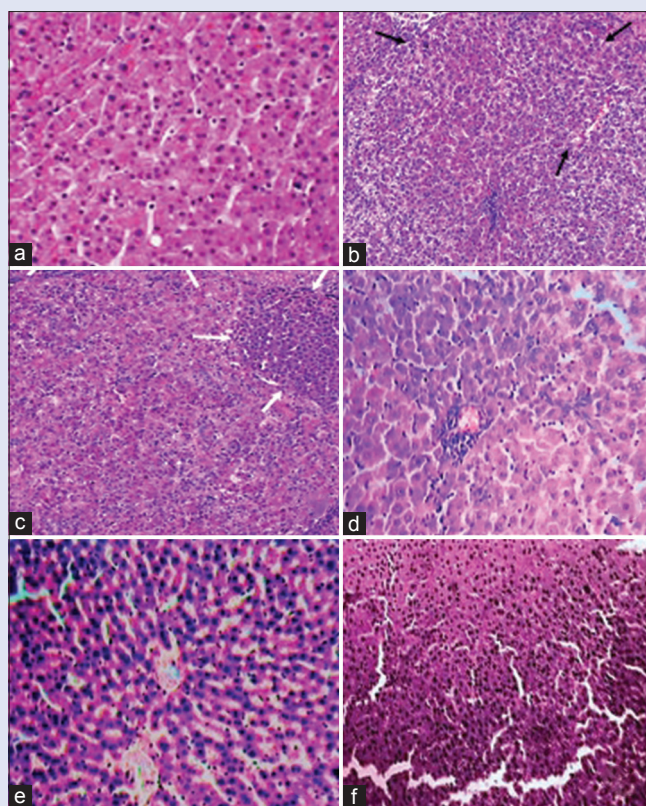


Figure 2: Histologic studies of liver tissue in *Garcinia mangostana* Linn. treated against diethylnitrosamine-induced rats. (a) the normal architecture in control rats; (b) a big tumor nodule (indicated by arrow mark) in diethylnitrosamine-induced rats; (c) reduced size of tumor nodule in diethylnitrosamine + *Garcinia mangostana* Linn. (200 mg/kg bwt)-treated rats; (d) less number of tumor nodules in diethylnitrosamine + *Garcinia mangostana* Linn. (400 mg/kg bwt)-treated rats; (e) minor pathological changes in diethylnitrosamine + *Garcinia mangostana* Linn. (600 mg/kg bwt)-treated rats; (f) normal hepatocytes with no pathological changes in *Garcinia mangostana* Linn. extract alone treated rats

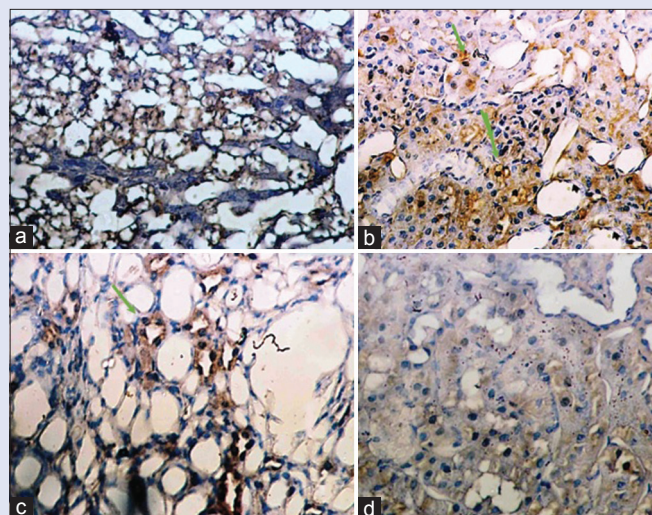


Figure 3: Immunohistochemistry study of vascular endothelial growth factor expressions in normal and experimental groups ($\times 40$). (a and d) Control and *Garcinia mangostana* Linn. alone treated liver tissue showed weak positive expression of vascular endothelial growth factor; (b) diethylnitrosamine-induced liver tissue showed strongly positive vascular endothelial growth factor expression; (c) diethylnitrosamine + *Garcinia mangostana* Linn. (400 mg/kg bwt)-treated rats showed moderated positive vascular endothelial growth factor expression

of control group due to fibrotic activity.^[23] GME treatment significantly reduced this increase in the hepatic hydroxyl proline content to the levels that were close to control rats.

The plasma proteins were reduced in DEN-administered rats which occur as a consequence of decreased synthesis or excessive losses.^[24] The most abundant xanthone from GME, alpha-mangostin was found to suppress the carcinogen-induced formation of adherent crypt foci in a short-term colon carcinogenesis model.^[10] The histological observation showed the presence of tumor nodule, pleomorphism of nuclei, some cells exhibit multiple nucleoli, others are pyknotic, some cells possess intranuclear vacuole and cellular infiltration. Liver tissue of DEN and GME cotreated rats showed very much reduced number of tumor nodules, shrunken nucleus, and less damage to cellular architecture. Earlier studies prove that GME is a powerful drug against DEN-induced HCC by altering the levels of antioxidants and liver marker enzymes favorably at normal condition^[25] which supports the current study.

It has been demonstrated by various investigators that circulating pro-inflammatory cytokines, such as TNF- α and interleukin 6 which triggers hepatic injury, were increased at least in part by a free-radical-mediated apoptotic mechanism.^[26] Augmented production of ROS on DEN induction in GME-treated rats could have been established by the free-radical scavenging potential of alpha-mangostin in preventing the depletion of GSH, thereby contributing to the curtailment in TNF- α expression. Suppressed TNF- α expression by xanthones in the present study is concurrent with the earlier studies.^[27]

The extensive hypervascularity associated HCC is thought to be driven in part by the pro-angiogenic factor known as VEGF.^[28] In the current study, the DEN-induced carcinogenic rats showed increased expression of VEGF in liver tissues. The antiangiogenic properties of alpha-mangostin may be very important to the development of cancer therapies, particularly those involved with molecular targeting in neoplasms. The treatment with alpha-mangostin induces a significant increase in survival and suppression of tumor growth and lymph node metastasis in cancer model carrying a p53 mutation^[29] which is the active constituent

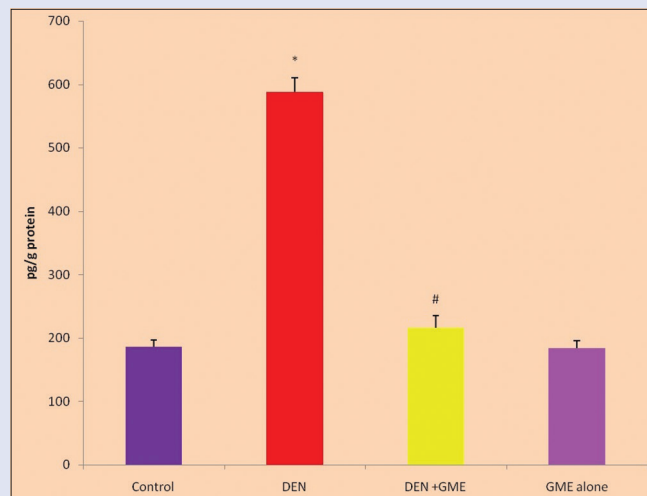


Figure 4: Effect of *Garcinia mangostana* Linn. on tumor necrosis factor-alpha levels in diethylnitrosamine-induced hepatocarcinogenic rats. The concentration of tumor necrosis factor-alpha level was measured by ELISA technique. Data represent the means \pm standard error of mean, $n = 6$. * $P < 0.001$, statistically significant as compared with control rats and # $P < 0.001$ statistically significant as compared with diethylnitrosamine-treated rats

of *G. Mangostana*. In addition, GME may have chemopreventive benefits or as a complementary alternative medicine in the treatment of hepatic cancer by reducing the tumor promoting growth factor levels.

CONCLUSION

The results of the current study shed light on the promising anticancer potential of GME on the hepatocellular carcinoma-induced experimental model through its reduction of growth promoting factor levels and inhibition of cancer marker proteins.

Financial support and sponsorship

Nil.

Conflicts of interest

There are no conflicts of interest.

REFERENCES

- Balunas MJ, Kinghorn AD. Drug discovery from medicinal plants. *Life Sci* 2005;78:431-41.
- Bhosale P, Motiwale L, Ignle AD, Gadre RV, Rao KV. Protective effect of *Rhodotorula glutinis* NCIM3353 on the development of hepatic preneoplastic lesions. *Curr Sci* 2002;83:303-8.
- Anis KV, Rajeshkumar NV, Kuttan R. Inhibition of chemical carcinogenesis by berberine in rats and mice. *J Pharm Pharmacol* 2001;53:763-8.
- Chakraborty T, Chatterjee A, Rana A, Dhachinamoorthi D, Kumar PA, Chatterjee M, et al. Carcinogen-induced early molecular events and its implication in the initiation of chemical hepatocarcinogenesis in rats: Chemopreventive role of vanadium on this process. *Biochim Biophys Acta* 2007;1772:48-59.
- Valko M, Rhodes CJ, Moncol J, Izakovic M, Mazur M. Free radicals, metals and antioxidants in oxidative stress-induced cancer. *Chem Biol Interact* 2006;160:1-40.
- Newman LA, Kuerer HM, Hunt KK, Ames FC, Ross MI, Feig BW, et al. Response to induction chemotherapy in black and white patients with locally advanced breast cancer. *Breast J* 2000;6:242-6.
- Mahabusarakam W, Wiriyaichitra P, Taylor WC. Chemical constituents of *Garcinia mangostana*. *J Nat Prod* 1987;50:474-8.
- Peres V, Nagem TJ, de Oliveira FF. Tetraoxygenated naturally occurring xanthones. *Phytochemistry* 2000;55:683-710.

9. Pedraza-Chaverri J, Cárdenas-Rodríguez N, Orozco-Ibarra M, Pérez-Rojas JM. Medicinal properties of mangosteen (*Garcinia mangostana*). *Food Chem Toxicol* 2008;46:3227-39.
10. Suksamrarn S, Komutiban O, Ratananukul P, Chimnoi N, Lartpormmatulee N, Suksamrarn A, *et al.* Cytotoxic prenylated xanthenes from the young fruit of *Garcinia mangostana*. *Chem Pharm Bull (Tokyo)* 2006;54:301-5.
11. Yu L, Zhao M, Yang B, Zhao Q, Jiang Y. Phenolics from hull of *Garcinia mangostana* fruit and their antioxidant activities. *Food Chem* 2007;104:176-8.
12. Nakatani K, Nakahata N, Arakawa T, Yasuda H, Ohizumi Y. Inhibition of cyclooxygenase and prostaglandin E2 synthesis by gamma-mangostin, a xanthone derivative in mangosteen, in C6 rat glioma cells. *Biochem Pharmacol* 2002;63:73-9.
13. Vishnu Priya V, Mallika J, Mohan SK, Saraswathi P, Chandra Sada Gopan V. Antimicrobial activity of pericarp extract of *Garcinia mangostana* linn. *Int J Pharma Sci Res* 2010;1:278-81.
14. Moongkarndi P, Kosem N, Kaslungka S, Luanratana O, Pongpan N, Neungton N, *et al.* Antiproliferation, antioxidation and induction of apoptosis by *Garcinia mangostana* (mangosteen) on SKBR3 human breast cancer cell line. *J Ethnopharmacol* 2004;90:161-6.
15. Akao Y, Nakagawa Y, Iinuma M, Nozawa Y. Anti-cancer effects of xanthenes from pericarps of mangosteen. *Int J Mol Sci* 2008;9:355-70.
16. Nabandith V, Suzui M, Morioka T, Kaneshiro T, Kinjo T, Matsumoto K, *et al.* Inhibitory effects of crude alpha-mangostin, a xanthone derivative, on two different categories of colon preneoplastic lesions induced by 1, 2-dimethylhydrazine in the rat. *Asian Pac J Cancer Prev* 2004;5:433-8.
17. Vishnu Priya V, Sankari G, Jainu M, Mohan SK, Saraswathi P, Chandra Sada Gopan V. Auto fluorescence and fourier transform – Infrared (FTIR) spectral investigation on di ethyl nitrosamine (DEN) induced hepatocellular carcinoma, treated with pericarp extract of *Garcinia mangostana* linn in rats. *J Clin Diagn Res* 2010;4:3289-97.
18. Vishnu Priya V, Mallika J, Krishna Mohan S, Karthik B. Toxicity study of *Garcinia Mangostana* Linn. Pericarp extract in rats. *Asian J Exp Biol Sci* 2010;1:633-7.
19. Ashwaq AS, Al-Qubaisi MS, Rasedee A, Abdul AB, Taufiq-Yap YH, Yeap SK, *et al.* Inducing G2/M cell cycle arrest and apoptosis through generation reactive oxygen species (ROS)-mediated mitochondria pathway in HT-29 cells by Dentatin (DEN) and Dentatin incorporated in hydroxypropyl- β -cyclodextrin (DEN-HP β CD). *Int J Mol Sci* 2016;17: pii: E1653.
20. Wu L, Hu A, Tam N, Zhang J, Lin M, Guo Z, *et al.* Salvage liver transplantation for patients with recurrent hepatocellular carcinoma after curative resection. *PLoS One* 2012;7:e41820.
21. Srigopalram S, Ilavenil S, Indira, Jayraaj A. Apoptosis associated inhibition of DEN-induced hepatocellular carcinogenesis by ellagic acid in experimental rats. *Biomed Prev Nutr* 2012;2:1-8.
22. Hiroshima Y, Lwin TM, Murakami T, Mawy AA, Kuniya T, Chishima T, *et al.* Effective fluorescence-guided surgery of liver metastasis using a fluorescent anti-CEA antibody. *J Surg Oncol* 2016;114:951-8.
23. Wang L, Potter JJ, Rennie-Tankersley L, Novitskiy G, Sipes J, Mezey E, *et al.* Effects of retinoic acid on the development of liver fibrosis produced by carbon tetrachloride in mice. *Biochim Biophys Acta* 2007;1772:66-71.
24. Joseph JM, Gross N, Lassau N, Rouffiac V, Opolon P, Laudani L, *et al.* *In vivo* echographic evidence of tumoral vascularization and microenvironment interactions in metastatic orthotopic human neuroblastoma xenografts. *Int J Cancer* 2005;113:881-90.
25. Vishnu Priya V, Krishna Mohan S, Mallika J Chandra Sada Gopan VS. Ameliorating effects of *Garcinia mangostana* Linn pericarp extract on hepatic antioxidants in Diethyl nitrosamine (DEN) induced hepatocellular carcinoma (HCC). *Ind J Pharm Educ Res* 2015;49:329-37.
26. Aoubakr EM, Taye A, Aly OM, Gamal-Eldeen AM, El-Moselhy MA. Enhanced anticancer effect of combretastatin A-4 phosphate when combined with vincristine in the treatment of hepatocellular carcinoma. *Biomed Pharmacother* 2017;89:36-46.
27. Dai Z, Jiang DJ, Hu GY, Du YH, Yu J, Hu CP, *et al.* 3,4,5,6-tetrahydroxyxanthone protects against myocardial ischemia-reperfusion injury in rats. *Cardiovasc Drugs Ther* 2004;18:279-88.
28. Pang RW, Poon RT. Clinical implications of angiogenesis in cancers. *Vasc Health Risk Manag* 2006;2:97-108.
29. Shibata MA, Iinuma M, Morimoto J, Kurose H, Akamatsu K, Okuno Y, *et al.* A-mangostin extracted from the pericarp of the mangosteen (*Garcinia mangostana* linn) reduces tumor growth and lymph node metastasis in an immunocompetent xenograft model of metastatic mammary cancer carrying a p53 mutation. *BMC Med* 2011;9:96.