

Cystic adventitial disease of popliteal artery with significant stenosis

Ranjana Gupta, Puneet Mittal, Praveen Gupta¹, Nancy Jindal

Departments of Radiodiagnosis, and ¹Medicine, Maharishi Markandeshwer Institute of Medical Sciences and Research, Mullana, Ambala, Haryana, India

Correspondence: Dr. Puneet Mittal, 448, Opp. Singla Memorial Hospital, Prem Basti, Sangrur, Punjab - 148 001, India.
E-mail: drpuneetmittal@gmail.com

Abstract

Cystic adventitial disease of popliteal artery is a rare condition of unknown etiology which usually presents in middle-aged men. We present Doppler and computed tomography angiography findings in a case of cystic adventitial disease with significant obstruction of popliteal artery, with secondary narrowing of popliteal vein.

Key words: Adventitial; cystic; popliteal; computed tomography angiography

Introduction

Cystic adventitial disease most commonly affects popliteal artery and is a rare cause of intermittent claudication in middle-aged non-smoking men.^[1] It is an important treatable cause of vascular disease in non-smokers because it can be readily diagnosed with the currently available imaging techniques.

Case Report

A 40-year-old male patient presented with complaints of intermittent claudication in the right lower limb for past 6 months. There was no history of fever, trauma, diabetes mellitus, or hypertension. He was an occasional smoker. There were no other significant associated complaints. Physical examination revealed diminished pulses in right lower limb arteries, for which Doppler USG (ultrasound) examination was requested. Doppler study revealed multiloculated cystic lesion in relation to the popliteal artery, causing significant

luminal narrowing with dampened low resistance flow in distal arteries [Figure 1]. It was also causing focal narrowing of popliteal vein. Subsequently, the patient underwent computed tomography angiography (CTA) on 128-slice multidetector computed tomography (MDCT) scanner (Ingenuity CT, Philips Healthcare, Cleveland, OH, USA). CTA revealed multiloculated cystic lesion in relation to right popliteal artery, with mild peripheral enhancement. There was significant focal eccentric narrowing of popliteal artery. Distal vessels were normally opacified. It was also causing narrowing of popliteal vein [Figure 2]. Based on the characteristic imaging findings, diagnosis of cystic adventitial disease of popliteal artery was made. Patient underwent surgery with partial resection of the cysts and the diagnosis was confirmed on histopathology. Patient improved symptomatically. Postoperative CTA revealed significant reduction of cystic disease and reduction of popliteal artery stenosis [Figure 3].

Discussion

Cystic adventitial disease was reported by Atkins and Key^[2] in a case affecting the external iliac artery. It most commonly affects popliteal artery; however, involvement of other arteries like axillary, brachial, radial, ulnar, and common femoral has also been reported. Rarely, it can also affect the veins.^[3] It more commonly affects males in their 4th or 5th decade, compared to females, with a male:female ratio of 5:1, with unilateral disease being more common.^[3,4] However, bilateral cases have also been reported.^[3,5]

Access this article online

Quick Response Code:



Website:
www.ijri.org

DOI:
10.4103/0971-3026.116572

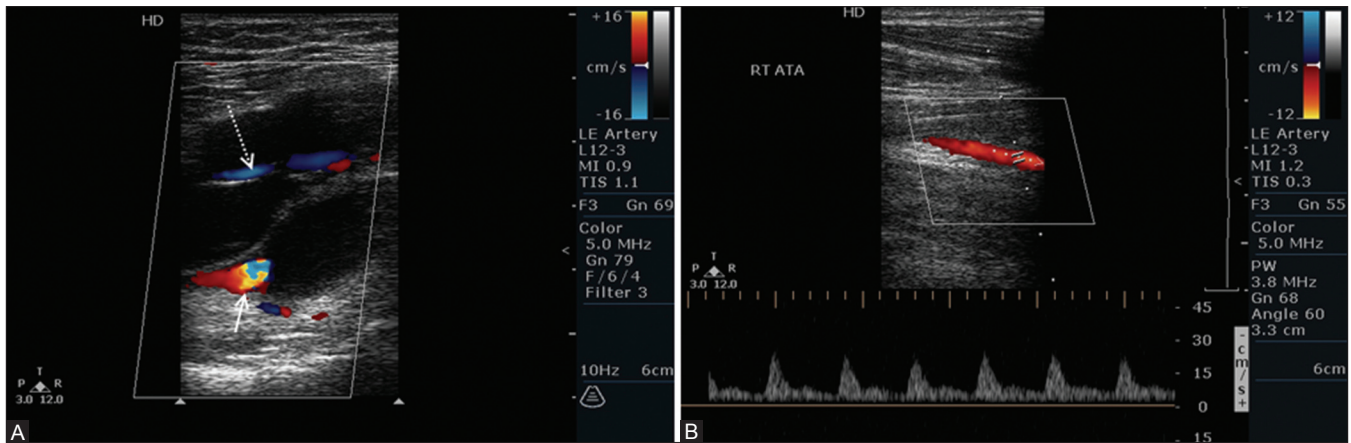


Figure 1 (A, B): (A) Color doppler image showing multilocular cystic lesion with no internal flow in the popliteal region causing narrowing of popliteal artery (white arrow) and vein (dotted white arrow). (B) Spectral doppler image shows dampened low resistance flow in right anterior tibial artery

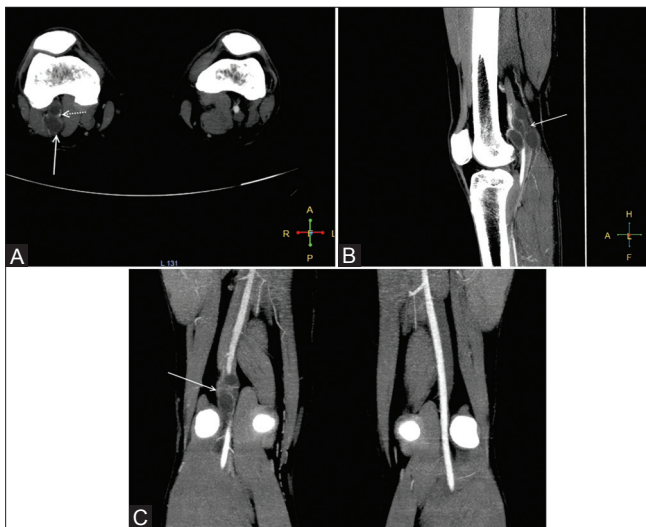


Figure 2 (A-C): (A) Axial, (B) Sagittal and (C) Coronal CT angiography images show multiseptated cystic lesion (white arrow) causing marked eccentric narrowing of popliteal artery (dotted white arrow in A). Contralateral normal popliteal artery is seen in C

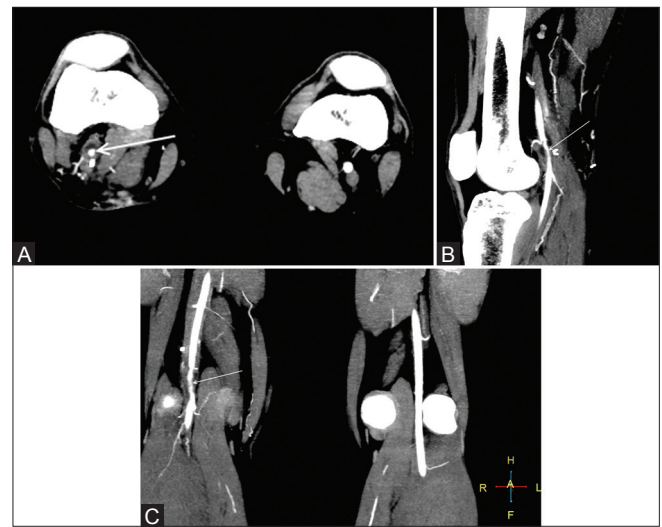


Figure 3 (A-C): (A) Axial, (B) Sagittal and (C) Coronal CT angiography images show mild residual cystic disease with reduction in popliteal artery stenosis (white arrow)

The exact etiology of the disease remains uncertain; however, various theories have been put forward. Degenerative theory considers it to be manifestation of systemic myxomatous degenerative process. However, it has been disputed due to lack of any other systemic manifestations in most reported cases. Traumatic theory considers it to be due to repetitive microtrauma with resultant intramural microbleeds with subsequent cystic degeneration. Synovial theory postulates that the adventitial cysts are in fact ectopic ganglions that originated from synovial structures of adjoining knee joint which might have migrated retrogradely along articular branches of popliteal artery. The most plausible theory for the origin of disease is developmental theory which states that during development, undifferentiated mesenchymal cells from the adjacent joint migrate into the adventitia of the artery. These cells secrete mucinous material later in life, which results in the manifestation of the disease.^[3-6]

Cystic adventitial disease usually manifests with intermittent claudication due to arterial stenosis which can even progress to complete occlusion.^[3,7] Sometimes, obstruction may be dynamic so that it only manifests during exercise, while imaging studies done in resting state may fail to show any stenosis.^[5] Usually there is no evidence of atherosclerotic disease in other arteries.^[3,5]

On USG, cysts appear as unilocular or multilocular cystic masses in relation to the popliteal artery. Doppler USG shows no flow within the cysts, thus helping to differentiate it from pseudoaneurysm. Doppler USG is also helpful for demonstrating vascular stenosis.^[5,8]

Magnetic resonance imaging (MRI) with magnetic resonance angiography (MRA) is very helpful in the diagnosis as it provides excellent anatomic detail with cysts appearing as hyperintense structure on T2W images

and luminal compromise can also be assessed. CTA can provide similar information with cysts appearing as hypoattenuating structures, which may sometimes show peripheral enhancement. Digital subtraction angiography is not preferred for diagnosis as it is only diagnostic if specific pattern of luminal narrowing is demonstrated. If there is no stenosis, angiography may be normal.^[3,5]

Imaging differential diagnosis of cystic adventitial disease includes partially thrombosed aneurysm, Baker's cyst, ganglion cyst, and parameniscal cyst. Cystic adventitial disease may be difficult to differentiate from partially thrombosed aneurysm on Doppler USG; however, multilocular cysts favor cystic adventitial disease. Moreover, MRA and CTA are diagnostic by demonstrating lack of vascular dilatation. Other cystic lesions can be distinguished because of their characteristic location.^[5]

Many treatment methods have been tried. Percutaneous aspiration has been tried, but recurrence rate is high. Results of endovascular treatments are disappointing and should be avoided as they can cause intimal injury which otherwise is healthy in this disease. The preferred treatment in symptomatic patients is incision of the cysts with evacuation of its contents as was done in our case. In cases with complete occlusion, resection with bypass grafting is required.^[1] There are also reports of spontaneous resolution of the cystic disease;^[9] however, long-term follow-up is unknown and even recurrences after spontaneous resolution have been reported.^[10]

In conclusion, although rare, cystic adventitial disease should be included in the differential diagnosis of intermittent claudication, especially in young and middle-aged men. Doppler USG supplemented with CTA

or MRA is helpful in the diagnosis.

References

1. Michaelides M, Pervana S, Sotiridadis C, Tsitouridis I. Cystic adventitial disease of the popliteal artery. *Diagn Interv Radiol* 2011;17:166-8.
2. Atkins HJ, Key JA. A case of myxomatous tumour arising in the adventitia of the left external iliac artery; case report. *Br J Surg* 1947;34:426.
3. Drac P, Köcher M, Utikal P, Cerna M, Kozak J, Bachleda P. Cystic adventitial disease of the popliteal artery: Report on three cases and review of the literature. *Biomed Pap Med Fac Univ Palacky Olomouc Czech Repub* 2011;155:309-21.
4. Monroe E, Ha A. Cystic adventitial disease of the popliteal artery. *J Radiol Case Rep* (Online) 2011;6:558. Available from <http://www.radiology.casereports.net/index.php/rcr/article/viewArticle/558/881>. (last assessed 2013 Feb 7).
5. França M, Pinto J, Machado R, Fernandez GC. Case 157: Bilateral adventitial cystic disease of the popliteal artery. *Radiology* 2010;255:655-60.
6. Levien LJ, Benn CA. Adventitial cystic disease: A unifying hypothesis. *J Vasc Surg* 1998;28:193-205.
7. Samson RH, Willis PD. Popliteal artery occlusion caused by cystic adventitial disease: Successful treatment by urokinase followed by nonresectional cystotomy. *J Vasc Surg* 1990;12:591-3.
8. Chappel P, Gielen J, Salgado R, Van Dyck P, Vanhoenacker FM. Cystic adventitial disease with secondary occlusion of the popliteal artery. *JBR-BTR* 2007;90:180-1.
9. Pursell R, Torrie EP, Gibson M, Galland RB. Spontaneous and permanent resolution of cystic adventitial disease of the popliteal artery. *J R Soc Med* 2004;97:77-8.
10. Zhang L, Guzman R, Kirkpatrick I, Klein J. Spontaneous resolution of cystic adventitial disease: A word of caution. *Ann Vasc Surg* 2012;26:422.e1-4.

Cite this article as: Gupta R, Mittal P, Gupta P, Jindal N. Cystic adventitial disease of popliteal artery with significant stenosis. *Indian J Radiol Imaging* 2013;23:148-50.

Source of Support: Nil, **Conflict of Interest:** None declared.