

## CASE REPORT

# Catastrophic intracranial hemorrhage associated with eosinophilic granulomatous polyangiitis in a patient after Fontan operation

Hiroki Ezaki<sup>1,2</sup> | Jun Muneuchi<sup>1,2</sup>  | Naoyuki Imamoto<sup>1,2</sup>

<sup>1</sup>Department of Pediatrics, Japan Community Healthcare Organization Kyushu Hospital, Kitakyushu, Japan

<sup>2</sup>Department of Neurosurgery, Japan Community Healthcare Organization Kyushu Hospital, Kitakyushu, Japan

## Correspondence

Jun Muneuchi, Department of Pediatrics, Japan Community Healthcare Organization Kyushu Hospital, 1-8-1, Kishinoura, Yahatanishi-ku, Kitakyushu, Fukuoka 806-8501, Japan.

Email: jmune@msn.com

## Abstract

A 29-year-old man after the Fontan operation had a catastrophic intracranial hemorrhage associated with eosinophilic granulomatous polyangiitis. Despite combination therapy with cyclophosphamide and methylprednisolone, he was dead at 6 months after the onset. The clinical course was worse owing to underlying coagulopathy and endothelial dysfunction associated with congenital heart disease.

## Key Clinical Message

The majority of patients with complex congenital heart disease survive into adulthood. Potential endothelial dysfunction and coagulopathy can attribute to unexpected clinical manifestations of other extracardiac disease among them.

## KEYWORDS

Churg-Strauss syndrome, Fontan operation, neurological complication

## 1 | INTRODUCTION

Eosinophilic granulomatosis with polyangiitis (EGPA), formerly called Churg-Strauss syndrome, is a multiorgan disorder characterized by a small-vessel necrotizing vasculitis and extravascular eosinophilic granulomatous formation, associated with antineutrophil cytoplasmic antibodies (ANCA) and hypereosinophilic syndrome.<sup>1</sup> The clinical manifestations in EGPA are heterogeneous as both vascular inflammation and eosinophilic proliferation insult systemic multiple organs. However, their roles in EGPA are not fully understood. ANCA-positive patients have a higher prevalence of peripheral neuropathy, glomerulonephritis, and purpura, compared with myocardial involvement, lung infiltrates, and gastrointestinal symptoms, which are more prevalent in the ANCA-negative patients.<sup>2,3</sup> The prevalence of central nervous system involvement is 6%-10%; cerebral infarction and

diffuse encephalopathy are the most common features in patients with EGPA. We herein present a notable case of a 29-year-old male after the Fontan operation who had a catastrophic intracranial hemorrhage associated with EGPA.

## 2 | CASE PRESENTATION

A 29-year-old man was admitted to our hospital because of persistent fever and bilateral leg pain. The present patient had undergone a staged repair of tricuspid atresia to Fontan operation at 3 years of age. He had been doing well as New York Heart Association functional class I. Following a cardiac catheterization at 10 years of age, he had an acceptable hemodynamic status as shown by a central venous pressure and cardiac index were 14 mm Hg and cardiac index of 5.6 L/min/m<sup>2</sup>, respectively. He was regularly followed up every

This is an open access article under the terms of the Creative Commons Attribution-NonCommercial-NoDerivs License, which permits use and distribution in any medium, provided the original work is properly cited, the use is non-commercial and no modifications or adaptations are made.

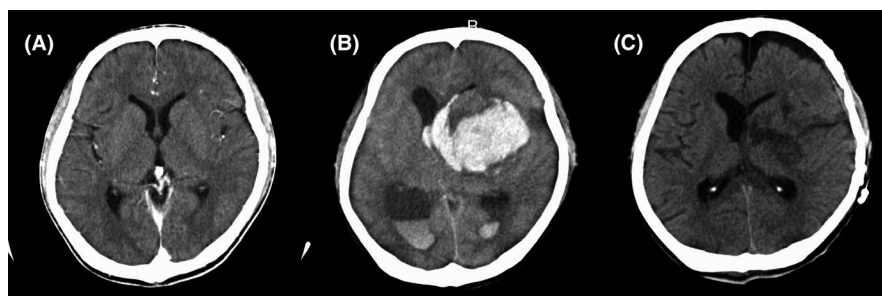© 2020 The Authors. *Clinical Case Reports* published by John Wiley & Sons Ltd.

3 months at the outpatient clinic in our hospital and treated with low-dose aspirin and an angiotensin converting enzyme inhibitor. He had fever, pain, and bilateral leg numbness for 2 months, for which he was administered an antimicrobial agent and warfarin, and was instructed to wear elastic stockings at the referred hospital because of the suspicion of deep venous thrombosis associated with infection. However, a contrast-enhanced computed tomography (CT) scan showed no findings associated with venous thrombosis. On admission to our hospital, he had pain and bilateral leg numbness, with body temperature of 38.6°C, heart rate of 78 beats per minute, systemic oxygen saturation of 94%, and blood pressure of 120/75 mm Hg. His neurological examination showed no central nervous deficiency or impairment of motor and sensory nerves. His deep tendon reflexes on the upper and lower limbs were normal. Bilateral expiratory rhonchi were heard on chest auscultation. No heart murmur, rubs, or gallop were found on cardiac examination. Hepatomegaly due to Fontan-associated liver disease was present. A chest radiograph showed a cardiothoracic ratio of 0.41 and mild infiltration of the lung. His blood counts and biochemistry investigation results were as the follows: white blood cell:  $12.4 \times 10^9/L$  (neutrophil 86%, lymphocyte 5.5%, monocyte 6.5%, eosinophil 1.2%, basophil 0.2%), hemoglobin: 125 g/L, platelet:  $161 \times 10^9/L$ , serum albumin: 22 g/L (reference range [rr]: 41–52 g/L), creatinine: 42.4  $\mu\text{mol/L}$  (rr: 53–106  $\mu\text{mol/L}$ ), and C-reactive protein: 149 mg/L (rr: <8.2 mg/L). Coagulation studies showed an international ratio of prothrombin time of 0.32, and D-dimer levels of 48.2 nmol/dL (rr: <5.4 nmol/dL). Urinalysis showed neither hematuria nor proteinuria. A few days after admission, he developed skin macular rashes on the trunk and limbs. Further examinations for fever of unknown origin revealed an elevation of serum myeloperoxidase (MPO)–antineutrophil cytoplasmic antibody (ANCA) > 300 U/mL (rr: <3.5 U/mL). We performed full-body contrast-enhanced CT, which was unremarkable. Brain CT image and angiography showed no remarkable findings (Figures 1A and 2). A skin biopsy at the lower limb revealed an infiltration of eosinophils around the small vessels, without granulomatous formation or deposition of immunoglobulin of complements

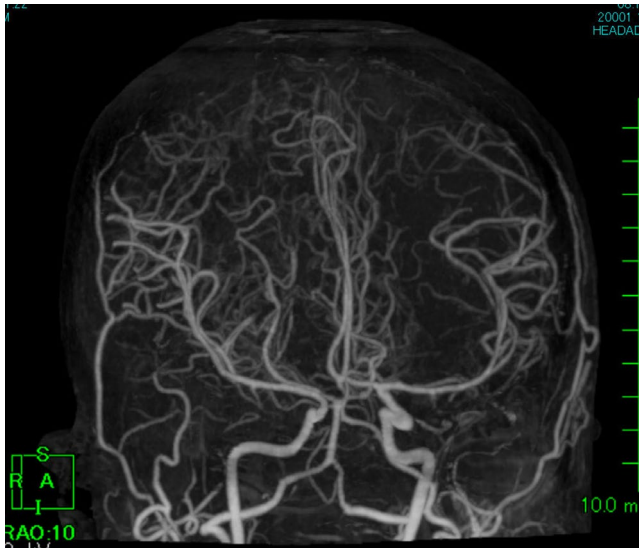
(Figure 3). Four findings which satisfied the diagnostic criteria for EGPA were present, namely expiratory rhonchi, transient pulmonary infiltration, histopathologically proven vasculitis with extravascular eosinophilia, and polyneuropathy. He was then treated with oral cyclophosphamide and prednisolone. However, snoring and alteration of consciousness were noted in the early morning on 8th days after admission. An emergency brain CT scan showed an intracranial hemorrhage from the putamen (Figure 1B). We decided to perform an emergency intracranial drainage after acquiring informed consent provided by his parents. Under general anesthesia, a craniotomy was performed after the left craniotomy. The intracranial hematoma was removed macroscopically, and the hematoma in the deep ventricle was removed microscopically. After the removal of the intracranial hematoma, a drainage tube was placed in the ventricle. The skin was closed remaining the craniotomy. Subsequently, he was admitted to the intensive care units. His arterial and central venous blood pressures were monitored by indwelled lines to confirm his hemodynamic stability. The external drainage tube was placed for 2 days. Despite the emergent removal of hematoma (Figure 1C), he was bedridden due to severe neurological sequelae. We continued treatment with cyclophosphamide and prednisolone. However, he presented with persistent fever, with an elevation of C-reactive protein and leukocytosis. After numerous discussions between our healthcare team and his family, we concluded that further administration of immunosuppressive agents was not indicated and that conservative cares were needful. On the 6th months of the illness, he had recurrent melena, probably due to intestinal bleeding. Unfortunately, he was died on the 6th months of the illness, due to the hemorrhage shock.

### 3 | DISCUSSION

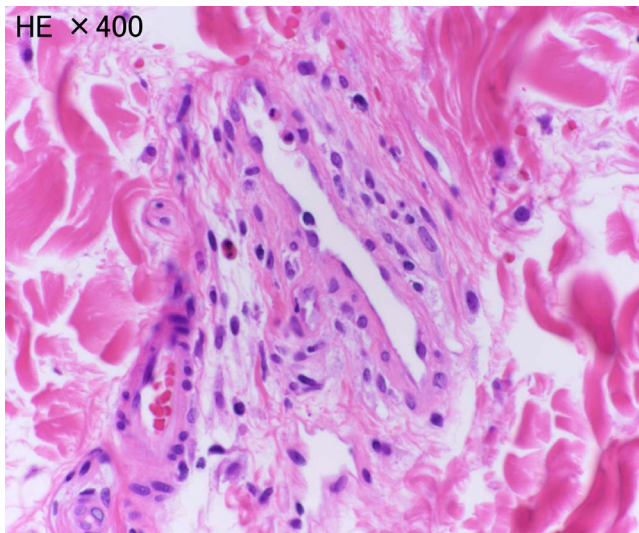
We present a notable case of a patient after the Fontan operation who present with a catastrophic intracranial hemorrhage, diagnosed as EGPA. Recent advances in surgical and clinical managements allow children with complex congenital heart



**FIGURE 1** Temporal head CT images are shown. A CT image on admission (A) showed no remarkable finding. When the patient presented with consciousness disturbance, a CT image (B) showed a massive hematoma extending to the ventricle from the left putamen. A CT image after the removal of hematoma (C) showed that hematoma was effectively evacuated without recurrent hemorrhage



**FIGURE 2** Computed tomography angiography on admission showed neither aneurysm nor arteriovenous malformation



**FIGURE 3** The histopathological finding of a skin biopsy specimen is shown (400 × 400). Eosinophils infiltrate around small vessels without a granulomatous formation

disease to survive into adulthood. The number of patients who undergo the Fontan operation, which is the final palliative surgery, continues to increase yearly. Therefore, adults after the Fontan operation have an increasing chance of being affected by other systemic diseases. The circulation after a Fontan operation is characterized by the lack of a subpulmonary ventricle, which leads to elevated central venous pressure and decreased cardiac output. Thromboembolic complications occur in 4%-20% of patients after the Fontan operation responsible for a sluggish flow in the absence of a pump, flow turbulence related to the anatomical properties, abnormalities in coagulation factors,<sup>4</sup> and endothelial dysfunction due to

the previous hypoxia.<sup>5</sup> Ohuchi et al<sup>6</sup> described that hemorrhagic events are more common than thromboembolic events in patients who underwent the Fontan patients, which may be due to inappropriate anticoagulation therapy. Fontan patients managed with warfarin are at risk, not only for thromboembolic events, but also for hemorrhagic events.<sup>7</sup> Our present patient was not treated with warfarin, but low-dose aspirin as an antithrombotic treatment, which did not contribute to the development for the intracranial hemorrhage.

Central nervous hemorrhage occasionally occurs in patients with EGPA, whereas it is extremely rare in other types of ANCA-related angiitis, including granulomatosis with polyangiitis and microscopic polyangiitis. Hemorrhagic lesions associated with EGPA are characterized by intraventricular, subarachnoid, and/or intracerebral hemorrhages. Patients with EGPA-related cerebral hemorrhage have features consistent with extensive structural damage of vasculatures and eosinophil-related tissue damage.<sup>8</sup> However, previous reports have shown that patients with cerebral infarction associated with EGPA frequently have cardiac involvement and that hemorrhage after cerebral infarction may be a potential cause among them. Therefore, we assumed that concurrence with potential endothelial dysfunction and coagulopathy associated with Fontan operation and extensive structural damage of vasculatures associated with EPGA might be attributable to develop catastrophic intracranial hemorrhage in our present case.

## 4 | CONCLUSIONS

We present a notable case of an adult after the Fontan operation, who presented with catastrophic intracranial hemorrhage, which is responsible for potential endothelial dysfunction associated with the Fontan operation and an extensive structural damage of vasculature associated with EPGA. It is possible for adults after the Fontan operation to develop unexpected manifestation when they acquire other systemic disease.

## CONFLICT OF INTEREST

The authors declare that they have no competing interests.

## AUTHOR CONTRIBUTIONS

HE, JM, and NI: were actively involved in the clinical care of the patient. HE wrote the manuscript. JM: revised the manuscript.

## ETHICAL APPROVAL

This work does not involve any human/animal experimentation.

## INFORMED CONSENT

Written informed consent was obtained from the patient family.

## DATA AVAILABILITY STATEMENT

All data will be offered if applicable.

## ORCID

Jun Muneuchi  <https://orcid.org/0000-0003-0500-2585>

## REFERENCES

1. Greco A, Rizzo MI, De Virgilio A, et al. Churg–Strauss syndrome. *Autoimmun Rev*. 2015;14(4):341-348.
2. Sinico RA, Di Toma L, Maggiore U, et al. Prevalence and clinical significance of antineutrophil cytoplasmic antibodies in Churg–Strauss syndrome. *Arthritis Rheum*. 2005;52(9):2926-2935. <https://doi.org/10.1002/art.21250>
3. Sablé-Fourtassou R, Cohen P, Mahr A, et al. Antineutrophil cytoplasmic antibodies and the Churg–Strauss syndrome. *Ann Intern Med*. 2005;143(9):632. <https://doi.org/10.7326/0003-4819-143-9-200511010-00006>
4. Viswanathan S. Thromboembolism and anticoagulation after fontan surgery. *Ann Pediatr Cardiol*. 2016;9(3):236. <https://doi.org/10.4103/0974-2069.189109>
5. Jin SM, Il NC, Bae EJ, Choi JY, Yun YS. Impaired vascular function in patients with Fontan circulation. *Int J Cardiol*. 2007;120(2):221-226. <https://doi.org/10.1016/j.ijcard.2006.09.020>
6. Ohuchi H, Yasuda K, Miyazaki A, et al. Prevalence and predictors of haemostatic complications in 412 Fontan patients: their relation to anticoagulation and haemodynamics. *Eur J Cardio-thoracic Surg*. 2015;47(3):511-519. <https://doi.org/10.1093/ejcts/ezu145>
7. Faircloth JM, Miner KM, Alsaied T, et al. Time in therapeutic range as a marker for thrombotic and bleeding outcomes in Fontan patients. *J Thromb Thrombolysis*. 2017;44(1):38-47. <https://doi.org/10.1007/s11239-017-1499-8>
8. André R, Cottin V, Saraux JL, et al. Central nervous system involvement in eosinophilic granulomatosis with polyangiitis (Churg–Strauss): Report of 26 patients and review of the literature. *Autoimmun Rev*. 2017;16(9):963-969. <https://doi.org/10.1016/j.autrev.2017.07.007>

**How to cite this article:** Ezaki H, Muneuchi J, Imamoto N. Catastrophic intracranial hemorrhage associated with eosinophilic granulomatous polyangiitis in a patient after Fontan operation. *Clin Case Rep*. 2021;9:547–550. <https://doi.org/10.1002/ccr3.3579>