



## Standards and Guidelines

# SCAI Expert Consensus Statement on the Management of Patients With STEMI Referred for Primary PCI



Jacqueline E. Tamis-Holland, MD, FSCAI (Chair)<sup>a,\*</sup>, J. Dawn Abbott, MD, FSCAI<sup>b</sup>, Karim Al-Azizi, MD, FSCAI<sup>c</sup>, Nitin Barman, MD<sup>d</sup>, Anna E. Bortnick, MD, PhD, MSc, FSCAI<sup>e</sup>, Mauricio G. Cohen, MD, FSCAI<sup>f</sup>, Payam Dehghani, MD, FSCAI<sup>g</sup>, Timothy D. Henry, MD, MSCAI<sup>h</sup>, Faisal Latif, MD, FSCAI<sup>i</sup>, Mohammad Madjid, MD, FSCAI<sup>j</sup>, Celina M. Yong, MD, MBA, MSc, FSCAI<sup>k,l</sup>, Yader Sandoval, MD, FSCAI (Co-Chair)<sup>m</sup>

<sup>a</sup> Cleveland Clinic Heart, Vascular & Thoracic Institute, Cleveland, Ohio; <sup>b</sup> Lifespan Cardiovascular Institute, Warren Alpert Medical School of Brown University, Providence, Rhode Island; <sup>c</sup> Baylor Scott & White The Heart Hospital – Plano, Plano, Texas; <sup>d</sup> Mount Sinai Morningside, New York, New York; <sup>e</sup> Montefiore Medical Center and Albert Einstein College of Medicine, Bronx, New York; <sup>f</sup> Cleveland Clinic Florida, Weston, Florida; <sup>g</sup> University of Saskatchewan College of Medicine, Regina, Saskatchewan, Canada; <sup>h</sup> The Carl and Edyth Lindner Center for Research and Education at The Christ Hospital, Cincinnati, Ohio; <sup>i</sup> SSM Health St. Anthony Hospital and University of Oklahoma, Oklahoma City, Oklahoma; <sup>j</sup> David Geffen School of Medicine at UCLA, Los Angeles, California; <sup>k</sup> Stanford University School of Medicine, Stanford, California; <sup>l</sup> Palo Alto Veterans Affairs Healthcare System, Palo Alto, California; <sup>m</sup> Minneapolis Heart Institute, Abbott Northwestern Hospital, and Center for Coronary Artery Disease, Minneapolis Heart Institute Foundation, Minneapolis, Minnesota

## ABSTRACT

ST-elevation myocardial infarction (STEMI) remains a leading cause of morbidity and mortality in the United States. Timely reperfusion with primary percutaneous coronary intervention is associated with improved outcomes. The Society for Cardiovascular Angiography & Interventions puts forth this expert consensus document regarding best practices for cardiac catheterization laboratory team readiness, arterial access with an algorithm to help determine proper arterial access in STEMI, and diagnostic angiography. This consensus statement highlights the strengths and limitations of various diagnostic and therapeutic interventions to access and treat a patient with STEMI in the catheterization laboratory, reviews different options to manage large thrombus burden during STEMI, and reviews the management of STEMI across the spectrum of various anatomical and clinical circumstances.

## Table of Contents

<b>Introduction</b> . . . . .	2	Cardiogenic shock . . . . .	9
<b>Methods</b> . . . . .	2	STEMI treated with fibrinolytic therapy . . . . .	9
<b>CCL equipment</b> . . . . .	2	Stent thrombosis . . . . .	9
<b>CCL team readiness and initial assessment</b> . . . . .	2	Multivessel coronary artery disease . . . . .	10
<b>Optimal techniques for angiography and intervention</b> . . . . .	4	Coronary artery bypass graft . . . . .	10
Arterial access . . . . .	4	<b>Anatomical subsets</b> . . . . .	10
Diagnostic assessment . . . . .	5	Coronary calcification . . . . .	10
Initial approach to PCI . . . . .	5	Bifurcation lesions . . . . .	10
<b>Managing thrombus</b> . . . . .	5	Coronary aneurysms/ectasia . . . . .	11
Managing no-reflow . . . . .	6	<b>Nonatherosclerotic causes of STEMI</b> . . . . .	11
<b>Intracoronary imaging</b> . . . . .	7	Epicardial vasospasm . . . . .	11
<b>Emerging approaches to reduce infarct size</b> . . . . .	8	Spontaneous coronary artery dissection . . . . .	11
<b>Special circumstances</b> . . . . .	9	Coronary embolism . . . . .	11
		Myocardial infarction without obstructive coronary arteries . . . . .	12
		<b>Quality of care and outcomes</b> . . . . .	12

**Abbreviations:** CCL, cardiac catheterization laboratory; ECG, electrocardiogram; IVUS, intravascular ultrasound; LVEDP, left ventricular end-diastolic pressure; MCS, mechanical circulatory support; MINOCA, myocardial infarction with nonobstructive coronary artery; MVO, microvascular obstruction; OCT, optical coherence tomography; PCI, percutaneous coronary intervention; STEMI, ST-elevation myocardial infarction.

**Keywords:** intravascular imaging; mechanical circulatory support; microvascular obstruction; no reflow; PCI; STEMI.

\* Corresponding author: [tamisj@ccf.org](mailto:tamisj@ccf.org) (J.E. Tamis-Holland).

<https://doi.org/10.1016/j.jsc.2024.102294>

Available online 7 October 2024

2772-9303/© 2024 The Author(s). Published by Elsevier Inc. on behalf of the Society for Cardiovascular Angiography and Interventions Foundation. This is an open access article under the CC BY-NC-ND license (<http://creativecommons.org/licenses/by-nc-nd/4.0/>).

<b>Future directions</b> .....	12
<b>Conclusions</b> .....	12
<b>Acknowledgments</b> .....	13
<b>Declaration of competing interest</b> .....	13
<b>Funding sources</b> .....	13
<b>Supplementary material</b> .....	13
<b>References</b> .....	13

## Introduction

ST-elevation myocardial infarction (STEMI) is a cardiac emergency that requires rapid diagnosis and timely treatment, with primary percutaneous coronary intervention (PCI), recognized as the preferred mode of reperfusion.<sup>1</sup> Over the past 3 decades, there have been considerable advancements in the treatment of patients with STEMI, beginning with fibrinolytic therapy, the implementation of primary PCI, and subsequent focus on improving reperfusion times through the coordination of systems of care.<sup>2</sup> The American College of Cardiology (ACC) and American Heart Association (AHA) have published clinical practice guidelines that address the management of STEMI.<sup>1,3,4</sup> Although these guidelines provide a robust and well-established clinical framework to manage patients with STEMI that is largely informed by randomized clinical trials and meta-analyses, they are not designed to address the procedural and technical aspects of the management of STEMI, nor the implementation of newer approaches. Likewise, the evidence-base informing the guidelines is primarily derived from patients with suspected atherosclerotic plaque disruption (type 1 MI) and therefore is often unable to guide clinicians on specific circumstances such as the management of patients with nonatherosclerotic etiologies of STEMI. The purpose of this consensus statement is to provide a summary of best practices for managing patients with STEMI, focusing on the management of the cardiac catheterization laboratory (CCL) and technical aspects of the procedure, and to address special circumstances, anatomical subsets, and nonatherosclerotic causes of STEMI. This document is not intended to replace or duplicate current ACC/AHA guideline recommendations for managing patients with STEMI; however, some aspects of care critical to managing these patients may be discussed that reiterate current guidelines. In such instances, a reference to the guideline recommendations is provided. A more detailed discussion of medical therapies and other considerations for managing STEMI outside of the CCL can be found in the clinical practice guidelines.<sup>1,3</sup>

## Methods

This statement has been developed according to the Society for Cardiovascular Angiography & Interventions (SCAI) Publications Committee policies for writing group composition, disclosure, and management of relationships with industry, internal and external review, and organizational approval.<sup>5</sup>

The writing group was organized to ensure a diversity of perspectives and demographic characteristics and an appropriate balance of relationships with the industry. Relevant author disclosures are included in [Supplemental Table S1](#). Before the appointment, members of the writing group were asked to disclose financial and intellectual relationships from the 12 months prior to their nomination. A majority of the writing group disclosed no relevant, significant financial relationships. The work of the writing committee was supported exclusively by SCAI, a nonprofit medical specialty society, without commercial support. Writing group members contributed to this effort on a volunteer basis and did not receive payment from SCAI.

Literature searches were performed by group members designated to lead each section, and initial section drafts were authored primarily

by the section leads in collaboration with other members of the writing group. Consensus statements on the various aspects of CCL management were discussed and agreed upon by the full writing group using a modified Delphi process, which required 75% agreement among authors for a consensus. The draft manuscript was peer-reviewed via a public comment period in May and June 2024, and the document was revised to address pertinent comments. The writing group unanimously approved the final version of the document. The SCAI Publications Committee and Executive Committee endorsed the document as official society guidance in August 2024.

The SCAI statements are primarily intended to help clinicians make decisions about treatment alternatives. Clinicians also must consider the clinical presentation, setting, and preferences of individual patients to make judgments about the optimal approach.

## CCL equipment

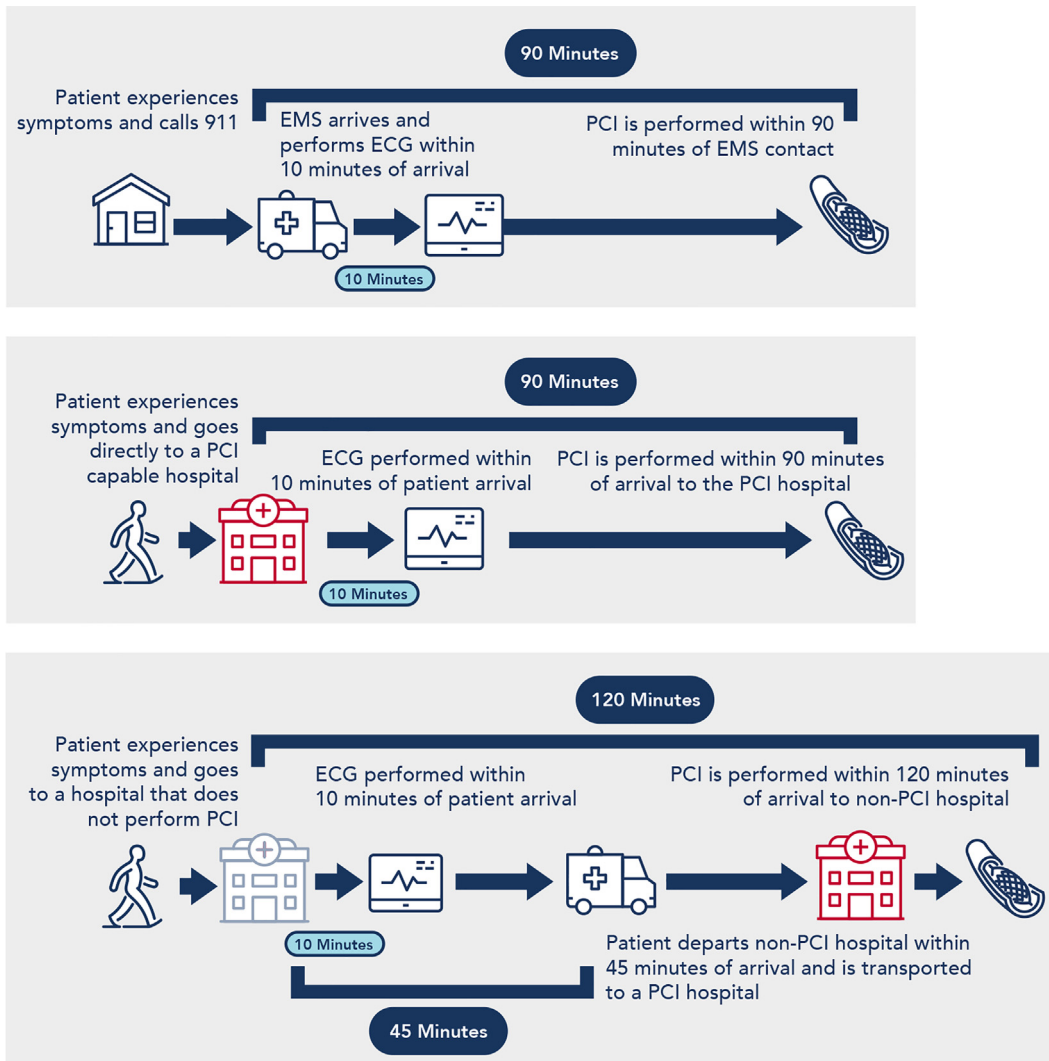
Hospitals offering primary PCI should ensure that the CCL is equipped with the necessary tools required to complete angiographic and intravascular imaging assessment and facilitate PCI. Prior statements have outlined the minimal procedural requirements and qualifications of CCL staff to perform PCI,<sup>6</sup> but do not focus on the necessary equipment to care for patients with STEMI. Although there may be some differences in operator preferences, there are key categories of devices (beyond the standard PCI equipment) that should be available for any CCL offering primary PCI ([Table 1](#)).

## CCL team readiness and initial assessment

ST-elevation myocardial infarction systems of care must accomplish rapid transition of acutely ill patients from the field to the CCL.<sup>7</sup> Prompt treatment is associated with improved clinical outcomes<sup>8</sup> and time represents an overall priority to streamline care at every level of the STEMI system ([Figure 1](#)). Hospitals should develop and maintain protocols and quality-improvement assessments to achieve these goals, as

**Table 1.** Essential equipment for the cardiac catheterization laboratory treating patients with ST-elevation myocardial infarction using primary percutaneous coronary intervention.

Standard equipment	Comments
Plaque modification tools: At least 1 of the following: <ul style="list-style-type: none"> <li>• Cutting or scoring balloon</li> <li>• Intracoronary lithotripsy</li> <li>• Rotational atherectomy</li> <li>• Orbital atherectomy</li> </ul>	To facilitate stent delivery and expansion in severely calcified lesions
Microcatheters	For delivery of medications to the distal vessel and to help exchange wires in tortuous arteries
Guide extension devices	For delivery of balloons and stents in tortuous arteries
Aspiration catheters: At least 1 of the following: <ul style="list-style-type: none"> <li>• Manual aspiration catheter</li> <li>• Mechanical aspiration catheter</li> </ul>	For cases of large thrombus burden or emboli
Intracoronary imaging: At least 1 of the following: <ul style="list-style-type: none"> <li>• Intravascular ultrasound</li> <li>• Optical coherence tomography</li> </ul>	To assess lesion morphology and guide percutaneous coronary intervention
Mechanical circulatory support: At least 1 of the following: <ul style="list-style-type: none"> <li>• Intraaortic balloon pump</li> <li>• Microaxial flow pump</li> <li>• Extracorporeal membrane oxygenation</li> </ul>	For cases of refractory shock
Transvenous pacer	For unstable patients with complete heart block



**Figure 1.** Reperfusion timeline in primary PCI for ST-elevation myocardial infarction. The various modes of presentation and the time-to-treatment goals. ECG, electrocardiogram; EMS, emergency medical services; PCI, percutaneous coronary intervention.

STEMI teams are often activated outside of usual working hours (Table 2). Prehospital activation of the STEMI team by the emergency medical services (EMS) or the emergency department (ED) allows team members time to prepare the CCL during working hours, and time to travel to the hospital after working hours. This has been associated with improved time-to-treatment and outcomes.<sup>9</sup> A single page and/or telephone call activation to a list of STEMI team members is efficient as a mechanism to alert the proper parties, either through the hospital operator or via an electronic application-based system.<sup>10,11</sup> For transferred patients, location and estimated time of arrival are valuable information to include in the communication. Transmission of the 12-lead electrocardiogram (ECG) is helpful to allow the team an opportunity to

review the findings, concur with the diagnosis, and anticipate potential diagnostic or therapeutic interventions.<sup>12</sup> ECG transmission may also alert the team about cases with equivocal ECG findings or uncertain clinical presentations that may require clinical evaluation prior to CCL transfer. Although ECG transmission to the CCL team members is valuable, transmission should not delay the patient's transportation. CCL team members should be expected to arrive at the CCL within 30 minutes and ideally 20 minutes after notification.

Once a STEMI is confirmed on the initial ECG and there are no circumstances precluding emergent revascularization, the patient should be directly transported to the CCL. When feasible, patients presenting to a PCI-capable hospital via EMS should go directly to the CCL, bypassing the ED. This process known as "ED bypass" has been associated with shorter times to treatment and better outcomes.<sup>13</sup> The definition of ED bypass varies across centers. In some institutions, the ED is literally bypassed, and the patient is brought straight to the CCL from the ambulance. Alternatively, some centers make a brief stop in the ED for registration, identification of a proxy, a brief review of the ECG, and to ensure that the patient has a working IV. In these situations, there is no need to obtain a repeat ECG if the ECG performed by EMS is diagnostic for STEMI. ED bypass is appropriate in cases when the diagnosis is clear, and there is no need to stabilize the patient or perform additional

**Table 2.** Key components to successful CCL team readiness.

- Prehospital activation of CCL for patients presenting via EMS
- Single activation of all CCL team members
- Electrocardiogram transmission to the CCL team
- Emergency department bypass for stable patients presenting via EMS directly to the CCL team
- Expectation for CCL team members' arrival is 20-30 min from the time of page

CCL, cardiac catheterization laboratory; EMS, emergency medical services.

assessment. Patients with cardiac arrest and unknown down time, respiratory failure requiring intubation, or other concomitant conditions often warrant additional evaluation prior to transfer to the CCL and thus would not likely be appropriate for ED bypass. In all cases, transport of the patient to the CCL should occur once laboratory staff are prepared to receive the patient. Some hospitals designate an ED or critical care nurse to report to the CCL to receive the patient and prepare the laboratory while waiting for team members to arrive. This can help to expedite treatment during off hours.

Some patients with acute coronary occlusion do not always manifest ST elevation on ECG (eg, acute left circumflex occlusion) or may have subtle ST elevation not meeting the defined diagnostic criteria for STEMI. When there is a high index of suspicion, the acquisition of additional ECG including leads V7-V9, or the use of bedside point-of-care ultrasound (POCUS) can be helpful. In the appropriate clinical setting, patients with features of an acute coronary occlusion but not meeting the ECG criteria for STEMI may require the same management pathway as patients with definite STEMI.<sup>14</sup>

Although the time to reperfusion is essential, this should not preclude a careful evaluation including a focused history and physical exam, as some concomitant conditions or situations may warrant specific precautions (eg, severe peripheral vascular disease, prior coronary artery bypass graft surgery, use of oral anticoagulants, acute or chronic kidney disease, severe aortic stenosis, pregnancy) or influence the decision to proceed with an invasive approach (eg, stroke or altered mental status, severe anemia, low life expectancy, code status and advanced directives) or prompt additional interventions to stabilize the patient before proceeding with PCI (eg, respiratory failure requiring airway protection and/or intubation, unstable arrhythmias requiring treatment, cardiogenic shock [CS]). Caution is warranted in late presenters (>12 hours) who are at risk for mechanical complications, or in cases of CS, in which case, prompt POCUS can facilitate evaluation. Importantly, in cases of futility (eg, advanced dementia and/or advanced directives against resuscitation), discussion with the patient and/or family members is critical to ensure patient goals of care are respected prior to the procedure.

A detailed evaluation is also important in cases with equivocal clinical presentation or uncertain ECG findings which can lead to false STEMI activations due to interpretation errors, technical issues, or STEMI mimics (eg, pericarditis or myocarditis, early repolarization, Brugada syndrome, altered electrolytes, ventricular aneurysms). This can result in potentially unnecessary invasive procedures and

complications, as well as delays in the treatment of other conditions requiring timely management.<sup>15</sup> A high rate of false activations can also have downstream consequences with respect to the availability of STEMI staff for other simultaneous activations, and resource utilization including risk of staff fatigue and burnout, financial costs, and time management. False activation rates can be reduced with educational efforts and training on ECG interpretation. In unclear clinical scenarios, POCUS may enhance clinical decision-making.

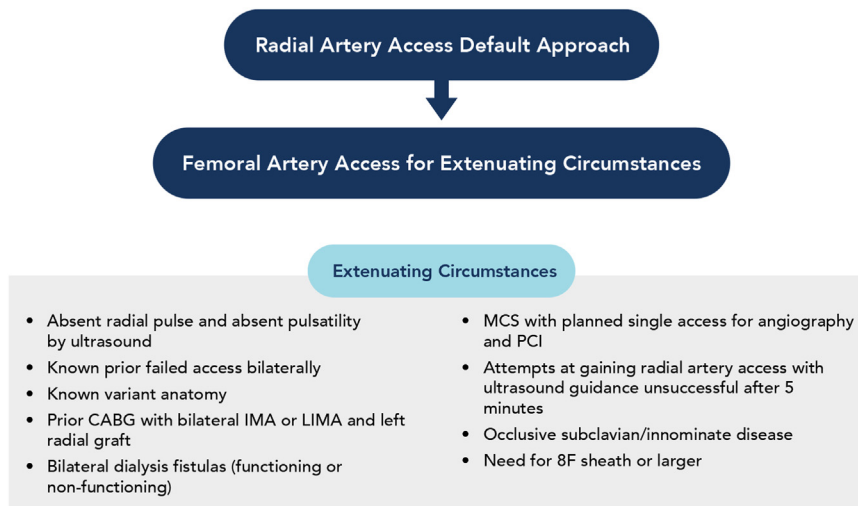
#### Consensus Key Points Regarding CCL Team Readiness

- Prehospital notification and ECG transmission streamline care.
- When feasible, an ED bypass should be implemented.
- A focused history and physical exam should be performed by a member of the cardiovascular team.

### Optimal techniques for angiography and intervention

#### Arterial access

Transradial access is endorsed by the ACC/AHA/SCAI Guidelines on Coronary Revascularization as a class I recommendation in preference to femoral access to reduce the risk of access-site bleeding, vascular complications, and death.<sup>1</sup> Radial access is an important bleeding avoidance strategy for high-risk patients such as those who have received fibrinolytic therapy, glycoprotein IIb/IIIa receptor inhibitors (GPI), or are on oral anticoagulants.<sup>16</sup> Radial access should be the preferred approach in STEMI (Figure 2). When performing radial artery access, careful attention to procedural technique is needed to allow for timely access, reduce complications, and maintain artery patency for future access<sup>17</sup> (Table 3). Femoral access represents an alternative access route reserved for patients in whom the radial artery cannot be used due to technical, clinical, or anatomical reasons, or cases in which a femoral approach may be preferred such as in patients with CS who require large-bore access for mechanical circulatory support (MCS) or those with prior coronary artery bypass graft surgery in whom a left radial approach may not be facile in the acute setting. Optimal access technique in the common femoral artery is associated with a lower risk of bleeding,<sup>18,19</sup> and requires certain key steps (Table 3). Irrespective of the access route, ultrasound guidance is a key, beneficial component of



**Figure 2.**

**An algorithm for determining the proper arterial access in ST-elevation myocardial infarction.** The considerations to be taken when determining arterial access in ST-elevation myocardial infarction. CABG, coronary artery bypass graft surgery; ESRD, end-stage renal disease; IMA, internal mammary artery graft; LIMA, left internal mammary artery graft; MCS, mechanical circulatory support; PCI, percutaneous coronary intervention.

**Table 3.** Best practices for arterial access in ST-elevation myocardial infarction.

Radial artery access	Femoral artery access
<ul style="list-style-type: none"> <li>• Preprocedure assessment to consider right vs left radial access</li> <li>• Ultrasound guidance</li> <li>• Radial artery puncture 1-2 cm proximal to the styloid process</li> <li>• Use of hydrophilic sheath and arterial vasodilators to avoid spasm</li> <li>• Limited angiography of the artery when there is resistance with wire advancement after sheath placement</li> <li>• Patent hemostasis for sheath removal</li> </ul>	<ul style="list-style-type: none"> <li>• Fluoroscopic guidance to identify the lower half of the femoral head</li> <li>• Ultrasound guidance</li> <li>• Micropuncture needle</li> <li>• Fluoroscopic guidance when advancing wire</li> <li>• Femoral angiography to confirm the proper location</li> <li>• Vascular closure devices (especially with large-bore access)</li> </ul>

contemporary vascular access techniques to reduce the number of attempts and time to access. Its use in both radial and femoral access is supported by randomized trials and several meta-analyses.<sup>20,21</sup>

#### Consensus Key Points Regarding Arterial Access

- Transradial access is the preferred route for coronary angiography and PCI.
- When femoral access is necessary, the use of contemporary techniques including routine ultrasound and fluoroscopy is advised.

#### Diagnostic assessment

Interventional cardiologists often have different styles for performing diagnostic angiography and PCI. Complete angiography of both the left and right coronary systems, as well as bypass grafts (if present), should be routinely performed. The timing of complete angiography (ie, before or after PCI) will depend on the clinical circumstances and operator preference. Performing complete diagnostic angiography prior to PCI helps identify the culprit lesion in cases in which the infarct vessel is uncertain, determines the extent and severity of noninfarct artery disease, allows for assessment of collateral blood flow, and may help inform guide selection. Alternatively, if the infarct artery can be predicted based on ECG findings, an upfront guide catheter to assess the coronary circulation and facilitate PCI, with subsequent completion of diagnostic angiography of the remaining vessels can reduce treatment delays.<sup>22</sup> In most cases, the added knowledge of the noninfarct anatomy is unlikely to alter the mode of revascularization. One caveat to this approach is that in RCA-territory STEMI, initial angiography of the left system may identify critical left main or multivessel coronary artery disease (CAD) that can influence the approach to PCI of the infarct artery. In patients with hemodynamic or electrical instability, or with CS, a full angiogram before proceeding with PCI may be prudent irrespective of the infarct artery location, although this will invariably result in a several-minute delay to PCI. When complete angiography is performed prior to PCI, it is important to limit the amount of contrast used and minimize views to the fewest number of cine-angiograms necessary to obtain a full diagnostic assessment.

Measurement of left ventricular end-diastolic pressure (LVEDP) can serve as a useful guide to intraprocedural and postprocedural volume management, as well as provide objective information to help with decisions surrounding the need for diuresis, afterload reduction, or MCS. An elevated LVEDP is associated with higher short and long-term mortality and the development of congestive heart failure.<sup>23</sup> Instrumentation of the left ventricle (LV) should be avoided in late presenters who are at risk for LV thrombus unless POCUS has confirmed the absence of thrombus. The value of LV angiography in contemporary

practice is limited, particularly with the wider availability of POCUS. It can be useful, however, in cases of CS if a mechanical complication is suspected, or when there are ambiguous clinical circumstances where the infarct artery is uncertain. An LV angiogram can also help establish a diagnosis in patients with nonobstructive or normal coronaries including stress cardiomyopathy and those with myocardial infarction with nonobstructive coronary artery (MINOCA) disease.

#### Consensus Key Points Regarding Diagnostic Angiography

- A complete diagnostic coronary angiogram should be performed during the index procedure.
- Measurement of LVEDP can help guide further treatment.

#### Initial approach to PCI

Current guidelines recommend treatment with a loading dose of aspirin and a P2Y12 inhibitor<sup>1</sup> for patients undergoing PCI. Although a comprehensive discussion surrounding the choice and timing of antiplatelet therapy is beyond the scope of this document, it is critical to remember the importance of potent and timely antiplatelet therapy in STEMI patients. The first step in PCI invariably begins with attempts to reestablish flow. After initial wiring, a deflated compliant balloon may be passed back and forth across the lesion to reestablish flow. This is referred to as "balloon dottering" and is beneficial as it may allow for visualization of the distal vessel to confirm the distal wire position prior to balloon dilatation. If the artery remains totally occluded, low-pressure balloon inflation with an under sized balloon can also restore flow and identify the distal landing zone. Following initial angioplasty, repeat angiography and reclassification of Thrombolysis in Myocardial Infarction (TIMI) flow and thrombus burden can then guide the next steps. If the TIMI flow is  $\geq 2$  and there is an absence of a large residual thrombus with adequate visualization of the distal vessel, then PCI can follow. Direct stenting without initial balloon angioplasty is a reasonable strategy but should ideally be guided by intracoronary imaging prior to stenting. In the absence of significant calcification, a strategy of direct stenting is associated with a lower corrected TIMI frame count, and a greater degree of ST-segment resolution, in addition to shorter procedure time, reduced contrast utilization, and improved medium-term outcomes.<sup>24,25</sup> If direct stenting is employed a prolonged (60-90 seconds) stent balloon inflation at high pressures (while also ensuring appropriate sizing to the vessel wall based on the manufacturer's suggestions for stent balloon compliance) will optimize stent expansion while avoiding repeated dilations that can result in distal embolization. This may help prevent no-reflow and stent underexpansion. An important exception to direct stenting is when significant calcium or evidence for a fibrotic lesion is identified either fluoroscopically or via intracoronary imaging or when there is tortuosity in the vessel requiring lesion modification prior to stenting. If after initial wiring and passing of a deflated balloon, there is TIMI  $\leq 1$  flow or there is a large thrombus burden, additional thrombus management is needed prior to stenting.

#### Managing thrombus

Intracoronary thrombus can lead to distal embolization with resultant microvascular obstruction (MVO), impaired tissue perfusion (no-reflow), and occasional terminal vessel truncation. Intracoronary thrombus may also result in side-branch compromise during PCI and has been associated with late stent malapposition.<sup>26</sup> The most widely accepted and thorough classification of intracoronary thrombus is the TIMI thrombus grade (Supplemental Table S2).<sup>27</sup> Practically, thrombus can be classified as either large thrombus (grade 4-5) or small/no thrombus burden (grade 0-3), as this more specifically informs

subsequent steps in PCI. Given that an initial TIMI thrombus grade 5, defined as a complete vessel occlusion, may rapidly improve to grade 0 or grade 1 once the guide wire has crossed the lesion (or with “balloon dottering”), the determination of thrombus grade that will dictate management should not be made until after guide wire placement.

Available options to manage thrombus can be categorized as those that exclude, extract, or dissolve intracoronary thrombus. Thrombus extraction with manual and mechanical aspiration thrombectomy are the most employed treatment strategies for large thrombus burden. Initial trials of manual aspiration thrombectomy demonstrated improved TIMI flow, myocardial blush grade, and clinical outcomes with thrombus aspiration<sup>28,29</sup>; however, the larger thrombus aspiration during ST Segment Elevation Myocardial infarction trial<sup>30</sup> and the Trial of Primary PCI with or without Routine Manual Thrombectomy,<sup>31</sup> which collectively enrolled over 18,000 patients, failed to show a reduction in all-cause mortality or cardiovascular events with thrombus aspiration. Additionally, the Trial of Primary PCI with or without Routine Manual Thrombectomy reported higher rates of stroke with thrombus aspiration. An individual patient-level meta-analysis confirmed these findings with no difference in cardiovascular death but a trend toward a higher rate of stroke.<sup>32</sup> In this report, a subgroup analysis of end points demonstrated a consistent “lack of benefit” with thrombus aspiration irrespective of thrombus size. Notably, there was a higher stroke risk with thrombus aspiration only in the patients with a large thrombus burden. Current guidelines recommend against the routine use of thrombus aspiration in STEMI.<sup>1</sup> This recommendation does not apply to patients with more extensive thrombus burden in whom there may be concern for distal embolization, or when balloon angioplasty is unsuccessful, in which case bail-out thrombus aspiration may be needed. Mechanical aspiration devices provide continuous aspiration of thrombus and are an alternative to manual devices. Although a prospective registry of patients with large thrombus burden managed with mechanical aspiration demonstrated excellent TIMI 3 flow on final angiogram and stroke rates comparable to the control arm of other studies,<sup>33</sup> randomized data are not available; therefore a direct comparison of the various aspiration devices cannot be made.

Regardless of the device used, optimal aspiration thrombectomy technique is imperative and includes avoidance of thrombectomy in severely tortuous arteries, active thrombectomy with initial antegrade advancement, deep seating of the guiding catheter upon withdrawal of the device to minimize the chance of dislodgement of thrombus down a side branch or into the aorta, continuous active aspiration until just before the catheter enters the hemostatic valve at the hub of the guiding catheter (so as not to entrain air), and “back bleeding” of the hemostatic valve followed by rigorous flushing to ensure any residual thrombus remaining in the catheter has been removed.

For cases with large residual thrombus that persist despite usual measures including thrombectomy, the approach to treatment is more nuanced. The use of either IV or intracoronary GPI and the use of intracoronary fibrinolytic agents can be considered as adjunctive therapy. In theory, the antiplatelet effects of a GPI may be potentiated by local drug delivery via the intracoronary route resulting in relatively higher concentrations of drug at the site of an occlusive thrombus; however, trials examining intracoronary GPI vs IV GPI during PCI for STEMI have reported conflicting results,<sup>34–37</sup> and a meta-analysis reporting on 14 trials (3754 patients) of intracoronary vs IV GPI showed no difference in long-term major adverse cardiovascular events (MACE).<sup>38</sup> In this study, the use of intracoronary GPI, was associated with improved markers of reperfusion including ST-segment resolution, myocardial blush grade, and infarct size, as well as reduced short-term MACE. Intracoronary fibrinolytic studies have been limited to case reports or series, or smaller trials performed in the lytic era, with the absence of contemporary data from randomized trials,<sup>39</sup> and are rarely used in current times. Intracoronary agents are generally reserved for

situations when there is a significantly large thrombus or no-reflow despite usual aspiration techniques. When used, it is important that the drug be delivered directly to the distal artery using microcatheters.

The excimer laser has been described for use in restenotic lesions, calcified lesions, and lesions with thrombus, but its use fell out of favor until recent times due to higher-than-normal rates of complications.<sup>40</sup> More recently, the use of excimer laser coronary angioplasty to “vaporize” large thrombi has also been explored. Several small studies demonstrated improved myocardial blush grade and less slow/no-reflow in cases of large thrombus burden, particularly in patients with longer symptom onset-to-balloon times.<sup>41,42</sup> Given the potential for coronary rupture with laser in de novo lesions as well as the added time and cost considerations, the laser is generally reserved for cases of refractory thrombus, particularly in saphenous venous grafts, or in patients with COVID-19 complicated STEMI.

In some cases, when the flow has been reestablished but there is a residual large thrombus burden that persists despite the techniques described above, deferral of stenting while treating patients with prolonged IV antiplatelet and antithrombotic therapy is an alternative strategy to reduce no-reflow risk and infarct size, with planned repeat coronary angiogram and stenting to follow in the ensuing days. A small, randomized trial demonstrated improved coronary blood flow with this technique,<sup>43</sup> but a larger clinical trial and meta-analysis did not report a reduction in clinical events with deferred stenting.<sup>44,45</sup> Available treatment options and a decision-making pathway are summarized in Figure 3.

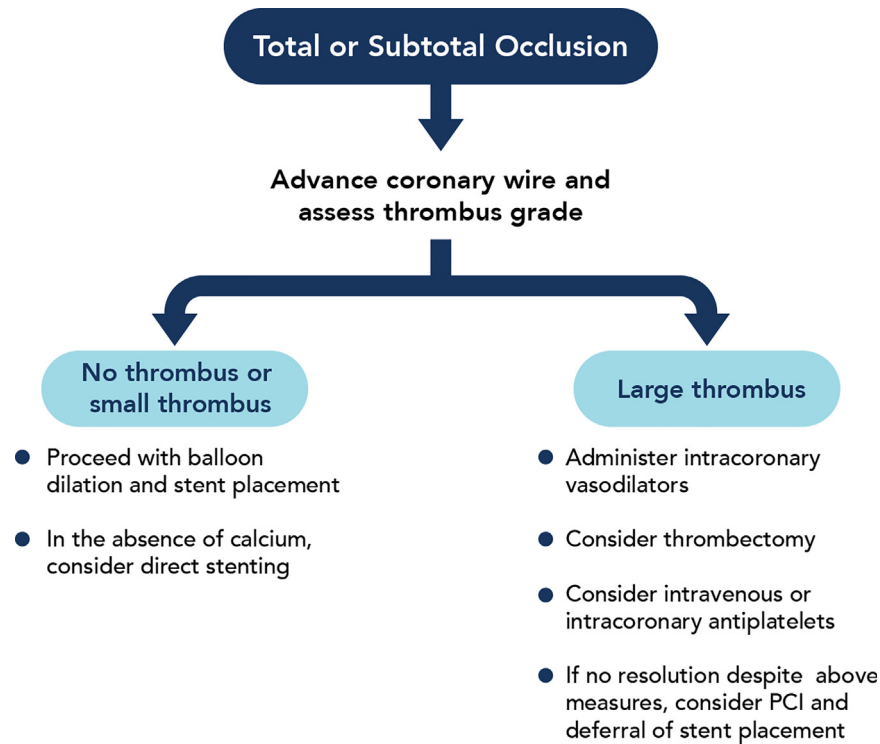
#### Consensus Key Points on Managing Thrombus

- Angiographic assessment of thrombus burden should be made after the wire crosses the lesion.
- Bail-out aspiration thrombectomy in selected cases of large thrombus is an acceptable treatment strategy.
- Parenteral (or intracoronary) antiplatelet agents can be used for refractory thrombus.

#### Managing no-reflow

Coronary no-reflow during primary PCI, defined as the lack of antegrade coronary flow in the absence of epicardial obstruction, is a frequent challenge that is associated with larger infarct size and increased long-term mortality.<sup>46</sup> The primary basis for no-reflow is MVO. The pathologic mechanism underlying MVO includes individual susceptibility, ischemia/reperfusion injury, endothelial dysfunction, microvascular spasm, interstitial edema, intramyocardial hemorrhage, and distal thromboembolization.<sup>47</sup> Important risk factors include advanced age, male sex, longer ischemic times, hyperglycemia, leukocytosis, elevated creatinine, and elevated cardiac biomarkers at baseline. Angiographic and hemodynamic predictors include initial TIMI flow, high thrombus burden, and higher Killip class.<sup>48</sup>

Prevention and early recognition are the foundations of the management of no-reflow. Systems that promote early presentation after symptom onset and shorter ischemic times would likely have a favorable effect on the incidence of no-reflow. Acute glycemic control and preprocedural statin use have been shown to decrease the incidence of no-reflow, presumably by mitigating endothelial dysfunction and ischemia/reperfusion injury,<sup>49</sup> although preprocedural glycemic control may not be feasible in cases of primary PCI. From a technical standpoint, the best treatment of no-reflow is also prevention. Thus, careful assessment for thrombus after initial wiring, and maneuvers to treat thrombus, (see Managing Thrombus section) are associated with greater myocardial blush and ST-segment resolution, which are clinical markers of tissue-level reperfusion.<sup>28,37,43</sup> When poor distal flow is noted, it is important to exclude coronary artery dissection which can



**Figure 3.** Managing intracoronary thrombus. The step-by-step approach to managing intracoronary thrombus. PCI, percutaneous coronary intervention.

mimic no-reflow. A small injection of 1 to 2 mL of contrast through a microcatheter advanced to the distal coronary artery can facilitate visualization of the distal vessel and confirm the intraluminal location of the wire. Despite the potential advantages of confirming wire location, this technique runs the risk of distal perforation in small vessels and should be used with caution.

Coronary perfusion pressure is an often unappreciated, yet critically important variable contributing to no-reflow. Augmentation of cardiac output and active reduction of LVEDP, with afterload reduction, diuresis, and at times with the use of MCS, can aid in the prevention of no-reflow, particularly in larger anterior infarcts.<sup>50,51</sup> Maximization of distal capacitance with the prophylactic use of intracoronary vasodilators, including adenosine, nitroprusside, and calcium channel blockers, prior to stenting is another important strategy. When used for prophylaxis, these medications should be given before and after each coronary manipulation (ie, thrombectomy, angioplasty, and/or stenting), and may be given via the guide catheter, a microcatheter, or aspiration catheter.

Once no-reflow is noted, the goal of therapy should focus on reversing vasoconstriction and treatment of microvascular thrombosis. Therefore, delivery of medications to the distal coronary bed is necessary. In addition to their prophylactic role, intracoronary vasodilators remain the mainstay of treatment once no-reflow occurs, although evidence is limited. The most employed agents include adenosine, nitroprusside, calcium channel blocking agents, and diluted epinephrine (Table 4). Most of these agents have been used anecdotally with limited and conflicting data. They have been associated with improved TIMI flow and a greater degree of ST-segment resolution, but they have not been shown to improve myocardial infarct size, LV ejection fraction or reduce the rates of MACE in long-term follow-up.<sup>52-55</sup> More recently, the use of diluted IC epinephrine has been explored as an alternative to other vasodilating agents, demonstrating improvement in TIMI flow in cases of refractory no-reflow resistant to other intracoronary vasodilators<sup>56</sup> or when used as an alternative to other agents.<sup>57</sup> Factors to consider before choosing a vasodilating agent include LV function, LVEDP, mean arterial blood pressure, the presence of conduction delays

or significant bradyarrhythmias, and the presence of significant aortic stenosis, or obstructive hypertrophic cardiomyopathy.

**Consensus Key Points for Management of No-Reflow**

- Use intracoronary arteriolar vasodilators delivered to the distal bed
- Maximize coronary perfusion pressure with augmentation of mean arterial pressure and reduction of LVEDP

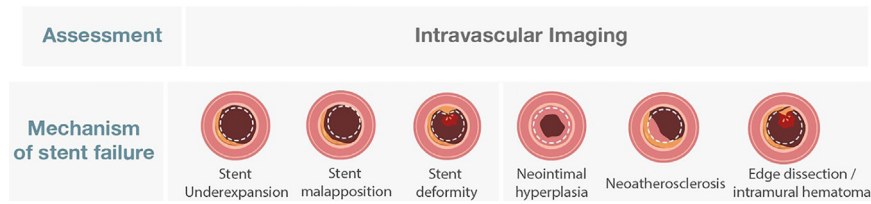
**Intracoronary imaging**

Intracoronary imaging with intravascular ultrasound (IVUS) or optical coherence tomography (OCT) is recommended as a reasonable option to guide PCI and in patients with stent thrombosis or in-stent restenosis to assess the mechanism of stent failure.<sup>1,58</sup> Observational studies, randomized trials, and meta-analyses have demonstrated a reduction in MACE, stent thrombosis, cardiac death, and all-cause mortality in longer-term follow-up with the use of intracoronary imaging.<sup>59-62</sup> Although robust data support the use of intracoronary imaging, few patients in these studies were undergoing PCI for STEMI. Registry data comparing intracoronary imaging with angiography-guided PCI in

**Table 4.** Suggested dosing for intracoronary administration of drugs used for no-reflow.

Agent	Dose	Comments
Adenosine	50-200 µg	Avoid in heart block
Nitroprusside	50-200 µg	Avoid in severe aortic stenosis or hypertrophic cardiomyopathy
Diltiazem	400 µg	Avoid in cardiogenic shock or heart block
Verapamil	100-250 µg	Avoid in cardiogenic shock or heart block
Nicardipine	50-200 µg	Avoid in severe aortic stenosis
Epinephrine	50-200 µg	Avoid in ventricular arrhythmias

## STENT THROMBOSIS



**Figure 4.**

**Mechanisms of stent thrombosis.** The potential mechanisms of stent thrombosis. These are often assessed using intracoronary imaging. Adapted from Klein et al.<sup>66</sup>

patients with acute myocardial infarction (AMI), including approximately 50% with STEMI, have demonstrated lower MACE and lower adjusted mortality with intracoronary imaging.<sup>63,64</sup> Future randomized control trials examining the benefits of IVUS (NCT04775914) and OCT<sup>65</sup> in STEMI will provide important insights for STEMI patients.

Intracoronary imaging plays a key role in assessing lesion morphology, the extent of plaque, and vessel size. It can help to investigate the underlying cause of stent thrombosis and can also be useful to investigate plaque disruption or intramural hematoma in cases of nonobstructive disease or ambiguous culprit lesions, (Figure 4).<sup>66</sup> In these situations, OCT may be preferred as it provides greater resolution than IVUS (although it should be used with caution in cases with impaired renal function). When feasible, imaging acquisition should be performed before and after stent placement (Figure 5). Morphology, including the assessment of plaque burden, areas of positive remodeling, thrombotic burden, and the extent of calcium may influence the approach to PCI. Distal and proximal reference vessel cross-sectional diameters and lesion length are important variables necessary for optimal stent sizing. After the intervention, the focus of intracoronary imaging is to assess stent expansion, apposition, geographic miss, and edge dissection.

### Consensus Key Points for Intracoronary Imaging

- Routine use of intracoronary imaging is encouraged to guide PCI.
- In case of stent thrombosis or stent failure, intracoronary imaging is an essential step to investigate the mechanism.
- In cases when there is a suspicion of a nonatherosclerotic cause of STEMI, intracoronary imaging can be helpful in assessing ambiguous lesions and delineating the mechanism.

### Emerging approaches to reduce infarct size

Infarct size is associated with an increased risk of MACE including all-cause mortality and heart failure.<sup>67</sup> Infarct size, which is an objective measure of the extent of myocardial damage, is dependent on a variety of factors including the amount of myocardium supplied by the occluded vessel, the total ischemic time, and the presence of reperfusion injury.<sup>68</sup> Infarct size is best measured using cardiac MRI with various end points used in clinical practice and research trials.<sup>69</sup> MVO resulting from distal embolization, microvascular spasm, interstitial edema, and intramyocardial hemorrhage<sup>70</sup> is an important correlate of reperfusion injury and a useful surrogate marker of infarct size. MVO is often assessed by cardiac MRI at a time remote from the acute event and is an independent predictor of outcome after myocardial infarction.<sup>71,72</sup> Newer data have suggested larger infarct size and worse outcomes only in cases of MVO with intramyocardial hemorrhage.<sup>73</sup>

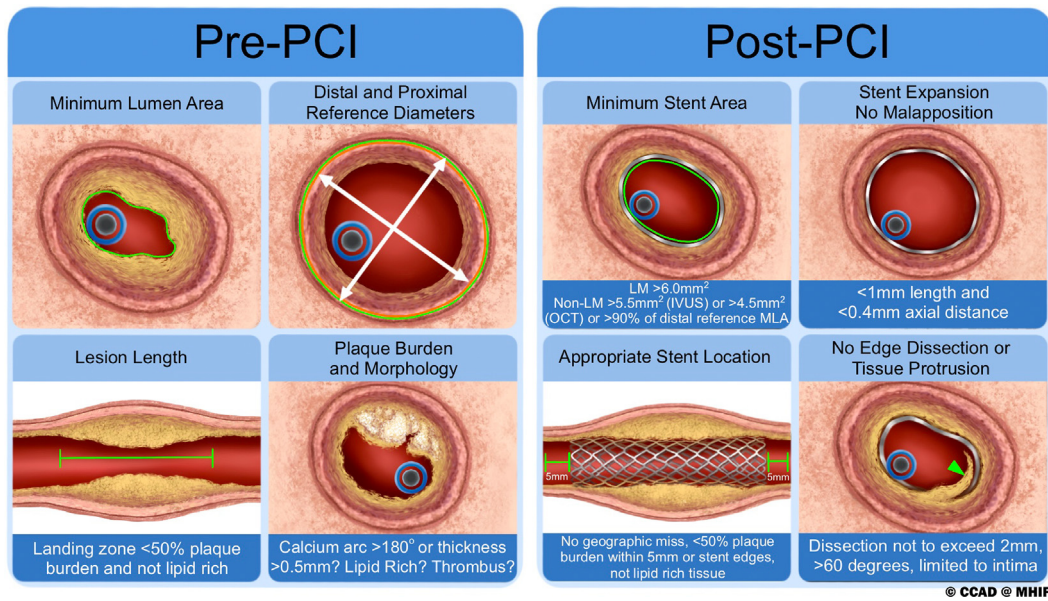
Several studies have explored various methods of reducing reperfusion injury and limiting infarct size,<sup>74–79</sup> but there are limited data to

support any of the approaches as a routine first-line therapy for STEMI. Supersaturated oxygen (SSO<sub>2</sub>) is US Food and Drug Administration (FDA)-approved as a therapy to reduce infarct size in patients with anterior STEMI treated with primary PCI within 6 hours of symptom onset in the absence of shock.<sup>80</sup> The catheter-based system used immediately following PCI allows for blood that is withdrawn from the side arm of a sheath to mix with aqueous oxygen (via an oxygenator) to provide high levels of dissolved oxygen to the “at-risk” myocardium, limiting microvascular and myocardial damage. Studies have shown an average reduction in infarct size of 28% with SSO<sub>2</sub><sup>76,81</sup> and low rates of net adverse clinical events including death, reinfarction, clinically driven target vessel revascularization, stent thrombosis, and severe heart failure compared with the historical control arm taken from a randomized trial evaluating STEMI patients.<sup>82</sup> Furthermore, translational model studies have shown that SSO<sub>2</sub> normalizes endothelial structure and function and increases microvascular flow.<sup>80</sup> Although early iterations used larger femoral sheaths that were associated with more bleeding complications, the latest system allows the use of a smaller 5F contralateral sheath. Following FDA clearance, postmarket observational studies are ongoing addressing real-life experience (REAL SSO<sub>2</sub> NCT05156996) in a larger subset of patients receiving SSO<sub>2</sub>. An individual patient data pooled analysis of 90 patients from the optimized SSO<sub>2</sub> and IC-HOT studies and 784 control patients who underwent primary PCI without SSO<sub>2</sub> from across 7 randomized trials suggests that SSO<sub>2</sub> is associated with a lower extent of MVO compared with patients not receiving SSO<sub>2</sub>.<sup>83</sup>

Mild hypothermia (32.0–35.9 °C) reduces reperfusion injury by blunting inflammation, thrombosis, and myocardial metabolism.<sup>84,85</sup> Randomized control trials with varying protocols for cooling have investigated adjunctive hypothermia as a strategy to decrease infarct size and preserve microvascular integrity.<sup>78,86–90</sup> Although most of the studies demonstrated that cooling was safe, the efficacy end points have been largely negative, although there was some suggestion of benefit in patients with anterior infarct.<sup>87,89</sup> The European Intracoronary Cooling Evaluation in Patients With ST-Elevation Myocardial Infarction trial is an ongoing clinical trial that will randomize 200 patients with an anterior infarct and TIMI 0 or 1 flow in the infarct artery to a strategy of intracoronary cooling during PCI or PCI alone.<sup>91</sup> The primary end point is infarct size as a percentage of LV mass on MRI at 3 months.

Left ventricular unloading is another approach aimed at reducing infarct size. The Door-to-Unload-STEMI Pilot trial randomized 50 patients with anterior STEMI to a protocol of 30 minutes of LV unloading with the Impella CP (Johnson & Johnson) and delayed reperfusion vs immediate primary PCI without unloading.<sup>79</sup> The study was designed as a feasibility trial, with a focus on safety, and demonstrated no differences in MACE or major cerebrovascular events between the groups. The STEMI-Door to Unload trial aims to enroll 668 patients with an anterior infarct and randomize them to a strategy of LV unloading 30 minutes before PCI or immediate PCI without LV unloading and will assess the effects of LV unloading on myocardial infarct size measured with MRI at 3 to 5 days.<sup>92</sup>





**Figure 5.**

**Important parameters assessed by intracoronary imaging.** The important variables that should be determined with intracoronary imaging before percutaneous coronary intervention (PCI) and at the end of PCI. IVUS, intravascular ultrasound; LM, left main; MLA, minimal lumen area; OCT, optical coherence tomography.

### Special circumstances

#### Cardiogenic shock

Patients with CS are at significantly higher risk of mortality, which is reduced by prompt revascularization as demonstrated in the Should We Emergently Revascularization Occluded Coronaries for Arteries for Cardiogenic Shock trial.<sup>93</sup> In patients with CS, the implementation of algorithmic risk stratification and treatment protocols has been associated with improved survival.<sup>94</sup> Designating regional centers by level may be useful to facilitate interhospital transfer or EMS triage for primary PCI in the context of CS.<sup>7</sup> This designation, as outlined by the AHA STEMI Systems of Care Policy Statement<sup>7</sup> provides 3 levels of care for STEMI: Level 1 centers provide a complete range of treatment for STEMI and shock including MCS and surgical support when needed. Level 2 centers provide primary PCI and some level of MCS. Level 3 centers are non-PCI hospitals that can administer fibrinolytic therapy or provide rapid transfer to a PCI hospital for primary PCI. Although these designations facilitate triage to appropriate facilities, such allocation is not always practical in real-world settings and has an unclear impact on outcomes. The management of STEMI complicated by CS requires thoughtful decisions to optimize care and prevent bleeding and vascular events while the patient is in the CCL and subsequently in the critical care units. A detailed discussion surrounding the assessment and management of CS in the CCL is described elsewhere.<sup>95,96</sup> Notable aspects of catheterization lab management in patients with STEMI complicated by CS are summarized below.

Point-of-care ultrasound can aid in determining the etiology of CS, particularly in patients with delayed presentation. The evaluation should focus on an assessment of biventricular systolic function and the presence of significant valvular disease, intracardiac shunts, or pericardial effusion. If done prior to angiography, it is best performed during the time when the CCL is preparing for the patient so that it can provide important information before the start of the procedure while not delaying the time to PCI.

In the absence of a known or suspected LV thrombus, LVEDP should be routinely measured in cases of CS (unless right heart catheterization [RHC] measurements are available at the time of the procedure) as it may help guide management. Additionally, right heart catheterization with measurement of pulmonary capillary wedge pressure, pulmonary artery pressures, cardiac output and index, and calculation of

pulmonary artery pulsatility index and cardiac power index can help guide the need for, and type of, MCS. RHC can influence decisions and is associated with improved outcomes in patients with CS.<sup>97,98</sup>

For patients with SCAI stage C or D shock, an MCS device can help reduce ventricular workload and, in some cases, can allow for ventricular unloading before PCI. The Danish-German Cardiogenic Shock trial<sup>99</sup> randomized 355 patients with STEMI and SCAI stages C through E CS to a strategy of MCS support using the microaxial flow pump or standard care. Approximately 50% of patients received the device before PCI. The primary end point, death from any cause was lower in the group that received a microaxial flow pump as compared with standard care. Notably, there was a significantly higher rate of adverse events, including moderate or severe bleeding, limb ischemia, need for renal replacement therapy, and sepsis in the microaxial flow pump group. These results provide support for using this microaxial flow pump in advanced SCAI stage CS in the studied population. Efforts to minimize bleeding and ischemic complications, such as careful case selection and/or vascular access optimization with ultrasound guidance (Table 3), would likely strengthen this benefit, but awaits further data.

#### STEMI treated with fibrinolytic therapy

If primary PCI cannot be performed within 120 minutes of first medical contact, fibrinolytic therapy is recommended,<sup>3</sup> but this approach carries important limitations including failure of reperfusion or the potential for reocclusion. For this reason, after treatment with fibrinolytic therapy, current guidelines recommend early transfer to a PCI hospital.<sup>1</sup> Patients with CS, decompensated heart failure, and failed reperfusion (defined by a lack of ST resolution >50% and absence of reperfusion arrhythmias) should undergo immediate angiography and revascularization.<sup>1</sup> In the remaining patients, it is reasonable to transfer with the plans for coronary angiography and PCI early after fibrinolysis.<sup>1</sup> In these situations, radial access is valuable to mitigate access site-related bleeding complications.

#### Stent thrombosis

Approximately 1% of patients experience stent thrombosis in the first 2 years after PCI.<sup>100</sup> Most patients with stent thrombosis present

with STEMI. Premature discontinuation of dual antiplatelet therapy and stent-related factors such as stent underexpansion, stent fracture, malapposition or edge dissection, stent gap, residual uncovered plaque, and stent undersizing are the most common factors leading to stent thrombosis (Figure 4). The management of stent thrombosis has been described.<sup>66</sup> Notable aspects of the management of STEMI due to stent thrombosis include the use of intracoronary imaging (OCT or IVUS) to determine the cause of stent thrombosis. In these cases, the higher resolution of OCT may provide better assessments of uncovered struts, malapposition, stent fracture, and neo-atherosclerosis. The approach to intervention will depend on the mechanism of stent thrombosis. If underexpansion or malapposition is noted, then high-pressure balloon inflation with an appropriately sized balloon based on intracoronary imaging may be all that is needed. On the other hand, for stent fractures, edge dissections, or neo-atherosclerosis, a second drug-eluting stent is often warranted. Stent thrombosis frequently presents with a large thrombus burden and thoughtful considerations for treatment are needed (see Managing Thrombus section).

#### Multivessel coronary artery disease

Multivessel coronary artery disease is present in approximately 50% of patients with STEMI and is associated with increased adjusted mortality compared with patients with disease of the infarct artery only.<sup>101</sup> Current guidelines recommend staged PCI of a significantly stenosed noninfarct artery<sup>1</sup>; however, more recent studies have suggested that multivessel PCI at the time of primary PCI reduces the risk of recurrent ischemic events when compared with a staged PCI procedure.<sup>102,103</sup> For this reason, individualized care is needed when determining the indications for and timing of PCI of the noninfarct artery in STEMI. This will depend on multiple factors including clinical and hemodynamic stability, lesion complexity of both the infarct artery and the noninfarct artery, the extent of myocardium at risk, and the presence of other comorbidities.<sup>1</sup> The benefits of noninfarct artery PCI should not be extrapolated to patients with CS in whom multivessel PCI at the time of primary PCI is associated with worse outcomes compared with culprit-only PCI<sup>104</sup> and is not recommended by ACC-AHA guidelines.<sup>1</sup> The functional assessment of the noninfarct artery to guide the decision for PCI is controversial with conflicting results from randomized trials.<sup>105,106</sup> The Physiology-Guided vs Angiography-Guided Non-culprit Lesion Complete Revascularization for Acute MI & Multivessel Disease trial (NCT05701358) which plans to enroll 5100 patients with AMI and multivessel disease will examine the role of physiology-guided PCI of the noninfarct artery in acute infarction.

#### Coronary artery bypass graft

Approximately 4% of patients with STEMI have a history of prior coronary artery bypass surgery.<sup>107</sup> The management of these patients will vary depending on the location of the bypass graft and the native anatomy. In many cases, PCI of the native vessel is not possible due to underlying chronic occlusions, and PCI of the bypass grafts is often necessary. Except for STEMI occurring in the early postoperative period, an anterior wall infarction occurring in a patient with a left internal thoracic artery (LIMA) graft to the left anterior descending artery is generally due to plaque rupture in the native vessel distal to the anastomosis. In such cases, left radial artery access may be preferred. In tortuous LIMA bypass grafts or very distal occlusions, a short guide may be needed to allow adequate length for the delivery of balloons and stents to the distal vessel. Hydrophilic floppy wires are preferred to mitigate the plication of the LIMA. When using the LIMA graft as a conduit to the distal vessel, concomitant flow abnormalities during delivery of balloons and stents may occur warranting the liberal use of arterial vasodilators to manage spasm of the LIMA bypass graft. STEMI

cases resulting from acute occlusion of a saphenous vein graft are commonly complicated by large thrombus, and filter-based devices are often necessary to avoid embolization to the distal vessels. These cases are best treated with direct stenting (when feasible) and postdilation with high-pressure balloons should be avoided unless intravascular imaging demonstrates inadequate stent expansion or apposition. The liberal use of vasodilators is important to prevent no-reflow. Due to the limited engagement of guiding catheters in bypass grafts, a higher threshold for using aspiration thrombectomy devices is warranted so as to avoid the risk of embolism of aspirated thrombus.

#### Consensus Key Points for Special Circumstances

- RHC should be performed in STEMI with CS during the index procedure.
- Microaxial flow pumps can be beneficial in patients with STEMI and CS.
- Immediate catheterization and rescue PCI are essential when fibrinolytic therapy has failed.
- In stable patients, early catheterization within 24 hours of fibrinolytic therapy is indicated.
- Intracoronary imaging should be routinely performed in cases of stent thrombosis to investigate the mechanism.
- Complete revascularization with treatment of significant non-infarct stenosis should be performed in patients with STEMI and MVD.

#### Anatomical subsets

##### Coronary calcification

Moderate and severe calcification of the culprit lesion has been reported in 26% and 6% of STEMI cases, respectively, when reviewed by an angiographic core laboratory.<sup>108</sup> The presence of moderate/severe calcification is associated with suboptimal angiographic results and higher procedural complications, and independently predicts an increased risk of stent thrombosis and ischemic target lesion revascularization at 1 year.<sup>108</sup> A detailed OCT analysis of a cohort of patients with acute coronary syndrome found 3 calcified culprit plaque phenotypes: eruptive calcified nodules, superficial calcific sheet, and calcified protrusion.<sup>109</sup> The management of calcified culprit lesions in STEMI has not been prospectively examined; however, reports of advanced calcium modification modalities in STEMI (including atherectomy, excimer laser, and lithotripsy) suggest these techniques can be useful. Until further evidence is available, as in all cases of calcified lesions, the choice of plaque modification strategies should be individualized based on intracoronary imaging guidance.<sup>110</sup>

##### Bifurcation lesions

Bifurcation lesions are encountered in 10% to 20% of patients with STEMI, which results in longer fluoroscopy times and higher contrast use but have rates of acute procedural success similar to nonbifurcation lesions. There are no prospective studies examining the approach to patients with STEMI involving a bifurcation lesion, and the management of complex bifurcations lesions in a stable patient may not be similarly applicable to a patient with STEMI where propagation of thrombus into the branch vessel can occur. An earlier retrospective study with first-generation drug-eluting stents showed higher rates of cardiovascular events with the use of 2 stents<sup>111</sup>; however, a more recent study addressing patients with anterior STEMI with bifurcation disease of the left anterior descending artery and diagonal artery using current-generation drug-eluting stents showed similar rates of cardiovascular events at 6 months with a single or 2 stent strategy.<sup>112</sup> Although

an individualized approach to management considering the TIMI flow in the side branch, size of the side branch, and degree of thrombus is always important, a provisional 1-stent strategy is a practical initial strategy in most cases of bifurcation disease of the infarct artery.

### Coronary aneurysms/ectasia

A coronary artery aneurysm is a localized vascular dilation  $\geq 1.5$  times the diameter of the normal adjacent reference segment. Coronary aneurysms are found in up to 5% of patients undergoing coronary angiography, usually in association with connective tissue disorders or prior Kawasaki disease.<sup>113</sup> Aneurysms can also result from iatrogenic wall injury after coronary intervention with stenting or brachytherapy.<sup>113</sup> Giant coronary artery aneurysms leading to thrombosis with STEMI can be difficult to treat due to the potential for distal embolization and the limited options for stent sizing. As such, PCI of an aneurysmal segment in the setting of STEMI is problematic, with a higher incidence of no-reflow or distal embolization, and increased rates of adverse cardiovascular events and definite stent thrombosis.<sup>114</sup> The most important goal for managing a STEMI involving a coronary artery aneurysm is to restore flow. This may require advanced techniques to manage thrombus such as mechanical or manual aspiration thrombectomy or the use of IV GPI (see Managing Thrombus section). Once the flow is restored, consideration for percutaneous or surgical treatment will depend on several factors including the size of the aneurysm, side branch involvement, and the extent of residual stenosis within the lesion. In some cases, if balloon angioplasty alone results in restoration of flow and there is a large aneurysm with extensive thrombus, then aggressive antiplatelet and anticoagulant therapies without further stenting may be preferred. If stenting is indicated and the artery is  $< 5$  mm in diameter, a large-sized coronary artery stent may be sufficient; however, when the aneurysm is  $> 5.5$  to 6 mm (depending on available stent brand), peripheral stents are needed.<sup>115</sup> When managing these cases, a 7F guiding catheter can aid in the delivery of these large devices. In the absence of a large side branch, covered stenting and/or stent-assisted coiling has been reported with success,<sup>115,116</sup> although covered stents are not approved by the FDA for treatment of coronary artery aneurysms and thus cannot be endorsed. For larger aneurysms or those with the involvement of a significant side branch, urgent surgery (in the case of ongoing symptoms and slow flow) or delayed surgery should be considered.

#### Consensus Key Points for Managing Anatomical Subsets

- When necessary, plaque modification for calcified lesions can be used to facilitate stent delivery and expansion after restoration of blood flow.
- A provisional (1-stent) strategy in bifurcation lesions is preferred.
- The focus of the management of a coronary artery aneurysm is to restore flow.

### Nonatherosclerotic causes of STEMI

#### Epicardial vasospasm

Abnormal vasoconstriction sometimes precipitated by a pharmacologic substance (eg, cocaine, triptans) and/or emotional stress can lead to transient occlusion of 1 or more epicardial coronary arteries with accompanying ST elevation. Epicardial coronary artery spasm is an uncommon but important nonatherosclerotic mechanism of acute STEMI.<sup>117</sup> The threshold for suspecting coronary artery vasospasm should be especially high in younger patients ( $< 50$  years of age) who do not have cardiac risk factors when diffuse disease is seen on coronary angiography. Irrespective of the suspicion of spasm, unless

hemodynamically contraindicated, intracoronary nitroglycerin is useful in patients with an acute STEMI at the time of coronary angiography. This important measure can help identify and treat patients with coronary artery spasm while also facilitating the accurate assessment of vessel diameter for those patients undergoing PCI due to atherosclerotic plaque. Patients with MINOCA and suspected epicardial coronary artery spasm may be referred for a comprehensive evaluation for coronary microvascular dysfunction and coronary spasm assessment with intracoronary acetylcholine provocation in the elective setting. Patients with epicardial coronary vasospasm are best managed with vasodilators such as nitrates or calcium channel blockers.

#### Spontaneous coronary artery dissection

Spontaneous coronary artery dissection (SCAD) with intimal disruption and intramural hematoma is an increasingly recognized non-atherosclerotic mechanism of STEMI leading to acute coronary occlusion and is often a cause of myocardial infarction in young women. Recognition of SCAD features on coronary angiography is critical, as the management is different than the management of STEMI due to atherosclerosis. One should suspect SCAD when managing STEMI in a young woman, a patient with concurrent systemic arteriopathies, and those with few or no conventional cardiovascular risk factors with angiographic characteristics suggestive of SCAD.<sup>118</sup> Angiographic SCAD classification includes the following: type I: multiple radiolucent lumens or arterial wall contrast staining; type II: diffuse stenosis that can be of varying severity and length; and type III: focal or tubular stenosis that mimics atherosclerosis.<sup>119</sup> Although intracoronary imaging may confirm the diagnosis of SCAD, vessel instrumentation has risks in patients with SCAD where inadvertent wiring of the false lumen can cause complications. Additionally, the use of OCT can propagate the hematoma due to the need for contrast injections.<sup>120</sup> For this reason, intracoronary imaging should be reserved for those patients in whom the diagnosis is uncertain if imaging will impact management. PCI for the treatment of SCAD is associated with an increased risk of complications, including further extension of the dissection due to wire manipulation or propagation of the hematoma.<sup>121</sup> Therefore, conservative therapy is often indicated especially in stable patients, or in those with a limited territory of myocardium at risk due to distal disease. PCI (or coronary bypass surgery) may be necessary in the setting of an acute total occlusion of a vessel with a large area of myocardium at risk and/or in patients with refractory ongoing symptoms or hemodynamic instability. If PCI is indicated, the goal of PCI should be to restore vessel patency with adequate TIMI flow. If this can be achieved without stenting, then a balloon alone is preferred. Various techniques have been described<sup>122</sup> (the use of compliant balloons; the use of cutting balloons; stenting proximal and distal to the dissection followed by stenting of the dissected segment; or the use of a long stent with 5 mm margins proximal and distal to the dissected segment), but there are limited data to support a single technique and care should be individualized. When PCI is used in STEMI, contemporary data suggest reasonable success with rates exceeding 90%.<sup>123</sup>

#### Coronary embolism

Coronary embolism as a cause of infarction occurs in about 3% of cases of STEMI.<sup>124</sup> It should be suspected when there is angiographic presence of thrombus in the absence of features suggesting a plaque rupture (such as luminal stenosis  $> 50\%$ , plaque ulceration, plaque irregularity, and/or dissection), or when there is thrombosis in the setting of otherwise angiographically normal coronary arteries.<sup>124,125</sup> Corroborative evidence that would support a diagnosis of embolism includes the involvement of more than 1 coronary artery, concomitant systemic embolization, and demonstration of a potential source, eg, intracardiac tumor, prosthetic valves, infective endocarditis, atrial fibrillation,

hypercoagulable state, and presence of intracardiac communication.<sup>126</sup> A scoring system has been proposed and may be useful in ambiguous cases, although it has not been externally validated.<sup>126</sup> The management of STEMI in the setting of coronary embolism depends on the size of the embolism, the flow in the involved vessel, and the amount of myocardium at risk. A distal coronary embolism or embolism of small branch vessels may be conservatively managed with IV antithrombotic therapies. In these cases, the focus of management should be on identifying and treating the underlying source of the thrombus to prevent future events. This can include transesophageal echo with an assessment for an intracardiac shunt, as well as long-term telemetry monitoring and a hematologic evaluation for a hypercoagulable state. On the other hand, a large thrombus burden in a proximal vessel will often require PCI. When PCI is indicated, wire manipulation alone may open coronary occlusions and the resultant improvement in coronary flow will allow for intrinsic fibrinolysis. For larger thrombus burden in a more proximal vessel, clot extraction devices may be needed (see Managing Thrombus section). Stent placement is usually not indicated unless intracoronary imaging suggests underlying plaque rupture or flow cannot be fully restored without it.

#### Myocardial infarction without obstructive coronary arteries

Approximately 8% of patients presenting with AMI do not have obstructive CAD on angiography defined as <50% stenosis of all coronary arteries<sup>127</sup> and are diagnosed with MINOCA.<sup>128</sup> MINOCA is more commonly seen with NSTEMI-ACS, with ~20% of patients with MINOCA presenting with STEMI. It can be caused by atherothrombotic plaque disruption (rupture, erosion) or nonatherothrombotic conditions such as SCAD, vasospasm, coronary microvascular dysfunction, or coronary embolism. Mortality and reinfarction rates have been reported at 2.6% and 3.9%, respectively.<sup>127</sup> Although pooled data suggest better outcomes with MINOCA than AMI due to obstructive CAD,<sup>127</sup> in 1 report, the adjusted long-term mortality was higher in MINOCA.<sup>129</sup> In STEMI cases and suspected MINOCA, evaluation including serial cardiac troponin (to confirm myocardial injury) and multimodality imaging with IVUS or OCT followed by cardiac MRI can be helpful to determine the etiology and help excluded MINOCA mimics such as myocarditis, Takotsubo cardiomyopathy or nonischemic causes of myocardial injury.<sup>130</sup> When possible, cardiac MRI should be performed early after the infarct to improve the diagnostic yield.<sup>131</sup> After the initial evaluation, if the etiologic cause of MINOCA remains unclear then evaluation for coronary microvascular dysfunction including provocative spasm testing is strongly encouraged.

#### Consensus Key Points for Managing Nonatherosclerotic Causes of STEMI

- In the absence of contraindications, intracoronary nitroglycerin should be administered during the diagnostic angiogram to help identify cases of epicardial spasm.
- In patients with SCAD and a patent infarct artery with TIMI 3 flow, conservative management is advised.
- Thrombectomy may be used in patients with coronary embolism.
- When MINOCA is suspected, additional investigations such as left ventriculogram, intracoronary imaging, cardiac MRI, and/or coronary microvascular dysfunction testing, may be necessary to identify the etiology and exclude MINOCA mimics.

#### Quality of care and outcomes

Hospital or health system-level STEMI committees should ideally track each STEMI to review activation times, times to treatment, and outcomes with the intent of identifying areas for improvement, crafting focused interventions, measuring the results of said interventions, and considering different strategies until the goal is obtained. Once goals are achieved,

maintenance and monitoring of quality should be the objective.<sup>7</sup> Quality of care includes care across the entire system, encompassing prehospital, intraprocedural, and postprocedural management. Measures that should be tracked include the following: (1) door-to-ECG acquisition; (2) door-in-door-out for transferred patients; (3) first door-to-device times for transferred patients; (4) first medical contact to device times for EMS presenting patients; (5) door-to-device times for walk-ins; (6) complaints of chest pain to device times for in-hospital STEMI cases; (7) periprocedural complications, and (8) mortality. Quality measures should also consider the balance of false activation rates (which can unduly burden and cost health care systems) and the outcomes for medically treated patients with STEMI. Additionally, the inclusion of every STEMI patient undergoing primary PCI (without exclusions), may be more informative about real-world conditions. Individual operators and programs can use national and state registry data for feedback to improve quality as compared to geographic benchmarks.

#### Consensus Key Points on Quality of Care and Outcomes

- All hospitals/health care systems should track every STEMI case to assess time-to-treatment, and outcomes with an aim for continued quality improvement.

#### Future directions

The percutaneous techniques for managing STEMI have dramatically evolved over the years. Despite these advances, there remain unanswered questions related to the management of certain patient subsets. First, the ECG is not always accurate in identifying patients with acute coronary occlusions, particularly in the left circumflex territory. The use of artificial intelligence to create a detailed scoring system (incorporating clinical and ECG variables) to predict acute arterial occlusion could prove useful and improve the number of patients getting timely reperfusion in the setting of an acute occlusion. This is currently under investigation.<sup>132</sup> Mobilizing STEMI team members to improve time to reperfusion continues to be challenging, particularly for patients transferred from outside institutions. App-based programs to aid in coordinated communication that provide real-time details regarding estimated time to transfer and patients' clinical status may assist in achieving more effective communication and shorter time to transfer to the CCL.<sup>133</sup> Additionally, future research is needed to better identify the optimal management of patients who present late after symptom onset or in those with large thrombus burden or no-reflow. Finally, given the newer wire-based methods to investigate microvascular function in the CCL and predict MVO, the focus may shift from TIMI flow as a marker of PCI success to measures of the index of microcirculatory resistance (IMR). The IMR is a guide wire-based quantitative measure of coronary microvasculature function that has been shown to correlate with the presence of MVO and infarct size measured on cardiac MRI.<sup>134,135</sup> Although data regarding the utility of IMR to guide therapies are currently lacking, it may prove to be a useful tool to assess MVO after PCI. IMR and other novel approaches to identify patients at risk for MVO in the CCL immediately after PCI may help identify those at-risk patients who might derive the greatest benefit from therapies aimed at reducing infarct size. Future studies are needed to further explore the options for limiting infarct size following PPCI.

#### Conclusions

ST-elevation myocardial infarction remains a leading cause of morbidity and mortality in the United States. Timely reperfusion with primary PCI is associated with improved outcomes. Optimal techniques for performing coronary angiography and PCI should always be employed to minimize procedural complications and optimize timely

tissue-level reperfusion with the goal of improving short- and long-term outcomes. Although there remains variability in practice across hospitals and CCL teams, standard protocols for rapid assessment, and mobilization of the CCL team as well as protocols for angiography and PCI can provide consistency and, ultimately, quality of care.

### Acknowledgments

The authors thank the Minneapolis Heart Institute Foundation (MHIF) Center for Coronary Artery Disease (CCAD) and AJ Chu (MHIF CCAD, Medical Audiovisual, Illustration and Animation Intern) for the assistance with creating Figure 5.

### Declaration of competing interest

J. Dawn Abbott discloses serving as a consultant for Boston Scientific Corporation. Nitin Barman discloses serving on the speakers bureau and receiving honoraria from Boston Scientific Corporation. All other authors reported no financial interests.

### Funding sources

This work was not supported by funding agencies in the public, commercial, or not-for-profit sectors.

### Supplementary material

To access the supplementary material accompanying this article, visit the online version of the *Journal of the Society for Cardiovascular Angiography & Interventions* at [10.1016/j.jscv.2024.102294](https://doi.org/10.1016/j.jscv.2024.102294).

### References

- Lawton JS, Tamis-Holland JE, Bangalore S, et al. 2021 ACC/AHA/SCAI guideline for coronary artery revascularization: a report of the American College of Cardiology/American Heart Association Joint Committee on Clinical Practice Guidelines. *Circulation*. 2022;145(3):e18–e114. <https://doi.org/10.1161/CIR.0000000001038>
- Jacobs AK, Antman EM, Faxon DP, Gregory T, Solis P. Development of systems of care for ST-elevation myocardial infarction patients: executive summary. *Circulation*. 2007;116(2):217–230. <https://doi.org/10.1161/CIRCULATIONAHA.107.184043>
- O'Gara PT, Kushner FG, Ascheim DD, et al. 2013 ACCF/AHA guideline for the management of ST-elevation myocardial infarction: executive summary: a report of the American College of Cardiology Foundation/American Heart Association Task Force on Practice Guidelines. *J Am Coll Cardiol*. 2013;61(4):485–510. <https://doi.org/10.1002/ccd.28754>
- Levine GN, Bates ER, Blankenship JC, et al. 2015 ACC/AHA/SCAI focused update on primary percutaneous coronary intervention for patients with ST-elevation myocardial infarction: an update of the 2011 ACCF/AHA/SCAI guideline for percutaneous coronary intervention and the 2013 ACCF/AHA guideline for the management of ST-elevation myocardial infarction. *J Am Coll Cardiol*. 2016;67(10):1235–1250. <https://doi.org/10.1016/j.jacc.2015.10.005>
- Szerlip M, Feldman DN, Aronow HD, et al. SCAI publications committee manual of standard operating procedures. *Catheter Cardiovasc Interv*. 2020;96(1):145–155. <https://doi.org/10.1002/ccd.28754>
- Naidu SS, Abbott JD, Bagai J, et al. SCAI expert consensus update on best practices in the cardiac catheterization laboratory: this statement was endorsed by the American College of Cardiology (ACC), the American Heart Association (AHA), and the Heart Rhythm Society (HRS) in April 2021. *Catheter Cardiovasc Interv*. 2021;98(2):255–276. <https://doi.org/10.1002/ccd.29744>
- Jacobs AK, Ali MJ, Best PJ, et al. Systems of care for ST-segment-elevation myocardial infarction: a policy statement from the American Heart Association. *Circulation*. 2021;144(20):e310–e327. <https://doi.org/10.1161/CIR.0000000000001025>
- Jollis JG, Al-Khalidi HR, Roettig ML, et al. Impact of regionalization of ST-segment-elevation myocardial infarction care on treatment times and outcomes for emergency medical services-transported patients presenting to hospitals with percutaneous coronary intervention: Mission: Lifeline Accelerator-2. *Circulation*. 2018;137(4):376–387. <https://doi.org/10.1161/CIRCULATIONAHA.117.032446>
- Shavadia JS, Roe MT, Chen AY, et al. Association between cardiac catheterization laboratory pre-activation and reperfusion timing metrics and outcomes in patients with ST-segment elevation myocardial infarction undergoing primary percutaneous coronary intervention: a report from the ACTION Registry. *JACC Cardiovasc Interv*. 2018;11(18):1837–1847. <https://doi.org/10.1016/j.jcin.2018.07.020>
- Bradley EH, Herrin J, Wang Y, et al. Strategies for reducing the door-to-balloon time in acute myocardial infarction. *N Engl J Med*. 2006;355(22):2308–2320. <https://doi.org/10.1056/NEJMsa063117>
- Krishnamoorthy P, Vengrenyuk A, Wasielewski B, et al. Mobile application to optimize care for ST-segment elevation myocardial infarction patients in a large healthcare system, STEMIcathAID: rationale and design. *Eur Heart J Digit Health*. 2021;2(2):189–201. <https://doi.org/10.1093/ehjdh/ztab010>
- Bosson N, Kaji AH, Niemann JT, et al. The utility of prehospital ECG transmission in a large EMS system. *Prehosp Emerg Care*. 2015;19(4):496–503. <https://doi.org/10.3109/10903127.2015.1005260>
- Bagai A, Jollis JG, Dauerman HL, et al. Emergency department bypass for ST-Segment-elevation myocardial infarction patients identified with a prehospital electrocardiogram: a report from the American Heart Association Mission: Lifeline program. *Circulation*. 2013;128(4):352–359. <https://doi.org/10.1161/CIRCULATIONAHA.113.002339>
- Meyers HP, Bracey A, Lee D, et al. Accuracy of OMI ECG findings versus STEMI criteria for diagnosis of acute coronary occlusion myocardial infarction. *Int J Cardiol Heart Vasc*. 2021;33:100767. <https://doi.org/10.1016/j.ijcha.2021.100767>
- Chen A, Ren X. Aortic dissection manifesting as ST-segment-elevation myocardial infarction. *Circulation*. 2015;131(21):e503–e504. <https://doi.org/10.1161/CIRCULATIONAHA.114.015200>
- Gargiulo G, Giacoppo D, Jolly SS, et al. Effects on mortality and major bleeding of radial versus femoral artery access for coronary angiography or percutaneous coronary intervention: meta-analysis of individual patient data from 7 multicenter randomized clinical trials. *Circulation*. 2022;146(18):1329–1343. <https://doi.org/10.1161/CIRCULATIONAHA.122.061527>
- Shroff AR, Gulati R, Drachman DE, et al. SCAI expert consensus statement update on best practices for transradial angiography and intervention. *Catheter Cardiovasc Interv*. 2020;95(2):245–252. <https://doi.org/10.1002/ccd.28672>
- Pitta SR, Prasad A, Kumar G, Lennon R, Rihal CS, Holmes DR. Location of femoral artery access and correlation with vascular complications. *Catheter Cardiovasc Interv*. 2011;78(2):294–299. <https://doi.org/10.1002/ccd.22827>
- Sandoval Y, Burke MN, Lobo AS, et al. Contemporary arterial access in the cardiac catheterization laboratory. *JACC Cardiovasc Interv*. 2017;10(22):2233–2241. <https://doi.org/10.1016/j.jcin.2017.08.058>
- Moussa Pacha H, Alahdab F, Al-Khadra Y, et al. Ultrasound-guided versus palpation-guided radial artery catheterization in adult population: a systematic review and meta-analysis of randomized controlled trials. *Am Heart J*. 2018;204:1–8. <https://doi.org/10.1016/j.ahj.2018.06.007>
- d'Entremont M-A, Alrashidi S, Seto AH, et al. Ultrasound guidance for transfemoral access in coronary procedures: an individual participant-level data metaanalysis from the femoral ultrasound trialist collaboration. *EuroIntervention*. 2024;20(1):66–74. <https://doi.org/10.4244/EIJ-D-22-00809>
- Levi N, Wolff R, Jubeh R, et al. Culprit lesion coronary intervention before complete angiography in ST-elevation myocardial infarction: a randomized clinical trial. *JAMA Netw Open*. 2024;7(3):e243729. <https://doi.org/10.1001/jamanetworkopen.2024.3729>
- Planer D, Mehran R, Witzensbichler B, et al. Prognostic utility of left ventricular end-diastolic pressure in patients with ST-segment elevation myocardial infarction undergoing primary percutaneous coronary intervention. *Am J Cardiol*. 2011;108(8):1068–1074. <https://doi.org/10.1016/j.amjcard.2011.06.007>
- Vogel RF, Delewi R, Wilschut JM, et al. Direct stenting versus stenting after predilatation in STEMI patients with high thrombus burden: a subanalysis from the randomized COMPARE CRUSH trial. *Eur Heart J*. 2022;43(Suppl 2). <https://doi.org/10.1093/eurheartj/ehac544.2068>
- Piscione F, Piccolo R, Cassese S, et al. Is direct stenting superior to stenting with predilatation in patients treated with percutaneous coronary intervention? Results from a meta-analysis of 24 randomised controlled trials. *Heart*. 2010;96(8):588–594. <https://doi.org/10.1136/hrt.2009.183277>
- Attizzani GF, Capodanno D, Ohno Y, Tamburino C. Mechanisms, pathophysiology, and clinical aspects of incomplete stent apposition. *J Am Coll Cardiol*. 2014;63(14):1355–1367. <https://doi.org/10.1016/j.jacc.2014.01.019>
- Sianos G, Papafaklis MI, Serruys PW. Angiographic thrombus burden classification in patients with ST-segment elevation myocardial infarction treated with percutaneous coronary intervention. *J Invasive Cardiol*. 2010;22(10 Suppl B):6B–14B.
- Swilaas T, Vlaar PJ, van der Horst IC, et al. Thrombus aspiration during primary percutaneous coronary intervention. *N Engl J Med*. 2008;358(6):557–567. <https://doi.org/10.1056/NEJMoa0706416>
- Vlaar PJ, Swilaas T, van der Horst IC, et al. Cardiac death and reinfarction after 1 year in the Thrombus Aspiration during Percutaneous coronary intervention in acute myocardial infarction Study (TAPAS): a 1-year follow-up study. *Lancet*. 2008;371(9628):1915–1920. [https://doi.org/10.1016/S0140-6736\(08\)60833-8](https://doi.org/10.1016/S0140-6736(08)60833-8)
- Fröbert O, Lagerqvist B, Olivecrona GK, et al. Thrombus aspiration during ST-segment elevation myocardial infarction. *N Engl J Med*. 2013;369(17):1587–1597. <https://doi.org/10.1056/NEJMoa1308789>
- Jolly SS, Cairns JA, Yusuf S, et al. Randomized trial of primary PCI with or without routine manual thrombectomy. *N Engl J Med*. 2015;372(15):1389–1398. <https://doi.org/10.1056/NEJMoa1415098>
- Jolly SS, James S, Džavik V, et al. Thrombus aspiration in ST-segment-elevation myocardial infarction: an individual patient meta-analysis: thrombectomy trialists collaboration. *Circulation*. 2017;135(2):143–152. <https://doi.org/10.1161/CIRCULATIONAHA.116.025371>

33. Mathews SJ, Parikh SA, Wu W, et al. Sustained mechanical aspiration thrombectomy for high thrombus burden coronary vessel occlusion: the multicenter CHEETAH study. *Circ Cardiovasc Interv.* 2023;16(2):e012433. <https://doi.org/10.1161/CIRCINTERVENTIONS.122.012433>
34. Thiele H, Schindler K, Friedenberger J, et al. Intracoronary compared with intravenous bolus abciximab application in patients with ST-elevation myocardial infarction undergoing primary percutaneous coronary intervention: the randomized Leipzig immediate percutaneous coronary intervention abciximab IV versus IC in ST-elevation myocardial infarction trial. *Circulation.* 2008;118(1):49–57. <https://doi.org/10.1161/CIRCULATIONAHA.107.747642>
35. Thiele H, Wöhrle J, Hambrecht R, et al. Intracoronary versus intravenous bolus abciximab during primary percutaneous coronary intervention in patients with acute ST-elevation myocardial infarction: a randomised trial. *Lancet.* 2012;379(9819):923–931. [https://doi.org/10.1016/S0140-6736\(11\)61872-2](https://doi.org/10.1016/S0140-6736(11)61872-2)
36. Stone GW, Maehara A, Witzenbichler B, et al. Intracoronary abciximab and aspiration thrombectomy in patients with large anterior myocardial infarction: the INFUSE-AMI randomized trial. *JAMA.* 2012;307(17):1817–1826. <https://doi.org/10.1001/jama.2012.421>
37. Gu YL, Kampinga MA, Wieringa WG, et al. Intracoronary versus intravenous administration of abciximab in patients with ST-segment elevation myocardial infarction undergoing primary percutaneous coronary intervention with thrombus aspiration: the comparison of intracoronary versus intravenous abciximab administration during emergency reperfusion of ST-segment elevation myocardial infarction (CICERO) trial. *Circulation.* 2010;122(25):2709–2717. <https://doi.org/10.1161/CIRCULATIONAHA.110.002741>
38. Elbadawi A, Elgendy IY, Megaly M, et al. Meta-analysis of randomized trials of intracoronary versus intravenous glycoprotein IIb/IIIa inhibitors in patients with ST-elevation myocardial infarction undergoing primary percutaneous coronary intervention. *Am J Cardiol.* 2017;120(7):1055–1061. <https://doi.org/10.1016/j.amjcard.2017.06.040>
39. Agarwal SK, Agarwal S. Role of intracoronary fibrinolytic therapy in contemporary PCI practice. *Cardiovasc Revasc Med.* 2019;20(12):1165–1171. <https://doi.org/10.1016/j.carev.2018.11.021>
40. Bittl JA, Ryan TJ, Keaney JF, et al. Coronary artery perforation during excimer laser coronary angioplasty. The percutaneous Excimer Laser Coronary Angioplasty Registry. *J Am Coll Cardiol.* 1993;21(5):1158–1165. [https://doi.org/10.1016/0735-1097\(93\)90240-2](https://doi.org/10.1016/0735-1097(93)90240-2)
41. Yamanaka Y, Shimada Y, Tonomura D, et al. Laser vaporization of intracoronary thrombus and identifying plaque morphology in ST-segment elevation myocardial infarction as assessed by optical coherence tomography. *J Interv Cardiol.* 2021;2021:5590109. <https://doi.org/10.1155/2021/5590109>
42. Faria D, Jeronimo A, Escaned J, Nuñez-Gil JJ. Subacute right coronary artery thrombosis treated by using excimer laser coronary angioplasty: a case report. *Eur Heart J Case Rep.* 2023;7(10), ytaad499. <https://doi.org/10.1093/ehjcr/ytaad499>
43. Carrick D, Oldroyd KG, McEntegart M, et al. A randomized trial of deferred stenting versus immediate stenting to prevent no- or slow-reflow in acute ST-segment elevation myocardial infarction (DEFER-STEMI). *J Am Coll Cardiol.* 2014;63(20):2088–2098. <https://doi.org/10.1016/j.jacc.2014.02.530>
44. Qiao J, Pan L, Zhang B, et al. Deferred versus immediate stenting in patients with ST-segment elevation myocardial infarction: a systematic review and meta-analysis. *J Am Heart Assoc.* 2017;6(3):e004838. <https://doi.org/10.1161/JAHA.116.004838>
45. Kelbæk H, Hofsten DE, Køber L, et al. Deferred versus conventional stent implantation in patients with ST-segment elevation myocardial infarction (DANAMI 3-DEFER): an open-label, randomised controlled trial. *Lancet.* 2016;387(10034):2199–2206. [https://doi.org/10.1016/S0140-6736\(16\)30072-1](https://doi.org/10.1016/S0140-6736(16)30072-1)
46. Ndrepepa G, Tiroch K, Fusaro M, et al. 5-year prognostic value of no-reflow phenomenon after percutaneous coronary intervention in patients with acute myocardial infarction. *J Am Coll Cardiol.* 2010;55(21):2383–2389. <https://doi.org/10.1016/j.jacc.2009.12.054>
47. Niccoli G, Scalone G, Lerman A, Crea F. Coronary microvascular obstruction in acute myocardial infarction. *Eur Heart J.* 2016;37(13):1024–1033. <https://doi.org/10.1093/eurheartj/ehv484>
48. Fajar JK, Heriansyah T, Rohman MS. The predictors of no reflow phenomenon after percutaneous coronary intervention in patients with ST elevation myocardial infarction: a meta-analysis. *Indian Heart J.* 2018;70(Suppl 3):S406–S418. <https://doi.org/10.1016/j.ihj.2018.01.032>
49. Li XD, Yang YJ, Hao YC, et al. Effect of pre-procedural statin therapy on myocardial no-reflow following percutaneous coronary intervention: a meta analysis. *Chin Med J (Engl).* 2013;126(9):1755–1760. <https://doi.org/10.3760/cma.j.issn.0366-6999.20122700>
50. Alqarqaz M, Basir M, Alaswad K, O'Neill W. Effects of Impella on coronary perfusion in patients with critical coronary artery stenosis. *Circ Cardiovasc Interv.* 2018;11(4):e005870. <https://doi.org/10.1161/CIRCINTERVENTIONS.117.005870>
51. Maekawa K, Kawamoto K, Fuke S, et al. Effects of intraaortic balloon pumping on the angiographic no-reflow phenomenon after percutaneous coronary intervention in patients with anterior myocardial infarction. *Circ J.* 2006;70(1):37–43. <https://doi.org/10.1253/circj.70.37>
52. Navarese EP, Buffon A, Andreotti F, et al. Adenosine improves post-procedural coronary flow but not clinical outcomes in patients with acute coronary syndrome: a meta-analysis of randomized trials. *Atherosclerosis.* 2012;222(1):1–7. <https://doi.org/10.1016/j.atherosclerosis.2011.11.001>
53. Nazir SA, McCann GP, Greenwood JP, et al. Strategies to attenuate micro-vascular obstruction during P-PCI: the randomized reperfusion facilitated by local adjunctive therapy in ST-elevation myocardial infarction trial. *Eur Heart J.* 2016;37(24):1910–1919. <https://doi.org/10.1093/eurheartj/ehw136>
54. Niccoli G, Rigattieri S, De Vita MR, et al. Open-label, randomized, placebo-controlled evaluation of intracoronary adenosine or nitroprusside after thrombus aspiration during primary percutaneous coronary intervention for the prevention of microvascular obstruction in acute myocardial infarction: the REOPEN-AMI study (Intracoronary Nitroprusside Versus Adenosine in Acute Myocardial Infarction). *JACC Cardiovasc Interv.* 2013;6(6):580–589. <https://doi.org/10.1016/j.jcin.2013.02.009>
55. Su Q, Li L, Liu Y. Short-term effect of verapamil on coronary no-reflow associated with percutaneous coronary intervention in patients with acute coronary syndrome: a systematic review and meta-analysis of randomized controlled trials. *Clin Cardiol.* 2013;36(8):E11–E16. <https://doi.org/10.1002/clc.22143>
56. Navarese EP, Frediani L, Kandzari DE, et al. Efficacy and safety of intracoronary epinephrine versus conventional treatments alone in STEMI patients with refractory coronary no-reflow during primary PCI: the RESTORE observational study. *Catheter Cardiovasc Interv.* 2021;97(4):602–611. <https://doi.org/10.1002/ccd.29113>
57. Khan KA, Qamar N, Saghir T, et al. Comparison of intracoronary epinephrine and adenosine for no-reflow in normotensive patients with acute coronary syndrome (COAR trial). *Circ Cardiovasc Interv.* 2022;15(2):e011408. <https://doi.org/10.1161/CIRCINTERVENTIONS.121.011408>
58. Byrne RA, Rossello X, Coughlan JJ, et al. 2023 ESC Guidelines for the management of acute coronary syndromes. *Eur Heart J.* 2023;44(38):3720–3826. <https://doi.org/10.1093/eurheartj/ehad191>
59. Gao XF, Ge Z, Kong XQ, et al. 3-year outcomes of the ULTIMATE trial comparing intravascular ultrasound versus angiography-guided drug-eluting stent implantation. *JACC Cardiovasc Interv.* 2021;14(3):247–257. <https://doi.org/10.1016/j.jcin.2020.10.001>
60. Hannan EL, Zhong Y, Reddy P, et al. Percutaneous coronary intervention with and without intravascular ultrasound for patients with complex lesions: utilization, mortality, and target vessel revascularization. *Circ Cardiovasc Interv.* 2022;15(6):e011687. <https://doi.org/10.1161/CIRCINTERVENTIONS.121.011687>
61. Holm NR, Andreasen LN, Neghabat O, et al. OCT or angiography guidance for PCI in complex bifurcation lesions. *N Engl J Med.* 2023;389(16):1477–1487. <https://doi.org/10.1056/NEJMoa2307770>
62. Stone GW, Christiansen EH, Ali ZA, et al. Intravascular imaging-guided coronary drug-eluting stent implantation: an updated network meta-analysis. *Lancet.* 2024;403(10429):824–837. [https://doi.org/10.1016/S0140-6736\(23\)02454-6](https://doi.org/10.1016/S0140-6736(23)02454-6)
63. Choi IJ, Lim S, Choo EH, et al. Impact of intravascular ultrasound on long-term clinical outcomes in patients with acute myocardial infarction. *JACC Cardiovasc Interv.* 2021;14(2):2431–2443. <https://doi.org/10.1016/j.jcin.2021.08.021>
64. Kim Y, Bae S, Johnson TW, et al. Role of intravascular ultrasound-guided percutaneous coronary intervention in optimizing outcomes in acute myocardial infarction. *J Am Heart Assoc.* 2022;11(5):e023481. <https://doi.org/10.1161/JAHA.121.023481>
65. Yonetsu T, Wakabayashi K, Mizukami T, et al. Optical coherence tomography-guided percutaneous coronary intervention for ST-segment elevation myocardial infarction: rationale and design of the ATLAS-OCT study. *Am J Cardiol.* 2023;203:466–472. <https://doi.org/10.1016/j.amjcard.2023.07.077>
66. Klein LW, Nathan S, Maehara A, et al. SCAI Expert Consensus Statement on management of in-stent restenosis and stent thrombosis. *J Soc Cardiovasc Angiogr Interv.* 2023;2(4):100971. <https://doi.org/10.1016/j.jscai.2023.100971>
67. Stone GW, Selker HP, Thiele H, et al. Relationship between infarct size and outcomes following primary PCI: patient-level analysis from 10 randomized trials. *J Am Coll Cardiol.* 2016;67(14):1674–1683. <https://doi.org/10.1016/j.jacc.2016.01.069>
68. Welt FGP, Batchelor W, Spears JR, et al. Reperfusion injury in patients with acute myocardial infarction: JACC Scientific Statement. *J Am Coll Cardiol.* 2024;83(22):2196–2213. <https://doi.org/10.1016/j.jacc.2024.02.056>
69. Ibanez B, Aletas AH, Arai AE, et al. Cardiac MRI endpoints in myocardial infarction experimental and clinical trials: JACC Scientific Expert Panel. *J Am Coll Cardiol.* 2019;74(2):238–256. <https://doi.org/10.1016/j.jacc.2019.05.024>
70. Galli M, Niccoli G, De Maria G, et al. Coronary microvascular obstruction and dysfunction in patients with acute myocardial infarction. *Nat Rev Cardiol.* 2024;21(5):283–298. <https://doi.org/10.1038/s41569-023-00953-4>
71. van Kranenburg M, Magro M, Thiele H, et al. Prognostic value of microvascular obstruction and infarct size, as measured by CMR in STEMI patients. *JACC Cardiovasc Imaging.* 2014;7(9):930–939. <https://doi.org/10.1016/j.jcmg.2014.05.010>
72. de Waha S, Patel MR, Granger CB, et al. Relationship between microvascular obstruction and adverse events following primary percutaneous coronary intervention for ST-segment elevation myocardial infarction: an individual patient data pooled analysis from seven randomized trials. *Eur Heart J.* 2017;38(47):3502–3510. <https://doi.org/10.1093/eurheartj/ehx414>
73. Lechner I, Reindl M, Stiermaier T, et al. Clinical outcomes associated with various microvascular injury patterns identified by CMR after STEMI. *J Am Coll Cardiol.* 2024;83(21):2052–2062. <https://doi.org/10.1016/j.jacc.2024.03.408>
74. Hausenloy DJ, Kharbanda RK, Møller UK, et al. Effect of remote ischaemic conditioning on clinical outcomes in patients with acute myocardial infarction (CONDI-2/ERIC-PPCI): a single-blind randomised controlled trial. *Lancet.* 2019;394(10207):1415–1424. [https://doi.org/10.1016/S0140-6736\(19\)32039-2](https://doi.org/10.1016/S0140-6736(19)32039-2)
75. Gibson CM, Ajmi I, von Koenig CL, Turco MA, Stone GW. Pressure-controlled intermittent coronary sinus occlusion: a novel approach to improve

- microvascular flow and reduce infarct size in STEMI. *Cardiovasc Revasc Med.* 2022; 45:9–14. <https://doi.org/10.1016/j.carrev.2022.07.007>
76. Stone GW, Martin JL, de Boer MJ, et al. Effect of supersaturated oxygen delivery on infarct size after percutaneous coronary intervention in acute myocardial infarction. *Circ Cardiovasc Interv.* 2009;2(5):366–375. <https://doi.org/10.1161/CIRCINTERVENTIONS.108.840066>
  77. Chen S, David SW, Khan ZA, et al. One-year outcomes of supersaturated oxygen therapy in acute anterior myocardial infarction: the IC-HOT study. *Catheter Cardiovasc Interv.* 2021;97(6):1120–1126. <https://doi.org/10.1002/ccd.29090>
  78. Dallan LAP, Giannetti NS, Rochitte CE, et al. Cooling as an adjunctive therapy to percutaneous intervention in acute myocardial infarction: COOL-MI InCor Trial. *Ther Hypothermia Temp Manag.* 2021;11(3):135–144. <https://doi.org/10.1089/ther.2020.0018>
  79. Kapur NK, Alkhouli MA, DeMartini TJ, et al. Unloading the left ventricle before reperfusion in patients with anterior ST-segment-elevation myocardial infarction. *Circulation.* 2019;139(3):337–346. <https://doi.org/10.1161/CIRCULATIONAHA.118.038269>
  80. Kloner RA, Creech JL, Stone GW, O'Neill WW, Burkhoff D, Spears JR. Update on cardioprotective strategies for STEMI: focus on supersaturated oxygen delivery. *JACC Basic Transl Sci.* 2021;6(12):1021–1033. <https://doi.org/10.1016/j.jacbst.2021.07.011>
  81. O'Neill WW, Martin JL, Dixon SR, et al. Acute Myocardial Infarction with Hyperoxemic Therapy (AMIHOT): a prospective, randomized trial of intracoronary hyperoxemic reperfusion after percutaneous coronary intervention. *J Am Coll Cardiol.* 2007;50(5):397–405. <https://doi.org/10.1016/j.jacc.2007.01.099>
  82. David SW, Khan ZA, Patel NC, et al. Evaluation of intracoronary hyperoxemic oxygen therapy in acute anterior myocardial infarction: the IC-HOT study. *Catheter Cardiovasc Interv.* 2019;93(5):882–890. <https://doi.org/10.1002/ccd.27905>
  83. Falah B, Kotinkaduwa LN, Schonning MJ, et al. Microvascular obstruction in patients with anterior STEMI treated with supersaturated oxygen. *J Soc Cardiovasc Angiogr Interv.* 2024;3(5):101356. <https://doi.org/10.1016/j.jscai.2024.101356>
  84. Berg J, Jablonowski R, Nordlund D, et al. Mild hypothermia attenuates ischaemia/reperfusion injury: insights from serial non-invasive pressure-volume loops. *Cardiovasc Res.* 2023;119(12):2230–2243. <https://doi.org/10.1093/cvr/cvad028>
  85. Gao R, Zhao H, Wang X, et al. Mild hypothermia therapy lowers the inflammatory level and apoptosis rate of myocardial cells of rats with myocardial ischemia-reperfusion injury via the NLRP3 inflammasome pathway. *Comp Math Methods Med.* 2021;2021:6415275. <https://doi.org/10.1155/2021/6415275>
  86. Götberg M, Olivecrona GK, Koul S, et al. A pilot study of rapid cooling by cold saline and endovascular cooling before reperfusion in patients with ST-elevation myocardial infarction. *Circ Cardiovasc Interv.* 2010;3(5):400–407. <https://doi.org/10.1161/CIRCINTERVENTIONS.110.957902>
  87. Erlinge D, Götberg M, Lang I, et al. Rapid endovascular catheter core cooling combined with cold saline as an adjunct to percutaneous coronary intervention for the treatment of acute myocardial infarction. The CHILL-MI trial: a randomized controlled study of the use of central venous catheter core cooling combined with cold saline as an adjunct to percutaneous coronary intervention for the treatment of acute myocardial infarction. *J Am Coll Cardiol.* 2014;63(18):1857–1865. <https://doi.org/10.1016/j.jacc.2013.12.027>
  88. Nichol G, Strickland W, Shavelle D, et al. Prospective, multicenter, randomized, controlled pilot trial of peritoneal hypothermia in patients with ST-segment-elevation myocardial infarction. *Circ Cardiovasc Interv.* 2015;8(3):e001965. <https://doi.org/10.1161/CIRCINTERVENTIONS.114.001965>
  89. Noc M, Erlinge D, Neskovic AN, et al. COOL AMI EU pilot trial: a multicentre, prospective, randomised controlled trial to assess cooling as an adjunctive therapy to percutaneous intervention in patients with acute myocardial infarction. *EuroIntervention.* 2017;13(5):e531–e539. <https://doi.org/10.4244/EIJ-D-17-00279>
  90. Testori C, Beitzke D, Mangold A, et al. Out-of-hospital initiation of hypothermia in ST-segment elevation myocardial infarction: a randomised trial. *Heart.* 2019; 105(7):531–537. <https://doi.org/10.1136/heartjnl-2018-313705>
  91. El Farissi M, Keulards DCJ, van 't Veer M, et al. Selective intracoronary hypothermia in patients with ST-elevation myocardial infarction. Rationale and design of the EURO-ICE trial. *EuroIntervention.* 2021;16(17):1444–1446. <https://doi.org/10.4244/EIJ-D-19-00471>
  92. Kapur NK, Kim RJ, Moses JW, et al. Primary left ventricular unloading with delayed reperfusion in patients with anterior ST-elevation myocardial infarction: rationale and design of the STEMI-DTU randomized pivotal trial. *Am Heart J.* 2022;254: 122–132. <https://doi.org/10.1016/j.ahj.2022.08.011>
  93. Hochman JS, Sleeper LA, Webb JG, et al. Early revascularization in acute myocardial infarction complicated by cardiogenic shock. SHOCK Investigators. Should We Emergently Revascularize Occluded Coronaries for Cardiogenic ShockN. *Engl J Med.* 1999;341(9):625–634. <https://doi.org/10.1056/NEJM199908263410901>
  94. Basir MB, Kapur NK, Patel K, et al. Improved outcomes associated with the use of shock protocols: updates from the National Cardiogenic Shock Initiative. *Catheter Cardiovasc Interv.* 2019;93(7):1173–1183. <https://doi.org/10.1002/ccd.28307>
  95. Naidu SS, Baran DA, Jentzer JC, et al. SCAI SHOCK Stage Classification Expert Consensus Update: a review and incorporation of validation studies. *J Soc Cardiovasc Angiogr Interv.* 2022;1(1):100008. <https://doi.org/10.1016/j.jscai.2021.100008>
  96. Henry TD, Tomey MI, Tamis-Holland JE, et al. Invasive management of acute myocardial infarction complicated by cardiogenic shock: a scientific statement from the American Heart Association. *Circulation.* 2021;143(15):e815–e829. <https://doi.org/10.1161/CIR.0000000000000959>
  97. Garan AR, Kanwar M, Thayer KL, et al. Complete hemodynamic profiling with pulmonary artery catheters in cardiogenic shock is associated with lower in-hospital mortality. *JACC Heart Fail.* 2020;8(11):903–913. <https://doi.org/10.1016/j.jchf.2020.08.012>
  98. Saxena A, Garan AR, Kapur NK, et al. Value of hemodynamic monitoring in patients with cardiogenic shock undergoing mechanical circulatory support. *Circulation.* 2020;141(14):1184–1197. <https://doi.org/10.1161/CIRCULATIONAHA.119.043080>
  99. Møller JE, Engstrøm T, Jensen LO, et al. Microaxial flow pump or standard care in infarct-related cardiogenic shock. *N Engl J Med.* 2024;390(15):1382–1393. <https://doi.org/10.1056/NEJMoa2312572>
  100. Chau KH, Kirtane AJ, Easterwood RM, et al. Stent thrombosis risk over time on the basis of clinical presentation and platelet reactivity: analysis from ADAPT-DES. *JACC Cardiovasc Interv.* 2021;14(4):417–427. <https://doi.org/10.1016/j.jcin.2020.12.005>
  101. Park DW, Clare RM, Schulte PJ, et al. Extent, location, and clinical significance of non-infarct-related coronary artery disease among patients with ST-elevation myocardial infarction. *JAMA.* 2014;312(19):2019–2027. <https://doi.org/10.1001/jama.2014.15095>
  102. Stähli BE, Varbella F, Linke A, et al. Timing of complete revascularization with multivessel PCI for myocardial infarction. *N Engl J Med.* 2023;389(15): 1368–1379. <https://doi.org/10.1056/NEJMoa2307823>
  103. Diletti R, den Dekker WK, Bennett J, et al. Immediate versus staged complete revascularisation in patients presenting with acute coronary syndrome and multivessel coronary disease (BIOVASC): a prospective, open-label, non-inferiority, randomised trial. *Lancet.* 2023;401(10383):1172–1182. [https://doi.org/10.1016/S0140-6736\(23\)00351-3](https://doi.org/10.1016/S0140-6736(23)00351-3)
  104. Thiele H, Akin I, Sandri M, et al. PCI strategies in patients with acute myocardial infarction and cardiogenic shock. *N Engl J Med.* 2017;377(25):2419–2432. <https://doi.org/10.1056/NEJMoa1710261>
  105. Pymirat E, Cayla G, Simon T, et al. Multivessel PCI guided by FFR or angiography for myocardial infarction. *N Engl J Med.* 2021;385(4):297–308. <https://doi.org/10.1056/NEJMoa2104650>
  106. Lee JM, Kim HK, Park KH, et al. Fractional flow reserve versus angiography-guided strategy in acute myocardial infarction with multivessel disease: a randomized trial. *Eur Heart J.* 2023;44(6):473–484. <https://doi.org/10.1093/eurheartj/ehac763>
  107. Panchoy SB, Patel P, Patel GA, et al. Effects of previous coronary artery bypass graft surgery on in-hospital mortality in ST-segment elevation myocardial infarction: national dataset analysis. *Int J Cardiol Heart Vasc.* 2021;36:100878. <https://doi.org/10.1016/j.ijcha.2021.100878>
  108. Généreux P, Madhavan MV, Mintz GS, et al. Ischemic outcomes after coronary intervention of calcified vessels in acute coronary syndromes. Pooled analysis from the HORIZONS-AMI (Harmonizing Outcomes With revascularization and Stents in acute myocardial infarction) and ACUITY (Acute Catheterization and Urgent Intervention Triage Strategy) trials. *J Am Coll Cardiol.* 2014;63(18): 1845–1854. <https://doi.org/10.1016/j.jacc.2014.01.034>
  109. Sugiyama T, Yamamoto E, Fracassi F, et al. Calcified plaques in patients with acute coronary syndromes. *JACC Cardiovasc Interv.* 2019;12(6):531–540. <https://doi.org/10.1016/j.jcin.2018.12.013>
  110. Riley RF, Patel MP, Abbott JD, et al. SCAI expert consensus statement on the management of calcified coronary lesions. *J Soc Cardiovasc Angiogr Interv.* 2024;3(2):101259. <https://doi.org/10.1016/j.jscai.2023.101259>
  111. Choi KH, Song YB, Jeong JO, et al. Treatment strategy for STEMI with bifurcation culprit lesion undergoing primary PCI: the COBIS II Registry. *Rev Esp Cardiol (Engl Ed).* 2018;71(10):811–819. <https://doi.org/10.1016/j.rec.2018.01.002>
  112. Assal A, Almaghraby A, El Amrawy A. Management of bifurcation culprit lesion in the setting of anterior ST elevation myocardial infarction. *Eur Heart J.* 2021; 42(Suppl 1):ehab724.1445. <https://doi.org/10.1093/eurheartj/ehab724.1445>
  113. Crawley PD, Mahlow WJ, Huntsinger DR, Afniwala S, Wortham DC. Giant coronary artery aneurysms: review and update. *Tex Heart Inst J.* 2014;41(6):603–608. <https://doi.org/10.14503/THIJ-13-3896>
  114. Kawsara A, Núñez Gil IJN, Alqahtani F, Moreland J, Rihal CS, Alkhouli M. Management of coronary artery aneurysms. *JACC Cardiovasc Interv.* 2018; 11(13):1211–1223. <https://doi.org/10.1016/j.jcin.2018.02.041>
  115. Kim TH, Marfatia R, Lee J, Azrin M. Giant coronary aneurysm management with Viabahn covered stent. *Cardiovasc Revasc Med.* 2017;18(6S1):56–59. <https://doi.org/10.1016/j.carrev.2017.03.019>
  116. Win HK, Polsani V, Chang SM, Kleiman NS. Stent-assisted coil embolization of a large fusiform aneurysm of proximal anterior descending artery: novel treatment for coronary aneurysms. *Circ Cardiovasc Interv.* 2012;5(1):e3–e5. <https://doi.org/10.1161/CIRCINTERVENTIONS.111.966754>
  117. Ong P, Athanasiadis A, Hill S, Vogelsberg H, Voehringer M, Sechtem U. Coronary artery spasm as a frequent cause of acute coronary syndrome: the CASPAR (Coronary Artery Spasm in Patients With Acute Coronary Syndrome) Study. *J Am Coll Cardiol.* 2008;52(7):523–527. <https://doi.org/10.1016/j.jacc.2008.04.050>
  118. Hayes SN, Tweet MS, Adlam D, et al. Spontaneous coronary artery dissection: JACC state-of-the-art review. *J Am Coll Cardiol.* 2020;76(8):961–984. <https://doi.org/10.1016/j.jacc.2020.05.084>
  119. Saw J. Coronary angiogram classification of spontaneous coronary artery dissection. *Catheter Cardiovasc Interv.* 2014;84(7):1115–1122. <https://doi.org/10.1002/ccd.25293>

120. Hayes SN, Kim ESH, Saw J, et al. Spontaneous coronary artery dissection: current state of the science: a scientific statement from the American Heart Association. *Circulation*. 2018;137(19):e523–e557. <https://doi.org/10.1161/CIR.0000000000000564>
121. Tweet MS, Eleid MF, Best PJM, et al. Spontaneous coronary artery dissection: revascularization versus conservative therapy. *Circ Cardiovasc Interv*. 2014;7(6):777–786. <https://doi.org/10.1161/CIRCINTERVENTIONS.114.001659>
122. Krittanawong C, Gulati R, Eitzman D, Jneid H. Revascularization in patients with spontaneous coronary artery dissection: where are we now? *J Am Heart Assoc*. 2021;10(13):e018551. <https://doi.org/10.1161/JAHA.120.018551>
123. Lobo AS, Cantu SM, Sharkey SW, et al. Revascularization in patients with spontaneous coronary artery dissection and ST-segment elevation myocardial infarction. *J Am Coll Cardiol*. 2019;74(10):1290–1300. <https://doi.org/10.1016/j.jacc.2019.06.065>
124. Popovic B, Agrinier N, Bouchahda N, et al. Coronary embolism among ST-segment-elevation myocardial infarction patients: mechanisms and management. *Circ Cardiovasc Interv*. 2018;11(1):e005587. <https://doi.org/10.1161/CIRCINTERVENTIONS.117.005587>
125. Raphael CE, Heit JA, Reeder GS, et al. Coronary embolus: an underappreciated cause of acute coronary syndromes. *JACC Cardiovasc Interv*. 2018;11(2):172–180. <https://doi.org/10.1016/j.jcin.2017.08.057>
126. Shibata T, Kawakami S, Noguchi T, et al. Prevalence, clinical features, and prognosis of acute myocardial infarction attributable to coronary artery embolism. *Circulation*. 2015;132(4):241–250. <https://doi.org/10.1161/CIRCULATIONAHA.114.015134>
127. Pasupathy S, Lindahl B, Litwin P, et al. Survival in patients with suspected myocardial infarction with nonobstructive coronary arteries: a comprehensive systematic review and meta-analysis from the MINOCA global collaboration. *Circ Cardiovasc Qual Outcomes*. 2021;14(11):e007880. <https://doi.org/10.1161/CIRCOUTCOMES.121.007880>
128. Tamis-Holland JE, Jneid H, Reynolds HR, et al. Contemporary diagnosis and management of patients with myocardial infarction in the absence of obstructive coronary artery disease: a scientific statement from the American Heart Association. *Circulation*. 2019;139(18):e891–e908. <https://doi.org/10.1161/CIR.0000000000000670>
129. Quesada O, Yildiz M, Henry TD, et al. Mortality in ST-segment elevation myocardial infarction with nonobstructive coronary arteries and mimickers. *JAMA Netw Open*. 2023;6(11):e2343402. <https://doi.org/10.1001/jamanetwo.rkopen.2023.43402>
130. Reynolds HR, Maehara A, Kwong RY, et al. Coronary optical coherence tomography and cardiac magnetic resonance imaging to determine underlying causes of myocardial infarction with nonobstructive coronary arteries in women. *Circulation*. 2021;143(7):624–640. <https://doi.org/10.1161/CIRCULATIONAHA.120.052008>
131. Dastidar AG, Rodrigues JCL, Johnson TW, et al. Myocardial infarction with nonobstructed coronary arteries: impact of CMR early after presentation. *JACC Cardiovasc Imaging*. 2017;10(10 Pt A):1204–1206. <https://doi.org/10.1016/j.jccm.2016.11.010>
132. Al-Zaiti SS, Martin-Gill C, Zègre-Hemsey JK, et al. Machine learning for ECG diagnosis and risk stratification of occlusion myocardial infarction. *Nat Med*. 2023;29(7):1804–1813. <https://doi.org/10.1038/s41591-023-02396-3>
133. Garcia H, Springer B, Vengrenyuk A, et al. Deploying a novel custom mobile application for STEMI activation and transfer in a large healthcare system to improve cross-team workflow. STEMIcathAID implementation project. *Am Heart J*. 2022;253:30–38. <https://doi.org/10.1016/j.ahj.2022.06.008>
134. De Maria GLD, Alkhalil M, Wolfrum M, et al. Index of microcirculatory resistance as a tool to characterize microvascular obstruction and to predict infarct size regression in patients with STEMI undergoing primary PCI. *J Am Coll Cardiol Imaging*. 2019;12(5):837–848. <https://doi.org/10.1016/j.jcmg.2018.02.018>
135. McGeoch R, Watkins S, Berry C, et al. The index of microcirculatory resistance measured acutely predicts the extent and severity of myocardial infarction in patients with ST-segment elevation myocardial infarction. *JACC Cardiovasc Interv*. 2010;3(7):715–722. <https://doi.org/10.1016/j.jcin.2010.04.009>