



COVID-19 Vaccines: A Radiological Review of the Good, the Bad, and the Ugly

Ishan Kumar¹ Mohammad Sharoon Ansari¹ Ashish Verma¹ Pramod Kumar Singh¹
Sankha Shubhra Chakrabarti² Ram Chandra Shukla¹

¹Department of Radiodiagnosis and Imaging, Institute of Medical Sciences, Banaras Hindu University, Varanasi, Uttar Pradesh, India

²Department of Geriatrics, Institute of Medical Sciences, Banaras Hindu University, Varanasi, Uttar Pradesh, India

Address for correspondence Ashish Verma, MBBS, DNB, PhD, Professor, Department of Radio diagnosis, Institute of Medical Sciences, Banaras Hindu University, Varanasi 221005, Uttar Pradesh, India (e-mail: averma@bhu.ac.in).

Indian J Radiol Imaging 2024;34:714–725.

Abstract

The World Health Organization has declared “with great hope” an end to COVID-19 as a public health emergency. The vaccination drive that started in December 2020 played a crucial role in controlling the pandemic. However, the pace at which COVID-19 vaccines were developed and deployed for general population use led to vaccine hesitancy, largely owing to concerns regarding the safety and efficacy of the vaccines. Radiology has been instrumental in demonstrating the extent of pulmonary involvement and identification of the complications of COVID-19, and the same holds true for vaccine-related complications. This review summarizes the existing body of radiological literature regarding the efficacy, adverse events, and imaging pitfalls that accompany the global rollout of various COVID-19 vaccines.

Keyword

- ▶ COVID-19 vaccines
- ▶ radiology
- ▶ complications
- ▶ effectiveness

Introduction

It has been almost 4 years since the first case of COVID-19 was reported. The disease has infected nearly 650 million people and claimed more than 6 million lives to date. The disease has profoundly affected the geopolitical, socioeconomic, and public health structure of the world and continues to do so. It was very soon realized that an effective vaccine is the only solution for this calamity and within less than a year from the beginning of this pandemic, several research teams developed vaccines against SARS-CoV-2. The vaccination drive that started in December 2020 reached an unprecedented scale within months and within almost 2 years, more than 13 billion doses had been distributed globally with 68.5% of the world population receiving at least one dose of a COVID-19 vaccine.

COVID-19 vaccines have been proven to be an effective tool to bring the pandemic under control. But despite their proven efficacy and safety, COVID-19 vaccines initially did

not find widespread acceptance, particularly due to the phenomenon of vaccine hesitancy, defined by the World Health Organization (WHO) as a delay in acceptance or refusal of vaccines despite the availability of vaccination services.¹ Reasons for COVID-19 vaccine hesitancy and acceptance are determined by a complex interplay of many factors, with different countries having different vaccine hesitancy factors. However, lack of visible proof of vaccine effectiveness and concerns related to vaccine-associated adverse events have been important factors affecting vaccine hesitancy, particularly because most of the COVID-19 infections are either asymptomatic or mild, and the pace with which COVID-19 vaccines have been developed and deployed for general population use. In general, vaccine development takes approximately 15 years; therefore, the speed of development of COVID-19 vaccine within 1 year contributed toward vaccine hesitancy.^{2,3}

article published online
April 21, 2024

DOI <https://doi.org/10.1055/s-0044-1785210>
ISSN 0971-3026.

© 2024. Indian Radiological Association. All rights reserved.

This is an open access article published by Thieme under the terms of the Creative Commons Attribution-NonDerivative-NonCommercial-License, permitting copying and reproduction so long as the original work is given appropriate credit. Contents may not be used for commercial purposes, or adapted, remixed, transformed or built upon. (<https://creativecommons.org/licenses/by-nc-nd/4.0/>)

Thieme Medical and Scientific Publishers Pvt. Ltd., A-12, 2nd Floor, Sector 2, Noida-201301 UP, India

Radiology has been very instrumental in demonstrating the extent of pulmonary involvement, identification of complications, and even early diagnosis of COVID-19. High-resolution computed tomography (HRCT) of lungs provided an objective method in assessing the volume of lungs involved in a case of COVID-19 utilizing various semiquantitative scores. Moreover, radiological investigations were key in diagnosing various abdominal, cardiovascular, neurological, and musculoskeletal complications, especially potentially lethal pulmonary thromboembolism (PTE). Magnetic resonance imaging (MRI) provided important information about the extent of involvement of rhino-orbital-cerebral mucormycosis (ROCM) and HRCT was used to diagnose secondary fungal and other bacterial infections affecting the lung and guide the management of these coinfections.⁴ The field of radiology is uniquely poised to assess both the advantages and various adverse effects of vaccinations. A comprehensive radiological appraisal of the effects of the COVID-19 vaccine can yield crucial information that can provide a roadmap for the future management course of the pandemic. The benefits of a comparative review include providing an opportunity to establish the efficacy of vaccines in terms of involvement of pulmonary parenchyma by SARS-CoV-2 and secondarily identifying the possible adverse events and their radiological manifestations. This review encompasses information provided by the existing body of radiological literature regarding the efficacy, adverse events, and imaging pitfalls that accompany the global rollout of various COVID-19 vaccines.

Radiological Assessment of Efficacy of COVID-19 Vaccines

Chest radiographs have relatively low sensitivity for detecting COVID-19 pneumonia; however, these are vital imaging tools for continuous monitoring of disease severity progression. The Brixia score is a semiquantitative score employed from frontal radiographs to assess the disease severity of COVID-19.⁵ In this scoring system, both lungs are divided into three zones each (upper, middle, and lower), and a score of 0 to 3 is assigned to each zone (score 0: no lung abnormalities; score 1: interstitial infiltrates; score 2: interstitial predominance; score 3: alveolar predominance) and a total score out of 18 is allotted. HRCT is the most sensitive modality to assess pulmonary involvement, and typical findings seen are bilateral, peripheral ground-glass opacities (GGOs) with or without overlapping areas of consolidation, or associated interlobular septal thickening. Various scoring systems are used for assessing the severity of lung involvement in CT. The most commonly used CT severity scoring systems are the following:

- CT visual quantitative score (scale 0–25): scores of 1 to 5 are assigned according to the percentage of involvement (score 1: <5%; score 2: 5–25%; score 3: 25–49%; score 4: 50–74%; and score 5: >75%) in five anatomical lobes of the lungs, that is, right upper, right middle, right lower, left upper, and left lower lobes.⁶
- Chest CT severity score (scale 0–40): scores of 0–2 are assigned according to percentage of involvement (score 0: no involvement; score 1: <50%; score 2: ≥50% involvement)

in 18 anatomical segments of the lung with an additional division of the apicoposterior segment of the left upper lobe into apical and posterior divisions and anteromedial segment of the left lower lobe into anterior and medial segments.⁷

Several studies assessed the safety and efficacy of COVID-19 vaccines that are being administered and have shown that the administration of vaccines scales down the disease severity in COVID-19 along with an effect on the systemic inflammatory and coagulopathic responses. However, there is a relative paucity of radiological data to provide substantial evidence of the reduction of the extent of pulmonary involvement to document the effectiveness of the vaccines. ► **Table 1** summarizes the results of the radiological studies documenting the comparison between pulmonary involvement in unvaccinated patients and partially or completely vaccinated individuals who acquired breakthrough COVID-19 infection.^{7–17} The largest such study has been published by Verma et al from our institution involving 826 patients (581 unvaccinated, 196 single-dose incomplete vaccination, and 49 two-dose complete vaccination), using CT severity score (scale 0–40) as an imaging surrogate of the biological activity of the virus.⁸ The study demonstrated that patients receiving both doses of the SARS-CoV-2 vaccine showed lower CT severity scores in comparison to unvaccinated individuals or those who received only one dose of vaccine. Also, the mean severity scores were significantly lesser in younger patients (<60 years). Among the various radiological findings, GGOs and consolidations were significantly less in the vaccinated group, while other findings such as fibrosis, discoid atelectasis, and halo were similar in both groups. Similar results have been observed in the studies by Dubey et al¹⁷ and Lee et al,⁹ demonstrating the efficacy of complete vaccination. As opposed to these studies, a study by Gurumurthy et al showed that vaccination results in lower CT scores regardless of complete two-dose vaccination or partial one-dose vaccination. Few of the studies have demonstrated similar results using chest X-ray-based Brixia score, which was significantly lower in vaccinated patients.¹⁶

Granata et al made an interesting observation in their study on aerated residual lung volume (%) calculated by automated software using CT scan images in different strains of COVID.¹⁵ The study demonstrated that for the Delta variant, the aerated residual lung volume percentage is significantly higher in individuals vaccinated with at least two doses. However, for the Omicron variant, the residual aerated lung percentage was higher in patients inoculated with three doses, whereas vaccination with two doses did not improve lung aeration.

Very few studies have compared the extent of pulmonary involvement between the types of vaccines. In the study by Verma et al, a comparison between two vaccine types showed that the mean CT severity score was significantly lower in patients receiving nonreplicating viral vector vaccine (ChAdOx1-S, Covishield, AstraZeneca, University of Oxford) compared to those receiving inactivated virus vaccine (BBV152, Covaxin, Bharat Biotech). However, the latter group was very small in their study.⁸ Another study

Table 1 Comparison between pulmonary involvement on radiological studies in unvaccinated patients and partially or completely vaccinated individuals who acquired breakthrough COVID infection

Study	No. of patients	Study population	Key radiological findings
Verma et al ⁸	826	Vaccinated ($n = 245$) <ul style="list-style-type: none"> • Nonreplicating viral vector vaccine ChAdOx1-S ($n = 209$) • Inactivated virus vaccine BBV152 ($n = 36$) Completely vaccinated ($n = 49$) Partially vaccinated ($n = 196$) Unvaccinated ($n = 581$)	CT severity score (0–40 scale): <ul style="list-style-type: none"> • Mean score was significantly lower in completely vaccinated patients (3.5 ± 6.3) vis-à-vis incompletely vaccinated (10.1 ± 10.5) and nonvaccinated (10.1 ± 11.4) patients • The mean CT scores were significantly lower in vaccinated patients of lower ages (<60 y), while patients >60 y did not show significantly different CT scores between the vaccinated and nonvaccinated groups Consolidations and ground-glass opacities were significantly lower in the group receiving complete vaccination as compared to the unvaccinated and incompletely vaccinated patients
Lee et al ⁹	761	Vaccinated ($n = 47$) Unvaccinated ($n = 587$)	In 412 patients who underwent chest CT examination during hospitalization, absence of pneumonia was seen in 59% of fully vaccinated patients and 22% of unvaccinated patients
Vicini et al ¹⁰	467	Vaccinated ($n = 251$) <ul style="list-style-type: none"> • BNT162b2 mRNA ($n = 167$) • ChAdOx1-S adenovirus vector ($n = 84$) Unvaccinated ($n = 216$)	Absence of pneumonia: <ul style="list-style-type: none"> • 15% in unvaccinated patients; 29% in ChAdOx1-S group and 51% with BNT162b2 vaccine Mean CT score (0–25 scale): <ul style="list-style-type: none"> • Significantly higher in unvaccinated patients (9.7 ± 6.1) than in the BNT162b2 (5.2 ± 6.1) or ChAdOx1-S (6.2 ± 5.9) group
Hanafi et al ¹¹	60	Vaccinated ($n = 30$) Unvaccinated ($n = 30$)	Chest X-ray Brixia score (0–18): <ul style="list-style-type: none"> • Mean score significantly lower in the vaccinated group ($1.53 + 1.27$) compared to the unvaccinated patients ($6.0 + 2.61$)
Borghesi et al ¹²	205	Vaccinated ($n = 109$) Unvaccinated ($n = 96$)	Chest X-ray Brixia score (0–18): <ul style="list-style-type: none"> • Median score significantly lower in the vaccinated group (median: 1; IQR: 0–6) compared to the unvaccinated group (median: 5; IQR: 3–7)
Rahman et al ¹³	50	Vaccinated ($n = 50$)	• CT score (0–25 scale): 0 in 14% cases; 1–8 in 46%; 9–14 in 22% cases, and >15 in 18% cases
Lakhia et al ¹⁴	229	Vaccinated ($n = 67$) <ul style="list-style-type: none"> • Completely vaccinated ($n = 29$) • Partially vaccinated ($n = 38$) Unvaccinated ($n = 162$)	CT score (0–25 scale): <ul style="list-style-type: none"> • Median CT score significantly lower in the completely vaccinated group (median: 0; IQR: 0–3) compared to the partially vaccinated group (median: 3.5; IQR: 0–9) and the unvaccinated group (median: 10; IQR: 7–14)
Granata et al ¹⁵	71	Vaccinated ($n = 31$) <ul style="list-style-type: none"> • Delta variant ($n = 18$) • Omicron ($n = 13$) Unvaccinated ($n = 40$) <ul style="list-style-type: none"> • Delta variant ($n = 20$) • Omicron ($n = 20$) 	Median value of (range) of aerated residual lung volume (%) calculated by automated software using CT scan images <i>In Delta variant</i> <ul style="list-style-type: none"> • Significantly lower median values in the unvaccinated group (median: 46.7; IQR: 13.60–75.60) compared to those vaccinated with two doses (median: 67.10;

Table 1 (Continued)

Study	No. of patients	Study population	Key radiological findings
			IQR: 17.10–89.80) or three doses (median: 52.00; IQR: 19.40–84.50) <i>In Omicron variant</i> <ul style="list-style-type: none"> Significantly lower median values in the unvaccinated group (median: 48.35; IQR: 8.20–83.30) and vaccinated with two doses (median: 38.30; IQR: 18.90–73.30) compared to those vaccinated with three doses (median: 61.9; IQR: 31.60–73.60)
Gurumurthy et al ¹⁶	306	Vaccinated (<i>n</i> = 163) ChAdOx1-S adenovirus vector (<i>n</i> = 107) Inactivated virus vaccine BBV152 (<i>n</i> = 56) <ul style="list-style-type: none"> Completely vaccinated (<i>n</i> = 39) Partially vaccinated (<i>n</i> = 124) Unvaccinated (<i>n</i> = 143)	CT score (0–25 scale): <ul style="list-style-type: none"> Mild CT score (<7) was significantly in higher percentage in the vaccinated group (31%) than in the unvaccinated group (11.9%) No significant difference between partially vaccinated (single-dose) and completely vaccinated (double-dose) groups
Dubey et al ¹⁷	200	Vaccinated (<i>n</i> = 100) <ul style="list-style-type: none"> Completely vaccinated (<i>n</i> = 73) Partially vaccinated (<i>n</i> = 27) Unvaccinated (<i>n</i> = 100)	CT score (0–25 scale): <ul style="list-style-type: none"> Median score was significantly lower in the vaccinated group (median: 7; range: 0–24) compared to the unvaccinated group (median: 13; range: 1–25) The median score of the fully vaccinated group was lower than that of the partially vaccinated individuals (6 vs. 9)

Abbreviations: CT; computed tomography; IQR, interquartile range.

comparing these two vaccines showed that a mild score (<7) was present in 33% of the patients vaccinated with non-replicating viral vector vaccine (ChAdOx1-S) and in 25% of the patients receiving inactivated virus vaccine (BBV152). A study by Vicini et al showed that the mean CT score was slightly lower in patients receiving messenger ribonucleic acid (mRNA) vaccine (BNT162b2, Pfizer BioNTech) compared to those receiving viral vector vaccine (ChAdOx1-S).¹⁰

Imaging of COVID-19-Related Vaccine Complications

Cardiovascular Complications

Before the COVID-19 pandemic, cardiac complications related to hepatitis B, smallpox, and *Haemophilus influenzae* vaccines were reported.^{18,19} Myocarditis is the most commonly described cardiac complication after receiving these vaccines. With such an unprecedented level of mass vaccination for COVID-19, a spectrum of cardiac complications has been reported all over the world after various vaccines. While myopericarditis has been the most common cardiac complication of COVID-19 vaccination, few cases of myocardial infarction and arrhythmias have been reported, but the association appears unclear.¹⁹

Myocarditis/Pericarditis

As per the data provided by the Advisory Committee on Immunization Practices, 1,226 reports of probable

myocarditis/pericarditis have been reported after administration of 300 million COVID-19 mRNA vaccine doses till June 2021, two-thirds of which followed the second dose.^{19,20} Several mechanisms like hyperimmune response, aberrant nonspecific innate immune response, molecular mimicry, or functional autoantibodies, etc., have been postulated for postvaccination myocarditis. The clinical features were mostly mild chest pain and most of the patients improved without any treatment other than supportive measures and rest. Symptoms typically started within 1 week after vaccination (median of 3 days from the second dose in 81% of patients). Electrocardiographic (ECG) changes are nonspecific and the majority of patients had ST- or T-wave changes, and/or elevated cardiac enzymes.²⁰ Cardiac MRI plays an important role in the evaluation of acute myocarditis, and the diagnosis of myocarditis on MRI is based on the 2018 Revised Lake Louise consensus criteria.²¹

- T2-weighted images:** regional/global hyperintensity (edema); increased T2 relaxation time on T2 mapping.
- T1-weighted images:** Late postgadolinium enhancement (LGE; **–Fig. 1**); increased T1 relaxation time on T1 mapping.
- Supportive criteria:** Pericardial effusion/enhancement; regional/global wall motion abnormalities.

A retrospective study by Fronza et al on 92 patients with myocarditis (COVID-19 vaccine group [*n* = 21]; COVID-19 illness group [*n* = 10]; other myocarditis group [*n* = 61])

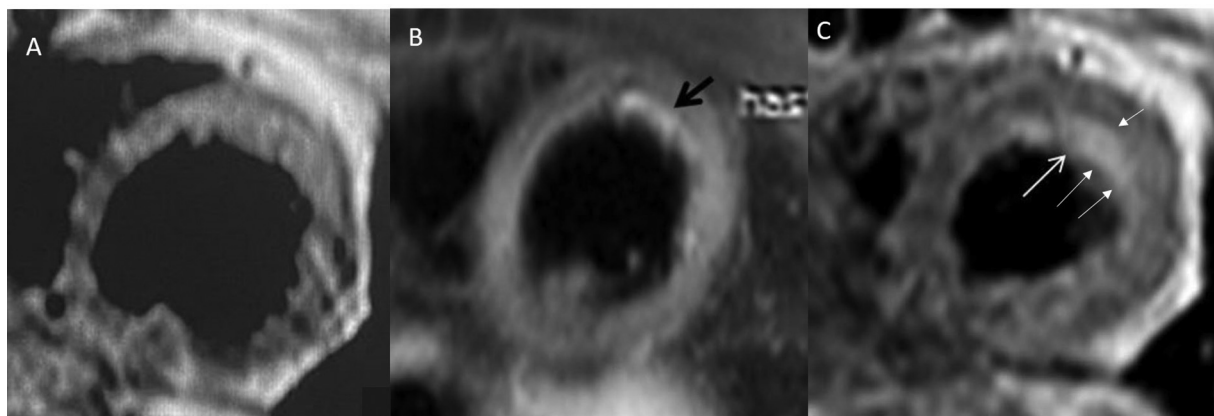


Fig. 1 A 48-year-old woman presented with nausea, dyspnea on exertion, difficulty in talking, and chest discomfort, 7 days after receiving her first dose of ChAdOx1 vaccine. (A) Magnetic resonance imaging (MRI) short-axis T1 image, (B) fat-suppressed T2 image, and (C) T1 image obtained after 10 minutes of contrast administration show T2 hyperintensity in the subendocardial region (*black arrow*) and subendocardial and mid-myocardial delayed postcontrast enhancement (*white arrows*) in the anterolateral part of the left ventricle suggestive of myocarditis.

showed that there is no significant difference in the pattern of the myocardial findings at cardiac MRI in COVID-19-vaccine-associated myocarditis compared to other causes of myocarditis including COVID-19.²² The common findings on MRI are T2 wall hyperintensity (77%), subepicardial LGE (62%), mid-wall LGE (20%), pericardial enhancement (43%), and effusion/edema (19%). Subendocardial/transmural LGE was not reported in this study; however, others have reported isolated cases of subendocardial LGE.²³ Less severe functional impairment, lower T1 signal, and less frequent involvement of the septum have been observed in COVID-19-vaccine-associated myocarditis compared to other forms of myocarditis.^{23–25} Patel et al demonstrated that septal LGE and mid-wall LGE involvements were more common in other cases of myocarditis compared to COVID-19-vaccine-associated myocarditis.²⁴ No significant difference in myocardial injury patterns among different COVID-19 vaccines has been noted. Nonhospitalized patients with myocarditis had MRI abnormalities comparable to those needing hospital admission for vaccine-associated myocarditis. Even the extent of late gadolinium enhancement in the vaccine group was lower and abnormalities on tissue characterization (T1 and T2 mapping) were less severe relative to the other groups.^{23–25} In a series of 15 pediatric patients (<19 years) with suspected myocarditis following the Pfizer vaccine, LGE was observed in 12 children (80%).²⁶

Acute Coronary Syndrome

Few studies have reported cases of myocardial infarction resulting from coronary artery disease occurring within 24 hours of receiving the first dose of mRNA vaccines. A report describing CT coronary angiography findings showed extensive noncalcified plaque in the proximal left coronary artery resulting in complete focal occlusion just proximal to the origin of the first obtuse marginal artery as well as thrombotic occlusion of the proximal segment of the left circumflex artery.²⁷ A case of thrombosis of the distal left anterior descending coronary artery, in the first diagonal

branch, and the distal part of the dominant right coronary artery has been reported after Pfizer vaccine.²⁸ Kounis' syndrome has also been suggested as a possible explanation for acute coronary events following vaccination, which is referred to as allergic vasospastic acute coronary syndrome with or without the presence of underlying coronary artery disease.^{28,29} A recent study comparing coronary thromboembolic disease in those who received COVID-19 vaccine ($n = 37$) and those who did not ($n = 52$) showed that thrombus grades on coronary angiography were significantly higher in the vaccinated group.³⁰

Pulmonary and Other Vascular Thromboembolism and Vasculitis

Along with cerebral venous sinus thrombosis and coronary tree thrombosis, pulmonary arterial thrombosis and deep vein thrombosis (DVT) are the most common vascular complications of COVID-19 vaccines, mostly reported with AstraZeneca vaccine or Pfizer COVID-19 vaccination. DVT can be diagnosed on Doppler ultrasound (US), which demonstrates noncompressible thrombosed lumen and absence of Doppler flow in femoropopliteal and calf veins. Pulmonary CT angiography is the most appropriate modality used to diagnose PTE (→ **Fig. 2**), with variable reported findings ranging from bilateral massive thrombosis to submassive saddle thrombosis and multiple filling defects in the segmental and subsegmental branches of both lobes and pulmonary infarcts.^{31–35}

Vaccine-induced immune thrombotic thrombocytopenia (VITT) is a condition identified mostly with ChAdOx1 vaccine that can result in multiple-site vascular thrombosis.³⁶ Other less commonly implicated vaccines include Ad26.COV2.S (Janssen; Johnson & Johnson); data are limited for the Gam-COVID-Vac/Sputnik V (Gamaleya Institute) vaccine, but a few cases have been reported.³⁷ A study describing the pattern and anatomical distribution of thrombosis from 32 centers in the United Kingdom using US, CT, and MRI on 40 patients showed that the most common types of thrombosis

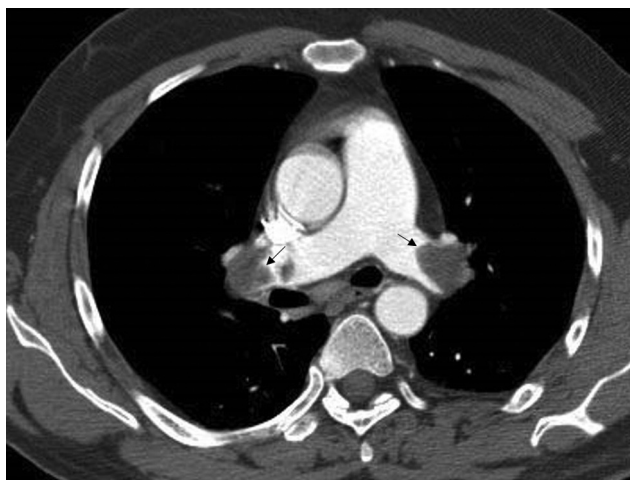


Fig. 2 A 26-year-old man presented with shortness of breath, 2 days after receiving the second dose of ChAdOx1 vaccine. Computed tomography (CT) pulmonary angiography axial image shows filling defect in the right and left pulmonary arteries (black arrows), suggestive of pulmonary thromboembolism.

were cerebral venous thrombosis (CVT; 85%), pulmonary embolism (PE; 43%), portomesenteric venous thrombosis (25%), DVT (27%), and systemic arterial thrombosis (20%).³⁸ The analysis showed that in VITT, additional site imaging revealed additional sites of thrombus, the most common being a combination of CVT and PTE, followed by CVT and portomesenteric thrombosis. Various case reports have demonstrated aortic, iliac arterial, and femoral arterial thrombosis after ChAdOx1 vaccination, resulting in abdominal symptoms or limb ischemia. Thrombosis of the aortic arch and unilateral radial artery has been also reported.³⁹

Along with cutaneous, antineutrophil cytoplasmic antibody (ANCA) associated vasculitis and renal small vessel vasculitis have been the most common vasculitic patterns observed after COVID-19 vaccination. A case report has demonstrated large-vessel arteritis after 1 day of the first injection of BNT162b2 in a 63-year-old woman, involving the aortic arch, thoracic and abdominal aorta, carotid, and subclavian arteries, similar to giant cell arteritis pattern. Although the patient refused MR angiography, increased fluorodeoxyglucose (FDG) vascular uptake in positron emission tomography (PET) scan was seen in the involved vessel wall, suggestive of large-vessel vasculitis.⁴⁰

Neurological Complications

The National Board of UK and Vaccine Adverse Events Reporting System (VAERS) have reported a spectrum of complications involving the central and peripheral nervous systems. **Table 2** summarizes the radiological spectrum of complications involving the central and peripheral nervous systems after COVID-19 vaccination.^{41–68}

The most common peripheral nervous system complication is Guillain-Barré syndrome (GBS) with variable imaging and clinical findings.^{41–46} Thickening and postcontrast enhancement of the caudal nerve roots are the most common abnormalities seen on lumbar spine MRI. Similar thickening

and enhancement have been observed in the facial nerve at the fundus of the internal acoustic meatus in three cases of facial diplegia variant of GBS.^{47–49} Keir et al have reported enhancement and T2/fluid attenuated inversion recovery (FLAIR) hyperintensity of the olfactory nerve and bilateral olfactory tracts in a patient feeling weak, and fatigued, with random episodes of smokelike smell after receiving the second dose of Pfizer COVID-19 vaccine and progressed to hyposmia to additional odorants.⁵⁰ Cases of Parsonage-Turner syndrome were reported with MR neurography findings showing hyperintensity and hourglasslike constrictions of the suprascapular nerve of the median and suprascapular nerves.^{51–55}

Among the central nervous system (CNS) complications, the most frequently reported adverse event is cerebral venous sinus thrombosis, with superior sagittal and sigmoid sinus being the most commonly thrombosed sinuses seen on MR or CT venography (**Fig. 3**).^{56,57} Cerebral dural venous thrombosis is assumed to be a manifestation of VITT, a well-recognized adverse event associated with ChAdOx1 nCov-19 vaccine (AstraZeneca). VITT is related to autoantibody generation against platelet factor four (PF4), with all the confirmed cases showing raised titers and the patients phenotypically demonstrating thrombosis in various sites. Other known, but relatively less common, adverse events are transverse myelitis, superior ophthalmic vein thrombosis, acute disseminated encephalomyelitis, multiple sclerosis, neuromyelitis optica, hemorrhagic stroke, and ischemic stroke, etc.^{41,42,58–68}

Pulmonary Complications

Vaccine-induced interstitial lung disease (ILD) was first reported in an 86-year-old man who presented with acute onset of fever, shortness of breath, and hypoxemia requiring high-flow nasal cannula 1 day after receiving the first dose of COVID-19 mRNA vaccine in which CT of the chest showed bilateral, diffuse GGOs, with areas of focal consolidation and centrilobular nodules.⁶⁹ High-dose methylprednisolone was administered, which led to rapid improvement in clinical condition and imaging findings. Other cases of ILD have been reported after mRNA vaccine, which revealed acute interstitial pneumonia pattern (bilateral diffuse GGOs) or cryptogenic organizing pneumonia (COP) pattern of opacities (X-ray showed an infiltrative shadow in the right lower lobe).⁷⁰ Acute exacerbation of idiopathic pulmonary fibrosis has been reported in which CT showed bilateral GGOs, which were replaced by subpleural reticulation after steroid therapy which remained and progressed.⁷¹

Abdominal Complications

A wide spectrum of abdominal manifestations of COVID-19 vaccination has been described. These complications are assumed to be the outcome of either vaccine-associated vascular abnormalities or the consequence of vaccine-mediated autoimmune phenomenon.

The VITT can result in thrombosis of the abdominal and pelvic vessels, with the most common being portomesenteric thrombosis and systemic arterial thrombosis. CT/MR

Table 2 Radiological spectrum of complications involving the central and peripheral nervous systems after COVID-19 vaccination

Disorder	Vaccine	Clinical feature	MRI features
Peripheral nervous system			
Guillain–Barré syndrome (GBS)	ChAdOx1 vaccine Pfizer Johnson & Johnson, d26. COV2.S	Distal paresthesia and symmetrical, progressive muscle weakness hands and feet, 10–20 d after vaccination; spontaneous recovery after 5 d	<ul style="list-style-type: none"> Thickening and postcontrast enhancement of caudal nerve roots and pial enhancement of conus medullaris
Facial diplegia variant of GBS	Janssen vaccine Pfizer Johnson & Johnson	Unilateral facial droop (similar to Bell's palsy), subjective weakness, and paresthesias in all limbs	<ul style="list-style-type: none"> T2 hyperintensity in the median and suprascapular nerves Enhancement of the bilateral internal auditory canal fundi and bilateral cisternal segments of the trigeminal nerves
Phantosmia	Pfizer-BioNTech vaccine	Fatigue, “smokelike” smell, hyposmia	<ul style="list-style-type: none"> Enhancement and T2/FLAIR hyperintensity of olfactory nerve and bilateral olfactory tracts Thickened and clumped olfactory nerve filia
Parsonage–Turner syndrome	mRNA-1273 Moderna BNT162b2 vaccine (Pfizer-BioNTech)	Persistent severe shoulder pain/cramping pain, inability to abduct shoulder	<ul style="list-style-type: none"> T2 hyperintensity and areas of hourglasslike constriction in the median nerve in the distal arm with edema in the pronator teres T2 hyperintensity hourglasslike constrictions of the suprascapular nerve with edema of the supraspinatus and infraspinatus muscles
Central nervous system			
Cerebral sinus venous thrombosis (CVST)	AstraZeneca Vaxzevria vaccine	Severe headache, acute cerebrovascular accident 6–12 d after vaccination Patient died within 2 h–5 d	<ul style="list-style-type: none"> Multiple subacute intra-axial hemorrhages in the frontal and temporal lobes with the vein of Galen, superior sagittal and aortic arch, and basilar artery thrombosis Superior sagittal, sigmoid sinus thrombus, and diffuse cortical vein thrombosis
Transverse myelitis	ChAdOx1	2 wk after vaccination, progressive paresthesia below T4, along with lower limb weakness	<ul style="list-style-type: none"> T2 hyperintense, intramedullary-enhancing lesion over the spinal cord at the T1–T6 vertebral levels
Infarct	ChAdOx1	10–14 d	<ul style="list-style-type: none"> Middle cerebral artery/internal cerebral artery territory infarct with hemorrhagic transformation
ADEM	Pfizer vaccine Sinovac	2–10 wk after vaccination Seizure, hemiparesis, or progressive generalized weakness Improved after treatment	<ul style="list-style-type: none"> Diffuse, symmetric T2 hyperintensity in the bilateral central semi-ovale, internal capsules extending through the brainstem into the bilateral cerebellar hemispheres T2/FLAIR hyperintensity in unilateral cerebellar peduncle, with mass effect on the fourth ventricle T2/FLAIR hyperintensity in the thalamus, bilateral corona radiata, left diencephalon, and parietal cortex
Multiple sclerosis	Pfizer-BioNTech BNT162b2	6 d after vaccination, sensory impairment below the T6 level Mild improvement after plasma exchange	<ul style="list-style-type: none"> Contrast-enhancing lesion at the T6 level, T2/FLAIR hyperintense plaques (>20) in the splenium, periventricular, juxtacortical region, and cerebellum

Table 2 (Continued)

Disorder	Vaccine	Clinical feature	MRI features
Superior ophthalmic artery thrombosis	ChAdOx1	Binocular diplopia at vertical and right lateral gaze 10 d after vaccination. Patient treated and recovered 26 d after admission	• Bilateral high T2 signal intensity, and postcontrast filling defect in the superior ophthalmic veins
Creutzfeldt–Jakob disease	ChAdOx1	Rapidly progressive dementia with asymmetric rigidity 1 d after receiving the 2nd dose	• Diffusion restriction in the bilateral caudate, putamina, and cerebral cortex in the bilateral cerebral hemispheres (→ Fig. 4)
Rhombencephalitis	Pfizer/BioNTech	Unilateral facial paralysis, paralysis of the hypoglossal nerve, and massive ataxia of all extremities, 2 wk after vaccination	• FLAIR hyperintensity of the brainstem, mesencephalon, and cerebellar hemispheres around the fourth ventricle

Abbreviations: FLAIR; fluid attenuated inversion recovery; MRI, magnetic resonance imaging.

angiography is the key modality for assessment of thrombus distribution and it has been shown that inclusion of additional sites in the scan can reveal additional locations of thrombosis, especially CVT and PTE.³⁸ A case report has shown a combined thrombus involving arterial (coeliac trunk, hepatic, and splenic arteries), portal (superior and inferior mesenteric veins, splenic and portal veins), and venous system (inferior vena cava and

common iliac vein) in a 62-year-old patient, 1 day after receiving the first dose of vaccine (ChAdOx1-S [mfgd. by AstraZeneca] vaccine).⁷²

Vaccine-mediated abdominal autoimmune phenomena usually present with a wide spectrum of manifestations ranging from autoimmune hepatitis to glomerular disease.^{73,74} COVID-19 vaccine (mostly Pfizer-BioNTech COVID-19 mRNA vaccine) associated acute pancreatitis has been reported as case reports with a variety of CT findings ranging from normal to mildly edematous pancreas (interstitial pancreatitis) with/without peripancreatic inflammation/fluid collection to pancreatic necrosis and necrotic collections. The causal association is debatable in most cases; however, using the Naranjo criteria, the

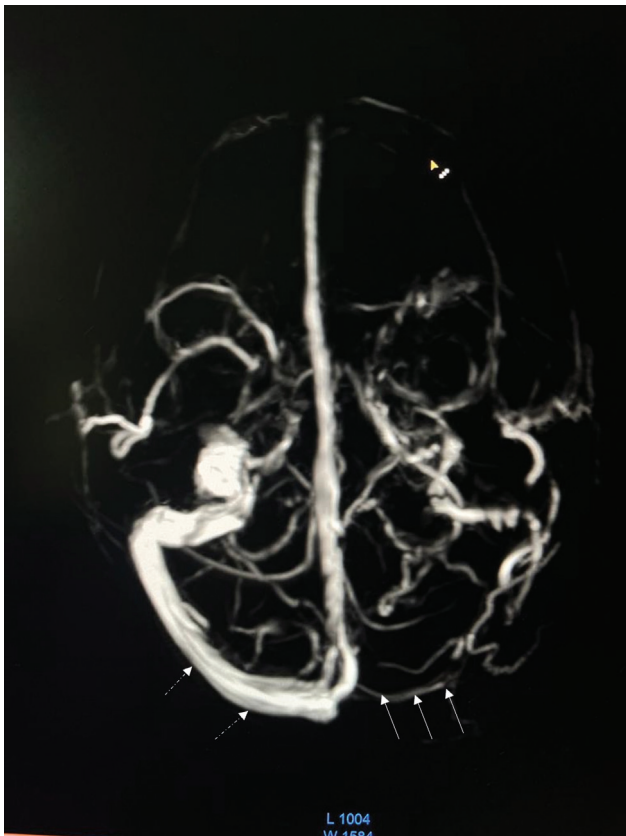


Fig. 3 A 33-year-old woman presented with severe headache 3 days after the first dose of ChAdOx1 vaccination. There was hemorrhagic infarct in the left thalamus extending to the midbrain (not shown). Magnetic resonance (MR) venography revealed nonvisualization of the left sigmoid sinus (arrow) indicating venous thrombosis. The right sigmoid sinus was normally seen (dashed arrows).

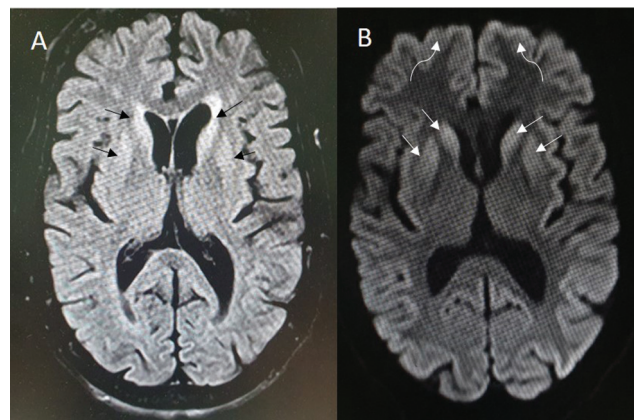


Fig. 4 A 65-year-old woman presented with behavioral abnormality 1 day after receiving the second dose of ChAdOx1 vaccine, which rapidly deteriorated to incoherent speech, aggravated forgetfulness, hallucinations, abnormal movements of limbs, and jaw and neck dystonia. (A) Magnetic resonance imaging (MRI) axial fluid attenuated inversion recovery (FLAIR) and (B) diffusion weighted images showed FLAIR hyperintensity (black arrows) and diffusion restriction in bilateral caudate, putamina (white arrows), and the cerebral cortex in bilateral hemispheres (curved arrows). Electroencephalogram (EEG) revealed bilateral biphasic and triphasic sharp wave periodic discharges of 1 Hz, with slowing of background activity, suggestive of Creutzfeldt–Jakob disease. Over the next 2 weeks, she developed respiratory distress and shock and died after 1 month of admission.

pancreatitis being “caused” by the COVID-19 mRNA vaccine score was probable.^{75–77}

Musculoskeletal Complications

Besides cases of Parsonage–Turner syndrome, a case of inflammatory fasciitis has been reported in which MRI revealed edema in the subcutaneous fascia, fluid in the sternoclavicular joint, mild supraspinatus tendinitis, and enlarged cervical nodes in a 48-year-old male patient who experienced intense pain in the left shoulder 1 day after the second dose of Pfizer–BioNTech vaccine and was unable to lift his shoulder.⁷⁸ Shoulder injury related to vaccine administration (SIRVA) is a medicolegal entity first introduced in 2010 to describe shoulder pain with limited range of motion within 48 hours after various vaccine receipt in subjects with no prior symptoms.⁷⁹ In regard to COVID-19 vaccination, SIRVA is considered an under-reported entity and its radiological manifestation is even more under-recognized. Vaccine-associated myositis has been described on MRI, which revealed T2 hyperintense edema of the middle head of the deltoid muscle tracking along muscle fascicles with no tear or abscess and significant enhancement on postcontrast T1 sequence.⁸⁰

Several cases of COVID-19-vaccine-related arthritis have been reported after various COVID-19 vaccines (most commonly Sinovac vaccine) with varied joint involvement. The cases were polyarticular (50%) and half of all cases involved a single joint. The metacarpophalangeal (MCP), proximal interphalangeal (PIP), and distal interphalangeal (DIP) joints were involved in the majority of cases, followed by the knee, shoulder, ankle, and elbow joints. However, there is no description of radiographic/MRI findings in the reported cases of arthritis.⁸¹

Endocrine System Complications

Cases of subacute thyroiditis, recurrent Graves' disease, and painless thyroiditis have been reported after Pfizer, Moderna, and AstraZeneca vaccines.^{82–85} In a systematic review of the US examination of 36 cases of vaccine-induced Graves' disease, 24 showed increased vascularity on color Doppler. Of the 12 patients on whom thyroid scintigraphy was performed, the majority had an increased diffuse uptake. In subacute thyroiditis, diffusely heterogeneous thyroid was seen on US, with increased peripheral and internal vascularity on Doppler. Asymptomatic thyroiditis has also been observed after 3 weeks of receipt of AstraZeneca vaccine where US showed diffusely hypochoic thyroid gland with reduced blood flow.

A case of vaccine-associated hypopituitarism has been reported in a patient who complained of headache, nausea, vomiting, malaise, and diffuse arthralgias 3 days after receiving the second dose of Moderna vaccine. MRI of the brain showed a diffusely enlarged pituitary gland without any focal lesion, and the imaging features were consistent with acute hypophysitis. The patient was started on glucocorticoid and thyroid hormone supplementation and

showed clinical and radiological improvement. After 1 month of therapy, a follow-up MRI revealed significantly reduced pituitary size with a partially empty sella.⁸⁶

Bilateral adrenal hemorrhage appearing as hyperdense bulky adrenals with adjacent fat stranding on CT has been reported after AstraZeneca vaccine administration in the setting of VITT in a patient who had features of adrenal insufficiency. Another case of VITT showed an enlarged left rounded adrenal gland, with loss of shape and decreased CT attenuation along with thrombosis in the ipsilateral renal vein, consistent with adrenal infarction and postinfarction necrosis. This patient had no clinical or biochemical evidence of adrenal insufficiency. Another case of primary adrenal insufficiency, after AstraZeneca vaccine, has been described where abdominal MRI showed bilateral adrenal nodular enlargement with T1 hyperintense peripheral halo and hypointense center suggestive of ongoing subacute bilateral adrenal hemorrhage.^{87–89}

Imaging Pitfalls after Vaccination

Few case reports have intimated about intense FDG uptake in the axillary, supraclavicular, and cervical lymph nodes on FDG-PET/CT following mRNA COVID-19 vaccination after ipsilateral arm vaccination.^{90,91} These findings of vaccine-associated hypermetabolic lymphadenopathy (VAHL) may result in spurious interpretation in cases of related malignancies such as breast cancer, melanoma, or lymphoma as accurate nodal staging is one of the key roles of PET/CT in these cases. Therefore, it is important to carefully manage the timing of FDG-PET scans either immediately after or 4 to 6 weeks after vaccination. Nodal FDG uptake tends to occur within 7 days of vaccination and generally disappears by 12 to 14 days. A study demonstrated the potential of ⁶⁸Ga fibroblast activation protein inhibitor (⁶⁸Ga-FAPI) PET/CT to avoid ¹⁸F-FDG-PET/CT postvaccination pitfalls and enable superior tumor localization. Increased FDG uptake has also been observed in the spleen after COVID-19 vaccination.⁹²

Inflammatory changes have been seen in the ipsilateral breast of a 60-year-old woman 5 days after a booster dose of Pfizer–BioNTech vaccine on mammography seen as a new asymmetry in the upper breast that was categorized as probably a benign lesion (Breast Imaging Reporting and Data System [BI-RADS] category 3). The patient's follow-up mammography 2 months later showed resolution of the asymmetry.⁹³

Conclusion

Nearly 2 years since the onset of the expeditious and largest vaccination drive in the history of mankind, our review reiterates the efficacy of these invaluable products of modern biomedical research and provides compelling evidence in terms of morphometric involvement of the pulmonary parenchyma by COVID-19 with CT/radiographic severity scores as imaging surrogate of biological activity. While the pandemic seems to have been curbed down presently, there are still lingering concerns regarding safety and

vaccine-induced adverse effects. Familiarity with various imaging manifestations presented in this review will help physicians and radiologists to promptly identify the various cardiovascular, neurological, musculoskeletal, and endocrine complications of COVID-19 vaccines. Finally, vaccine-induced local and systemic inflammatory changes might evoke confusing imaging patterns, mimicking oncological pathology, and hence these studies should be timed according to the receipt of the last vaccine dose.

Funding

None.

Conflict of Interest

None declared.

References

- MacDonald NESAGE Working Group on Vaccine Hesitancy. Vaccine hesitancy: definition, scope and determinants. *Vaccine* 2015; 33(34):4161–4164
- Thanh Le T, Andreadakis Z, Kumar A, et al. The COVID-19 vaccine development landscape. *Nat Rev Drug Discov* 2020;19(05): 305–306
- Wibawa T. COVID-19 vaccine research and development: ethical issues. *Trop Med Int Health* 2021;26(01):14–19
- Kumar I, Verma A, Dangwal J, Singh PK, Chandra Shukla R, Chakravarty J. Magnetic resonance imaging spectrum of COVID-associated rhino-orbital-cerebral mucormycosis and assessment of anatomical severity. *Neuroradiol J* 2023;36(04):404–413
- Borghesi A, Maroldi R. COVID-19 outbreak in Italy: experimental chest X-ray scoring system for quantifying and monitoring disease progression. *Radiol Med (Torino)* 2020;125(05):509–513
- Li K, Fang Y, Li W, et al. CT image visual quantitative evaluation and clinical classification of coronavirus disease (COVID-19). *Eur Radiol* 2020;30(08):4407–4416
- Yang R, Li X, Liu H, et al. Chest CT severity score: an imaging tool for assessing severe COVID-19. *Radiol Cardiothorac Imaging* 2020;2(02):e200047
- Verma A, Kumar I, Singh PK, et al. Initial comparative analysis of pulmonary involvement on HRCT between vaccinated and non-vaccinated subjects of COVID-19. *Eur Radiol* 2022;32(06):4275–4283
- Lee JE, Hwang M, Kim YH, et al. Imaging and clinical features of COVID-19 breakthrough infections: a multicenter study. *Radiology* 2022;303(03):682–692
- Vicini S, Bellini D, Iannarelli A, et al. Pneumonia frequency and severity in patients with symptomatic COVID-19: impact of mRNA and adenovirus vector vaccines. *AJR Am J Roentgenol* 2022;219(05):752–761
- Hanafi M, Maryetty IP, Widiastuti . Chest imaging of COVID-19 patients amongst diverse vaccination status: a comparative study using Brixia score. *GSC Advanced Research and Reviews* 2022;11(02):045–049
- Borghesi A, Zigliani A, Masciullo R, et al. Radiographic severity index in COVID-19 pneumonia: relationship to age and sex in 783 Italian patients. *Radiol Med (Torino)* 2020;125(05):461–464
- Rahman MT, Islam MI, Nahar NU, Ibrahim M, Zubery H, Shirin M. HRCT evaluation of post vaccinated RT-PCR positive COVID-19 patients at a dedicated COVID-19 hospital. *European Journal of Clinical Medicine* 2022;3(03):14–17
- Lakhia RT, Trivedi JR. The CT scan lung severity score and vaccination status in COVID-19 patients during the second wave in India: perspective of an independent radiology practice. *medRxiv* 2021.07.15.21260597
- Granata V, Fusco R, Villanacci A, et al. Imaging Severity COVID-19 assessment in vaccinated and unvaccinated patients: comparison of the different variants in a high volume Italian Reference Center. *J Pers Med* 2022;12(06):955
- Gurumurthy B, Das SK, Shetty S, Veerabhadrapa RC, Kosinepalli SS, Dharamaraju SH. CT severity score: an imaging biomarker to estimate the severity of COVID-19 pneumonia in vaccinated and non-vaccinated population. *Egypt J Radiol Nucl Med* 2022;53(01):88
- Dubey R, Sen KK, Mitra A, Sethi HS, Arora R, Goyal M. Correlation of radiological findings on high-resolution computed tomography chest in vaccinated and unvaccinated COVID-19 patients from Eastern India. *Indian J Respir Care* 2022;11:124–127
- Su JR, McNeil MM, Welsh KJ, et al. Myopericarditis after vaccination, Vaccine Adverse Event Reporting System (VAERS), 1990–2018. *Vaccine* 2021;39(05):839–845
- Bozkurt B, Kamat I, Hotez PJ. Myocarditis with COVID-19 mRNA vaccines. *Circulation* 2021;144(06):471–484
- Gargano JW, Wallace M, Hadler SC, et al. Use of mRNA COVID-19 vaccine after reports of myocarditis among vaccine recipients: update from the Advisory Committee on Immunization Practices: United States, June 2021. *MMWR Morb Mortal Wkly Rep* 2021;70(27):977–982
- Friedrich MG, Sechtem U, Schulz-Menger J, et al; International Consensus Group on Cardiovascular Magnetic Resonance in Myocarditis. Cardiovascular magnetic resonance in myocarditis: a JACC white paper. *J Am Coll Cardiol* 2009;53(17):1475–1487
- Fronza M, Thavendiranathan P, Chan V, et al. Myocardial injury pattern at MRI in COVID-19 vaccine-associated myocarditis. *Radiology* 2022;304(03):553–562
- Singh R, Chakrabarti SS, Gambhir IS, et al. Acute cardiac events after ChAdOx1 nCoV-19 corona virus vaccine: report of three cases. *Am J Ther* 2022;29(05):e579–e585
- Patel YR, Shah NR, Lombardi K, et al. Cardiac MRI findings in male patients with acute myocarditis in the presence or absence of COVID-19 vaccination. *Radiol Cardiothorac Imaging* 2022;4(03): e220008
- Sanchez Tijmes F, Zamorano A, Thavendiranathan P, Hanneman K. Imaging of myocarditis following mRNA COVID-19 booster vaccination. *Radiol Cardiothorac Imaging* 2022;4(02):e220019
- Dionne A, Sperotto F, Chamberlain S, et al. Association of myocarditis with BNT162b2 messenger RNA COVID-19 vaccine in a case series of children. *JAMA Cardiol* 2021;6(12):1446–1450
- Sung JG, Sobieszczyk PS, Bhatt DL. Acute myocardial infarction within 24. hours after COVID-19 vaccination. *Am J Cardiol* 2021; 156:129–131
- Tajstra M, Jaroszewicz J, Gąsior M. Acute coronary tree thrombosis after vaccination for COVID-19. *JACC Cardiovasc Interv* 2021; 14(09):e103–e104
- Özdemir İH, Özlek B, Özen MB, Gündüz R, Bayturan Ö Type 1 Kounis syndrome induced by inactivated SARS-COV-2 Vaccine. *J Emerg Med* 2021;61(04):e71–e76
- Showkathali R, Yalamanchi R, Narra L, et al. Coronary thromboembolic events after Covid-19 vaccination: a single centre study. *Indian Heart J* 2022;74(02):131–134
- Ifeanyi N, Chinenye N, Oladiran O, David E, Mmonu C, Ogbonna-Nwosu C. Isolated pulmonary embolism following COVID vaccination: 2 case reports and a review of post-acute pulmonary embolism complications and follow-up. *J Community Hosp Intern Med Perspect* 2021;11(06):877–879
- Al-Maqbali JS, Al Rasbi S, Kashoub MS, et al. A 59-year-old woman with extensive deep vein thrombosis and pulmonary thromboembolism 7 days following a first dose of the Pfizer-BioNTech BNT162b2 mRNA COVID-19 vaccine. *Am J Case Rep* 2021;22:e932946
- Wiest NE, Johns GS, Edwards E. A case of acute pulmonary embolus after mRNA SARS-CoV-2 immunization. *Vaccines (Basel)* 2021;9(08):903

- 34 Borisoff BD, Bohn KD, Sager J, Gracious BL. Unprovoked submassive saddle pulmonary embolism in an adult male after Pfizer COVID-19 vaccination. *Cureus* 2022;14(08):e27717
- 35 Ogunkoya JO, Ogunmola MI, Ogunlade AF, Ladele AE. COVID-19 vaccination associated bilateral pulmonary embolism: cause or coincidence. *Case Rep Pulmonol* 2022;2022:9596285
- 36 Warkentin TE, Cuker A. COVID-19: Vaccine-Induced Immune Thrombotic Thrombocytopenia (VITT). Waltham, MA: UpToDate; 2021
- 37 Herrera-Comoglio R, Lane S. Vaccine-induced immune thrombocytopenia and thrombosis after the Sputnik V vaccine. *N Engl J Med* 2022;387(15):1431–1432
- 38 Rogers P, Walker I, Yeung J, et al; RADIANT Group. Thrombus distribution in vaccine-induced immune thrombotic thrombocytopenia after ChAdOx1 nCoV-19 vaccination. *Radiology* 2022;305(03):590–596
- 39 Vierstraete M, Sabbe T. Aortic thrombosis and acute limb ischemia after ChAdOx1 nCoV-19 (Oxford-AstraZeneca) vaccination: a case of vaccine-induced thrombocytopenia and thrombosis (VITT). *Acta Chir Belg* 2023;123(03):329–332
- 40 Gilio M, De Stefano G. Large-vessel vasculitis following the Pfizer-BioNTech COVID-19 vaccine. *Intern Emerg Med* 2022;17(04):1239–1241
- 41 Garg RK, Paliwal VK. Spectrum of neurological complications following COVID-19 vaccination. *Neurol Sci* 2022;43(01):3–40
- 42 Sriwastava S, Shrestha AK, Khalid SH, Colantonio MA, Nwafor D, Srivastava S. Spectrum of neuroimaging findings in post-COVID-19 vaccination: a case series and review of literature. *Neurol Int* 2021;13(04):622–639
- 43 Waheed S, Bayas A, Hindi F, Rizvi Z, Espinosa PS. Neurological complications of COVID-19: Guillain-Barre syndrome following Pfizer COVID-19 vaccine. *Cureus* 2021;13(02):e13426
- 44 Patel SU, Khurram R, Lakhani A, Quirk B. Guillain-Barre syndrome following the first dose of the chimpanzee adenovirus-vectored COVID-19 vaccine, ChAdOx1. *BMJ Case Rep* 2021;14(04):e242956
- 45 Azam S, Khalil A, Taha A. Guillain-Barré syndrome in a 67-year-old male post COVID-19 vaccination (Astra Zeneca). *Am J Med Case Rep* 2021;9:424–427
- 46 Maramattom BV, Krishnan P, Paul R, et al. Guillain-Barré syndrome following ChAdOx1-S/nCoV-19 vaccine. *Ann Neurol* 2021;90(02):312–314
- 47 Rossetti A, Gheihman G, O'Hare M, Kosowsky JM. Guillain-Barré syndrome presenting as facial diplegia after COVID-19 vaccination: a case report. *J Emerg Med* 2021;61(06):e141–e145
- 48 Prasad A, Hurlburt G, Podury S, Tandon M, Kingree S, Sriwastava S. A novel case of bifacial diplegia variant of Guillain-Barré syndrome following Janssen COVID-19 vaccination. *Neurol Int* 2021;13(03):404–409
- 49 Bonifacio GB, Patel D, Cook S, et al. Bilateral facial weakness with paraesthesia variant of Guillain-Barré syndrome following Vaxzevria COVID-19 vaccine. *J Neurol Neurosurg Psychiatry* 2022;93(03):341–342
- 50 Keir G, Maria NI, Kirsch CFE. Unique imaging findings of neurologic phantosmia following Pfizer-BioNTech COVID-19 vaccination: a case report. *Top Magn Reson Imaging* 2021;30(03):133–137
- 51 Queler SC, Towbin AJ, Milani C, Whang J, Sneag DB. Parsonage-Turner syndrome following COVID-19 vaccination: MR neurography. *Radiol* 2022;302(01):84–87
- 52 Mahajan S, Zhang F, Mahajan A, Zimnowodzki S. Parsonage Turner syndrome after COVID-19 vaccination. *Muscle Nerve* 2021;64(01):E3–E4
- 53 Chua MMJ, Hayes MT, Cosgrove R. Parsonage-Turner syndrome following COVID-19 vaccination and review of the literature. *Surg Neurol Int* 2022;13:152
- 54 Sharma R, Dua B, Goyal S, Tiwari T. Parsonage-Turner syndrome following COVID-19 vaccine. *Ann Indian Acad Neurol* 2022;25(05):973–975
- 55 Ghanta RB, Karistinos A, Atassi OH. Parsonage-Turner Syndrome After COVID-19 vaccination: a case report. *JBJS Case Connect* 2022;12(02):
- 56 Castelli GP, Pognani C, Sozzi C, Franchini M, Vivona L. Cerebral venous sinus thrombosis associated with thrombocytopenia post-vaccination for COVID-19. *Crit Care* 2021;25(01):137
- 57 Mehta PR, Apap Mangion S, Bengler M, et al. Cerebral venous sinus thrombosis and thrombocytopenia after COVID-19 vaccination: a report of two UK cases. *Brain Behav Immun* 2021;95:514–517
- 58 Bayas A, Menacher M, Christ M, Behrens L, Rank A, Naumann M. Bilateral superior ophthalmic vein thrombosis, ischaemic stroke, and immune thrombocytopenia after ChAdOx1 nCoV-19 vaccination. *Lancet* 2021;397(10285):e11
- 59 Kakovan M, Ghorbani Shirkouhi S, Zarei M, Andalib S. Stroke associated with COVID-19 vaccines. *J Stroke Cerebrovasc Dis* 2022;31(06):106440
- 60 Kolahchi Z, Khanmirzaei M, Mowla A. Acute ischemic stroke and vaccine-induced immune thrombotic thrombocytopenia post COVID-19 vaccination; a systematic review. *J Neurol Sci* 2022;439:120327
- 61 Vogrig A, Janes F, Gigli GL, et al. Acute disseminated encephalomyelitis after SARS-CoV-2 vaccination. *Clin Neurol Neurosurg* 2021;208:106839
- 62 Cao L, Ren L. Acute disseminated encephalomyelitis after severe acute respiratory syndrome coronavirus 2 vaccination: a case report. *Acta Neurol Belg* 2022;122(03):793–795
- 63 Ozgen Kenangil G, Ari BC, Guler C, Demir MK. Acute disseminated encephalomyelitis-like presentation after an inactivated coronavirus vaccine. *Acta Neurol Belg* 2021;121(04):1089–1091
- 64 Tahir N, Koorapati G, Prasad S, et al. SARS-CoV-2 vaccination-induced transverse myelitis. *Cureus* 2021;13(07):e16624
- 65 Pagenkopf C, Südmeyer M. A case of longitudinally extensive transverse myelitis following vaccination against Covid-19. *J Neuroimmunol* 2021;358:577606
- 66 Havla J, Schultz Y, Zimmermann H, Hohlfeld R, Danek A, Kümpfel T. First manifestation of multiple sclerosis after immunization with the Pfizer-BioNTech COVID-19 vaccine. *J Neurol* 2022;269(01):55–58
- 67 Chakrabarti SS, Tiwari A, Jaiswal S, et al. rapidly progressive dementia with asymmetric rigidity following ChAdOx1 nCoV-19 vaccination. *Aging Dis* 2022;13(03):633–636
- 68 Walter A, Kraemer M. A neurologist's rhombencephalitis after comirnaty vaccination. A change of perspective. *Neurol Res Pract* 2021;3(01):56
- 69 DeDent AM, Farrand E. Vaccine-induced interstitial lung disease: a rare reaction to COVID-19 vaccination. *Thorax* 2022;77(01):9–10
- 70 So C, Izumi S, Ishida A, et al. COVID-19 mRNA vaccine-related interstitial lung disease: two case reports and literature review. *Respirol Case Rep* 2022;10(04):e0938
- 71 Bando T, Takei R, Mutoh Y, et al. Acute exacerbation of idiopathic pulmonary fibrosis after SARS-CoV-2 vaccination. *Eur Respir J* 2022;59(03):2102806
- 72 Graça LL, Amaral MJ, Serôdio M, Costa B. Extensive thrombosis after COVID-19 vaccine: cause or coincidence? *BMJ Case Rep* 2021;14(08):e244878
- 73 Leclerc S, Royal V, Lamarche C, Laurin L-P. Minimal change disease with severe acute kidney injury following the Oxford-AstraZeneca COVID-19 vaccine: a case report. *Am J Kidney Dis* 2021;78(04):607–610
- 74 Lodato F, Larocca A, D'Errico A, Cennamo V. An unusual case of acute cholestatic hepatitis after m-RNABNT162b2 (Comirnaty) SARS-CoV-2 vaccine: coincidence, autoimmunity or drug-related liver injury. *J Hepatol* 2021;75(05):1254–1256
- 75 Walter T, Connor S, Stedman C, Doogue M. A case of acute necrotising pancreatitis following the second dose of Pfizer-BioNTech COVID-19 mRNA vaccine. *Br J Clin Pharmacol* 2022;88(03):1385–1386

- 76 Parkash O, Sharko A, Farooqi A, Ying GW, Sura P. Acute pancreatitis: a possible side effect of COVID-19 vaccine. *Cureus* 2021;13(04):e14741
- 77 Naranjo CA, Busto U, Sellers EM, et al. A method for estimating the probability of adverse drug reactions. *Clin Pharmacol Ther* 1981;30(02):239–245
- 78 Sharma A, Parekh SG. Musculoskeletal sequelae following COVID-19 mRNA vaccination. *J Orthop Res* 2022;1(03):100044
- 79 Wiesel BB, Keeling LE. Shoulder injury related to vaccine administration. *J Am Acad Orthop Surg* 2021;29(17):732–739
- 80 Theodorou DJ, Theodorou SJ, Axiotis A, Gianniki M, Tsifetaki N. COVID-19 vaccine-related myositis. *QJM* 2021;114(06):424–425
- 81 Dawoud R, Haddad D, Shah V, et al. COVID-19 vaccine-related arthritis: a descriptive study of case reports on a rare complication. *Cureus* 2022;14(07):e26702
- 82 Zhao Y, Wu X. Influence of COVID-19 vaccines on endocrine system. *Endocrine* 2022;78(02):241–246
- 83 Bennet WM, Elamin A, Newell-Price JD. Subacute thyroiditis following COVID-19 vaccination: case report and Society for Endocrinology survey. *Clin Endocrinol (Oxf)* 2023;98(03):452–453
- 84 Triantafyllidis KK, Giannos P, Stathi D, Kechagias KS. Graves' disease following vaccination against SARS-CoV-2: a systematic review of the reported cases. *Front Endocrinol (Lausanne)* 2022;13:938001
- 85 Siolos A, Gartzonika K, Tigas S. Thyroiditis following vaccination against COVID-19: Report of two cases and review of the literature. *Metab Open* 2021;12:100136
- 86 Murvelashvili N, Tessnow A. A case of hypophysitis following immunization with the mRNA-1273 SARS-CoV-2 vaccine. *J Investig Med High Impact Case Rep* 2021;9:23247096211043386
- 87 Graf A, Armeni E, Dickinson L, et al. Adrenal haemorrhage and infarction in the setting of vaccine-induced immune thrombocytopenia and thrombosis after SARS-CoV-2 (Oxford–AstraZeneca) vaccination. *Endocrinol Diabetes Metab Case Rep* 2022
- 88 Taylor P, Allen L, Shrikrishnapalasuriyar N, Stechman M, Rees A. Vaccine-induced thrombosis and thrombocytopenia with bilateral adrenal haemorrhage. *Clin Endocrinol (Oxf)* 2022;97(01):26–27
- 89 Varona JF, García-Isidro M, Moeinvaziri M, Ramos-López M, Fernández-Domínguez M. Primary adrenal insufficiency associated with Oxford-AstraZeneca ChAdOx1 nCoV-19 vaccine-induced immune thrombotic thrombocytopenia (VITT). *Eur J Intern Med* 2021;91:90–92
- 90 Cohen D, Krauthammer SH, Wolf I, Even-Sapir E. Hypermetabolic lymphadenopathy following administration of BNT162b2 mRNA Covid-19 vaccine: incidence assessed by [¹⁸F]FDG PET-CT and relevance to study interpretation. *Eur J Nucl Med Mol Imaging* 2021;48(06):1854–1863
- 91 Minamimoto R, Kiyomatsu T. Effects of COVID-19 vaccination on FDG-PET/CT imaging: a literature review. *Glob Health Med* 2021;3(03):129–133
- 92 Demmert TT, Maric I, Pomykala KL, et al. Novel ⁶⁸Ga-FAPI PET/CT offers oncologic staging without COVID-19 vaccine-related pitfalls. *J Nucl Med* 2023;64(03):368–371
- 93 Kim E, Reig B. Breast inflammatory change is transient following COVID-19 vaccination. *Radiology* 2022;304(03):533