

LETTER TO THE EDITOR

Cortical Subarachnoid Hemorrhage Presenting with Hemibody Dystonic Myoclonus: An Illustrative Case

Hyunjin Ju, Eun Ji Lee, Mina Lee, Kayeong Im, Kyum-Yil Kwon

Department of Neurology, Soonchunhyang University Seoul Hospital, Soonchunhyang University College of Medicine, Seoul, Korea

Dear Editor,

Nontraumatic cortical subarachnoid hemorrhage (SAH) presents with various neurological symptoms, including headache, hemiparesis, dysarthria and seizures, with different etiologies.¹⁻³ An accurate understanding of presenting symptoms in patients with cortical SAH is very important not only for diagnosis but also for treatment. Herein, we present an interesting case of a woman in her late 30s presenting with sudden-onset dystonic myoclonus of the left hemibody who was finally diagnosed with isolated cortical SAH.

A 38-year-old woman came to the emergency room of our hospital for the evaluation of progressive involuntary movements starting one day before. The patient suddenly developed jerky movements in her left arm and leg without an alteration in consciousness. The left hemibody jerks were initially intermittent but became continuous after sleeping. The patient had neither headache nor a recent history of head trauma. She had no previous medical history and was taking no medications. On bedside examination, repetitive left hemimyoclonus or tremor-like movements accompanied by left hand dystonia were noted (Supplementary Video 1 in the online-only Data Supplement), whereas her face and right limbs were unaffected. Her sensory system was unremarkable. She revealed no symptoms or signs of cognitive impairment.

Brain CT demonstrated a thin hyperdense line along the right central sulcus (Figure 1A), suggesting cortical hemorrhage. Routine laboratory tests were unremarkable. Her involuntary move-

ments showed considerable improvement after the oral administration of levetiracetam (1,000 mg daily), clonazepam (1 mg daily), and baclofen (20 mg daily). However, an occasional mild degree of hemimyoclonus and subjective symptoms of left-sided paresthesia remained. Two days later, brain MRI showed an abnormal lesion in the right central sulcal space, hyperintensity in the fluid-attenuated inversion recovery images (Figure 1B), and hypointensity in susceptibility-weighted imaging (Figure 1C), indicating isolated cortical SAH.¹⁻³ However, MRI revealed no other abnormal findings, including tumor, encephalitis, and cortical venous thrombosis. In addition, an MR angiographic study revealed no abnormal findings, including cerebral vasospasm, vascular malformation, or aneurysm (data not shown). We increased the oral dosage of levetiracetam (1,500 mg daily), resulting in the complete remission of involuntary movements and paresthesia. In addition, electroencephalographic findings were unremarkable in the absence of involuntary movements two days after admission. The patient was treated with conservative management for cortical SAH and discharged without any neurological symptoms a week later. The patient discontinued her medications with no recurrence of involuntary movements six weeks later.

Based on the phenomenology of involuntary movements and neuroimaging findings of cortical SAH, we suspected that the patient might have hemimyoclonus combined with focal dystonia. To the best of our knowledge, there have been no reports of cortical SAH-induced focal dystonia or hemibody myoclonus.

Received: October 24, 2020 Revised: November 22, 2020 Accepted: November 27, 2020

Corresponding author: Kyum-Yil Kwon, MD, PhD

Department of Neurology, Soonchunhyang University Seoul Hospital, Soonchunhyang University College of Medicine, 59 Daesagwan-ro, Yongsan-gu, Seoul 04401, Korea / Tel: +82-2-709-9026 / Fax: +82-2-709-9226 / E-mail: denovo78@naver.com

© This is an Open Access article distributed under the terms of the Creative Commons Attribution Non-Commercial License (<https://creativecommons.org/licenses/by-nc/4.0>) which permits unrestricted non-commercial use, distribution, and reproduction in any medium, provided the original work is properly cited.

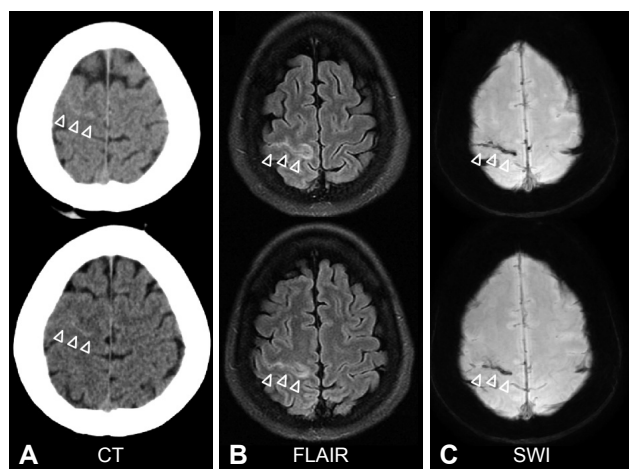


Figure 1. CT and MRI of the patient. A: Brain CT revealed a thin hyperdense line along the right central sulcus. B: Fluid-attenuated inversion recovery (FLAIR) images show hyperintensity along the right central sulcal space. C: Susceptibility-weighted imaging (SWI) revealed hypointensity in the right central sulcus.

The exact pathomechanisms through which cortical SAH caused left hemidystonic myoclonus in our patient remain unclear. We deduced that cortical SAH-induced neuronal hyperexcitability in the motor cortex might cause abnormalities in gamma-aminobutyric acid-mediated inhibitory neurotransmission,⁴ resulting in the dystonic myoclonus of the contralateral hemibody in our patient. It is reasonable to infer that the patient's involuntary movements of the left arm and leg might have resulted from damage to the right motor cortex that affected the basal ganglia-cortical pathway. This case suggests that stroke-related involuntary movements might be induced not only by basal ganglia involvement but also by cortical lesions.

In addition, epilepsy partialis continua (EPC) is linked to lesions in the cerebral cortex, and the differential diagnoses of EPC include ischemic stroke and inflammatory, neoplastic or metabolic-toxic causes.⁵ EPC in association with cortical SAH has also been reported to be extremely rare, and the patient's phenomenology suggested involuntary movements rather than symptomatic seizures. However, we could not fully exclude the possibility of EPC elicited by cortical SAH, although electroencephalogram findings did not support EPC.

In conclusion, we report that cortical SAH may induce not only myoclonus but also dystonia on the contralateral side. Clinicians should consider cortical SAH for patients presenting with focal or unilateral dystonia or myoclonus.

Ethics Statement

All procedures in studies involving human participants were performed in accordance with the ethical standards of the institutional and/or national research committee and with the 1975 Declaration of Helsinki and its later amendments or comparable ethical standards. Informed consent was obtained from the patient.

Supplementary Video Legends

Video 1. A 38-year-old woman continuously exhibited left hemimyoclonic jerks accompanied by left hand dystonic posture, whereas no involuntary movements were seen in her face or right arm and leg.

Supplementary Materials

The online-only Data Supplement is available with this article at <https://doi.org/10.14802/jmd.20127>.

Conflicts of Interest

The authors have no financial conflicts of interest.

Acknowledgments

This work was supported by the Soonchunhyang University Research Fund (No. 20190533).

Author Contributions

Conceptualization: Kyum-Yil Kwon. Data curation: Hyunjin Ju, Eun Ji Lee, Mina Lee, Kayeong Im. Formal analysis: all authors. Funding acquisition: Kyum-Yil Kwon. Investigation: all authors. Methodology: Hyunjin Ju, Eun Ji Lee, Mina Lee, Kayeong Im. Project administration: Kyum-Yil Kwon. Resources: Kyum-Yil Kwon. Supervision: Kyum-Yil Kwon. Validation: Kyum-Yil Kwon. Visualization: all authors. Writing—original draft: Hyunjin Ju, Kyum-Yil Kwon. Writing—review & editing: all authors.

ORCID iDs

| | |
|---------------|---|
| Hyunjin Ju | https://orcid.org/0000-0003-2930-8693 |
| Eun Ji Lee | https://orcid.org/0000-0001-6690-5783 |
| Mina Lee | https://orcid.org/0000-0002-5971-3633 |
| Kayeong Im | https://orcid.org/0000-0002-4786-096X |
| Kyum-Yil Kwon | https://orcid.org/0000-0001-5443-0952 |

REFERENCES

1. Refai D, Botros JA, Strom RG, Derdeyn CP, Sharma A, Zipfel GJ. Spontaneous isolated convexity subarachnoid hemorrhage: presentation, radiological findings, differential diagnosis, and clinical course. *J Neurosurg* 2008;109:1034-1041.
2. Cuvincius V, Viguier A, Calviere L, Raposo N, Larrue V, Cognard C, et al. Isolated acute nontraumatic cortical subarachnoid hemorrhage. *AJNR Am J Neuroradiol* 2010;31:1355-1362.
3. Geraldes R, Sousa PR, Fonseca AC, Falcão F, Canhã P, Pinho e Melo T. Nontraumatic convexity subarachnoid hemorrhage: different etiologies and outcomes. *J Stroke Cerebrovasc Dis* 2014;23:e23-e30.
4. Krauss GL, Mathews GC. Similarities in mechanisms and treatments for epileptic and nonepileptic myoclonus. *Epilepsy Curr* 2003;3:19-21.
5. Mameniskienė R, Wolf P. Epilepsia partialis continua: a review. *Seizure* 2017;44:74-80.