



Since January 2020 Elsevier has created a COVID-19 resource centre with free information in English and Mandarin on the novel coronavirus COVID-19. The COVID-19 resource centre is hosted on Elsevier Connect, the company's public news and information website.

Elsevier hereby grants permission to make all its COVID-19-related research that is available on the COVID-19 resource centre - including this research content - immediately available in PubMed Central and other publicly funded repositories, such as the WHO COVID database with rights for unrestricted research re-use and analyses in any form or by any means with acknowledgement of the original source. These permissions are granted for free by Elsevier for as long as the COVID-19 resource centre remains active.

# Cerebrovascular Involvement in Mucormycosis in COVID-19 Pandemic

Rahul Kulkarni, MD, DM, FAAN,<sup>a</sup> Shripad S Pujari, MD, DM, MRCP,<sup>b</sup>  
Dulari Gupta, MD, DM,<sup>a</sup> Pawan Ojha, MD, DM,<sup>c</sup> Megha Dhamne, MD,<sup>d</sup>  
Vyankatesh Bolegave, MD, DM,<sup>e</sup> Pramod Dhonde, MD, DM,<sup>f</sup> Anand Soni, MD, DM,<sup>g</sup>  
Sikandar Adwani, MD, DM,<sup>h</sup> Anand Diwan, MD, DNB,<sup>i</sup>  
Dhananjay Duberkar, MD, DM,<sup>j</sup> Dhruv Batra, MD, DM,<sup>k</sup>  
Rushikesh Deshpande, MD, DM,<sup>l</sup> Kaustubh Aurangabadkar, MD, DM,<sup>m</sup> and  
Nilesh Palasdeokar, MD, DM<sup>n</sup>

---

*Background:* Many countries have seen an unprecedented rise of cases of coronavirus disease 2019 (COVID-19) associated mucormycosis (CAM). Cerebrovascular involvement in CAM has not been studied so far. We describe clinico-radiological manifestations of cerebrovascular complications observed in CAM. *Methods:* In this multicentric retrospective observational study from India, patients with CAM who developed cerebrovascular involvement were studied. Their demographics, risk factors, clinical manifestations, imaging, laboratory profile and outcomes were noted. *Results:* Out of 49 subjects with cerebrovascular involvement, 71.4% were males while average age was 52.9 years. Ischemic stroke was commonest (91.8%) followed by intracranial haemorrhage (6.1%) and subarachnoid haemorrhage (2%). The incidence of cerebrovascular complications in CAM was found to be 11.8% in one center. Cerebrovascular symptoms appeared a median of 8.3 days from the onset of mucormycosis. Commonest presentation of mucormycosis was rhino-orbito-cerebral syndrome in 98%. Diabetes mellitus was present in 81.7%. Forty percent developed stroke despite being on antiplatelet agent and/or heparin. Amongst subjects with ischemic strokes, location of stroke was unilateral anterior circulation (62.2%); bilateral anterior circulation (17.8%); posterior circulation (11.1%) and combined anterior and posterior circulation (8.9%). Vascular imaging revealed intracranial occlusion in 62.1%; extracranial occlusion in 3.4% and normal vessels in 34.5%. Mortality was 51% during hospital stay. *Conclusions:* Cerebrovascular involvement was seen in 11.8% patients of CAM. Angio-invasive nature of the fungus,

---

From the <sup>a</sup>Department of Neurology, Deenanath Mangeshkar Hospital and Research Center, Pune, India; <sup>b</sup>Department of Neurology, Deenanath Mangeshkar Hospital and Research Center, Noble Hospital, Pune, India; <sup>c</sup>Department of Neurology, Grant Medical College and Sir JJ Hospital, Mumbai, India; <sup>d</sup>Department of Neurology, Dr L H Hiranandani Hospital, Mumbai, India; <sup>e</sup>Department of Neurology, RGMHC and CSM Hospital, Thane, India; <sup>f</sup>Dhonde Hospital, Nanded, India; <sup>g</sup>United Ciigma Hospital, Aurangabad, India; <sup>h</sup>Department of Neurology, Radiant Superspeciality Hospital, Amravati, India; <sup>i</sup>Department of Neurology, Narayani Hospital, Nashik, India; <sup>j</sup>Department of Neurology, Sahyadri Hospital, Nashik, India; <sup>k</sup>Department of Neurology, Viveka Hospitals Pvt Ltd, Nagpur, India; <sup>l</sup>Department of Neurology, Deenanath Mangeshkar Hospital and Research Center, Pune, India; <sup>m</sup>Diamond Superspeciality Hospital, Kolhapur, Pune; and <sup>n</sup>Department of Neurology, Noble hospital, Ruby Hall Clinic, Wanowarie, Pune, India.

Received October 16, 2021; revision received November 14, 2021; accepted November 16, 2021.

Declaration of originality, authorship and competing interest on behalf of all authors of the manuscript: This manuscript is based on original work and had not been published in whole in any print or electronic media. All persons listed as authors in the manuscript have read and approved the submitted manuscript. They have made substantial contribution, so as to take public responsibility to it, in the production of this manuscript.

Corresponding author at: Department of Neurology, Deenanath Mangeshkar Hospital and Research Center, Pune, India. E-mail: [rahulneuro@gmail.com](mailto:rahulneuro@gmail.com).

1052-3057/\$ - see front matter

© 2021 Elsevier Inc. All rights reserved.

<https://doi.org/10.1016/j.jstrokecerebrovasdis.2021.106231>

prothrombotic state created by COVID-19, and diabetes were important causative factors. Subjects with CAM should be screened for involvement of the brain as well as its vessel. Antiplatelet agents/heparin did not seem to provide complete protection from this type of stroke.

**Key Words:** COVID-19 associated mucormycosis, Mucormycosis associated stroke, Cerebrovascular involvement, COVID-19—COVID-19, Mucormycosis, Stroke

© 2021 Elsevier Inc. All rights reserved.

## Introduction

Mucormycosis is an acute to subacute infection caused by invasive fungus from the order *Mucorales*. It is ubiquitous in soil and decaying plants. The most common genera causing human infection are *Rhizopus*, *Lichtheimia*, *Apophysomyces*, *Mucor*, *Rhizomucor* and *Cunninghamella*. Mucormycosis causes rhino-orbito-cerebral syndrome, pulmonary, gastrointestinal, cutaneous and disseminated mycosis.<sup>2</sup> This fungal infection occurs almost exclusively in patients with uncontrolled diabetes mellitus, hematological malignancies, hemopoietic or solid organ transplant and iron overload state.<sup>2</sup>

In the ongoing coronavirus disease 2019 (COVID-19) pandemic due to the severe acute respiratory syndrome coronavirus 2 (SARS-CoV-2), there are multiple case reports of COVID-19 associated mucormycosis (CAM) causing pulmonary mucormycosis and rhino-orbito-cerebral mucormycosis (ROCM).<sup>3-6</sup> In a review by Singh AK et al, the majority (80%) of these reports are from India.<sup>4</sup>

Intracranial complications of mucormycosis include contiguous spread, cavernous sinus thrombosis, fungal abscess, meningitis and cerebrovascular disease.<sup>1</sup> Due to angioinvasion, the fungus involves intracranial vessels leading to ischemic stroke, aneurysm, carotico-cavernous fistula, sub-arachnoid haemorrhage (SAH) and intracerebral haemorrhage (ICH). Cerebrovascular events with mucormycosis are a rarity and the exact incidence is not known. In a systematic review, 78 cases of cerebrovascular involvement with invasive mycosis presenting over 60-years were included, of which 37 were due to mucormycosis.<sup>7</sup> India is the country with the second largest numbers of COVID-19 infections.<sup>8</sup> The western Indian state of Maharashtra has recorded the maximum number of COVID-19 infections in the country so far.<sup>9</sup> The state had reported 2770 cases of CAM till 5 Jun 2021 which was second-highest in the country.<sup>6</sup> In a previous retrospective study of 122 patients of COVID-19 associated mycosis, ischemic strokes were reported in 18 (14.8%) subjects.<sup>3</sup> In this study, we describe clinico-radiological manifestations of cerebrovascular complications observed in CAM.

## Methodology

This was a retrospective, observational, multi-centre study where consecutive cases of laboratory-confirmed CAM infection with cerebrovascular involvement from 13

urban tertiary care centres in state of Maharashtra, India, were included. The study was conducted in the time period from 1 Dec 2020 to 30 Jun 2021. The study was approved by the institutional ethics committee and waiver of consent for patients was granted.

COVID-19 was diagnosed if subjects had positive reverse transcription polymerase chain reaction (RT-PCR) for SARS-CoV-2 viral ribonucleic acid (RNA) or positive rapid antigen test on nasopharyngeal and/or oropharyngeal swab. The diagnosis of mucormycosis was achieved by potassium hydroxide (KOH) or calcofluor stain of tissue obtained from scrapping of nose, palate or paranasal sinus, histopathology of biopsied tissue, and/or fungal growth in cultures. ROCM was defined as laboratory-proven fungal infection of nose, paranasal sinuses, orbit and/or intracranial structures due to mucormycosis. Meningitis was defined as cerebrospinal fluid (CSF) pleocytosis with raised proteins and/or meningeal enhancement on contrast computerised tomography (CT)/magnetic resonance imaging (MRI). Fungal infection occurring within 60 days of onset of COVID-19 infection was considered as CAM.<sup>10</sup> Cerebrovascular involvement was defined as presence of ischemic stroke, intra-cerebral haemorrhage (ICH) or subarachnoid haemorrhage (SAH) on clinical examination and/or on appropriate imaging in subjects suffering from CAM.

C-reactive-protein (CRP) was considered to be elevated if it was >6 mg/L; D-dimer was considered elevated if it was >500 mcg/L; Ferritin was considered elevated if it was >350 mcg/L and haemoglobin A1 C (HbA1C) was considered elevated if it was >7%.

A standardized form was used to extract data from case-records of hospitalized patients with CAM. Data regarding age, gender, medical comorbidities, details about COVID-19 illness, onset of fungal infection after COVID-19, onset of cerebrovascular events after fungal infection, fungal syndromes, ongoing medications at time of cerebrovascular involvement, clinical features, National Institute of Health Stroke Score (NIHSS), type of cerebrovascular involvement, the site of involvement, relevant laboratory and radiological investigations and treatment done for the cerebrovascular event was collected. Ischemic strokes were classified according to the Oxfordshire Community Stroke Project (OCSP) classification.<sup>11</sup> The outcome of the patients was recorded at the time of discharge from hospital. The data was analysed by a central team based at the first hospital.

**Table 1.** Characteristics of patients with cerebrovascular involvement in COVID-19 associated mucormycosis (CAM)

		Number (N=49)	Percentage (%)
Age (years)	Mean 52.92 (10.96)		
Gender	Male	35	71.4
	Female	14	28.6
Onset of mucormycosis after COVID-19 (days)	Median Duration 18 (IQR 13-25)		
Onset of cerebrovascular involvement after mucormycosis (days)	Median 8.13 (IQR 3.75-10 days)		
Medical illness	Diabetes mellitus	31	63.3
	Diabetes after COVID-19	9	18.4
	Hypertension	18	36.7
	Smoking	6	12.2
	Dyslipidemia	5	10.2
Fungal syndrome	Rhino-orbito-cerebral syndrome	48	98
	Cavernous sinus involvement	17	34.7
	Meningitis	5	10.2
	Pulmonary mycosis	8	16.3
	Others (subdural empyema)	1	2
Cerebrovascular involvement	Ischemic stroke	45	91.8
	Sub-arachnoid haemorrhage	1	2
	Intracerebral haemorrhage	3	6.1

To study the incidence of cerebrovascular involvement in CAM, data from electronic medical records of the first hospital from Pune, India was analysed. The total number of COVID-19 subjects, total CAM subjects as well number of subjects who had CAM with cerebrovascular involvement during the study period were used to calculate incidence of cerebrovascular involvement in CAM.

We describe baseline characteristics as mean ( $\pm$ SD) or median (inter quartile range) as appropriate for continuous variables and proportions for categorical variables. All statistical analyses were performed using SPSS version 26 (SPSS for Windows, Chicago, SPSS Inc).

## Observations and results

A total of 49 patients were seen during the study period who had cerebrovascular involvement with CAM. Of the 49 cases, 18 cases were seen in earlier study<sup>3</sup> while we added 31 more cases. During the study period, a total of 4825 subjects with COVID-19 were admitted in one centre in Pune, Maharashtra, while 102 were admitted with CAM. Of these 102 patients, 12 subjects had cerebrovascular involvement. Thus, the incidence of cerebrovascular involvement in CAM was found to be 117.6 per 1000 subjects with CAM (11.8%).

The demographic features, details about mucormycosis, medical illnesses and cerebrovascular events are presented in [Table 1](#).

Most of the patients were above 50 years of age with male preponderance. The diagnosis of COVID-19 was confirmed by RT-PCR in 43 (87.8%) and by rapid antigen in 6 (12.2%). The symptoms of mucormycosis started

median 18 days (IQR 13-25 days) after onset of COVID-19 while the symptoms of cerebrovascular involvement occurred median 8.13 days (IQR 3.75-10 days) after onset of mucormycosis. In one patient, ischemic stroke was the presenting manifestation of CAM (case 1).

Diabetes is a well-known risk factor for mucormycosis.<sup>12</sup> In our study 31/49 (63.3%) of subjects had pre-existing diabetes while 9/49 (18.4%) subjects were detected to have new onset diabetes after COVID-19. Apart from hypertension noted in 36.7%, other medical illnesses were uncommon. No subject had past history of stroke or ischemic heart disease. ROCM was the commonest presenting syndrome of mucormycosis in 98% followed by associated cavernous sinus involvement in 34.7%. Other fungal syndromes were rare. The diagnosis of mucormycosis was made by staining in 38/49 (77.6%); histopathology in 34/49 (69.4%) and fungal culture in 10/49 (20.4%) subjects.

Ischemic stroke was the most common cerebrovascular event seen in 45/49 (91.8%) subjects; followed by intracranial haemorrhage in 3/49 (6.1%) and sub-arachnoid haemorrhage in 1/49 (2.0%). Ongoing treatment, clinical features, radiological features, treatment and outcomes of ischemic stroke in CAM are presented in [Table 2](#).

In addition to the clinical presentation of stroke described in [Table 2](#), one patient each also presented with altered behaviour, cortical blindness, dysarthria, ataxia, upper limb paraesthesia and seizure. The strokes were mild (NIHSS <8) in 23 (51.1%), moderate (NIHSS 9-15) in 11 (24.4%) and severe (NIHSS >15) in 11 (24.4%). One patient presented with NIHSS 0 and never had any symptoms suggestive of stroke (case 2).

**Table 2.** Features of patients with ischemic strokes in COVID-19 associated mucormycosis (CAM) (N=45)

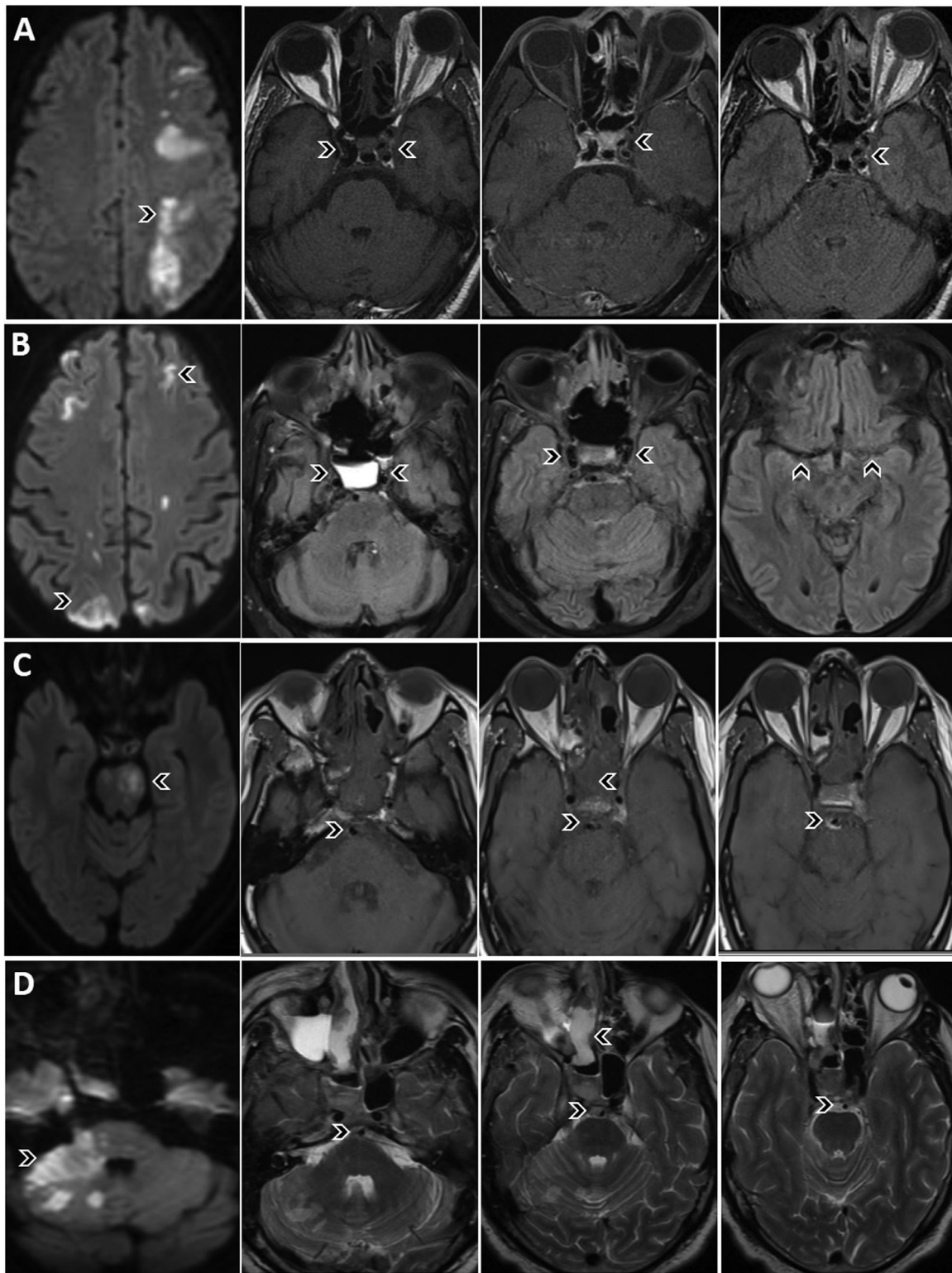
		Number (N=45)	Percentage (%)
Ongoing treatment before stroke	Aspirin	8	17.8
	Clopidogrel	4	8.9
	Aspirin + clopidogrel	3	6.7
	Statin	4	8.9
	Heparin	3	6.7
	Oral anticoagulation	0	0
Clinical features	Motor weakness	34	75.6
	Altered mentation	5	11.1
	Aphasia	9	20
	Hemianopia	2	4.4
	Asymptomatic	1	2.2
NIHSS	Mean 10.74 (SD 7.2)		
Stroke classification (N=51)	Total anterior	14	27.5
	Partial anterior	25	49
	Lacunar	0	0
	Posterior	12	23.5
Infarct location on imaging	Unilateral anterior circulation only		
	Complete MCA	11	24.4
	Partial MCA	15	33.3
	ACA	0	0
	Watershed	2	4.4
	Bilateral anterior circulation		
	Bilateral MCA	5	11.1
	Bilateral watershed	3	6.7
	Posterior circulation	5	11.1
	Anterior + posterior circulation	4	8.9
Vascular imaging (N=29)	Normal	10	34.5
	Intracranial large vessel occlusion	18	62.1
	Extracranial stenosis/occlusion	1	3.4
Investigations	Echocardiography (N=31)	Normal 27	EF <45% in 4 (12.9%)
	D-dimer (N=22)	799 (SD 595)	Elevated in 13 (41.9%)
	C-reactive-protein (N=32)	78 (SD 65)	Elevated in 30 (93.8%)
	HbA1C (N=14)	8.6 (SD 2.4)	Elevated in 10 (71.4%)
	Blood glucose level (N=26)	270 (SD 94)	Elevated in 21 (80.8%)
	Ferritin (N=12)	707 (SD 644)	Elevated in 8 (66.7%)
Treatment of stroke	Thrombolysis	1	2.2
	Endovascular thrombectomy	1	2.2
	Aspirin	25	55.6
	Aspirin + clopidogrel	17	37.8
	Low molecular weight heparin	10	22.2
	Heparin	2	4.4
Outcome	Survived	24	53.3
	Died	21	46.7

(NIHSS- National Institute of Health Stroke Scale, MCA- middle cerebral artery, ACA- anterior cerebral artery, EF-ejection fraction)

Strokes were classified according to OCSF classification. However, 12 (26.7%) patients had >1 arterial territory involvement (8 bilateral and 4 anterior + posterior circulation). All 45 patients had large artery infarcts and none had lacunar infarct. Amongst the 28 unilateral anterior circulation infarcts, 23 (82.1%) occurred on same side of sinus/orbit/cavernous sinus involvement (Fig. 1a). There were 5 watershed infarcts in the study. Two patients had unilateral watershed and 3 had bilateral watershed infarct (Fig. 1b). Of the 5 patients with bilateral middle cerebral artery (MCA)

infarcts, 4 had simultaneous MCA infarcts on presentation and one patient had developed infarct on opposite side during the course of illness. Of the 4 posterior circulation infarcts, 2 were in brainstem (Fig. 1c) and 2 involved both brainstem and cerebellum (Fig. 1d). Four patients had combined anterior and posterior circulation infarcts.

Eighteen patients had intracranial internal carotid artery (ICA) occlusion, site of occlusion being in the affected cavernous sinus. Two patients had progressive ipsilateral ICA occlusion on follow up imaging (case 3).



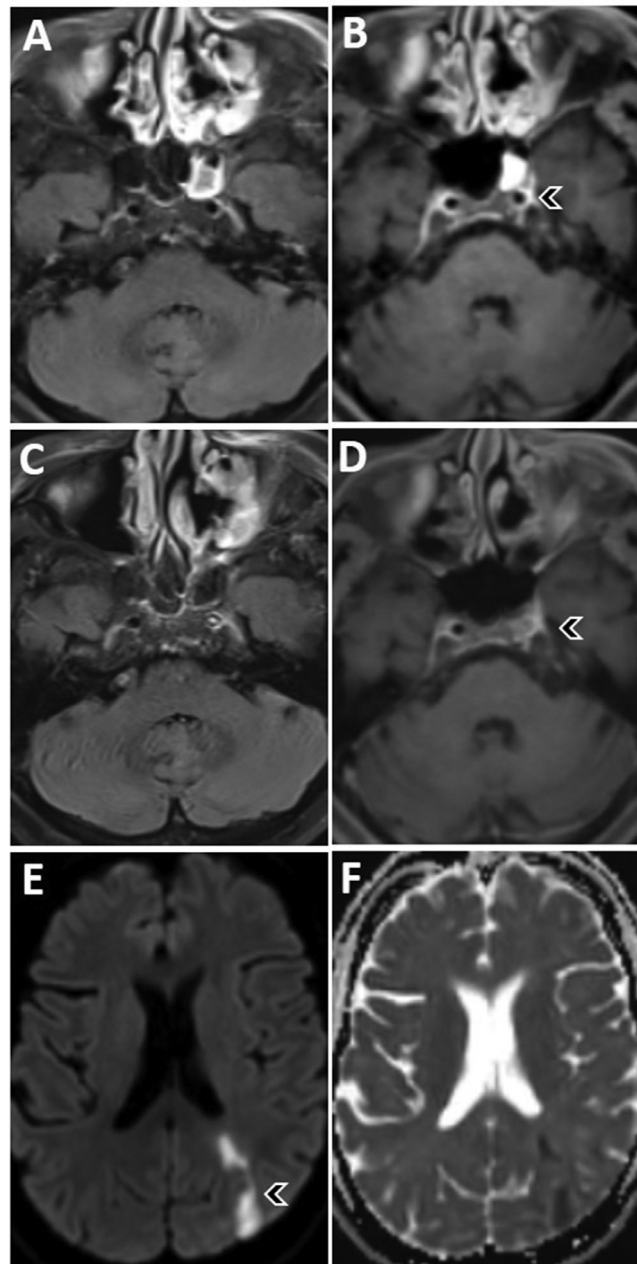
**Fig. 1.** COVID-19 associated mucormycosis-associated infarcts involving both anterior and posterior circulation territories in 4 different patients. Extreme left column shows DWI axial images of all patients and the rest of the columns show T1W axial sequences in patient A and C; T2 FLAIR axial in patient B and T2W axial in patient D.

*A:* left middle cerebral artery territory infarct with fungal soft tissue surrounding the left internal carotid artery compromising its flow.

*B:* bilateral watershed territory infarcts with soft tissue abutting both internal carotid arteries around the cavernous sinuses. Also appreciated is poor flow across the left middle cerebral artery in the sylvian fissure.

*C:* left pontine infarct and fungal soft tissue surrounding the basilar artery compromising its lumen.

*D:* right anterior cerebellar and lateral pontine infarct with basilar artery encased by the infective tissue.



**Fig. 2.** Progressive occlusion of left internal carotid artery (ICA) over one and a half months because of invasive mucormycosis. A and C are T2 FLAIR, B and D are T1W, E is DWI and F is ADC axial MRI brain images.

A and B: first MRI showing patent internal carotid arteries bilaterally and involvement of paranasal sinuses.

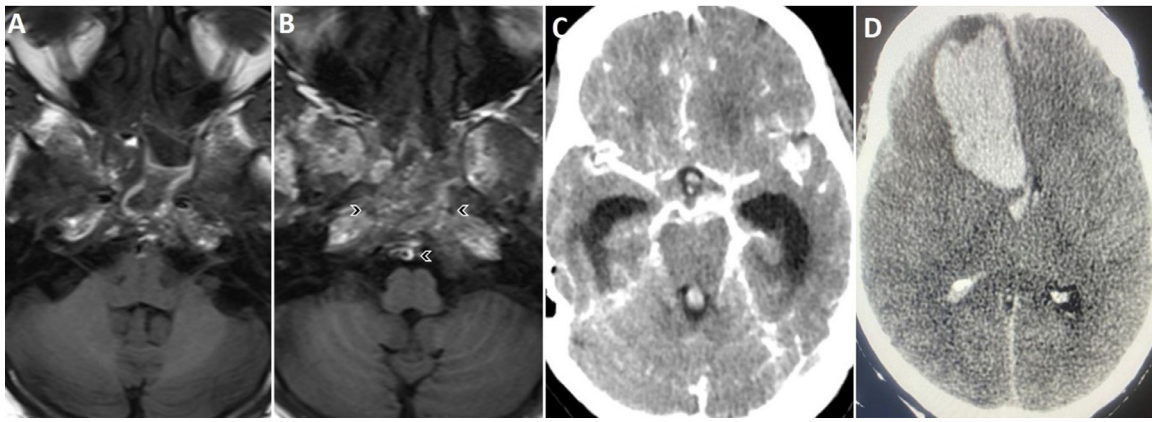
C and D: repeat MRI after one and a half months showing left ICA occluded by the invasive soft tissue.

E and F: show left middle cerebral artery territory infarct due to the diseased ICA.

Forty percent patients were already receiving anti-platelet and/or anticoagulation therapy prior to the onset of the ischemic strokes. One patient was thrombolysed and eventually underwent endovascular thrombectomy (case 4).

A 57-years-old lady with COVID-19 associated ROCM developed sudden loss of consciousness on second day of admission due to SAH secondary to rupture of vertebra-basilar junction aneurysm (Fig. 3a-c). She succumbed rather quickly, despite aggressive medical management.

Three patients developed intracerebral haemorrhage. They were 48-, 62- and 70-years old men who developed hemiparesis and reduced level of consciousness with Glasgow coma scale (GCS) of 13, 4 and 9 respectively. They developed ICH 3, 7 and 10 days after the onset of mucormycosis. Two patients had right fronto-temporal ICH and the third patient had left temporal ICH (Fig. 3d). Two patients underwent emergency decompression craniectomy with evacuation of the clot; however, all 3 succumbed despite all aggressive treatment.



**Fig. 3.** Intracranial haemorrhages due to invasive mucormycosis. A and B are T1W axial MRI images and C and D are CT brain plain images. A, B and C: scans of a patient showing clival invasive soft tissue infiltrating both the internal carotid arteries and the basilar artery resulting in a subarachnoid haemorrhage appreciated on the CT brain. D: right frontal parenchymal haemorrhage in another patient with invasive mucormycosis.

Of the total 49 patients, 25 (51%) died during the course of hospitalization while 24 (49%) survived with disabilities.

### Illustrative cases

**Case 1:** A 65-year-old diabetic man who presented with right hemiparesis and aphasia 5 days after COVID-19. MRI brain showed a left MCA infarct with left intracranial ICA occlusion with extensive sinusitis. Further investigations revealed positive fungal stains from tissue obtained from nasal cavity. He subsequently underwent functional endoscopic sinus surgery (FESS) and orbital exenteration. However, the disease progressed and he expired after 2 weeks.

**Case 2:** A 38-year-old man who presented with left facial pain, headache, left ophthalmoplegia after COVID-19. His MRI showed patchy acute infarct in left frontal and parietal regions with sinusitis and orbital involvement. He was treated with intravenous and intraconal Amphotericin B, underwent FESS and improved subsequently.

**Case 3:** A 55-year-old lady of ROCM with left total ophthalmoplegia and vision loss had acute infarct in the ipsilateral occipital and frontal lobe on MRI. Magnetic resonance angiography (MRA) of brain showed mild narrowing of supra-clinoid portion of ICA. She was treated with Amphotericin B and aspirin. After 2 months, the follow-up MRI showed a new infarct in ipsilateral centrum semiovale and repeat MRA showed complete thrombosis of left intracranial ICA even though she showed clinical improvement (Fig. 2).

**Case 4:** She was a 38-year-old lady who developed right complete external ophthalmoplegia 12-days after COVID-19. Mucormycosis was confirmed by microscopic examination of nasal scrapping and Amphotericin B was initiated. Next day she had a secondarily generalized seizure followed by left hemiplegia. MRI brain revealed a right MCA/anterior cerebral artery

(ACA) watershed infarct, with right internal carotid artery occlusion from its origin on MRA. She was treated with intravenous recombinant tissue plasminogen activator (rtPA). However, her sensorium worsened. CT scan of brain revealed no intracerebral haemorrhage. She was intubated and underwent endovascular thrombectomy, with successful recanalization of the ICA. A repeat CT scan 6 hours later revealed minimal haemorrhage in bilateral frontal regions. She worsened further the next day with absent brain stem reflexes suggestive of brain death. Repeat CT scan of brain showed worsening of haemorrhage and digital subtraction angiography (DSA) showed no intracranial blood flow after which she was declared brain dead.

### Discussion

Mucormycosis is an uncommon fungal infection caused by invasive mould belonging to the order *Mucoarales* that affects multiple organs. Amongst all organ involvement, rhino-orbito-cerebral form is the most common presentation.<sup>12</sup> India has the highest burden on mucormycosis with 140 cases per million.<sup>2</sup> In the ongoing COVID-19 pandemic, there has been an increased incidence of this fungal infection especially in India. The exact incidence of mucormycosis in COVID-19 is not known, however in a hospital-based study, there was more than 5-fold rise in hospital admissions due to invasive fungal infection during the COVID-19 pandemic compared to the previous 2 years.<sup>3</sup>

ROCM is an angio-invasive disease where the fungal spores invade the nasal mucosa and spread to paranasal sinuses; orbits and subsequently via superior orbital fissure to the cavernous sinus.<sup>1</sup> In the cavernous sinus, it invades the carotid artery leading to carotiditis. Occlusion of the carotid artery leads to ischemic strokes in the carotid artery territory. It can also cause aneurysm formation and subarachnoid haemorrhage.<sup>7</sup> If the fungal



infection invades the skull base, then basilar artery can be involved leading to posterior circulation stroke.<sup>13</sup> Rarely, hematogenous spread from the lungs or disseminated mucormycosis can lead to infarcts in multiple territories.<sup>1</sup> Other fungal species that can invade the vessels are *Aspergillus*, *Fusarium*, *Candida*, *Scedosporium*, *Paecilomyces*, and rare phaeohyphomycosis like *Exserohilum rostratum*.<sup>14</sup> Mucormycosis is more likely to cause ICA occlusion and thrombosis compared to *aspergillus*.<sup>7</sup>

Cerebrovascular involvement with mucormycosis is uncommon. Its exact incidence is not known and there are multiple case reports.<sup>7,13,15-23</sup> Little et al have described a total of 37 reported cases from literature over a period of 60 years.<sup>7</sup> In the ongoing mucormycosis epidemic in COVID-19 pandemic, the incidence of stroke seems to have increased many-fold. The incidence of cerebrovascular involvement was estimated to be 11.8% in one participating hospital in the present study. In an earlier study, the incidence of stroke was 14.8% amongst cases of CAM.<sup>3</sup> while 291 cases of cerebrovascular involvement are reported in CAM.<sup>24</sup> We saw 49 cases were seen in a period of 7 months during the ongoing COVID-19 pandemic. There are several explanations of the unusually high numbers which have been discussed hereafter.

India has the second highest burden of COVID-19 in the world next to United States;<sup>8</sup> second highest number of diabetic patients in the world.<sup>25</sup> and highest prevalence of mucormycosis in the world.<sup>2</sup> India has seen an unprecedented rise of CAM during the second-wave of COVID-19 with 11,109 reported cases till 5 Jun 21.<sup>6</sup> Due to an increase in the absolute numbers of CAM, the numbers of CAM associated cerebrovascular events also appear to have increased.

COVID-19 is more likely to be severe in those with comorbidities like diabetes mellitus.<sup>26</sup> Diabetes is also one of the most important risk factors for mucormycosis.<sup>12</sup> Diabetes is a well-known risk factor for ischemic stroke.<sup>27</sup> Thus, diabetic population is more vulnerable to COVID-19, CAM as well as ischemic stroke. In our series more than 81% subjects had diabetes.

The risk of ischemic stroke is higher with SARS-CoV-2 infection as compared to other infections like influenza.<sup>28</sup> The virus does so through multiple mechanisms.<sup>29</sup> COVID-19 is a hypercoagulable state as evident by thrombotic events, elevated prothrombin time and D-dimer levels, reduced fibrinogen levels and presence of antiphospholipid antibodies. The prothrombotic state of COVID-19 lasts for several days after COVID-19.<sup>30</sup> SARS-CoV-2 has a very high affinity for angiotensin converting enzyme 2 (ACE2) receptors on the endothelium, thus causing endothelial invasion and damage. Pro-inflammatory cytokines released during the SARS-CoV-2 infection produce endothelial inflammation. In CAM, both the angio-invasive fungus and prothrombotic state due to COVID-19 virus could have led to the high incidence of stroke in our study. D-dimer was elevated in over 40% of

the subjects which is a marker of the prothrombotic state due to COVID-19. Twelve (26.7%) of our subjects had multiple territorial strokes, a finding that has not been described before with mucormycosis. We suggest that the procoagulant state due to COVID-19 could be responsible for these multifocal strokes.<sup>31</sup> Known vascular risk factors like diabetes mellitus and hypertension are also risk factors for COVID-19. The same underlying medical comorbidities which predispose the subject to COVID-19 also predispose them to further develop cerebrovascular events with CAM.

Since these patients were primarily treated for mycosis, detailed investigations for stroke were not performed in all. All the ischemic strokes were large artery infarcts. ICA territory infarct in MCA or watershed area either on one side or both sides were seen in 35 (80%) patients. Though we could not demonstrate ICA occlusion in all patients, we saw at least 2 cases where initial angiogram showed no or minor vascular involvement that progressed in subsequent imaging. Thus, timing of imaging could have made a difference in demonstrating the vascular abnormalities. Similar progressive vasculopathy has been previously described.<sup>15</sup> The thrombus in the occluded artery is often infective and histopathology of the clot may show fungal elements.<sup>18</sup> The posterior circulation strokes could be due to basilar involvement. Remaining 5 (11.1%) strokes involving both anterior and posterior circulation may be due to prothrombotic state of COVID-19 or due to haematogenous spread of infection. There were 5 (11.1%) patients who had watershed infarcts. Hypotension during the course of illness could have led to these strokes.

In the study, 40% patients were on antiplatelets and/or anticoagulation when the stroke had occurred. These drugs were started as part of treatment of COVID-19, do not appear to provide protection from mucormycosis associated ischemic strokes. There are no guidelines on treatment of these type of strokes. In literature there are few reports of use of mechanical thrombectomy or endovascular stenting in treatment of mucormycosis associated strokes.<sup>18,23</sup> Till further guidelines are available, we suggest appropriate anti-fungal drugs and surgical debridement of the infection is the treatment strategy for these cerebrovascular events.

Due to the high numbers of cerebrovascular events seen in this study, we recommend that the treating physicians keep a rather low threshold for diagnosis of this complication. The cerebrovascular events can either be a presenting feature of CAM or may occur anytime during the course of illness. Hence, it is prudent to do appropriate imaging of brain as well as its vessels, as and when brain imaging is done during management of CAM. Ideally, weekly imaging should be obtained while treating a patient with CAM.<sup>32</sup> The management of CAM often involves a team of specialists from various fields, and it is worthwhile that a neurologist is also part of the treating team.

ICH and SAH are uncommon complications of mucormycosis and there are some case reports.<sup>7,33-36</sup> The

speculated mechanisms of ICH include venous congestion due to cortical vein involvement, mycotic aneurysm or arterial dissection.<sup>34</sup> In some cases, aggressive vascular interventions including coil embolization of aneurysms have led to successful outcomes.<sup>37</sup>

ROCM with cerebral involvement has been earlier reported to have 30-90% mortality rate and median time before succumbing to the disease was 75 days.<sup>6,12</sup> In the meta-analysis by Little et al, the mortality rates in patients with mucormycosis associated carotiditis were 46% at 6 weeks to 65% at 2 years. In our study, the in-hospital mortality was 51%. These results may change over time as the patients are followed up for longer duration. Increasing awareness amongst physicians and the general public about CAM has led to the early detection and improved overall outcomes. Early treatment with multidisciplinary team as well as availability of treatment protocols could have led to reduced mortality.<sup>32</sup>

COVID-19 associated mucormycosis along with its cerebrovascular complications appears to lead to prolonged hospital-stay and higher cost of treatment for the patients. It is also very likely to cause an immense burden on an already overworked healthcare system.

There are some limitations of the study. There could have been a selection bias in our study because all patients in our cohort have been included by neurologists. As the study was conducted during the COVID-19 pandemic, there are some limitations about access to investigations including imaging. During the period of study, there was an acute shortage of anti-fungal medicines in India.<sup>36</sup> The therapy had to be modified as per the availability of drugs. Most subjects were not given Amphotericin B for the prescribed 6-8 weeks duration and were treated with oral triazoles instead. This could have altered the survival rates. We did not study epidemiological features of CAM associated cerebrovascular events or compare the difference between COVID-19 and non-COVID-19 associated mucormycosis related cerebrovascular events.

## Conclusions

Cerebrovascular involvement in the form of ischemic stroke, ICH and SAH were seen in 11.8% patients with CAM. These high numbers are due to the increase in number of cases of CAM during the ongoing COVID-19 pandemic, prothrombotic state of COVID-19, co-morbidities like diabetes and increased awareness about CAM. All infarcts were large artery infarcts and 26.7% involved more than one arterial territory. Most commonly, strokes were ipsilateral to the side of ROCM (82.1%). Intracranial vascular involvement in cavernous sinus was the commonest vascular abnormality identified in 62.1% and 2 subjects had progressive vascular involvement. Forty percent patients developed ischemic stroke despite being on antiplatelets and/or anticoagulation. There are no guidelines for treatment or prevention of cerebrovascular

events in CAM. Subjects suffering from ROCM should be screened for brain as well as vessel involvement. Morbidity and mortality can often be reduced by early diagnosis and interventions by a multidisciplinary team. Systematic studies are needed to understand the natural history of this angio-invasive disease, precise contribution of serial imaging and usefulness of therapeutic modalities used traditionally for stroke. This study is one of the first of its kind to describe the patterns of both ischemic as well as haemorrhagic strokes occurring in COVID-19 associated mucormycosis.

## Sources of funding

None.

## Declaration of Competing Interest

None.

**Acknowledgment:** None.

## References

1. Chikley A, Ben-Ami R, Kontoyiannis DP. Mucormycosis of the central nervous system. *J Fungi (Basel)* 2019;5(3):59.
2. Prakash H, Chakrabarti A. Global epidemiology of mucormycosis. *J Fungi (Basel)* 2019;5(1):26.
3. Kulkarni R, Pujari S, Gupta D, et al. RhinoOrbitoCerebral mycosis and COVID19: from bad to worse? *Ann Ind Acad Neurol* 2021. [https://doi.org/10.4103/aian.aian\\_463\\_21](https://doi.org/10.4103/aian.aian_463_21) aian\_463\_21. [Epub ahead of print].
4. Singh AK, Singh R, Joshi SR, et al. Mucormycosis in COVID-19: A systematic review of cases reported worldwide and in India. *Diabetes Metab Syndr* 2021;15(4):102146.
5. John TM, Jacob CN, Kontoyiannis DP. When uncontrolled diabetes mellitus and severe COVID-19 converge: the perfect storm for mucormycosis. *Journal of Fungi* 2021;7(4):298.
6. Sen M, Honavar SG, Bansal R, et al. members of the Collaborative OPAI-IJO Study on Mucormycosis in COVID-19 (COSMIC) Study Group. Epidemiology, clinical profile, management, and outcome of COVID-19-associated rhino-orbital-cerebral mucormycosis in 2826 patients in India - Collaborative OPAI-IJO Study on Mucormycosis in COVID-19 (COSMIC), Report 1. *Indian J Ophthalmol* 2021;69(7):1670-1692.
7. Little JS, Cheng MP, Hsu L, et al. Invasive Fungal Carotiditis: A Rare Manifestation of Cranial Invasive Fungal Disease: Case Series and Systematic Review of the Literature. *Open Forum Infect Dis* 2019;6(10). ofz392.
8. Dong E, Du H, Gardner L. An interactive web-based dashboard to track COVID-19 in real time. *Lancet Infect Dis* 2020;20(5):533-534.
9. Lahane T. COVID-19: The battle of Maharashtra. *Indian J Ophthalmol* 2021;69(3):477-478.
10. Chopra V, Flanders SA, O'Malley M, et al. Sixty-Day Outcomes Among Patients Hospitalized With COVID-19. *Ann Intern Med* 2021;174(4):576-578.

11. Bamford J, Sandercock P, Dennis M, et al. Classification and natural history of clinically identifiable subtypes of cerebral infarction. *Lancet* 1991;337(8756):1521-1526.
12. Patel A, Kaur H, Xess I, et al. A multicenter observational study on the epidemiology, risk factors, management and outcomes of mucormycosis in India. *Clin Microbiol Infect* 2020;26(7). 944.e9-944.e15.
13. Fu KA, Nguyen PL, Sanossian N. Basilar artery territory stroke secondary to invasive fungal sphenoid sinusitis: a case report and review of the literature. *Case Rep Neurol* 2015;7(1):51-58.
14. Mihaïlides L, Croda M, Forrestel AK. Recognition and Management of Angioinvasive Fungal Infections. *Curr Derm Rep* 2020;9:166-174.
15. Patil A, Mohanty HS, Kumar S, et al. Angioinvasive rhinocerebral mucormycosis with complete unilateral thrombosis of internal carotid artery-case report and review of literature. *BJR Case Rep* 2016;2(2):20150448.
16. Mititelu R, Bourassa-Blanchette S, Sharma K, et al. Angioinvasive mucormycosis and paradoxical stroke: a case report. *JMM Case Rep* 2016;3(4):e005048.
17. Nagendra V, Thakkar KD, Prasad Hrishi A, et al. A Rare Case of Rhinocerebral Mucormycosis Presenting as Garcin Syndrome and Acute Ischemic Stroke. *Indian J Crit Care Med* 2020;24(11):1137-1138.
18. Kashyap S, Bernstein J, Ghanchi H, et al. Diagnosis of Rhinocerebral Mucormycosis by Treatment of Cavernous Right Internal Carotid Artery Occlusion With Mechanical Thrombectomy: Special Case Presentation and Literature Review. *Front Neurol* 2019;10:264.
19. Ermak D, Kanekar S, Specht CS, et al. Looks like a stroke, acts like a stroke, but it's more than a stroke: a case of cerebral mucormycosis. *J Stroke Cerebrovasc Dis* 2014;23(8):e403-e404.
20. Jiménez Caballero PE, Falcón García AM, Portilla Cuenca JC, et al. Multiple subcortical strokes caused by mucormycosis in a patient with lymphoma. *Arq Neuropsiquiatr* 2012;70(1):69-70.
21. Thajeb P, Thajeb T, Dai D. Fatal strokes in patients with rhino-orbito-cerebral mucormycosis and associated vasculopathy. *Scand J Infect Dis* 2004;36(9):643-648.
22. Siroos B, Sharify Bahram Z, Ghaemi O, et al. A Case of Progressive Rhino-Orbital Mucormycosis Involving the Brain Via Direct Extension, Retrograde Perineural Spreading and Middle Cerebral Artery Vasculopathy. *Arch Clin Infect Dis* 2014;9(3):e17580.
23. Scharf EL, Cloft HJ, Wijdicks E. Mucor Thrombus. *Neurocrit Care* 2016;24(2):268-272.
24. Padma Srivastava MV, Vishnu VY, Pandit AK. Mucormycosis Epidemic and Stroke in India During the COVID-19 Pandemic. *Stroke*. 2021;52(10):e622-e623.
25. Lin X, Xu Y, Pan X, et al. Global, regional, and national burden and trend of diabetes in 195 countries and territories: an analysis from 1990 to 2025. *Sci Rep* 2020;10(1):14790.
26. Lim S, Bae JH, Kwon HS, et al. COVID-19 and diabetes mellitus: from pathophysiology to clinical management. *Nat Rev Endocrinol* 2021;17:11-30.
27. Chen R, Ovbiagele B, Feng W. Diabetes and Stroke: Epidemiology, Pathophysiology, Pharmaceuticals and Outcomes. *Am J Med Sci* 2016;351(4):380-386.
28. Merkle AE, Parikh NS, Mir S, et al. Risk of Ischemic Stroke in Patients With Coronavirus Disease 2019 (COVID-19) vs Patients With Influenza. *JAMA Neurol* 2020;77(11):1366-1372.
29. Spence JD, de Freitas GR, Pettigrew LC, et al. Mechanisms of Stroke in COVID-19. *Cerebrovasc Dis* 2020;49(4):451-458.
30. Abou-Ismaïl MY, Diamond A, Kapoor S, et al. The hypercoagulable state in COVID-19: Incidence, pathophysiology, and management. *Thromb Res*. 2020;194:101-115.
31. Cerasti D, Ormitti F, Pardatscher S, et al. Multiple Acute Ischemic Strokes in a COVID-19 Patient: a Case Report. *SN Compr Clin Med* 2020:1-5. <https://doi.org/10.1007/s42399-020-00388-9>. [Epub ahead of print].
32. Cornely OA, Alastruey-Izquierdo A, Arenz D, et al. Mucormycosis ECMM MSG Global Guideline Writing Group. Global guideline for the diagnosis and management of mucormycosis: an initiative of the European Confederation of Medical Mycology in cooperation with the Mycoses Study Group Education and Research Consortium. *Lancet Infect Dis* 2019;19(12):e405-e421.
33. Muñoz J, Hughes A, Guo Y. Mucormycosis-associated intracranial hemorrhage. *Blood Coagul Fibrinolysis* 2013;24(1):100-101.
34. Takahashi S, Horiguchi T, Mikami S, et al. Subcortical intracerebral hemorrhage caused by mucormycosis in a patient with a history of bone-marrow transplantation. *J Stroke Cerebrovasc Dis* 2009;18(5):405-406.
35. Sasannejad P, Ghabeli-Juibary A, Aminzadeh S, et al. Cerebellar infarction and aneurysmal subarachnoid hemorrhage: An unusual presentation and rare complications of rhinocerebral mucormycosis. *Iran J Neurol* 2015;14(4):222-224.
36. Alvernia JE, Patel RN, Cai DZ, et al. A successful combined endovascular and surgical treatment of a cranial base mucormycosis with an associated internal carotid artery pseudoaneurysm. *Neurosurgery*. 2009;65(4):733-740.
37. Rocha ICN, Hasan MM, Goyal S, et al. COVID-19 and mucormycosis syndemic: double health threat to a collapsing healthcare system in India. *Trop Med Int Health* 2021. <https://doi.org/10.1111/tmi.13641>. [Epub ahead of print].