

# Pitfalls in diagnosing orbital malignancy through orbital incisional biopsy: A report of two cases with different scenarios

Hind M. Alkatan<sup>1,2,3</sup>, Khaled A. Helmi<sup>4</sup>, Azza M. Y. Maktabi<sup>5</sup>

## Access this article online

Quick Response Code:



## Website:

www.saudijophthalmol.org

## DOI:

10.4103/1319-4534.310420

## Abstract:

Several methods have been implemented to obtain suitable samples from patients for the purpose of histopathological examination and definitive diagnosis. This has been of paramount importance in dealing with oncology cases including orbital neoplasms. Open surgical biopsy has been the common standard technique used in our eye centers in Saudi Arabia for diagnosing various orbital lesions. Other modalities such as fine-needle aspiration biopsy, core biopsy, and imaging-guided core biopsy are not popular. We report two cases where open surgical biopsies may have not been optimal in reaching the desired tissue diagnosis of orbital malignancy on time, thus resulting in delaying further management of the two patients.

## Keywords:

Core biopsy, fine-needle aspiration biopsy, malignancy, neoplasm, orbit, surgical biopsy

## INTRODUCTION

Diagnosis of orbital malignancy is challenging, and confirmation of the lesion entity and diagnosis is essential for a management plan. The clinical diagnosis alone was not found to be necessarily accurate in predicting the diagnosis of pediatric neoplasm, thus the importance of obtaining tissue samples for this purpose.<sup>[1]</sup> Radiological diagnosis may also aid in the diagnosis, but only a few studies have been conducted to compare the accuracy of this modality when compared to the histopathological diagnosis. Koukkoulli *et al.* recently in 2018 investigated the clinical and radiological diagnostic validity and have concluded that surgical orbital biopsy “remains the gold standard” for accurate diagnosis of orbital lesions considering its safety.<sup>[2]</sup>

In this report of two different cases of orbital malignancy (one primary and one metastatic), we highlight the challenges that a pathologist might face with surgical orbital biopsies, whenever inadequate and/or nonrepresentative samples are obtained. Such challenges have ended in the

delay of the final definitive diagnosis and could have been avoided.

## CASE REPORTS

### Case 1

A 3-year-old healthy girl presented to the oculoplastic unit with a history of an increasing swelling of the right upper lid, without prior trauma or infection over the last 20 days. The swelling has been steadily enlarging in size without periorbital ecchymosis or pain. Her left eye and adnexa were normal. On examination, she had right proptosis accompanied by globe downward displacement, right afferent pupillary defect, and right optic disc swelling upon fundus examination. The patient was referred to the tertiary eye hospital based on the finding of an intraconal right orbital lesion by magnetic resonance imaging (MRI). Repeated noncontrast MRI of the brain and orbits showed soft-tissue mass between the lateral rectus muscles and the optic nerve without a definite line of infiltration and the working diagnosis was possible rhabdomyosarcoma or tumor of mesenchymal origin versus neurogenic tumor.

For this purpose, the patient underwent an incisional biopsy of the mass the following day.

**How to cite this article:** Alkatan HM, Helmi KA, Maktabi AM. Pitfalls in diagnosing orbital malignancy through orbital incisional biopsy: A report of two cases with different scenarios. Saudi J Ophthalmol 2020;34:205-8.

Departments of  
<sup>1</sup>Ophthalmology and <sup>2</sup>Pathology  
and Laboratory Medicine,  
College of Medicine, King  
Saud University, <sup>3</sup>King Saud  
University Medical City, King  
Saud University, <sup>4</sup>College of  
Medicine, Alfaisal University,  
<sup>5</sup>Department of Pathology and  
Laboratory Medicine, King  
Khaled Eye Specialist Hospital,  
Riyadh, Saudi Arabia

## Address for correspondence:

Dr. Hind Manaa Alkatan,  
Departments of Ophthalmology  
and Pathology & Laboratory  
Medicine, College of Medicine,  
King Saud University, Riyadh,  
Saudi Arabia.  
E-mail: hindkatan@yahoo.  
com, hkatan@ksu.edu.sa

Submitted: 16-Nov-2020

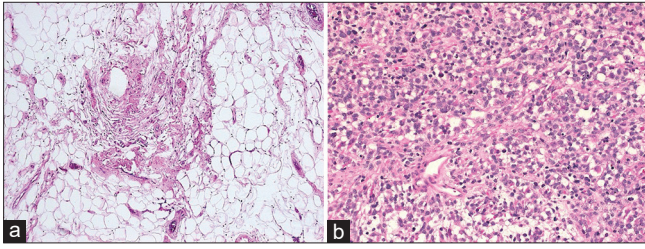
Revised: 11-Dec-2020

Accepted: 20-Dec-2020

Published: 27-Feb-2021

This is an open access journal, and articles are distributed under the terms of the Creative Commons Attribution-NonCommercial-ShareAlike 4.0 License, which allows others to remix, tweak, and build upon the work non-commercially, as long as appropriate credit is given and the new creations are licensed under the identical terms.

For reprints contact: WKHLRPMedknow\_reprints@wolterskluwer.com



**Figure 1:** (a) The histopathological image of the initial surgical open biopsy in the first patient showing normal orbital soft tissue (Original magnification  $\times 100$  Hematoxylin and eosin). (b) The histopathology of the representative second open biopsy in the same patient showing blue tumor cells of rhabdomyosarcoma (Original magnification  $\times 400$  Hematoxylin and eosin)

The specimen went through routine processing and eventually showed histologically unremarkable orbital soft tissue and fat [Figure 1a]. There was no evidence of malignancy. The pathologist recommended further biopsy (since the first one was nonrepresentative, thus inconclusive) in his report 5 days following the first procedure. The patient developed mild cough, which hindered an immediate second open biopsy under general anesthesia. Meanwhile, the mass continued to enlarge, and the second incisional biopsy was performed 1 week later, which confirmed the diagnosis of rhabdomyosarcoma, predominantly of the alveolar type [Figure 1b]. The diagnosis was further confirmed by immunohistochemical (IHC) staining showing expression of the tumor cells to smooth muscle markers. She was urgently transferred to a general hospital for further management approximately 3 weeks (in total) following her initial presentation.

## Case 2

A 51-year-old female who claimed to be completely healthy presented to the ophthalmology service with proptosis over the last year and conjunctival injection of the left eye for 2 weeks.

On preoperative ophthalmologic examination, her visual acuity was 20/100 improving to 20/25 with pinhole examination in the right eye and 20/70 in the left eye. She had no afferent pupillary defect. Extra-ocular motility was full on the right and limited by 20% in left eye abduction. Her Hertel measurements at the base of 105 were 20 on the right and 26 on the left. In addition, she had lagophthalmos of 8 mm without Bell's phenomenon.

Slit-lamp examination of the right eye was within normal limits, whereas on the left eye, there was swelling and erythema of the lid and dilated and tortuous blood vessels in the superior aspect of the conjunctiva, while the inferonasal aspect was dry and had chemosis. There was a corneal epithelial defect with a scar, superficial punctate keratitis, and no infiltrate in the left cornea.

She had computed tomography and MRI reports from another hospital showing multiple left orbital masses, for which an incisional biopsy was scheduled.

She underwent a left orbital mass biopsy; however, the first impression of the initial pathologist was suggestive of idiopathic

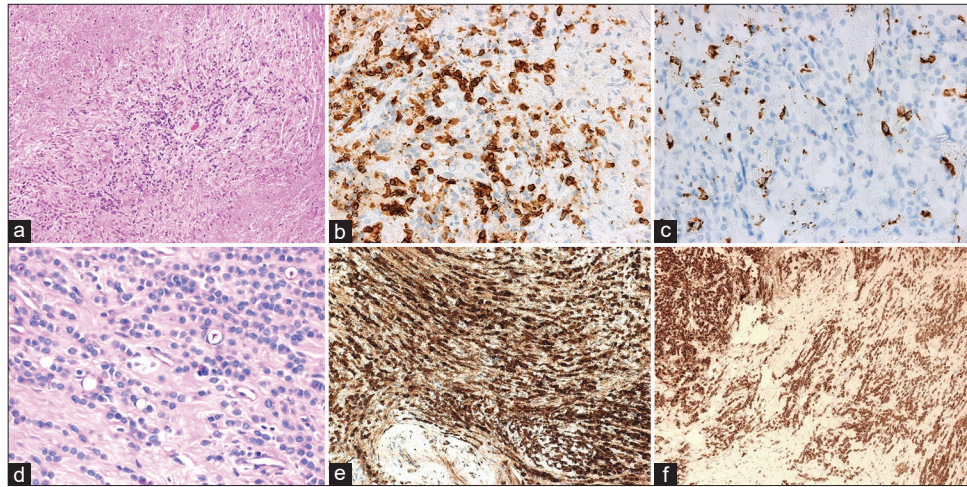
inflammatory disease, for which corresponding IHC stains such as CD3, CD20, and CD68 were requested [Figure 2a-c]. Meanwhile, the patient was treated with oral corticosteroids for 2 weeks until the next follow-up. Upon follow-up, the patient's symptoms improved slightly. However, a second pathologist took over the case few days after the initial biopsy and re-examined the histologic slides including the IHC stains and found a focus of suspected malignancy suggestive of metastatic breast cancer [Figure 2d]. The proper panel of IHC stains was thus ordered, which confirmed this diagnosis [Figure 2e and f]. The final diagnosis of metastatic breast cancer was made 10 days following the initial biopsy. The treating ophthalmologist was informed, and it was then realized that she had a history of untreated breast cancer 10 years prior to her presentation. The patient also did not disclose that she previously refused any treatment for her breast cancer. The patient was referred to a general hospital for further management.

## DISCUSSION

Orbital lesions of unknown nature usually necessitate histopathological diagnosis, especially whenever malignancy is suspected in spite of the advancing clinical and radiological diagnostic modalities. In a study on 40 cases of pediatric orbital neoplasm in Saudi Arabia (including rhabdomyosarcoma), radiological imaging was found to be superior to the clinical diagnosis, which was found to match the final histopathological diagnosis in only 32.5% of cases.<sup>[1]</sup>

This tissue diagnosis is usually achieved by either an incisional biopsy where further treatment can be planned based on the diagnosis or via an excisional biopsy where this serves as a diagnostic as well as a therapeutic procedure. On the other hand, core needle biopsy (CNB) has been reported as a diagnostic tool for orbital lesions in the 90s and gained popularity over Fine-needle aspiration biopsy (FNAB) in the oncology practice, especially in the head-and-neck region including the orbit.<sup>[3]</sup> CNB provides sufficient samples for proper histopathological examination and IHC staining and was recommended as an alternative for FNAB, particularly in diagnosing lymphoma, rhabdomyosarcoma, and inflammatory diseases.<sup>[3]</sup> Our first patient was a case of rhabdomyosarcoma and despite the clinical suspicious of this tumor, the diagnosis was delayed because of a nonrepresentative biopsy. The patient was subjected to another open biopsy as per the usually followed protocol in that institute and CNB was not considered. Yarovoy *et al.* in their study on the value of CNB have shown that a final histopathological diagnosis was successfully achieved in 94% of their orbital tumors.<sup>[3]</sup> Their remaining three nondiagnostic biopsies included one case of false-negative lacrimal gland adenocarcinoma that was missed by CNB and was initially diagnosed as fibrous tissue.<sup>[3]</sup>

The diagnosis of metastatic breast carcinoma in our second patient would have been also missed even though an incisional biopsy was obtained since the tissue appearance was mostly



**Figure 2:** (a) Histopathological image of the orbital biopsy in case 2 showing marked fibrosis with chronic inflammatory cell infiltration suggestive of chronic inflammatory pseudotumor (Original magnification  $\times 200$  Hematoxylin and eosin). (b and c) The immunohistochemical stains highlighting the reactive T-cell lymphocytes using a CD3 marker in (b) and the macrophages using CD68 marker in (c) (Original magnification  $\times 400$ ). (d) The histopathological focus of malignant cells with Indian files' pattern suggestive of metastatic breast carcinoma cells (Original magnification  $\times 400$  Periodic acid Schiff). (e and f) The tumor cells expressing positive staining to markers confirming the diagnosis (Original magnification  $\times 200$  GCDPF in e and Bcl2 in f)

suggestive of an orbital pseudotumor. It was only until the slides were reviewed by a second pathologist, who noticed a suspicious area of malignancy and another panel of suitable IHC stains was requested.

Jeng Tyng *et al.* further recommended computerized tomography-guided core biopsy as a safe method for selected orbital malignancy, in which the preoperative diagnosis is expected to alter the final management of the patient.<sup>[4]</sup>

Rhabdomyosarcomas are rare malignant tumors of soft tissue. The histopathological subtypes include alveolar, pleomorphic, (both of which are thought to have the worst overall survival), embryonal (with the highest 5-year survival rate of 73.9%), spindle cell, mixed type, and rhabdomyosarcoma with ganglionic differentiation.<sup>[5]</sup> In some institutions, image-guided needle biopsy is the favorable method for the diagnosis of rhabdomyosarcoma by providing sufficient material with minimal morbidity in spite of the fact that open-surgical incisional biopsy is often recommended by others.<sup>[6]</sup> Our first patient was unfortunate to have the alveolar type in addition to the approximate 2-week delay in her tissue diagnosis because of nonrepresentative incisional biopsy. She might have benefitted from such a technique that was advocated by Chowdhury *et al.*<sup>[6]</sup>

A large proportion (10%–30%) of orbital metastasis is from an unknown primary site. The most common primary sites for orbital metastases include breast, lung, hepatocellular carcinoma, melanoma, prostate, renal, dermatologic, and carcinoid tumors.<sup>[7]</sup> Sindoni *et al.* reported an incidence of orbital metastasis from breast cancer of 0.13%.<sup>[8]</sup> The average time from the diagnosis of breast cancer to the development of orbital metastases was reported to be approximately 5 years.<sup>[8,9]</sup> Orbital metastatic disease is one of the known indications for orbital biopsy, especially in the absence of previous history of

cancer.<sup>[10]</sup> Our patient had a denial of her breast cancer and was accordingly not compliant to any therapy over 10 years. The diagnosis of her metastatic disease could have been missed because the incisional biopsy was not perfectly representative and was suggestive of orbital pseudotumor. This would have definitely added to her morbidity and risk of mortality. The histopathologic appearance of sclerosing orbital pseudotumor usually shows fibrovascular reactive tissue and pleomorphic inflammatory infiltrate. Such a nonspecific morphology requires inflammatory markers and IHC stains to rule out lymphomas, metastatic diseases, and other conditions.<sup>[11]</sup> On the other hand, accuracy in diagnosing cancer depends on the pathologist's competence and the high suspicion by the clinician.<sup>[12]</sup> Pathologists are humans and subject to making erroneous diagnoses if they have a busy practice and do not scan carefully the whole tissue in all the sections. Other factors are the pathologist's experience, subspecialty field of practice, and methods of preparing specimens. Secondary review, which is the evaluation of the slides by another pathologist, has been suggested to be the common standard practice for cancer diagnosis.<sup>[12]</sup> In addition, proper communication by the treating ophthalmologist to relay important clinical findings and/or suspicion is essential for clinicopathologic correlation.

The outcome of diagnostic orbital biopsy depends on several factors including processing and interpretation. Careful preoperative tissue handling is also important, especially with small-volume biopsies.<sup>[13]</sup> Bombaerts *et al.* demonstrated a nice algorithm for the diagnosis of orbital mass lesions and included detailed methods for obtaining a proper biopsy.<sup>[13]</sup> They recommended giving the local anesthetic agent if needed away from the area of biopsy and a sample size of 6 mm  $\times$  6 mm  $\times$  6 mm in case of open biopsy. The tissue should be handled carefully without crushing and hemorrhage should be avoided.<sup>[13]</sup>

## CONCLUSION

The scenario in the above two patients was different, but they both shared an element of delayed histopathological diagnosis because of nonrepresentative and/or inadequate incisional biopsy. We do recommend careful and meticulous techniques when obtaining biopsies for orbital lesions, especially when malignancy is highly suspected as outlined above to avoid time-sensitive morbidity related to the delay in the histopathological diagnosis and commencement of proper treatment. Oculoplastic and orbital surgeons should also consider other diagnostic techniques recommended by others such as CNB and fine-needle biopsy – with or without radiological guidance – as an alternative to open surgical biopsy even if it is believed by some to be superior. In addition, a successful yield of any diagnostic biopsy depends on the combined good skills of both the orbital surgeon and the laboratory staff including the pathologist and his technologists. Pathologists should be cautious when interpreting orbital biopsies in order not to miss any focal serious findings suggestive of malignancy.

## Financial support and sponsorship

Nil.

## Conflicts of interest

There are no conflicts of interest.

## REFERENCES

- Alkatan HM, Al Marek F, Elkhamary S. Demographics of pediatric orbital lesions: A tertiary eye center experience in Saudi Arabia. *J Epidemiol Glob Health* 2019;9:3-10.
- Koukkoulli A, Pilling JD, Patatas K, El-Hindy N, Chang B, Kalantzis G. How accurate is the clinical and radiological evaluation of orbital lesions in comparison to surgical orbital biopsy? *Eye (Lond)* 2018;32:1329-33.
- Yarovoy AA, Bulgakova ES, Shatskikh AV, Uzunyan DG, Kleyankina SS, Golubeva OV. CORE needle biopsy of orbital tumors. *Graefes Arch Clin Exp Ophthalmol* 2013;251:2057-61.
- Jeng Tyng C, Matushita JP Jr, Bitencourt AG, Neves FB, Amoedo MK, Barbosa PN, *et al.* Uncommon primary tumors of the orbit diagnosed by computed tomography-guided core needle biopsy: Report of two cases. *Radiol Bras* 2014;47:380-3.
- Amer KM, Thomson JE, Congiusta D, Dobitsch A, Chaudhry A, Li M, *et al.* Epidemiology, incidence, and survival of rhabdomyosarcoma subtypes: SEER and ICES database analysis. *J Orthop Res* 2019;37:2226-30.
- Chowdhury T, Barnacle A, Haque S, Sebire N, Gibson S, Anderson J, *et al.* Ultrasound-guided core needle biopsy for the diagnosis of rhabdomyosarcoma in childhood. *Pediatr Blood Cancer* 2009;53:356-60.
- Wladis EJ, Lee KW, Nazeer T. Metastases of systemic malignancies to the orbit: A major review. *Orbit* 2020;40:93-7.
- Sindoni A, Fama' F, Vinciguerra P, Dionigi G, Manara SA, Gaeta R, *et al.* Orbital metastases from breast cancer: A single institution case series. *J Surg Oncol* 2020;122:170-5.
- Grajales-Alvarez R, Gutierrez-Mata A. Orbital metastases from breast cancer: A retrospective analysis of 28 cases. *Cancer Treat Res Commun* 2020;24:100184. doi: 10.1016/j.ctarc.2020.100184.
- Allen RC. Orbital metastases: When to suspect? When to biopsy? *Middle East Afr J Ophthalmol* 2018;25:60-4.
- Ronquillo Y, Patel BC. *Nonspecific Orbital Inflammation*. Treasure Island (FL): StatPearls Publishing; 2020.
- Fromer, Margot J. Study: Pathology errors can have serious effect on cancer diagnosis & treatment, oncology times. *Oncology Times* 2005;27:25-6.
- Mombaerts I, Ramberg I, Coupland SE, Heegaard S. Diagnosis of orbital mass lesions: Clinical, radiological, and pathological recommendations. *Surv Ophthalmol* 2019;64:741-56.