

CASE REPORT

Catheter-directed thrombolysis for massive deep vein thrombosis in an adolescent with severe antithrombin deficiency

Søren Thorgaard Bønløkke^{1,2}  | Maria Arvad Serifi³ | Torben Stamm Mikkelsen^{2,4} | Anne-Mette Hvas^{1,2}

¹Department of Clinical Biochemistry, Aarhus University Hospital, Aarhus, Denmark

²Department of Clinical Medicine, Aarhus University, Aarhus, Denmark

³Department of Radiology, Kolding Hospital, Kolding, Denmark

⁴Department of Pediatrics, Aarhus University Hospital, Aarhus, Denmark

Correspondence

Søren Thorgaard Bønløkke,
Department of Clinical Biochemistry,
Aarhus University Hospital, Palle Juul-Jensens Boulevard 99, 8200 Aarhus N,
Denmark.
Email: soboen@rm.dk

Funding information

None

Abstract

In this case report we describe a case of massive deep vein thrombosis in an adolescent. The case was complicated by severe antithrombin deficiency caused by a previously unreported mutation. We discuss the use of catheter directed thrombolysis and (F)Xa inhibitors in children and adolescents.

KEYWORDS

cardiovascular disorders, hematology, pediatrics and adolescent medicine

1 | INTRODUCTION

Venous thromboembolic events (VTE) in children and adolescents are very rare with an incidence of roughly 0.7–2 per 100,000 children years compared with 100–150 per 100,000 patient years in adults.^{1–3} The vast majority of VTE in children are related to acquired risk factors such as central venous catheters, which accounts for up to 90% of neonatal and 50% of pediatric VTEs.^{1,4} Most of the remaining cases are related to cancer, infection and inherent risk factors such as severe hereditary thrombophilia and venous malformations while only very few idiopathic VTEs occur in the pediatric population^{1,3,5,6}

Inferior vena cava agenesis/hypoplasia is found in up to 5% of patients younger than 30 years presenting with lower limb deep vein thrombosis.^{5,7} The prevalence in the general population is estimated to be between 1/100 and 1/200,000.⁵

Hereditary antithrombin (AT) deficiency has a prevalence of 1:5000 making it the rarest of the hereditary thrombophilias, but it is also the condition with the highest risk of VTE, and therefore, most patients with hereditary AT deficiency are given life-long anticoagulation treatment.^{2,8,9} AT is an anticoagulant protein which primary functions by inhibiting coagulation factor (F)IIa (thrombin) and FXa, but also, to a lesser extent, FIXa, FXIa,

This is an open access article under the terms of the Creative Commons Attribution-NonCommercial-NoDerivs License, which permits use and distribution in any medium, provided the original work is properly cited, the use is non-commercial and no modifications or adaptations are made.

© 2022 The Authors. *Clinical Case Reports* published by John Wiley & Sons Ltd.

FXIIa, tissue plasminogen activator, urokinase, trypsin, plasmin an kallikrein.¹⁰ The inhibitory activity of AT is increased at least a thousand fold in the presence of heparin, and it is this increase in AT activity which confers the anticoagulant effect of heparin treatment. Therefore, in the rare cases of hereditary, AT deficiency heparin treatment needs to be combined with AT supplementation.

Treatment of VTE in children and adolescents differ from the therapeutic approach in adults by being focused around low-molecular weight heparin and vitamin K antagonists, whereas in adults the increasingly preferred treatment is direct oral anticoagulants.³ However, recent evidence of the use of FXa inhibitor rivaroxaban in children and adolescents has emerged.¹¹ In the acute phase, another treatment approach is thrombolysis. Thrombolysis has the ability to restore blood vessel patency as opposed to anticoagulation, where the treatment goals are stopping clot propagation and embolization. However, thrombolysis also carries an increased risk of bleeding complications.^{12,13} Systemic thrombolysis caused clinically significant bleeding in 38% of patients.¹² In an attempt to reduce bleeding complications, catheter-directed approaches have been developed where the thrombolytic agent is administered directly at the site of the thrombus, reducing the percentage of bleeding complications to 16%.^{12,13}

In this paper, we present a case of bilateral iliofemoral deep vein thrombosis in a 15-year-old female adolescent with previously unknown AT deficiency successfully treated with catheter-directed thrombolysis followed by treatment by the Xa-inhibitor rivaroxaban.

2 | CASE DESCRIPTION, METHODS, AND RESULTS

An otherwise healthy 15-year-old girl was admitted to the Pediatric Department at Regional Hospital West Jutland, Denmark, presenting with pain and swelling in the lower extremities and lower back pain for the last 2 weeks. The physical examination showed bilateral swelling of the crura. There was tenderness of the legs but no redness or fever. Further, visibly extended veins on the lower abdomen were observed. Ultrasound of the lower extremities revealed bilateral deep vein thrombosis, extending from the femoral veins to the popliteal veins, and a computed tomography (CT) with venography demonstrated involvement of the iliac vessels as well. A CT angiography of the pulmonary vessels showed no sign of pulmonary embolism. The family history mentioned that two uncles, as well as a 13-year-old cousin, had been diagnosed with deep vein thrombosis. There was no known hereditary thrombophilia diagnosed in any of the family members. The

TABLE 1 Biochemical results and treatment in a 15-year-old girl experiencing advanced venous thromboembolism from admission (Day 1) and during the subsequent 13 days

Day (time)	Day 1	Day 4 (2:03 pm)	Day 4 (5:06 pm)	Day 4 (7:01 pm)	Day 5	Day 7	Day 9	Day 11	Day 12	Day 13
Biochemical analyses (reference interval)										
B-Hemoglobin (6.6–9.9 mmol/L)	4.4	5.1								
Etc(B) – MCV (77–91 fl)	63									
P-Ferritin (13–152 µg/L)	35									
P-Fibrin D-dimer (<0.70 mg/L(FEU))	10.3									
P-Antithrombin (enz.) (0.85–1.20 IU/L)	0.46	0.49	0.49	1.09	0.71	0.64		0.65	0.61	
Treatment										
Dalteparin 200 IE/kg			2000 IE							2000 IE
Antithrombin concentrate						2000 IE	2000 IE			
Thrombolysis								X	X	

Abbreviation: MCV, mean corpuscular volume.

patient was not taking any medication or using hormonal contraception. Treatment with dalteparin at 200 IE/kg (body weight 59 kg) was initiated according to standard guidelines.¹⁴

Biochemical results and treatment are summarized in Table 1.

Due to the extensive thrombosis and positive family history of deep vein thrombosis, hereditary thrombophilia was suspected, and on the 3rd day of admission a very low plasma-AT (enz.) was measured. This measurement was confirmed the next day at a plasma-AT level of 0.46 UI/L. After confirmation of the low plasma-AT (enz.) value, AT substitution was initiated with the aim of keeping AT above 0.60×10^3 IU. The patient

was further referred to the Department of Vascular Surgery, Kolding Hospital, which is one of two departments in Denmark performing catheter-directed thrombolysis. Despite the prolonged duration of symptoms, upwards of 3 weeks, the patient was accepted for catheter-directed thrombolysis. Conventional and magnetic resonance imaging phlebography performed prior to thrombolysis, demonstrated bilateral occlusion of the iliac and femoral vessels (Figure 1A,B), and a very thin/hypoplastic vena cava inferior from the bifurcation to just caudal to the renal veins (Figure 2). Thrombolysis was performed with thrombolysis catheters placed in both popliteal fossae. Phlebography after 24 h of treatment showed almost complete lysis of the thrombi in

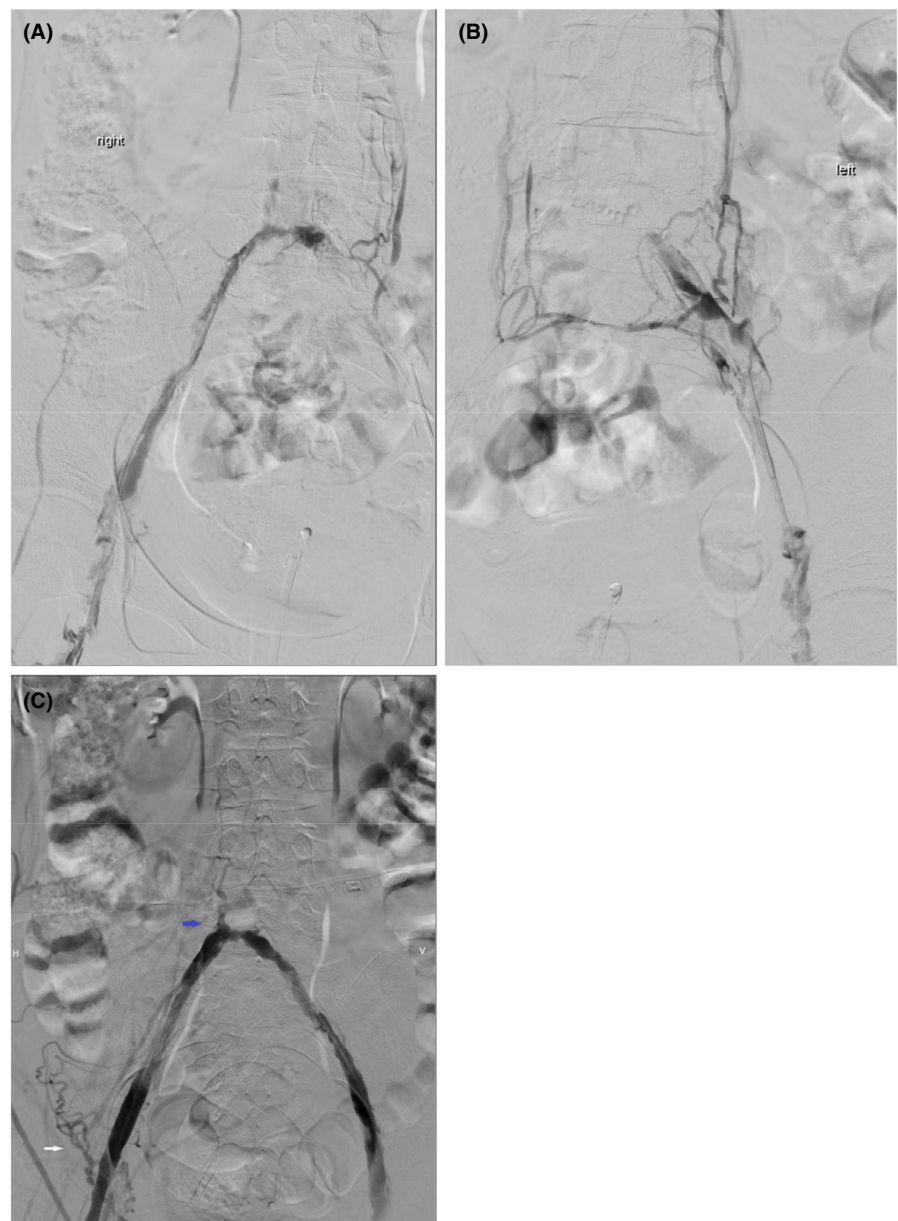


FIGURE 1 (A and B) Right and left side venography prior to thrombolysis showing no contrast flow in the femoral veins. (C) Post thrombolysis venography. White arrow shows extensive collateral formation. Blue arrow: Vena cava hypoplasia/agenesis

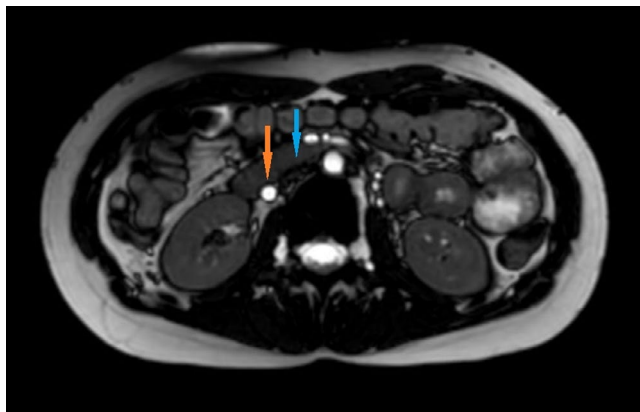


FIGURE 2 Axial balanced fast field echo (BFFE) MRI images at L2/L3 level above the iliac bifurcation. Blue arrow points to the atretic vena cava inferior with no flow. Orange arrow points to the dilated right ovarian vein, left ovarian vein is also prominent because of the collateral venous flow

the femoral veins on both sides and the right iliac vessels. In the left iliac vessels, partial thrombosis remained and thrombolysis was, therefore, continued. After 48 h, the treatment was discontinued due to continuous seeping bleeding from the left catheter. Thereafter, no other complications ensued. Post-treatment phlebography demonstrated open vessels on both sides and no remaining thrombi (Figure 1C). However, the hypoplastic vena cava inferior caused most of the run-off to be directed to large collaterals of the right common femoral vein. The agent used in the thrombolytic treatment was recombinant tissue plasminogen activator (Actilyse®) in combination with dalteparin (Fragmin®). No AT concentrate was administered during thrombolysis.

After successful thrombolysis the patient was transferred to the Pediatric Department, Aarhus University Hospital, for further treatment with dalteparin and AT concentrate as shown in Table 1. Life-long anticoagulation therapy is indicated in AT deficiency patients with thrombosis. Due to concerns about compliance to vitamin K antagonist treatment, and recent trials demonstrating adequate effect and safety of rivaroxaban in children,¹¹ treatment with rivaroxaban was chosen for this patient. Thrombophilia evaluation was performed 4 months after the initial event. At this time, the level of plasma-AT (antigen) was measured at 3.8 $\mu\text{mol/L}$ (ref: 4.1 – 6.3 $\mu\text{mol/L}$) confirming type 1 AT deficiency. At the same time, the corresponding enzymatic measurement was 0.60×10^3 IU. Because of the family history of deep vein thrombosis, genetic testing for hereditary AT deficiency was performed. Sanger sequencing of the coding regions of the SERPINC1 gene uncovered a heterozygotic deletion in exon 7 (p. Glu410del c.1225_1227del), which is assumed to be the cause of the patients type 1 AT deficiency.

3 | DISCUSSION

This case report illustrates the importance of considering thrombophilia and vascular malformations in children presenting with VTE without apparent risk factors. In this case, the family history with multiple VTEs on the paternal side was indicative of hereditary thrombophilia, and the quick diagnosis of AT deficiency allowed for treatment with AT concentrate to be commenced early on. Further, this case demonstrates that catheter-directed thrombolysis is feasible with a good outcome in a child with massive deep vein thrombosis complicated by AT deficiency and vascular malformation. The combination of severe inherited thrombophilia and inferior vena cava hypoplasia places this patient in extremely high risk of recurrent thrombosis. Because of recent evidence supporting the use of direct oral anticoagulants in children and adolescents, we decided to treat this patient with rivaroxaban, sparing her of daily injections and frequent INR monitoring. As long as the patient is free from recurrent thrombosis and does not experience bleeding complication, we will recommend the continued use of rivaroxaban. Rivaroxaban is known to be complicated by menorrhagia, and therefore, supportive measures may be necessary in this context.

ACKNOWLEDGEMENT

None.

CONFLICT OF INTEREST

STB has no conflicts regarding the present manuscript but has received research funding from CSL Behring. AMH has no conflicts of interest regarding the present work but has the following general conflicts of interest: speaker fees from CSL Behring, Bayer, Boehringer-Ingelheim, Bristol-Myers Squibb, and Astellas and unrestricted research support from CSL Behring and Octapharma. The remaining authors have no conflicts of interests to declare.

AUTHOR CONTRIBUTIONS

STB has written the manuscript. AMH, TSM, and MAS treated the patient and critically reviewed and edited the manuscript. MAS has supplied the images for Figure 1.

ETHICAL APPROVAL

This material is the authors own original work, which has not been previously published elsewhere and is not currently being considered for publication elsewhere. The paper credits the contributions of co-authors. The results are appropriately placed in the context of prior and existing research. All sources used are properly disclosed by citation. All authors have been personally and actively

involved in the work leading to this paper and will take public responsibility for its content.

CONSENT

The patient and her mother has consented to the publication of this case report by written consent.

DATA AVAILABILITY STATEMENT

None.

ORCID

Søren Thorgaard Bønløkke  <https://orcid.org/0000-0002-6289-4869>

REFERENCES

1. Radulescu VC, D'Orazio JA. Venous thromboembolic disease in children and adolescents. *Adv Exp Med Biol*. 2017;906:149-165.
2. Young G, Albisetti M, Bonduel M, et al. Impact of inherited thrombophilia on venous thromboembolism in children: a systematic review and meta-analysis of observational studies. *Circulation*. 2008;118(13):1373-1382.
3. Lassandro G, Palmieri VV, Palladino V, Amoroso A, Faienza MF, Giordano P. Venous thromboembolism in children: from diagnosis to management. *Int J Environ Res Public Health*. 2020;17(14):4993. doi:10.3390/ijerph17144993
4. Revel-Vilk S, Chan A, Bauman M, Massicotte P. Prothrombotic conditions in an unselected cohort of children with venous thromboembolic disease. *J Thromb Haemost*. 2003;1(5):915-921.
5. Pozzi A, El Lakis MA, Chamieh J, Carbonell BB, Villa F. The typical presentation spectrum of deep vein thrombosis associated with inferior vena cava malformations. *Thrombosis*. 2016;2016:4965458.
6. Nakano TA, Zeinati C. Venous thromboembolism in pediatric vascular anomalies. *Front Pediatr*. 2017;5:158.
7. Ruggeri M, Tosetto A, Castaman G, Rodeghiero F. Congenital absence of the inferior vena cava: a rare risk factor for idiopathic deep-vein thrombosis. *Lancet*. 2001;357(9254):441.
8. Nowak-Göttl U, Junker R, Kreuz W, et al. Risk of recurrent venous thrombosis in children with combined prothrombotic risk factors. *Blood*. 2001;97(4):858-862.
9. van Ommen CH, Nowak-Göttl U. Inherited thrombophilia in pediatric venous thromboembolic disease: why and who to test. *Front Pediatr*. 2017;5:50.
10. Patnaik MM, Moll S. Inherited antithrombin deficiency: a review. *Haemophilia*. 2008;14(6):1229-1239.
11. Young G, Lensing AWA, Monagle P, et al. Rivaroxaban for treatment of pediatric venous thromboembolism. An Einstein-Jr phase 3 dose-exposure-response evaluation. *J Thromb Haemost*. 2020;18(7):1672-1685.
12. Albisetti M. Thrombolytic therapy in children. *Thromb Res*. 2006;118(1):95-105.
13. Tarango C, Manco-Johnson MJ. Pediatric thrombolysis: a practical approach. *Front Pediatr*. 2017;5:260.
14. Trombose_hos_boern_030216.pdf. 2016. http://paediatri.dk/images/dokumenter/Vejledninger_2016/Trombose_hos_boern_030216.pdf

How to cite this article: Bønløkke ST, Serifi MA, Mikkelsen TS, Hvas A-M. Catheter-directed thrombolysis for massive deep vein thrombosis in an adolescent with severe antithrombin deficiency. *Clin Case Rep*. 2022;10:e5681. doi:[10.1002/ccr3.5681](https://doi.org/10.1002/ccr3.5681)