

Transesophageal Echocardiography Compared to Fluoroscopy for Avalon Bicaval Dual-Lumen Cannula Positioning for Venovenous ECMO

Abstract

The Avalon elite bicaval dual-lumen cannula for single site Venovenous Extracorporeal Membrane Oxygenation (VV ECMO) offers several advantages. Correct placement of the Avalon cannula is safe using image guidance and needs either fluoroscopy or Transesophageal echocardiography (TEE). We assessed our institutional ECMO performance, cannulation related complications, instances of cannula malposition among patients cannulated using the two imaging modalities. We reviewed all patients who had Avalon cannula placement for VV ECMO at our institute. Ten patients were included in the study. Patients were cannulated using either fluoroscopy (Group A, $n = 5$) or TEE (Group B, $n = 5$). Data included patient demographics, diagnosis, evidence of cannula malposition, ECMO performance, cannulation related complications. The primary outcomes ease of cannulation; cannula malposition and the need for repositioning were compared between the two groups. Visualisation of guidewire, Avalon cannula and the average number of attempts to cannulate were similar ($P > 0.05$) between the two groups. Four patients cannulated using fluoroscopy had low flows whereas none of the patients cannulated using TEE had flow problems which was statistically significant ($P = 0.024$). Four cannulas (80%) placed under fluoroscopy required repositioning whereas one cannula (20%) placed under TEE needed repositioning. This difference was not statistically significant though ($P = 0.099$). TEE is the ideal imaging modality to guide Avalon elite cannula placement for VV ECMO.

Keywords: *Avalon Elite bicaval dual-lumen cannula, fluoroscopy, transesophageal echocardiography, venovenous extracorporeal membrane oxygenation*

Introduction

Venovenous (VV) extracorporeal membrane oxygenation (ECMO) has historically required dual cannulation. The development of newer devices such as Avalon Elite bicaval dual-lumen cannula enables single cannulation VV ECMO. The Avalon Elite bicaval dual-lumen cannula is designed to drain blood from both inferior vena cava and superior vena cava (SVC) and return oxygenated blood into the right atrium, with the flow directed toward the tricuspid valve. Its advantages are single-site cannulation and a decreased propensity for recirculation.

These dual-lumen cannulas range in size from 13 to 31 Fr and are inserted via the right internal jugular vein (IJV). The dual-lumen cannula is designed as a straight cannula, and the recommended insertion configuration is through the right IJV. However, vascular anomalies

such as stenosis and venous thrombosis may prohibit the use of such insertion site. Alternative sites of cannulation using the left IJV^[1] and the left subclavian vein have been reported in case series.^[2,3] Nevertheless, robust data and safety reports are still lacking, hence their routine use cannot be recommended.

Correct positioning of the Avalon cannula during placement of VV ECMO is crucial for avoiding complications and to ensure effective oxygenation. Imaging is therefore recommended for dual-lumen cannula placement. Insertion may be guided by fluoroscopy or echocardiography. Each of these modalities has its advantages and disadvantages.

The institution's practice is Avalon cannula placement via right IJV under imaging guidance. Hemodynamically stable patients with no contraindications to contrast media were cannulated in the cath lab under fluoroscopic guidance. Transesophageal

**P. Hemamalini,
Prabhat Dutta¹,
Sandeep Attawar²**

Departments of Cardiac Anesthesia, ¹Anesthesia and Critical Care and ²Cardiac Sciences Thoracic Organ Transplants, Institute of Heart and Lung Transplantation, Gleneagles Global Health City, Chennai, Tamil Nadu, India

Submitted: 15-May-2019

Accepted: 14-Jul-2019

Published: 17-Jul-2020

Address for correspondence:

*Dr. P. Hemamalini,
No. 15, Sri Rajarajeshwari
Nagar, 1st Main Road,
Old Perungalathur,
Chennai - 600 063,
Tamil Nadu, India.
E-mail: drhema07@yahoo.com*

Access this article online

Website: www.annals.in

DOI: 10.4103/aca.ACA_75_19

Quick Response Code:



How to cite this article: Hemamalini P, Dutta P, Attawar S. Transesophageal echocardiography compared to fluoroscopy for Avalon bicaval dual-lumen cannula positioning for venovenous ECMO. *Ann Card Anaesth* 2020;23:283-7.

This is an open access journal, and articles are distributed under the terms of the Creative Commons Attribution-NonCommercial-ShareAlike 4.0 License, which allows others to remix, tweak, and build upon the work non-commercially, as long as appropriate credit is given and the new creations are licensed under the identical terms.

For reprints contact: reprints@medknow.com

echocardiography (TEE) guidance is used in patients with hemodynamic instability, in whom the choice of ECMO (VV) or venoarterial) needs to be ascertained by evaluation of cardiac function. Patients in need of urgent cannulation and with contraindications to contrast media were also cannulated in the intensive care unit (ICU) under TEE guidance. The purpose of this study is to compare the two imaging modalities, fluoroscopy, and TEE used to guide Avalon cannulation.

Materials and Methods

With ethical committee approval, we retrospectively reviewed the data concerning all consecutive ECMO runs performed between January 2018 and March 2019. All adult patients (age >18 years) with a primary diagnosis of acute respiratory failure who underwent Avalon cannula placement for VV ECMO were included in the study. Pediatric patients, adults with congenital heart disease, and patients who underwent dual cannulation technique for VV ECMO (the cannula for drainage is inserted into the inferior vena cava via the femoral vein and the return cannula is inserted into one of the IJV or femoral vein or subclavian veins) were excluded from the study. Patients with structural abnormalities of the right heart that may adversely affect the function and position of the cannula were also excluded from the study. Notable findings would include prominent patent foramen ovale, atrial septal defect, interatrial septal aneurysm, prominent Chiari network, presence of a pacemaker or implantable cardioverter-defibrillator leads, and tricuspid valve pathology (such as tricuspid stenosis or tricuspid valve replacement). Ethical committee approval has been obtained for the study dated 13.04.2019.

Data collected included demographics, diagnosis, imaging modality used for cannulation, ECMO support duration, complications, and problems with positioning, instances of cannula repositioning. The primary outcomes assessed were ease of guide wire and cannula visualisation, number of attempts needed for cannulation, problems with cannula positioning leading to low flows or inadequate gas exchange on initiation of VV ECMO, and the need for cannula repositioning. Outcomes were compared between the two imaging modalities, fluoroscopy and TEE used for Avalon cannula insertion. Statistical analysis was performed using Fisher's exact *t*-test (for categorical variables) and Mann-Whitney *U*-test (for continuous variables) with $P < 0.05$ defining significance.

Results

The institutional data review revealed 25 ECMO runs between January 2018 and March 2019. Twelve patients were supported with venoarterial ECMO and hence were excluded from the study. Thirteen patients were supported by VV ECMO using Avalon bicaval dual-lumen cannula, of which three patients were excluded due to lack of sufficient data.

Ten patients were included in the study; demographics and outcomes are summarized in Table 1. All patients had respiratory failure; secondary diagnosis included acute respiratory distress syndrome (30%), primary graft dysfunction (30%), bridge to lung transplant (20%), and pneumonia (20%). All cannulas were inserted percutaneously. Five (50%) were inserted with fluoroscopic guidance in the cath lab [Figure 1] and the other five (50%) cannulations were done in the ICU with the aid of TEE. There was no cannula-related death or pericardial effusion owing to chamber perforation during cannula placement.

Median age, sex distribution, and body surface area were comparable between the groups ($P > 0.05$). Visualization of the guide wire, Avalon cannula, and the average number of attempts to insert them were also similar between the two groups ($P > 0.05$) [Table 2].

On initiation of VV ECMO, four patients (4/5) cannulated with fluoroscopy had low flows. Two cannulas were lodged in the hepatic veins; one cannula was lodged in inferior vena cava–right atrium junction as determined by echocardiography, which was not evident on fluoroscopy. The fourth patient had low flows due to kinking of the cannula. None of the patients (0/5) cannulated with TEE had flow problems. This was statistically significant ($P = 0.024$).

The incidence of recirculation was similar in both the groups ($P = 0.556$). Four of five cannulas (80%) placed with fluoroscopy went on to require repositioning compared with one of five (20%) placed with TEE. This difference was not statistically significant ($P = 0.099$).

Discussion

VV ECMO is indicated in patients with severe respiratory failure that is refractory to optimal mechanical ventilation and medical therapy. ECMO may be used as a bridge to recovery,^[4] lung transplantation,^[5] or decision therapy in select patients with severe and often refractory respiratory failure. Following the results of CESAR trial^[6] and the

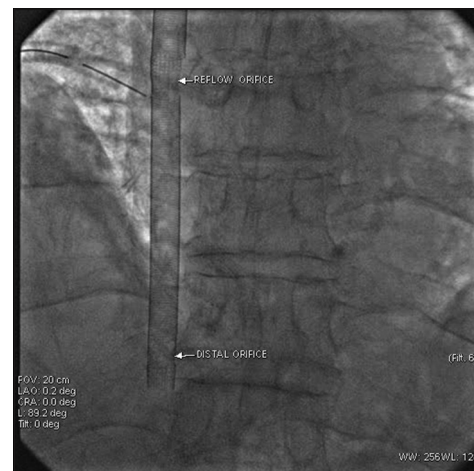

Figure 1: Fluoroscopy for Avalon positioning

Table 1: Procedure related data

Patient	Imaging modality	Guidewire visualisation	No. of attempts to insert guidewire	Cannula visualisation	No. of attempts to insert cannula	Rpm/Flow (l/min)*	Gas exchange on ECMO		Repositioning
							SaO ₂ (%) [†]	pCO ₂ (mm Hg) [†]	
Patient 1	FLUORO	EASY	1	EASY	1	2465/3.12	89	44	NIL
Patient 2	FLUORO	EASY	3	DIFFICULT	5	2975/1.5	75	55	YES
Patient 3	FLUORO	EASY	3	EASY	3	3200/1.7	70	62	YES
Patient 4	FLUORO	EASY	3	EASY	3	2986/1.8	77	59	YES
Patient 5	FLUORO	EASY	2	EASY	2	3100/1.9	72	50	YES
Patient 6	TEE	EASY	3	DIFFICULT	2	3750/4.0	72	40	YES
Patient 7	TEE	EASY	2	EASY	3	2875/3.0	88	42	NIL
Patient 8	TEE	EASY	2	EASY	2	4000/4.3	90	46	NIL
Patient 9	TEE	EASY	3	EASY	3	3299/4.5	84	35	NIL
Patient 10	TEE	EASY	2	EASY	2	2980/3.05	82	45	NIL

*ECMO flow >60% of cardiac output/>3 l/min is considered adequate.^[24] †SaO₂ 80-90% and pCO₂ 35-45 mm Hg is considered acceptable.^[25]

Table 2: Comparison between groups

		Imaging modality				P
		Fluoroscopy		TEE		
		Count	%	Count	%	
Age	In years	47 (±10.7)		52.4 (±18)		0.754
BSA	In m ²	1.63 (±0.2)		1.77 (±0.2)		0.207
Sex	Male	4	50.0%	4	50.0%	0.556
	Female	1	50.0%	1	50.0%	
Guide wire visualisation	Difficult	0	0.0%	0	0.0%	0.817
	Easy	5	50.0%	5	50.0%	
Guide wire attempts	Number	2.4 (±0.9)		2.4 (±0.5)		0.28
Cannula visualization	Difficult	1	33.3%	2	66.7%	0.913
	Easy	4	57.1%	3	42.9%	
Cannula attempts	Number	2.8 (±1.5)		2.8 (±0.8)		0.024
Flow problems	Yes	4	100.0%	0	0.0%	0.556
	Nil	1	16.7%	5	83.3%	
Recirculation	Yes	1	50.0%	1	50.0%	0.099
	Nil	4	50.0%	4	50.0%	
Repositioning	Yes	4	80.0%	1	20.0%	
	Nil	1	20.0%	4	80.0%	

success obtained with the use of ECMO in the (H1N1) influenza epidemic,^[7] the use of VV ECMO to treat severe respiratory failure has drastically increased. VV ECMO has traditionally required dual cannulation. However, the efficacy of gas exchange using this ECMO configuration is limited by recirculation, especially at high ECMO blood flow. Moreover, this technique also limits patients from active mobilization.

The introduction of Avalon bicaval dual-lumen cannula is a feasible solution to the above problems. The dual-lumen cannula enables single cannulation VV ECMO via the right IJV.^[8] The advantages of dual-lumen jugular vein VV ECMO include single vessel placement. Avoiding the femoral site facilitates prone positioning, physical therapy, extubation, and potential for early ambulation.^[9] This may be especially useful for patients who have an expected prolonged need for ECMO (e.g., bridge to transplantation or bridge to recovery). Femoral venous cannulation may be contraindicated in the case of lower extremity deep venous

thrombosis treated with IVC filter placement, which would favor selection of dual-lumen cannula.^[10] The infection rate may also be lower when the femoral vein is spared from cannulation. The incidence of recirculation is reported to be as low as 2% in optimally positioned cannula.^[11]

Proper insertion technique and precise positioning of the cannula is the key to patient safety and optimal functioning of the dual-lumen cannula. Malposition of this cannula can cause inadequate ECMO flow, hypoxia, and structural injuries with potentially fatal outcomes, such as IJV avulsion, SVC injury during serial dilatation, right ventricular rupture,^[12,13] cardiac tamponade and unintentional cannulation of the hepatic veins,^[14] and coronary sinus.

There are currently no recommendations on which imaging modality is superior to guide ECMO cannulation. Echocardiography^[15-17] and fluoroscopy^[18] have been reported as useful imaging techniques in the early detection and prevention of potential complications. The critical care setting frequently limits satisfactory transthoracic imaging. Transthoracic echo may not provide the required spatial resolution to guide ECMO initiation. Hence, we sought to compare fluoroscopy and TEE to guide Avalon bicaval dual-lumen cannula placement for VV ECMO.

Correct guide wire placement is the key first step in assuring proper advancement of the cannula. Fluoroscopic guidance allows continuous surveillance of the entire course and position of the guide wire and hence was claimed to possess a superior safety profile in guide wire placement when compared with TEE-guided insertion (the techniques in cannulation, in particular the choice and handling of different guide wires, are no different from TEE-guided approach). However, TEE provides excellent views of the appropriate position of the guide wire and cannula. The midesophageal bicaval and modified bicaval views with TEE provide excellent visualization of the inferior vena cava, SVC, tricuspid valve, and right atrium to guide placement of guide wire and cannula [Figure 2]. The initial limitation reported with echocardiography in

the initial studies is wire visualization can only be obtained in one anatomic location at a time. Simultaneous multiplane imaging possible with the matrix array transducers overcomes this limitation and provides better spatial orientation of the guide wire and cannula. In this study, TEE guidance was comparable to fluoroscopy in visualization of guide wire and the average number of attempts to insert guide wire was similar between the two imaging modalities ($P = 0.817$). This shows TEE is no longer inferior to fluoroscopy in guide wire visualization and insertion. Subsequently, cannula visualization and number of attempts to insert the cannula were also similar between the two groups ($P = 0.913$).

Once the cannula is inserted, the cardinal role of imaging is to ensure the venous drainage sites are in the SVC and inferior vena cava. However, the exact depth of the dual-lumen cannula in the inferior vena cava was not assessable by fluoroscopy leading to a significant ($P = 0.025$) incidence of flow problems in fluoroscopy group compared with patients cannulated using TEE guidance. The cannula malposition in fluoroscopy group was subsequently identified on TEE and repositioned. There was inadvertent cannulation of hepatic veins in two patients. A long-axis view of inferior vena cava from transgastric window identified the inadvertent hepatic venous cannulation. One of the cannula was lodged at the inferior vena cava–right atrium junction due to prominent Eustachian valve. This was evident on TEE and the cannula was advanced under TEE guidance so that the cannula tip moves posteriorly and inferiorly to enter the inferior vena cava. The fourth patient had low flows due to kinking of the distal tip of cannula. Echocardiography is the best modality to determine the exact position of the dual lumen cannula in the inferior vena cava.

The next key step to ensure the efficiency of the dual-lumen cannula is the optimal positioning of the reinfusion port. The cannula should be manipulated to a position where the reinfusion port is directed at the tricuspid valve. A useful echocardiographic window for evaluation of the position of

the inflow jet is the modified bicaval view, which includes the tricuspid valve in the far field. Color flow Doppler is used to confirm that the return jet is directed toward the tricuspid valve and not the interatrial septum. From a technical point of view, in addition to standard midesophageal views, dedicated deep gastric views on TEE, allowing clear visualization of the right ventricle, tricuspid valve annulus, and inferior vena cava, are particularly important for the guidance of cannula positioning [Figure 3]. As the TEE probe and the dual-lumen cannula are in a parallel orientation, the echocardiographer will be able to provide advice on the rotation (clockwise or counter clockwise) needed to improve the direction of return jet. Functional assessment of cannula position before starting ECMO flow is also feasible using echocardiography.^[19] Image validation under fluoroscopy requires the use of contrast media to verify the correct position of the proximal drainage inlet in the SVC and the return outlet in the right atrium. The incidence of recirculation though similar in both the groups ($P = 0.556$), TEE is better compared with fluoroscopy as it avoids the use of contrast media in critically ill patients.

TEE provides guidance in all three critical steps of cannulation: guide wire placement, assessing the exact depth of cannula in the inferior vena cava, and orientation of the reinfusion port toward the tricuspid valve. Other advantages of TEE include avoiding radiation and the ability to evaluate cardiac structure, filling, and function. TEE enables detection of pericardial effusion and tamponade, which is not feasible with fluoroscopy. In addition, placing the cannula in the ICU with TEE guidance eliminates the time and risk of transport. Nowadays, TEE is the preferred imaging modality to guide Avalon cannulation at our institute realizing the incidence of flow problems encountered in patients cannulated using fluoroscopy.

A survey of dual-lumen cannula in France reported that image guidance during placement was predominantly TEE (67%) compared with 25% with transthoracic echo, 4% with fluoroscopy, and 4% without image guidance.^[20] Javidfar *et al.* recommend using both fluoroscopy and TEE

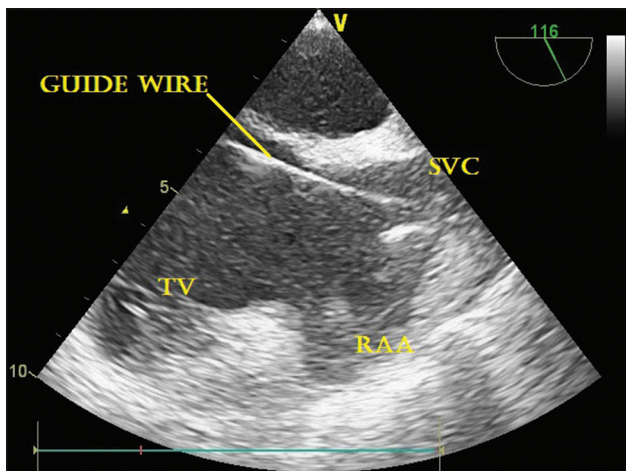


Figure 2: TEE ME modified bicaval view for guidewire insertion

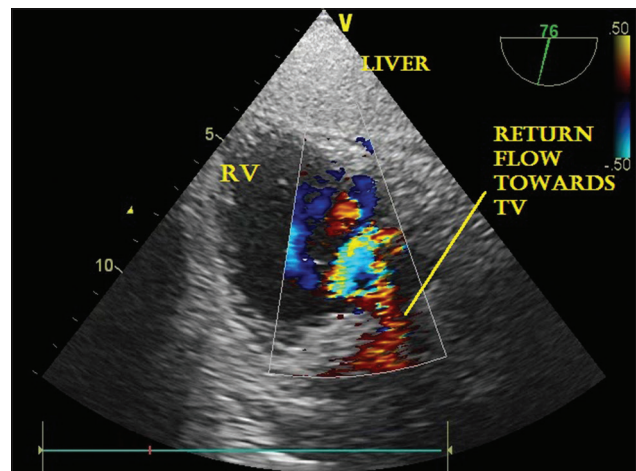


Figure 3: TEE deep transgastric view demonstrating return jet toward TV

for training purposes or during initial use of the Avalon cannula. As proficiency improves, TEE provides an excellent standard of care.^[21] Staudacher *et al.* reported a retrospective analysis of out of center dual-lumen cannula placement for ECMO using only echocardiography. In 52 cases out of 56 (94.6%), dual-lumen cannula insertions were successful. No patient developed any major or fatal complication related to ECMO implantation.^[22] A recently published position paper on the management of ECMO recommends that an echocardiography-trained physician should be a part of the team caring for patients on ECMO.^[23]

The limitations of this study were primarily its small sample size and its origin from a single institution. It was therefore underpowered for any strong recommendations, though despite this it did provide statistically driven support for the use of TEE to guide Avalon cannula insertion.

Conclusion

TEE is the ideal imaging modality to guide placement of bicaval dual-lumen cannula for VV ECMO, as it combines readily portable availability with excellent accuracy in the early recognition and management of complications.

Financial support and sponsorship

Nil.

Conflicts of interest

There are no conflicts of interest.

References

- Abrams D, Brodie D, Javidfar J, Brenner K, Wang D, Zwischenberger J, *et al.* Insertion of bicaval dual-lumen cannula via the left internal jugular vein for extracorporeal membrane oxygenation. *ASAIO J* 2012;58:636-7.
- Bojic A, Steiner I, Gamper J, Schellongowski P, Lamm W, Hermann A, *et al.* Supraclavicular approach to the subclavian vein as an alternative venous access site for ECMO cannulae? A retrospective comparison. *ASAIO J* 2017;63:679-83.
- Shafiq AE, McCurry KR. Subclavian insertion of the bicaval dual lumen cannula for venovenous extracorporeal membrane oxygenation. *Ann Thorac Surg* 2012;94:663-5.
- Brodie D, Bacchetta M. Extracorporeal membrane oxygenation for ARDS in adults. *N Engl J Med* 2011;365:1905-14.
- Javidfar J, Bacchetta M. Bridge to lung transplantation with extra corporeal membrane oxygenation support. *Curr Opin Organ Transplant* 2012;17:496-502.
- Peek GJ, Mugford M, Tiruvoipati R, Wilson A, Allen E, Thalanany MM, *et al.* Efficacy and economic assessment of conventional ventilator support versus extra corporeal membrane oxygenation for severe adult respiratory failure (CESAR): A multicentre randomized controlled trial. *Lancet* 2009;374:1351-63.
- Davies A, Jones D, Bailey M, Beca J, Bellomo R, Blackwell N, *et al.* Extracorporeal membrane oxygenation for 2009 influenza A (H1N1) acute respiratory distress syndrome. *JAMA* 2009;302:1888-95.
- Berdajs D. Bicaval dual-lumen cannula for venovenous extra corporeal membrane oxygenation: Avalon cannula in childhood disease. *Perfusion* 2015;30:182-6.
- Garcia JP, Kon ZN, Evans C, Wu Z, Iacono AT, McCormick B, *et al.* Ambulatory veno-venous extra corporeal membrane oxygenation: Innovation and pitfalls. *J Thorac Cardiovasc Surg* 2011;142:755-61.
- Palizas F, Garcia CC, Norese M. Use of a dual lumen cannula for venovenous extra corporeal membrane oxygenation in a patient with acute respiratory distress syndrome and a previously inserted inferior vena cava filter: A case report. *Rev Bras Ter Intensiva* 2016;28:78-82.
- Wang D, Zhou X, Liu X, Sidor B, Lynch J, Zwischenberger JB. Wang-Zwische double lumen cannula – Toward a percutaneous and ambulatory paracorporeal artificial lung. *ASAIO J* 2008;54:606-11.
- Hirose H, Yamane K, Marhefka G, Cavarocchi N. Right ventricular rupture and tamponade caused by malposition of the Avalon cannula for venovenous extra corporeal membrane oxygenation. *J Cardiothorac Surg* 2012;7:36.
- Yastrebov K, Manganas C, Kapalli T, Peeceeyen S. Right ventricular loop indicating malposition of J-wire introducer for double lumen bicaval venovenous extra corporeal membrane oxygenation (VV ECMO) cannula. *Heart Lung Circ* 2014;23:4-7.
- Tanaka D, Pitcher HT, Cavarocchi N, Hirose H. Migrated Avalon veno-venous extracorporeal membrane oxygenation cannula: How to adjust without interruption of flow. *J Card Surg* 2015;30:865-8.
- Griffie MJ, Tonna JE, McKellar SH, Zimmerman JM. Echocardiographic guidance and troubleshooting for venovenous extracorporeal membrane oxygenation using the dual-lumen bicaval cannula. *J Cardiothorac Vasc Anesth* 2018;32:370-8.
- Platts DG, Sedgwick JF, Burstow DJ, Mullany DV, Fraser JF. The role of echocardiography in the management of patients supported by extra corporeal membrane oxygenation. *J Am Soc Echocardiogr* 2012;25:131-41.
- Douflé G, Roscoe A, Billia F, Fan E. Echocardiography for adult patients supported with extra corporeal membrane oxygenation. *Crit Care* 2015;19:326.
- de Bucourt M, Teichgräber UK. Image guided placement of extra corporeal life support through bi-caval dual lumen venovenous membrane oxygenation in an interventional radiology setting—initial experience. *J Vasc Access* 2012;13:221-5.
- Dolch ME, Frey L, Buerkle MA, Weig T, Wassilowsky D, Irlbeck M. Trans esophageal echocardiography-guided technique for extra corporeal membrane oxygenation dual-lumen catheter placement. *ASAIO J* 2011;57:341-3.
- Chimot L, Marque S, Gros A, Gacouin A, Lavoue S, Camus C, *et al.* Avalon bicaval dual-lumen cannula for venovenous extra corporeal membrane oxygenation: Survey of cannula use in France. *ASAIO J* 2013;59:157-61.
- Javidfar J, Wang D, Zwischenberger JB, Costa J, Mongero L, Sonett J, *et al.* Insertion of bicaval dual lumen extra corporeal membrane oxygenation catheter with image guidance. *ASAIO J* 2011;57:203-5.
- Staudacher D, Schmutz A, Biever P, Kalbhenn J, Bode C, Wengenmayer T. Echocardiographic guidance for Avalon Elite dual-lumen catheter implantation. *Crit Care* 2014;18(Suppl 1):340.
- Combes A, Brodie D, Barlett R, Brochard L, Brower R, Conrad S, *et al.* Position paper for the organization of extra corporeal membrane oxygenation programs for acute respiratory failure in adult patients. *Am J Respir Crit Care Med* 2014;190:488-96.
- Banfi C, Pozzi M, Siegenthaler N, Brunner ME, Tassaux D, Obadia JF, *et al.* Veno-venous extra corporeal membrane oxygenation: Cannulation techniques. *J Thorac Dis* 2016;8:3762-73.
- Barlett R, Zwischenberger J. Management of blood flow and gas exchange during ECLS. In: Annich GM, Lynch WR, MacLauren G, Wilson JM, Barlett R, editors. *ECMO Extracorporeal Cardiopulmonary Support in Critical Care*. 4th ed. Michigan: Extracorporeal Life Support Organisation; 2012. p. 149-56.