

Mucormycosis in immunocompetent patient resulting in extensive maxillary sequestration

Deepak Venkatesh, Satyajit Dandagi¹, Pramod Redder Chandrappa², K N Hema³

Department of Dentistry, ESIC Medical College, PGIMSR and Model Hospital, Bengaluru, ¹Department of Oral and Maxillofacial Surgery, P.M.N.M. Dental College and Hospital, Bagalkot, Karnataka, India, ²Dentistry Programme, Batterjee Medical College Jeddah, Saudi Arabia, ³Department of Oral Pathology and Microbiology, V S Dental College and Hospital, Bengaluru, Karnataka, India

Abstract

Mucormycosis or zygomycosis, also called phycomycosis, is an uncommon, invasive, potentially lethal and an aggressive fungal infection of the order *Mucorales* that usually affects patients with alteration of their immunological system. From its initial description (Paltauf, 1885), this entity still has a high mortality. Imaging techniques are not usually diagnostic, and cultures are not totally reliable. Definitive diagnosis is exclusively obtained by means of histopathological examination. Early recognition and aggressive treatment are of paramount importance and have reduced the mortality and morbidity. We present here a case report of oral mucormycosis in a 32-year-old male, immunocompetent individual resulting in extensive maxillary sequestration.

Keywords: Immunocompetent, mucormycosis, osteomyelitis, predisposing factors, rhinocerebral, sequestration, zygomycosis

Address for correspondence: Dr. Deepak Venkatesh, Department of Dentistry, ESIC Medical College, PGIMSR and Model Hospital, Bengaluru, Karnataka, India.

E-mail: deepakv_dentist@yahoo.com

Received: 23.07.2017, **Accepted:** 25.10.2017

INTRODUCTION

Mucormycosis is a rare but emerging opportunistic fungal infection with high morbidity and mortality that is feared by clinicians worldwide. It predominantly affects immunocompromised hosts and is associated with a spectrum of disease.^[1] It is a potentially lethal infection caused primarily by filamentous fungus *Rhizopus*, *Mucor* and *Lichtheimia* species of the fungi of the order *Mucorales*.^[2] An ulcer or a dental extraction in the mouth can be the port of fungal invasion.^[1,3] Risk factors for invasive mucormycosis include a high dose of glucocorticoid therapy, long-term neutropenia, intravenous drug use, malnutrition, stem cell or solid organ transplantation,

treatment with deferoxamine and severe skin damages such as burns and surgical suture sites.^[2-4] Diagnosis is usually made by clinical suspicion and histopathological examination.^[5]

CASE REPORT

A 32-year-old male patient presented to the clinic with the chief complaint of bad breath and an extraction wound that had not healed for a month. The patient was referred from another clinician, and his previous dental record showed extraction of maxillary anterior and posterior teeth because of generalized periodontitis. On his recall visit, his previous clinician had noticed exposed bare bone

Access this article online

Quick Response Code:



Website:

www.jomfp.in

DOI:

10.4103/jomfp.JOMFP_163_17

This is an open access article distributed under the terms of the Creative Commons Attribution-NonCommercial-ShareAlike 3.0 License, which allows others to remix, tweak, and build upon the work non-commercially, as long as the author is credited and the new creations are licensed under the identical terms.

For reprints contact: reprints@medknow.com

How to cite this article: Venkatesh D, Dandagi S, Chandrappa PR, Hema KN. Mucormycosis in immunocompetent patient resulting in extensive maxillary sequestration. J Oral Maxillofac Pathol 2018;22:S112-6.

in the maxillary anterior area and had treated it as dry socket. After a few days, the patient went back to the clinic with the same complaint and the patient was referred to the present clinic. The patient had no history of diabetes mellitus or HIV infection or prolonged corticosteroid therapy. Clinical examination of the affected area revealed gray-colored exposed bone in the maxillary anterior area, and a panoramic radiograph taken before extraction showed diffused rarefaction of the alveolar process and the hard palate [Figure 1]. An magnetic resonance imaging scan showed a radio-opaque maxillary antrum and anterior wall destruction [Figure 2]. Based on these features, a provisional diagnosis of maxillary osteomyelitis was made followed by excision of anterior maxilla [Figure 3]. Excised specimen was fixed, decalcified, processed and stained with hematoxylin and eosin (H and E) stain. H and E stained section revealed pseudostratified ciliated columnar epithelium with edema in the submucosal areas with dense inflammatory infiltrate chiefly composed of eosinophil's interspersed with multiple colonies of thick nonseptate fungal hyphae, branching at right angles to obtuse angles, which were surrounded by extensive necrotic debris based on histopathological features diagnosed as mucormycosis [Figures 4-6]. This was followed by complete excision of the maxilla, as necrosis extends up to zygomatic bone, and surgical reconstruction of the maxilla was done [Figure 7]. The patient was administered a single daily

dose of liposomal amphotericin B, 1 mg/kg body weight as an infusion in 100 ml of 5% dextrose over 1–2 h for a period of 15 days.

DISCUSSION

Mucormycosis is the common name given to several different diseases caused by fungi of the order *Mucorales*.^[4] Mucormycosis is an opportunistic fungal infection usually occurs in immunocompromised patients but can infect healthy individuals as well. The predisposing factors for mucormycosis are uncontrolled diabetes, malignancies such as lymphomas and leukemias, renal failure, organ transplant, long-term corticosteroid and immunosuppressive therapy, cirrhosis, burns, protein-energy malnutrition and AIDS. Our patient was young immunocompetent with no comorbidity.^[3]

Mucorales invade deep tissues through inhalation of airborne spores, percutaneous inoculation or ingestion. It may occur after traumatic inoculation, especially in those cases where

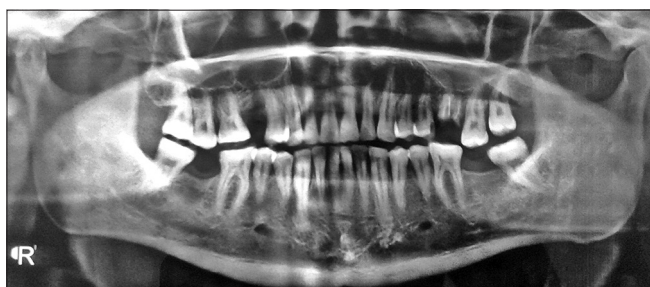

Figure 1: Panoramic radiograph showing diffuse rarefaction of the alveolar process and the hard palate

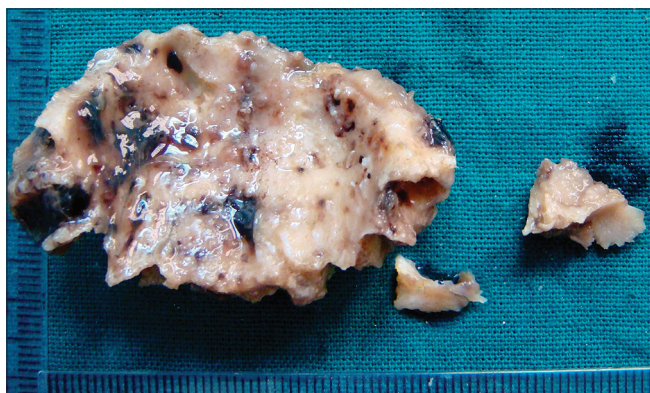


Figure 3: Surgically excised maxilla

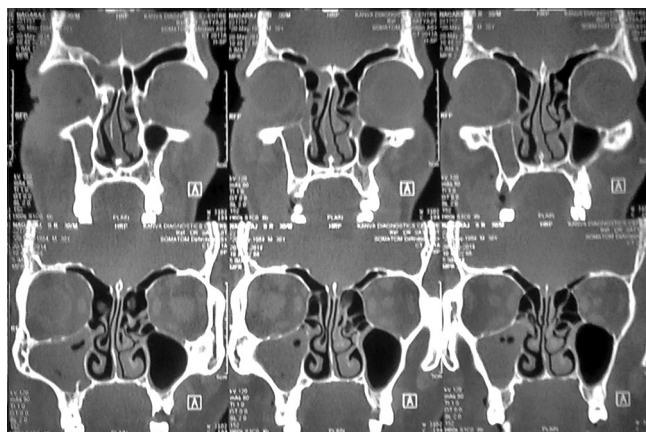


Figure 2: Coronal computed tomography image showing thickening of mucosa and opacification maxillary antrum with anterior wall destruction

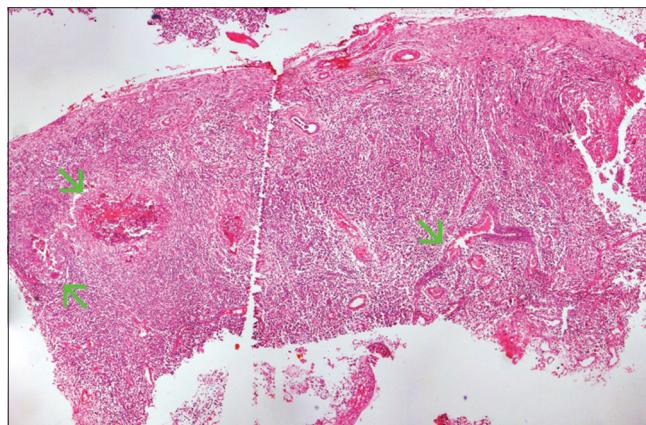


Figure 4: Whole slide scan showing (arrowheads) vasculitis consistent with inflammatory response to mucor angioinvasion (H&E, original magnification $\times 4$)

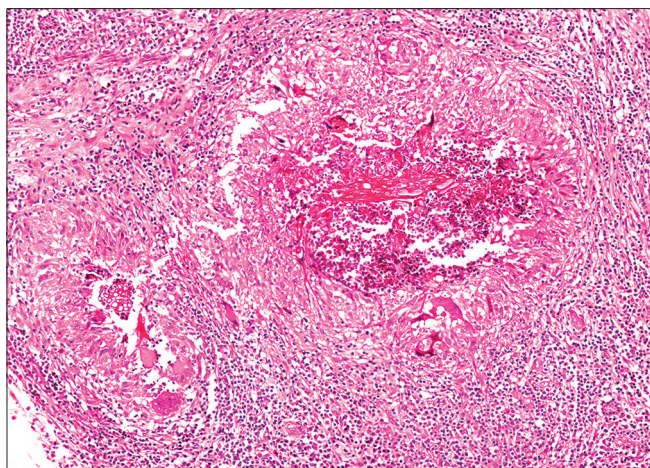


Figure 5: H&E stained section showing dense inflammatory infiltrate chiefly composed of eosinophils and hyphae branching in right angle and obtuse angles, mucormycotic hyphae, surrounded by extensive necrotic debris. These morphological features define mucor (H&E, original magnification $\times 100$)

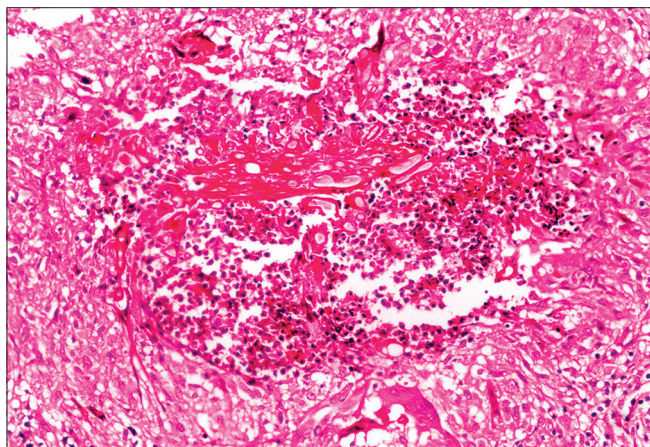


Figure 6: H&E section reveals numerous fungal hyphae which are aseptate, broad with obtuse angle branching, in right angle, typical of mucormycosis

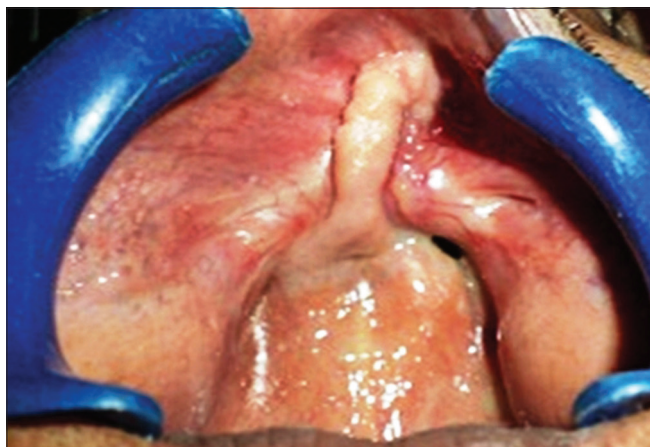

Figure 7: Postoperative wound healed uneventfully after surgical reconstruction

the inoculation is accompanied by contamination of water and soil.^[6] They colonize in patients with a high number

but do cause an invasion. Once the spores have penetrated to the lungs or subcutaneous tissues, they meet by the first line of defense, mononuclear and polynuclear phagocytes. The phagocytes of the healthy host are able to kill the spores of *Mucorales* by generating oxidative metabolites and defensins.^[7]

In immunocompetent patients, the nose and/or maxillary sinuses appear to be the predominant source of infection of the respiratory tract. If sporangiospores are larger than 10 μm , they may remain localized to the upper airways, giving an isolated form, i.e., sinus or rhino form; otherwise, they may colonize the distal alveolar spaces involving the pulmonary tract. Once infection has colonized nose and paranasal sinuses, if not promptly diagnosed and treated, it is likely that, in such patients, this infection may invade the base of the skull through blood vessels, disseminating to the central nervous system, giving the rhino-orbito-cerebral form or everywhere in the body, giving the disseminated form.^[4,5]

As the mucosal/cutaneous epithelium and endothelium represent a fundamental and effective barrier against tissue invasion and angioinvasion, it appears that this invasive fungal infection in immunocompetent/otherwise healthy controls might be relatively rare. Actually, the possibility of developing a mucor infection in such patients seems to be related to the ability of this fungus of attacking the epithelium previously damaged by prior infection, cytotoxic agents or direct trauma. It is likely that mucor sporangiospores are also capable of secreting several toxins or proteases, which may directly destroy endothelial cells in mucosal membranes.^[5]

Based on clinical presentation and the involvement of a particular anatomic site, mucormycosis can be divided into at least eight clinical categories [Table 1].^[8] Clinically, the most common clinical form of mucormycosis is rhino-orbito-cerebral (44%–49%), followed by cutaneous (10%–16%), pulmonary (10%–11%), disseminated (6%–11.6%) and gastrointestinal (2%–11%) presentations.^[4]

On clinical inspection, the infected tissue may appear normal during the earliest stages of the spread of the fungus. Infected tissue then progresses through an erythematous phase, with or without edema, before the onset of a violaceous appearance, and finally, the development of a black, necrotic eschar as the blood vessels become thrombosed and tissue infarction occurs. Palatal involvement is usually the result of the direct extension of disease from the maxillary sinus and in the distribution of the sphenopalatine and greater palatine arteries. Pain and swelling precede oral ulceration and the resulting tissue necrosis can result in palatal perforation.

Table 1: Clinical categories of mucormycosis

Number	Clinical subtypes	Predisposing conditions	Usual location
1	Rhinocerebral mucormycosis	Uncontrolled diabetes mellitus, steroidal hyperglycemia in leukemia, lymphoma patients and renal transplant patients under corticosteroids and azathioprine therapeutics	Paranasal sinuses, orbit, palate, face, nose and brain
2	Pulmonary mucormycosis	Hematological malignancies: lymphoma, leukemia, severe neutropenia cytotoxins, corticosteroids, desferrioxamine therapy, DM, organ transplantation	Bronchioles, alveoli causing pulmonary infraction, necrosis and cavitation
3	Gastrointestinal mucormycosis	Severe malnutrition in children, gastrointestinal diseases disrupting mucosal integrity	GI tract necrotic ulcers
4	Cutaneous mucormycosis	Extensive burns, DM, trauma, steroid-induced hyperglycemia	Skin implantation causing plaques, pustules, ulcerations, deep abscesses and ragged necrotic patches
5	Disseminated mucormycosis	Hematological malignancies, burns, DM and uremia	Any location
6	Central nervous system alone	Intravenous drug abuse	Traumatic implantation causing brain abscess
7	Entomophthoraceous type of mucormycosis caused by basidiobolus and conidiobolus	Chronic, slowly progressive infection in healthy individuals	Subcutaneous tissues without vascular invasion or infarction and a chronic inflammatory infiltrate with eosinophils and Splendore-Hoeppli phenomena around the hyphae
8	Organ and stem cell transplant	Solid organ and stem cell transplant recipients	Disseminated infection leading to severe immunosuppression, poor prognosis, resistant to antifungals and new azoles provide some benefit

DM: Diabetes mellitus, GI: Gastrointestinal

Infection can sometimes extend from the sinuses into the mouth and produce painful, necrotic ulcerations and perforation of the hard palate. The infection may rapidly extend into the neighboring tissues.^[4-7,9]

In routine maxillofacial practice, intraoral exposed bone and maxillary necrosis are generally diagnosed as osteomyelitis. Maxillary necrosis can occur due to bacterial osteomyelitis, herpes zoster, trauma, iatrogenic infections or fungal infections, such as mucormycosis and aspergillosis.^[10] In our case report too, we came across exposed bone, clinically mimicking bacterial osteomyelitis but suggesting a different picture on histopathological examination.

The diagnosis of mucormycosis is relatively easy in the case of rhino-orbital and mucocutaneous involvement. Nevertheless, when deep tissues are invaded like in pulmonary mucormycosis cases, a correct diagnosis is more difficult to obtain.^[10]

The reference standard for the definite diagnosis of mucormycosis concerns histopathological, cytopathological or direct microscopic examination from affected organs. The diagnosis relies on the evidence of tissue invasion. Thus, specimens obtained should be processed for fungal stains, cultures and any other procedures (e.g., molecular-based analyses) appropriate for ruling out differential diagnoses. The basis of mucormycosis treatment remains a combination of extensive surgical debridement and amphotericin B for a protracted period of 4–6 weeks. Although not currently used as first-line treatment, the concurrent use of posaconazole, a triazole antifungal drug,

has been shown to be effective against mucormycosis and use has been increasingly reported when amphotericin B had to be discontinued due to adverse side effects^[11] [Figure 8].

In summary, this case report suggests that a considerable proportion of rhinocerebral mucormycosis cases occur in patients without previously recognized predisposing factors. The characteristics and outcome of such patients are similar to those occurring in patients with the known underlying conditions. Whenever compatible clinical features for rhinocerebral mucormycosis are encountered, the absence of predisposing factors should not be used to exclude this dreadful disease, and maintaining a high index of suspicion may lead to timely diagnosis and therapy.

CONCLUSION

Mucormycosis is a rare, aggressive and life-threatening fungal infection that usually affects patients with or without alteration of the immune system. Immunocompromised or immunosuppressed patient having bone necrosis following tooth extraction should alert a clinician of possible mucormycotic infection. A multimodal treatment strategy comprising of early diagnosis, reversal or stabilization of underlying medical condition, systemic antifungals and surgical debridement has shown best results for the treatment of mucormycosis.

Declaration of patient consent

The authors certify that they have obtained all appropriate patient consent forms. In the form the patient(s) has/have given his/her/their consent for his/her/their images and

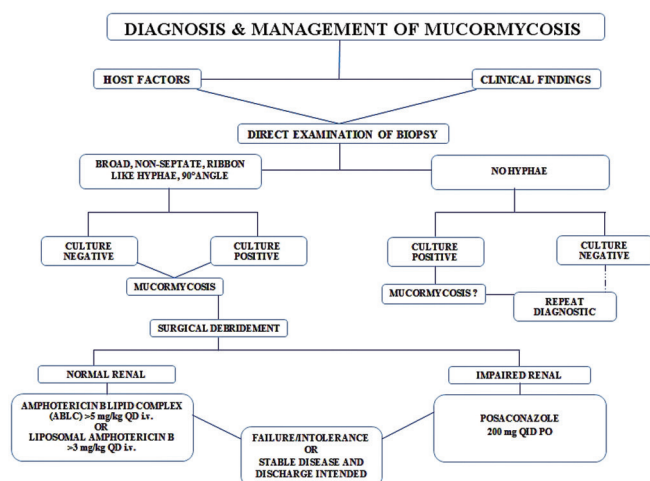


Figure 8: Diagnosis and management of mucormycosis

other clinical information to be reported in the journal. The patients understand that their names and initials will not be published and due efforts will be made to conceal their identity, but anonymity cannot be guaranteed.

Financial support and sponsorship

Nil.

Conflicts of interest

There are no conflicts of interest.

REFERENCES

- Sahota R, Gambhir R, Anand S, Dixit A. Rhino cerebral mucormycosis: Report of a rare case. *Ethiop J Health Sci* 2017;27:85-90.
- Berdai MA, Labib S, Harandou M. Rhinocerebral mucormycosis complicating ketoacidosis diabetes. *Presse Med* 2016;45:145-6.
- Dimaka K, Mallis A, Naxakis SS, Marangos M, Papadas TA, Stathas T, et al. Chronic rhinocerebral mucormycosis: A rare case report and review of the literature. *Mycoses* 2014;57:699-702.
- Prabhu RM, Patel R. Mucormycosis and entomophthoramyosis: A review of the clinical manifestations, diagnosis and treatment. *Clin Microbiol Infect* 2004;10 Suppl 1:31-47.
- Kontoyiannis DP, Lewis RE. Invasive zygomycosis: Update on pathogenesis, clinical manifestations, and management. *Infect Dis Clin North Am* 2006;20:581-607, vi.
- Kömür S, İnal AS, Kurtaran B, Ulu A, Uğuz A, Aksu HS, et al. Mucormycosis: A 10-year experience at a tertiary care center in Turkey. *Turk J Med Sci* 2016;46:58-62.
- Gamaletsou MN, Sipsas NV, Roilides E, Walsh TJ. Rhino-orbital-cerebral mucormycosis. *Curr Infect Dis Rep* 2012;14:423-34.
- Islam MN, Cohen DM, Celestina LJ, Ojha J, Claudio R, Bhattacharyya IB, et al. Rhinocerebral zygomycosis: An increasingly frequent challenge: Update and favorable outcomes in two cases. *Oral Surg Oral Med Oral Pathol Oral Radiol Endod* 2007;104:e28-34.
- Manjunatha BS, Das N, Sutariya RV, Ahmed T. Mucormycosis of the hard palate masquerading as carcinoma. *Clin Pract* 2012;2:e28.
- Kalaskar RR, Kalaskar AR, Ganvir S. Oral mucormycosis in an 18-month-old child: A rare case report with a literature review. *J Korean Assoc Oral Maxillofac Surg* 2016;42:105-10.
- Verma A, Singh V, Jindal N, Yadav S. Necrosis of maxilla, nasal, and frontal bone secondary to extensive rhino-cerebral mucormycosis. *Natl J Maxillofac Surg* 2013;4:249-51.