

Laparoscopic Transabdominal Cervical Cerclage by Broad Ligament Window Technique

B. Ramesh, T. M. Chaithra, G. Prasanna

Department of Advanced Laparoscopic Surgeries in Gynecology, Altius Hospital, Bengaluru, Karnataka, India

Abstract

Laparoscopic transabdominal cerclage (LTAC) is a well documented procedure for cervical incompetence. In this article we have done a detailed stepwise description of LTAC by broadligament window technique. This technique makes the procedure simpler, safer and easy to reproduce.

Keywords: Abdominal cerclage, cervical incompetence, laparoscopic transabdominal cervical cerclage

INTRODUCTION

Cervical incompetence occurs in approximately 0.1%–1.0% of all pregnancies.

The abdominal approach of cervical cerclage was described for the first time by Benson and Durfee in 1965.^[1] The reported success rate of abdominal cerclage is 85%–90%. Laparoscopic transabdominal cerclage (LTAC) has become the preferred choice in many tertiary care centers depending on the availability of surgical expertise. It has a success rate of 79%–100%.^[2] The most common indication for LTAC in women with cervical incompetence is failed vaginal cerclage in prior pregnancies. Many authors have reported a cumulative fetal survival rate of about 90% compared with a rate of 20% in the untreated pregnancies of the same patients.^[3] In patients with a prior failed transvaginal cerclage, transabdominal cerclage is associated with a lower incidence of preterm delivery and premature rupture of membranes.^[3] In this article, we are describing a technique of passing needle under vision throughout the procedure, compared to blind technique of passing needle mentioned in literature, so that the complications are very less.

SUBJECTS AND METHODS

The basic concept of performing LTAC remains the same whether during pregnancy or prepregnancy, that is to place a permanent nonabsorbable stich at the level of internal OS. However, the gravid uterus and the absence of a vaginal manipulator pose unique challenges.

After induction of general anesthesia via endotracheal intubation, in the pregnant group, 10 mm primary trocar was inserted supra-umbilically, whereas it was umbilical in the prepregnancy group. Supra-umbilical trocar placement varies according to the height of the uterus; this is to achieve space for maneuverability. Three accessory ports were inserted, varying according to gestational age. Uterine manipulation was done with a Hegar no. 8 dilator in a prepregnant state, whereas in the pregnant state, the vaginal manipulation was done by sponge mounted on ring forceps.

Step 1: Bladder dissection

Preoperatively, a self-retaining Foley's catheter no. 14 is inserted. The bladder flap is advanced downward by incising the uterovesical fold of the peritoneum and dissecting the pubocervical fascia, from the lower uterine segment and cervix. The anterior leaf of the broad ligament is opened by extending the incision laterally. The uterine arteries and bifurcation of the ascending branch with parametrial vessels are identified on both sides.

Step 2: Placing the Mersilene tape

Broad ligament window technique

A window 2 cm × 3 cm is created bilaterally in the broad ligament lateral to the uterine arteries at the level of the internal OS, using Maryland forceps and Harmonic scalpel, exposing

Address for correspondence: Dr. T. M. Chaithra,
Altius Hospitals, #6/63, 59th cross, 4th block, Rajajinagar Entrance, Opp.MEI
Polytechnic, Bengaluru, Karnataka - 560 010, India.
E-mail: drchaithralijesh@gmail.com

Access this article online

Quick Response Code:



Website:
www.e-gmit.com

DOI:
10.4103/GMIT.GMIT_50_18

This is an open access journal, and articles are distributed under the terms of the Creative Commons Attribution-NonCommercial-ShareAlike 4.0 License, which allows others to remix, tweak, and build upon the work non-commercially, as long as appropriate credit is given and the new creations are licensed under the identical terms.

For reprints contact: reprints@medknow.com

How to cite this article: Ramesh B, Chaithra TM, Prasanna G. Laparoscopic transabdominal cervical cerclage by broad ligament window technique. *Gynecol Minim Invasive Ther* 2018;7:139-40.

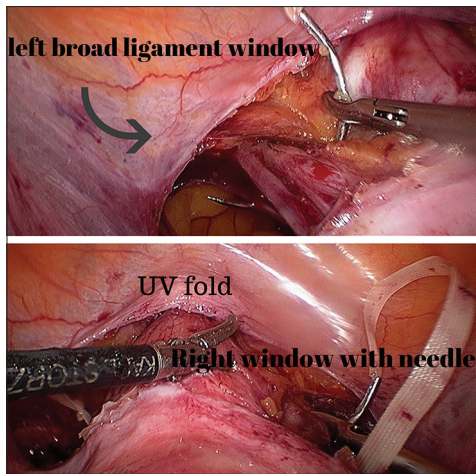


Figure 1: Needle passing through the cervical stroma medial to uterine complex, making use of broad ligament window

both anterior and posterior surfaces of uterus [Figure 1]. This technique is especially useful for gravid uterus, where space for maneuverability is reduced.

A Mersilene tape of 5 mm breadth and 30 cm long on a curved needle is then passed through the left parametrium, hugging the cervix, just medial to the uterine artery, in an anterior-to-posterior direction, under direct vision through the window [Figure 1]. The needle is caught with a needle holder posteriorly. The window assists in guiding the needle's passage and in placing the needle in the posterior aspect of the uterus. The needle is then brought anteriorly through the right window and under vision, placed at the entry point on the posterior parametrium 1.5 cm above and 1 cm lateral to the uterosacral ligament insertion, through the window. A left-hand instrument then assists in guiding the needle's exit point, which is medial to the uterine complex at the level of the internal OS. Care must be taken to ensure that the Mersilene tape is flat all the way around and not twisted. To tie the knot posteriorly, steps are started from the right side, the needle being passed in a posterior-to-anterior direction and vice versa on the opposite side.

Step 3: Placing the knot

A square knot is placed just below or at the level of the internal OS, compressing the cervical tissue but not too tightly [Figure 2].

RESULTS

LTAC by broad ligament window technique is a simpler and safer technique.

DISCUSSION

The main advantage of transabdominal cervical cerclage is the placement of the nonabsorbable permanent suture at the level of the internal OS, which theoretically represents the most appropriate placement to avoid cervical dilatation.

Conventionally, transvaginal cerclage placed during the first or early second trimester has been a common treatment for cervical incompetence. Unfortunately, the transvaginal approach to

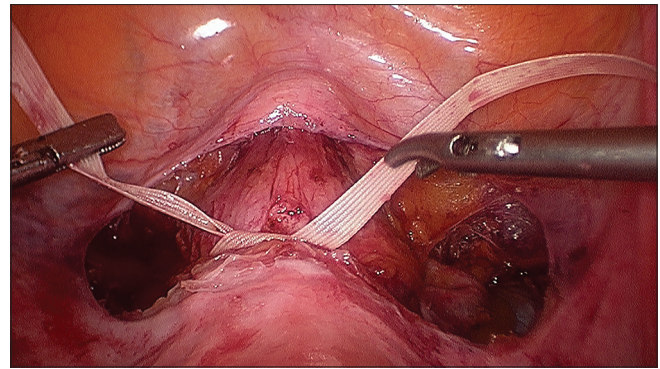


Figure 2: Knot being tied in the front

cerclage has a failure rate of about 13%.^[4] Previously failed vaginal cervical cerclage constituted the most common group for laparoscopic abdominal cerclage (100% and 94.5%), which is comparable to the systematic review by Burger *et al.* (>71%).^[5] The delivery is always by cesarean section due to the permanent nature of the nonabsorbable suture material.

With experience, we have learned that opening a window in the broad ligament and passing a curved needle under good visualization is the simplest technique for accomplishing laparoscopic cerclage, irrespective of pregnancy status.

CONCLUSION

LTAC is an advanced laparoscopic procedure requiring good laparoscopic skills and the broad ligament window technique is achievable due to simplicity and is a safer technique.

Acknowledgment

We acknowledge sincere efforts and inputs from Dr. Divya G and Dr. Rachana Ghanti in preparing manuscript.

Financial support and sponsorship

Nil.

Conflicts of interest

There are no conflicts of interest

REFERENCES

1. Benson RC, Durfee RB. Transabdominal cervico uterine cerclage during pregnancy for the treatment of cervical incompetence. *Obstet Gynecol* 1965;25:145-55.
2. Whittle WL, Singh SS, Allen L, Glaude L, Thomas J, Windrim R, *et al.* Laparoscopic cervico-isthmic cerclage: Surgical technique and obstetric outcomes. *Am J Obstet Gynecol* 2009;201:364.e1-7.
3. Davis G, Berghella V, Talucci M, Wapner RJ. Patients with a prior failed transvaginal cerclage: A comparison of obstetric outcomes with either transabdominal or transvaginal cerclage. *Am J Obstet Gynecol* 2000;183:836-9.
4. El-Nashar SA, Paraiso MF, Rodewald K, Muir T, Abdelhafez F, Lazebnik N, *et al.* Laparoscopic cervicoisthmic cerclage: Technique and systematic review of the literature. *Gynecol Obstet Invest* 2013;75:1-8.
5. Burger NB, Brölmann HA, Einarsson JI, Langebrette A, Huirne JA. Effectiveness of abdominal cerclage placed via laparotomy or laparoscopy: Systematic review. *J Minim Invasive Gynecol* 2011;18:696-704.