

# Femtosecond Laser-Assisted Small Incision Allogeneic Endokeratophakia Using a Hyperopic Lenticule in Rabbits

Tian Han<sup>1-3,\*</sup>, Yang Shen<sup>1-3,\*</sup>, Jianmin Shang<sup>2</sup>, Dan Fu<sup>1-3</sup>, Feng Zhao<sup>1-4</sup>, Jing Zhao<sup>1-3</sup>, Meiyuan Li<sup>1-3</sup>, and Xingtao Zhou<sup>1-3</sup>

<sup>1</sup> Eye Institute and Department of Ophthalmology, Eye & ENT Hospital, Fudan University, Shanghai, China

<sup>2</sup> NHC Key Laboratory of Myopia (Fudan University), Key Laboratory of Myopia, Chinese Academy of Medical Sciences, Shanghai, China

<sup>3</sup> Shanghai Research Center of Ophthalmology and Optometry, Shanghai, China

<sup>4</sup> The Department of Ophthalmology, Shuguang Hospital of Shanghai University of Traditional Chinese Medicine, Shanghai, China

**Correspondence:** Xingtao Zhou, Department of Ophthalmology and Vision Science, Eye and ENT Hospital of Fudan University, No.19 Baoqing Road, Xuhui District, Shanghai, China.

e-mail: [doctzhouxingtao@163.com](mailto:doctzhouxingtao@163.com)

**Received:** December 2, 2020

**Accepted:** July 20, 2021

**Published:** October 19, 2021

**Keywords:** femtosecond laser; lenticule allotransplantation; SMILE; concave lenticule

**Citation:** Han T, Shen Y, Shang J, Fu D, Zhao F, Zhao J, Li M, Zhou X. Femtosecond laser-assisted small incision allogeneic endokeratophakia using a hyperopic lenticule in rabbits. *Transl Vis Sci Technol.* 2021;10(12):29. <https://doi.org/10.1167/tvst.10.12.29>

**Purpose:** To investigate the morphologic and histopathologic changes in allogeneic endokeratophakia using hyperopic lenticules derived from small-incision lenticule extraction (SMILE).

**Methods:** Six New Zealand rabbits (12 eyes) were included in this experiment and randomly and evenly divided into donor and recipient groups. The donor group underwent bilateral hyperopic SMILE surgery, and the concave lenticules were implanted into eyes in the recipient group. Corneal topography and anterior segment optical coherence tomography (OCT) examinations were performed at 1 day, 1 week, 1 month, and 5 months after surgery. All eyes were enucleated 5 months after surgery. Hematoxylin and eosin (HE) staining and transmission electron microscopy (TEM) were used to observe the corneal morphology in the recipient group.

**Results:** No complications were observed, and the corneas remained transparent in the follow-up period. There was mild corneal edema within 1 week after surgery. Slit-lamp microscopy and OCT showed that the lenticules were gradually integrated with the surrounding corneal stroma. HE staining showed that the arrangement of corneal collagen was regular. The boundary between the lenticules and surrounding tissue could be identified with HE staining and TEM, and no inflammatory cells were found under TEM. The corneal Km values were significantly lower at 5 months postoperatively compared to preoperatively ( $P < 0.05$ ).

**Conclusions:** This pilot study showed that allogeneic hyperopic SMILE lenticule endokeratophakia seems to be safe and feasible.

**Translational Relevance:** Allogeneic hyperopic SMILE lenticule endokeratophakia may be applicable for the correction of corneal regression, ectasia, ultra-high myopia, or keratoconus.

## Introduction

Femtosecond laser-assisted small-incision lenticule extraction (SMILE) is an increasingly popular surgical method to correct myopia with good long-term efficacy and stability.<sup>1</sup> Contrary to the thermal ablation of laser-assisted in situ keratomileusis (LASIK), SMILE retains the complete corneal stromal lenticule, which could then be used for corneal transplantation.

In recent years, the application of endokeratophakia using myopic lenticules derived from SMILE has produced promising results.<sup>2</sup> Basic studies have shown that the transparency of the lenticule is maintained after transplantation.<sup>3-12</sup> Clinical application of endokeratophakia is becoming increasingly wide and includes fields such as hyperopia,<sup>13</sup> presbyopia,<sup>14</sup> corneal dystrophy,<sup>15</sup> corneal marginal degeneration,<sup>16</sup> keratoconus,<sup>17</sup> corneal ectasia after refractive surgery,<sup>18</sup> corneal dermoid,<sup>19,20</sup> corneal perforation,<sup>21</sup> corneal defects,<sup>22</sup> and other corneal diseases. Multiple

inventive studies have also described the application of lenticule implantation to LASIK flap loss,<sup>23</sup> glaucoma drainage exposure,<sup>24</sup> and recurrent pterygium.<sup>25</sup>

SMILE lenticule endokeratophakia is reversible, and its visual quality offers unique advantages. Liu et al.<sup>10</sup> compared the visual quality of hyperopic SMILE, LASIK, and SMILE convex lenticule implantation surgery and found that in the correction of low-degree hyperopia, lenticule implantation surgery resulted in minimal induced higher-order aberrations (HOA).

SMILE technique for correcting hyperopia has been recently developed. The concave lenticule obtained during hyperopic SMILE can also be used as a new graft material. However, there currently are few relevant studies on this matter,<sup>26–28</sup> mainly comprising case reports on keratoconus treatment.<sup>27,28</sup> Mastropasqua et al.<sup>26</sup> performed an ex vivo study and confirmed that hyperopic SMILE lenticule implantation surgery can flatten the cornea.

However, the feasibility and safety of SMILE concave lenticule implantation warrant further in vivo investigation. Given the influence of intraocular pressure and corneal biomechanics, its morphologic changes and the refractive power effects remain unclear.

This study aimed to investigate the morphologic and histopathologic changes in allogeneic endokeratophakia using hyperopic lenticules derived from SMILE.

## Materials and Methods

### Animal Preparation

Six healthy New Zealand white rabbits, weighing approximately 1.5 kg, were provided by the Department of Animals affiliated with the Shanghai Medical College of Fudan University. No obvious anterior segment lesions were present under slit-lamp microscopy. The six rabbits were divided into donor and recipient groups randomly and evenly.

### Ethics Statement

All experimental and animal handling procedures were in accordance with the Association for Research in Vision and Ophthalmology Statement for the Use of Animals in Ophthalmic and Vision Research and were conducted according to the requirements of the Animal Research and Ethics Committee of the Eye and ENT Hospital, Fudan University, Shanghai, China.

## Surgical Methods and Postoperative Medication

Both the hyperopic SMILE procedures in the donor group and the concave lenticule implantation operations in the recipient group were performed by the same physician (XZ). After routine surgery preparation, rabbits received general anesthesia by means of an intramuscular injection with 100 mg Xylazil and 1 mL ketamine hydrochloride. Local anesthesia was also induced using 0.4% oxybuprocaine hydrochloride eye drops.

In hyperopic SMILE surgery, a 500-kHz VisuMax femtosecond laser system (Carl Zeiss Meditec, Jena, Germany) was used to scan the corneal layers. The lenticules' refractive power, optical zone, and transition zone were set to +3 D, 5 mm, and 2 mm, respectively; the cap diameter was set to 7.5 mm at a 110- $\mu$ m depth. A 90° single side cut with a length of 2.5 mm was created to extract the lenticule.

A lamellar pocket similar to a corneal cap was produced using a femtosecond laser on the recipient's eye, with a diameter of 7.5 mm, thickness of 110  $\mu$ m, and a side-cut angle of 90° with a length of 2.5 mm. A Seibel spatula was used to separate the corneal stroma. The fresh concave stromal lenticule from the donor group was inserted into the femtosecond laser-created corneal stromal pocket and then flattened (Fig. 1). Both eyes of each rabbit in the recipient group received lenticules from eyes of different rabbits in the donor group.

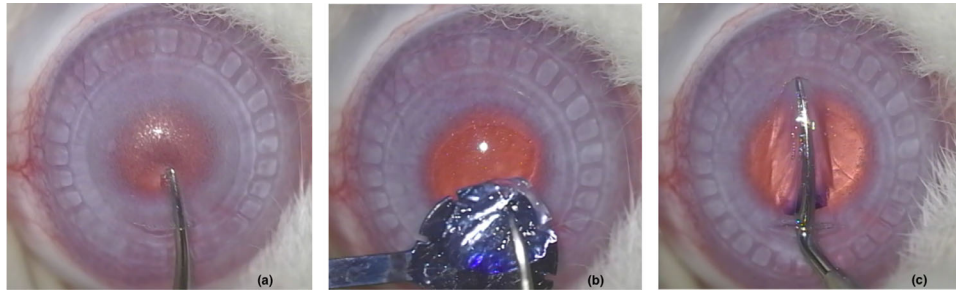
After the operation, an eye ointment containing 0.1% dexamethasone and 0.3% tobramycin was administered three times a day for 1 week.

### In Vivo Measurements

Slit-lamp microscopy, corneal topography (Pentacam HR, Type 70900; Oculus Optikgeräte GmbH, Wetzlar, Germany), and anterior segment optical coherence tomography (OCT) examinations were performed at 1 day, 1 week, 1 month, and 5 months after surgery to observe the changes in corneal morphology.

### Tissue Extraction

All eyes in the recipient group were enucleated 5 months postoperatively. The entire cornea was cut along the limbus; half was fixed in 4% polyformic acid to prepare paraffin sections for hematoxylin and eosin (HE) staining to observe the corneal morphology, and half was fixed in 2.5% glutaric acid for transmission



**Figure 1.** The corneal stroma of the recipient’s eye was separated with a Seibel spatula (a). The fresh concave stromal lenticule from the donor group was inserted into the femtosecond laser-created corneal stromal pocket through a 2.5-mm incision (b) and then gently flattened (c).

electron microscopy (TEM) observation of the ultra-structural corneal changes.

it could hardly be identified at 5 months postoperatively (Fig. 2).

### Statistical Analysis

All data were analyzed using SPSS 22 (IBM Corporation, Armonk, NY, USA). Data are presented as mean ± SD. The generalized linear mixed-model method was used for data comparisons. For all tests,  $P < 0.05$  was considered statistically significant.

### Anterior Segment OCT

Figure 3 shows the postoperative centration of the lenticule. The highly reflective boundary between the lenticule and the surrounding corneal stroma could be clearly identified at 1 day, 1 week, and 1 month postoperatively. Over time, the boundary gradually became indistinguishable, showing a tendency to merge with the surrounding tissue. The internal density of the lenticule showed a uniform low reflection at 1 day, 1 week, and 1 month postoperatively. At 5 months, the internal density of the lenticule became more similar to that of the surrounding corneal stroma (Fig. 4).

## Results

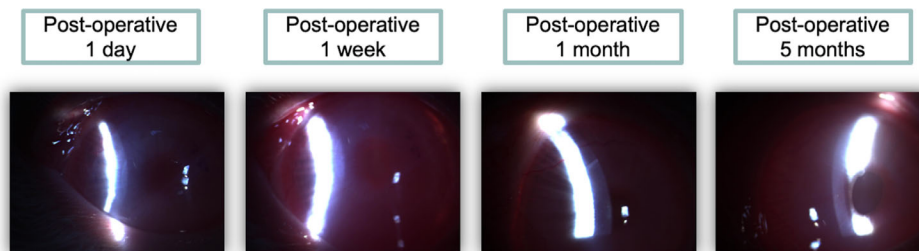
All eyes underwent successful surgery without obvious opaque bubble layers, lenticule, or incision tears.

### Corneal Topography

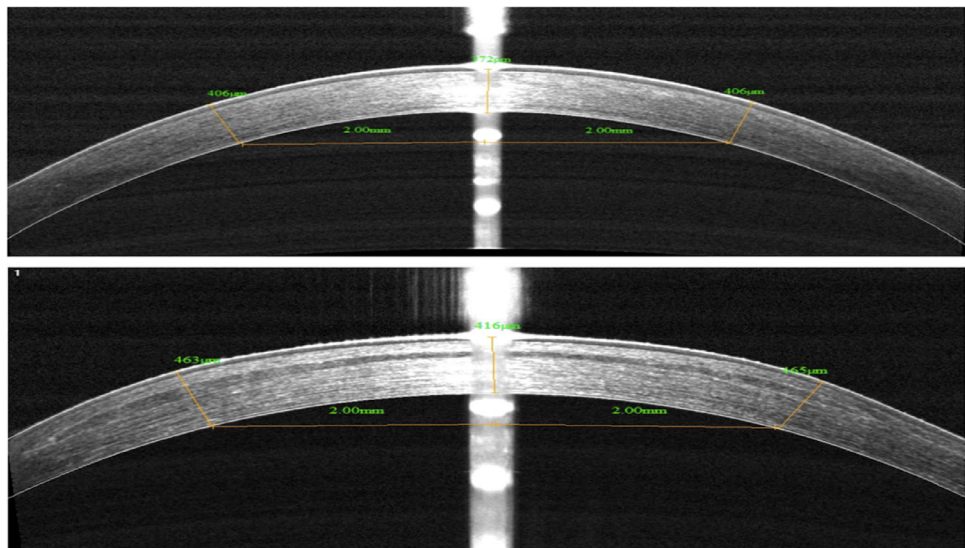
Corneal topography parameters are shown in the Table. The central corneal thickness of the recipient group was  $369.17 \pm 28.34 \mu\text{m}$ ,  $382.17 \pm 81.44 \mu\text{m}$ ,  $377.00 \pm 51.05 \mu\text{m}$ ,  $376.67 \pm 41.41 \mu\text{m}$ , and  $404.17 \pm 34.06 \mu\text{m}$  preoperatively and at 1 day, 1 week, 1 month, and 5 months postoperatively, respectively, with no significant difference across the time points ( $P > 0.05$ ).

### Slit-Lamp Microscopy

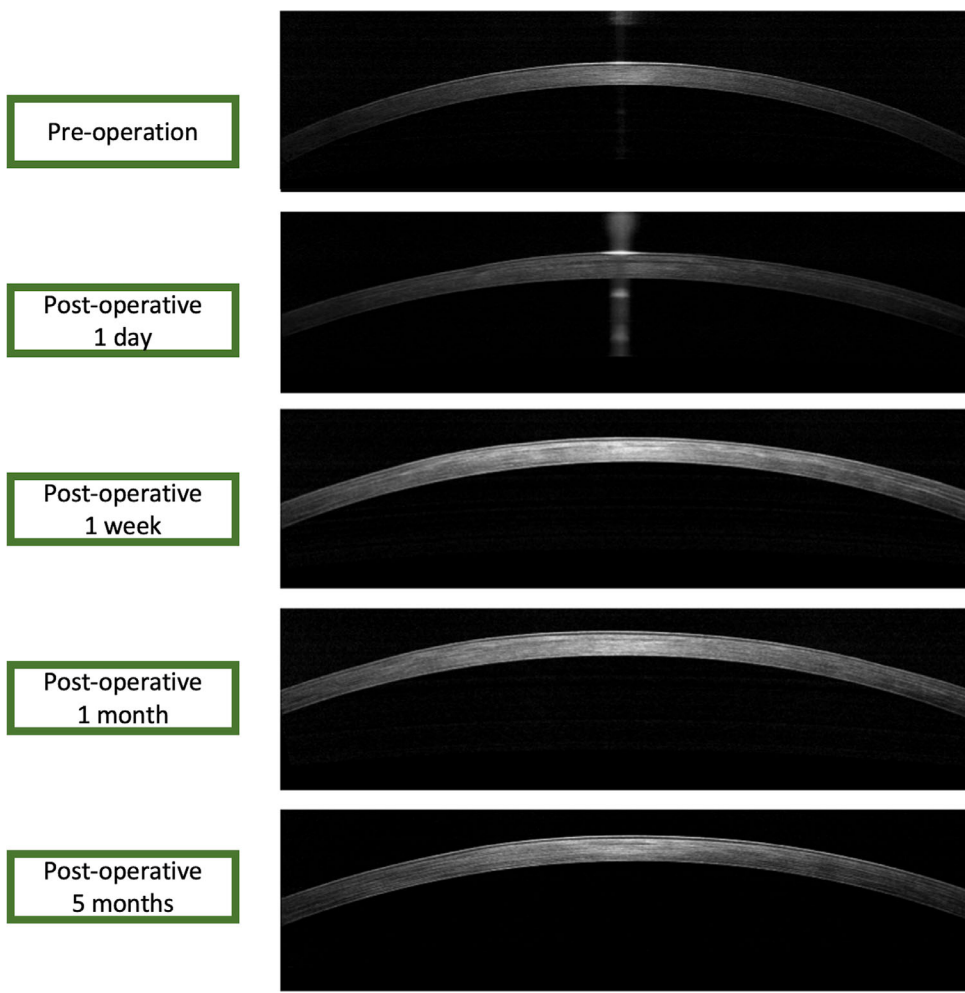
The eyes in the recipient group had mild corneal edema at 1 day and 1 week after surgery, but no infection, diffuse lamellar keratitis, or haze was seen. The boundary between the corneal lenticule and the surrounding corneal stroma gradually faded away, and



**Figure 2.** The cornea was mildly edematous under slit-lamp microscopy at postoperative 1 day and 1 week. The boundary gradually faded away and could hardly be identified after 5 months.



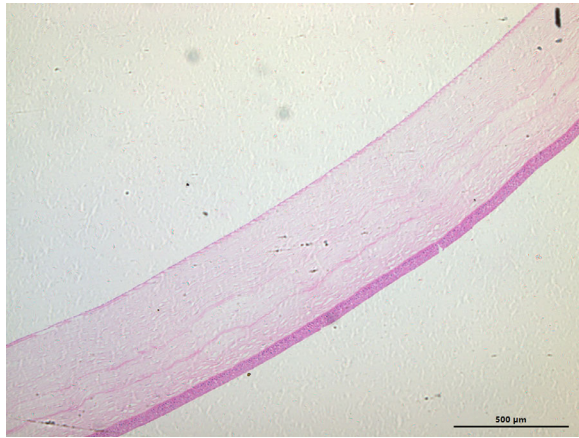**Figure 3.** Anterior segment OCT shows the postoperative centration of the lenticule at postoperative 3 months (*down*) together with the preoperative one (*up*) of No. 3 sample.



**Figure 4.** The boundary gradually became indistinguishable, and the internal density of the lenticule gradually merged as seen on anterior segment OCT.

**Table.** Changes in Corneal Topography Parameters After Lenticule Allotransplantation

Variable	Preoperation		Postoperative Day 1		Postoperative Week 1		Postoperative Month 1		Postoperative Month 5		P
	Mean	SD	Mean	SD	Mean	SD	Mean	SD	Mean	SD	
Central corneal thickness	369.17	28.34	382.17	81.44	377.00	51.05	376.67	41.41	404.17	34.06	0.436
Km	49.20	2.34	49.28	5.15	49.77	2.29	47.33	2.02	45.08	2.33	0.033
Anterior chamber volume	181.00	20.48	166.17	19.86	175.83	18.78	178.00	18.95	192.83	13.96	0.187
Anterior chamber depth	2.38	0.12	2.27	0.14	2.26	0.06	2.34	0.10	2.46	0.06	0.001
HOA	2.81	0.54	14.69	5.00	12.82	2.44	10.46	3.07	9.53	4.12	<0.001

**Figure 5.** HE staining shows that the collagen fibers inside the lenticule were regularly arranged.

At 5 months after surgery, the corneal Km value was significantly lower compared to before the surgery ( $P = 0.047$ ). At each postoperative follow-up time point, changes in anterior chamber depth and anterior chamber volume were not significant compared with the preoperative values ( $P > 0.05$ ).

The corneal high-order aberrations were  $2.81 \pm 0.54 \mu\text{m}$ ,  $14.69 \pm 5.00 \mu\text{m}$ ,  $12.82 \pm 2.44 \mu\text{m}$ ,  $10.46 \pm 3.07 \mu\text{m}$ , and  $9.53 \pm 4.12 \mu\text{m}$  preoperatively and at 1 day, 1 week, 1 month, and 5 months, postoperatively, respectively. The postoperative corneal HOA decreased over time but remained significantly higher than the preoperative values ( $P < 0.05$  at all time points).

## HE Staining

The boundary between the corneal lenticule and the surrounding corneal stroma could still be identified at 5 months postoperatively. In addition, the collagen fibers inside the lenticule were regularly arranged, and the corneal stroma structure around the lenticule was normal with ripples (Fig. 5).

## TEM

The clear boundary between the corneal lenticule and the surrounding tissue was also visible and showed


disorganized collagen fibers under TEM at 5 months postoperatively. The internal structure of the lenticule was similar to that of the surrounding corneal stroma, and no inflammatory cells were found (Fig. 6).

## Discussion

The feasibility and safety of autologous,<sup>4,9</sup> allogeneic,<sup>7,8</sup> heterogeneous,<sup>11,29</sup> and preservative<sup>3,5,6</sup> myopic SMILE lenticule endokeratophakia have been confirmed by multiple studies. Unlike a myopic lenticule, a hyperopic SMILE lenticule is concave, with a thick rim and thin center, complicating implantation. The feasibility and safety of hyperopic SMILE lenticule endokeratophakia warrant investigation.

In this study, no infection, diffuse lamellar keratitis, or haze was found in any eyes after surgery. The outcomes are in line with most of the previous studies.<sup>7,8</sup> However, Angunawela et al.<sup>3</sup> found that autogenous myopic lenticules stored at  $-80^\circ\text{C}$  for 28 days showed mild haze 3 days after implantation using femtosecond lenticule extraction (FLEX) surgery, which was found to be restored at postoperative 28 days. With the same method, Riau et al.<sup>5</sup> observed that an autologous myopic lenticule preserved for 16 weeks also showed mild haze at 2 weeks postoperatively, which improved after 8 weeks. The mild haze reported by these studies might be attributable to the changes in the stromal extracellular matrix and fiber disorganization by active corneal fibroblasts until the lenticule was fully integrated to the recipient.<sup>30,31</sup> Both of these studies used preserved lenticules, while in our study, fresh lenticules were used for implantation, which may explain why no haze was seen. There might be more abnormal water contents, abnormal collagen fiber structures (diameter, spacing, and orientation), and abnormal accumulation of macromolecules in the preserved lenticules than the fresh ones, which activate more corneal fibroblasts.<sup>31</sup>

Within 5 months after surgery, all corneas were transparent and showed good biocompatibility, as highlighted by the lack of rejections. This is consistent with the results of myopic SMILE lenticule autologous,<sup>4,9</sup> allogeneic,<sup>7,8</sup> xenogeneic,<sup>29</sup> and



**Figure 6.** TEM shows the disorganized collagen fibers (arrows) in the boundary area. An inactivated corneal fibroblast was found (star).

preservation<sup>3,5,6</sup> transplantation. To our knowledge, only Liu et al.<sup>11</sup> reported a case of rejection at 3.5 months after xenogeneic (porcine-monkey) lenticule implantation, indicating that the lenticule needs to be decellularized during xenotransplantation. There are three main reasons for the lack of rejection in our study. First, the histocompatibility of allogeneic transplantation is much better than that of xenogeneic transplantation. Second, although the hyperopic lenticule is larger than a myopic lenticule due to addition of the transition zone, the lenticule volume is limited relative to the cornea.<sup>2</sup> Third, the cornea is located in a site with immune privilege due to the lack of blood vessels. Finally, in our study, the minimal incision procedure was chosen to implant the concave lenticule. Without lifting a large corneal flap, corneal epithelial damage is limited. The initial surgical method was FLEx,<sup>3,5</sup> which requires the corneal flap to be opened. Surgical methods have now evolved from large-incision<sup>4,7,8</sup> to small-incision SMILE procedures,<sup>6,9,11</sup> thus becoming gradually less invasive. In this study, standard SMILE surgery was performed with a 2.5-mm incision, which minimized damage.

At 5 months postoperatively, the distinction between the lenticule and the surrounding corneal stroma could no longer be identified under slit-lamp microscopy and blurred in OCT. The internal reflection of the lenticule under OCT has become similar to that of the surrounding tissue gradually. However, under HE staining and TEM, the boundary between the lenticule and the surrounding corneal stroma could still be clearly identified, which is consistent with previous findings.<sup>8,12,32</sup> This boundary is similar to the one seen in a human myopic SMILE lenticule implanted in a rabbit eye at 5 months postoperatively

in Yam et al.<sup>32</sup> However, the internal structure of the lenticule in our study was similar to the surrounding tissue under TEM, which represents a more regular collagen distribution than the one found by Yam et al.<sup>32</sup> This may be attributed to the fact that we used fresh allogeneic lenticules, while Yam et al.<sup>32</sup> used preserved heterogeneous human lenticules with 0.1% sodium dodecyl sulfate decellularization. Given that the abnormal fiber arrangement of the boundary was clearly present 5 months after surgery, the boundary remains for a long time. Zhao et al.<sup>12</sup> observed that this boundary could still be identified under TEM 2 years after myopic SMILE allogeneic lenticule implantation in monkey eyes. In our opinion, the irregular boundary might cause only limited loss of HOA. The main bottleneck of the popularity of endokeratophakia still involves refractive power changes.

In this study, the corneal Km value was significantly lower at 5 months postoperatively compared to before surgery. According to Barraquer's law of thickness, myopia correction can be achieved though concave lenticule endokeratophakia. In Li et al.,<sup>27</sup> a concave SMILE lenticule was implanted in a patient with endangered keratoconus on the verge of corneal transplantation. After 10 months, the patient's refraction increased from  $-13.50\text{ D}/-6.00\text{ D} \times 10^\circ$  to  $-3.25\text{ D}/-1.50\text{ D} \times 10^\circ$  with this  $+5.75\text{ D}/-0.50\text{ D} \times 15^\circ$  lenticule, while the best-corrected visual acuity (BCVA) increased from 20/60 to 20/40. Mastropasqua et al.<sup>28</sup> implanted  $+8\text{ D}$  lenticules into 10 patients with stage III or IV keratoconus and found that the BCVA of 8 eyes improved by one to three lines. When treating keratoconus, although the implantation of myopic SMILE lenticules can also achieve

the aim of thickening the cornea and strengthening its biomechanics, hyperopic SMILE lenticule implantation adds the advantages of flattening the prominent cornea and reducing the refraction power. Hyperopic SMILE lenticule endokeratophakia has broad application prospects and can be used to correct myopia and keratoconus. Myopic variants include corneal regression after corneal refractive surgery, thin cornea, or ultra-high myopia. Keratoconic variants include keratoconus, abnormal corneal topography, and corneal ectasia after refractive surgery. In addition, the effect of the implanted concave lenticule on the refractive power in this study was different from the theoretically calculated value (3D). The reasons are as follows. The shape of the lenticule might change given the influence of the cornea's inherent convex morphology. Moreover, the corneal remodeling and biomechanics changes also play important roles in such a difference. The refractive power influence of the implanted lenticule on the recipient's eye remains to be further studied, as the eyes of a rabbit model cannot keep focusing and staring on the point of light of the corneal topography examination as do human eyes.

This study has some limitations. First, as a pilot observation experiment, the sample size of this study was small. Second, the observation time was short; thus, long-term changes need to be further studied. In addition, as mentioned above, the corneal topography parameters warrant further investigation.

In summary, allogeneic hyperopic SMILE lenticule transplantation seems to be safe and feasible. Concave lenticule implantation may effectively reduce the refractive power of the recipient cornea.

## Acknowledgments

Supported in part by the Shanghai Sailing Program (Grant No. 20YF1405000), the National Natural Science Foundation of China for Young Scholars (Grant No. 82000929), Research Project Grant of Shanghai Municipal Commission of Health and Family Planning (20204Y0058), National Natural Science Foundation of China (Grant No. 81770955), Joint Research Project of New Frontier Technology in Municipal Hospitals (SHDC12018103), Project of Shanghai Science and Technology (Grant No. 20410710100), major clinical research project of Shanghai Shenkang Hospital Development Center (SHDC2020CR1043B), and project of Shanghai Xuhui District Science and Technology (2020-015).

Disclosure: **T. Han**, None; **Y. Shen**, None; **J. Shang**, None; **D. Fu**, None; **F. Zhao**, None; **J. Zhao**, None; **M. Li**, None; **X. Zhou**, None

\* TH and YS contributed equally to this work and should be considered equal first authors.

## References

1. Blum M, Lauer AS, Kunert KS, Sekundo W. 10-Year results of small incision lenticule extraction. *J Refract Surg.* 2019;35:618–623.
2. Riau AK, Liu YC, Yam GHF, Mehta JS. Stromal keratophakia: corneal inlay implantation. *Prog Retin Eye Res.* 2019;75:100780.
3. Angunawela RI, Riau AK, Chaurasia SS, Tan DT, Mehta JS. Refractive lenticule re-implantation after myopic ReLEx: a feasibility study of stromal restoration after refractive surgery in a rabbit model. *Invest Ophthalmol Vis Sci.* 2012;53:4975–4985.
4. Liu H, Zhu W, Jiang AC, Sprecher AJ, Zhou X. Femtosecond laser lenticule transplantation in rabbit cornea: experimental study. *J Refract Surg.* 2012;28:907–911.
5. Riau AK, Angunawela RI, Chaurasia SS, Lee WS, Tan DT, Mehta JS. Reversible femtosecond laser-assisted myopia correction: a non-human primate study of lenticule re-implantation after refractive lenticule extraction. *PLoS One.* 2013;8:e67058.
6. Lim CH, Riau AK, Lwin NC, Chaurasia SS, Tan DT, Mehta JS. LASIK following small incision lenticule extraction (SMILE) lenticule re-implantation: a feasibility study of a novel method for treatment of presbyopia. *PLoS One.* 2013;8:e83046.
7. Liu R, Zhao J, Xu Y, Li M, Niu L, Liu H, Sun L, Chu R, Zhou X. Femtosecond laser-assisted corneal small incision allogenic intrastromal lenticule implantation in monkeys: a pilot study. *Invest Ophthalmol Vis Sci.* 2015;56:3715–3720.
8. Zhao J, Shen Y, Tian M, Sun L, Zhao Y, Zhang X, Zhou X. Corneal lenticule allotransplantation after femtosecond laser small incision lenticule extraction in rabbits. *Cornea.* 2017;36:222–228.
9. Williams GP, Wu B, Liu YC, Teo E, Nyein CL, Peh G, Tan DT, Mehta JS. Hyperopic refractive correction by LASIK, SMILE or lenticule reimplantation in a non-human primate model. *PLoS One.* 2018;13:e0194209.
10. Liu YC, Wen J, Teo EPW, Williams GP, Lwin NC, Mehta JS. Higher-order-aberrations

- following hyperopia treatment: small incision lenticule extraction, laser-assisted in situ keratomileusis and lenticule implantation. *Transl Vis Sci Technol.* 2018;7:15.
11. Liu YC, Teo EPW, Ang HP, Seah XY, Lwin NC, GHF Yam, Mehta JS. Biological corneal inlay for presbyopia derived from small incision lenticule extraction (SMILE). *Sci Rep.* 2018;8:1831.
  12. Zhao J, Liu R, Shen Y, Zhang X, Zhao Y, Xu H, Xu Y, Zhou X. Two-year observation of morphologic and histopathologic changes in the monkey cornea following small incision allogenic lenticule implantation. *Exp Eye Res.* 2020;192:107935.
  13. Sun L, Yao P, Li M, Shen Y, Zhao J, Zhou X. The safety and predictability of implanting autologous lenticule obtained by SMILE for hyperopia. *J Refract Surg.* 2015;31:374–379.
  14. Jacob S, Kumar DA, Agarwal A, Agarwal A, Aravind R, Saijmol AI. Preliminary evidence of successful near vision enhancement with a new technique: presbyopic allogenic refractive lenticule (PEARL) corneal inlay using a SMILE lenticule. *J Refract Surg.* 2017;33:224–229.
  15. Zhao J, Sun L, Shen Y, Tian M, Yao P, Zhou X. Using donor lenticules obtained through SMILE for an epikeratophakia technique combined with phototherapeutic keratectomy. *J Refract Surg.* 2016;32:840–845.
  16. Kalinnikov Y, Leontyeva G, Zinovyeva A, Nevrov D. Simultaneous implantation of refractive lenticule and intracorneal ring segment in the management of pellucid marginal degeneration. *J Refract Surg.* 2019;35:606–609.
  17. Li M, Yang D, Zhao F, Han T, Li M, Zhou X, Ni K. Thirty-month results after the treatment of post-LASIK ectasia with allogenic lenticule addition and corneal cross-linking: a case report. *BMC Ophthalmol.* 2018;18:294.
  18. Jiang Y, Li Y, Yang S, Lu TC. Tuck-in lamellar keratoplasty with an lenticule obtained by small incision lenticule extraction for treatment of post-LASIK ectasia. *Sci Rep.* 2017;7:17806.
  19. Wan Q, Tang J, Han Y, Ye H. Surgical treatment of corneal dermoid by using intrastromal lenticule obtained from small-incision lenticule extraction. *Int Ophthalmol.* 2020;40:43–49.
  20. Jacob S, Narasimhan S, Agarwal A, Agarwal A, Ai S. Combined interface tattooing and fibrin glue-assisted sutureless corneal resurfacing with donor lenticule obtained from small-incision lenticule extraction for limbal dermoid. *J Cataract Refract Surg.* 2017;43:1371–1375.
  21. Abd Elaziz MS, Zaky AG, El SaebaySarhan AR. Stromal lenticule transplantation for management of corneal perforations; one year results. *Graefes Arch Clin Exp Ophthalmol.* 2017;255:1179–1184.
  22. Bhandari V, Ganesh S, Brar S, Pandey R. Application of the SMILE-derived glued lenticule patch graft in microperforations and partial-thickness corneal defects. *Cornea.* 2016;35:408–412.
  23. Zhao J, Zhao F, Huang J, Xu H, Chen Y, Zhou X. Two-year outcome of a patient treated with phototherapeutic keratectomy and autologous SMILE lenticule transplantation for flap-related complications following LASIK. *J Refract Surg.* 2018;34:281–285.
  24. Wang Y, Li X, Huang W, Liu J, Xu Y, Chen M, Wang Q. Partial thickness cornea tissue from small incision lenticule extraction: a novel patch graft in glaucoma drainage implant surgery. *Medicine (Baltimore).* 2019;98:e14500.
  25. Pant OP, Hao JL, Zhou DD, Wang F, Lu CW. A novel case using femtosecond laser-acquired lenticule for recurrent pterygium: case report and literature review. *J Int Med Res.* 2018;46:2474–2480.
  26. Mastropasqua L, Nubile M. Corneal thickening and central flattening induced by femtosecond laser hyperopic-shaped intrastromal lenticule implantation. *Int Ophthalmol.* 2017;37:893–904.
  27. Li M, Zhao F, Li M, Knorz MC, Zhou X. Treatment of corneal ectasia by implantation of an allogenic corneal lenticule. *J Refract Surg.* 2018;34:347–350.
  28. Mastropasqua L, Nubile M, Salgari N, Mastropasqua R. Femtosecond laser-assisted stromal lenticule addition keratoplasty for the treatment of advanced keratoconus: a preliminary study. *J Refract Surg.* 2018;34:36–44.
  29. Sekundo W, Messerschmidt-Roth A, Reinstein DZ, Archer TJ, Blum M. Femtosecond lenticule extraction (FLEx) for spherocylindrical hyperopia using new profiles. *J Refract Surg.* 2018;34:6–10.
  30. Marino GK, Santhiago MR, Santhanam A, Torricelli AAM, Wilson SE. Regeneration of defective epithelial basement membrane and restoration of corneal transparency after photorefractive keratectomy. *J Refract Surg.* 2017;33:337–346.
  31. Moller-Pedersen T. Keratocyte reflectivity and corneal haze. *Exp Eye Res.* 2004;78:553–560.
  32. Yam GH, Yusoff NZ, Goh TW, Setiawan M, Lee XW, Liu YC, Mehta JS. Decellularization of human stromal refractive lenticules for corneal tissue engineering. *Sci Rep.* 2016;6:26339.