

Astym Therapy Improves Bilateral Hamstring Flexibility and Achilles Tendinopathy in a Child with Cerebral Palsy: A Retrospective Case Report



Nicole A. Scheer¹, Lucas R. Alstat² and Robert S. Van Zant¹

¹Physical Therapy Program, The University of Findlay, Findlay, OH, USA. ²Joyner Therapy Services, Marion, IL, USA.

ABSTRACT

PURPOSE: The purpose of this case report was to describe the use of Astym therapy to improve hamstring flexibility and Achilles tendinopathy in a child with cerebral palsy.

CASE DESCRIPTION: An eight-year-old female with cerebral palsy was referred to physical therapy for the treatment of bilateral hamstring inflexibility and Achilles tendinopathy. Treatment focused on an Astym therapy protocol of eccentric exercise, stretching, active and passive range of motion, gait training, and a home exercise program. The patient underwent a total of 11 physical therapy treatment sessions.

OUTCOMES: At the conclusion of treatment, the patient demonstrated improved resting muscle tone in bilateral lower extremities with active 90/90 hamstring flexibility measured at 165° and ankle dorsiflexion active range of motion of 5° without pain at 0° and 90° knee flexion. The patient exhibited an improved gait pattern with even stride length and diminished genu recurvatum, decreased pain with standing and walking, discontinued use of ankle-foot orthoses, and improved activity tolerance and overall function for daily activities.

DISCUSSION: The results of this case report indicate that physical therapy rehabilitation utilizing an Astym therapy protocol can successfully achieve gains in flexibility and strength and allow for improved function of bilateral lower extremities in a patient with cerebral palsy.

CONCLUSION: Based on the findings of this case report, clinicians should consider the use of Astym therapy in treating musculoskeletal soft tissue dysfunction in pediatric patients with cerebral palsy.

KEYWORDS: cerebral palsy, Astym therapy, hamstring flexibility, Achilles tendinosis

CITATION: Scheer et al. Astym Therapy Improves Bilateral Hamstring Flexibility and Achilles Tendinopathy in a Child with Cerebral Palsy: A Retrospective Case Report. *Clinical Medicine Insights: Case Reports* 2016;9 95–98 doi: 10.4137/CCRep.S40623.

TYPE: Case Report

RECEIVED: July 25, 2016. **RESUBMITTED:** August 23, 2016. **ACCEPTED FOR PUBLICATION:** August 29, 2016.

ACADEMIC EDITOR: Srinivas Melpakkam, Editor in Chief

PEER REVIEW: Three peer reviewers contributed to the peer review report. Reviewers' reports totaled 490 words, excluding any confidential comments to the academic editor.

FUNDING: The publication costs of this article were funded by Performance Dynamics Inc, the owners of the Astym treatment system. The authors confirm that the funder had no influence over the study design, content of the article, or selection of this journal.

COMPETING INTERESTS: Authors disclose no potential conflicts of interest.

CORRESPONDENCE: vanzant@findlay.edu

COPYRIGHT: © the authors, publisher and licensee Libertas Academica Limited. This is an open-access article distributed under the terms of the Creative Commons CC-BY-NC 3.0 License.

Paper subject to independent expert blind peer review. All editorial decisions made by independent academic editor. Upon submission manuscript was subject to anti-plagiarism scanning. Prior to publication all authors have given signed confirmation of agreement to article publication and compliance with all applicable ethical and legal requirements, including the accuracy of author and contributor information, disclosure of competing interests and funding sources, compliance with ethical requirements relating to human and animal study participants, and compliance with any copyright requirements of third parties. This journal is a member of the Committee on Publication Ethics (COPE).

Published by Libertas Academica. Learn more about this journal.

Introduction

Cerebral palsy is a nonprogressive neurological disorder resulting from brain injury that occurs before cerebral development is complete and affects approximately 2–2.5 children per 1000 live births in the United States.¹ Symptoms include permanent movement and posture disorders that may present with impairment in body function and structure, such as abnormal muscle tone, strength, range of motion (ROM), and reflexes.^{2,3} Physical therapy for patients with cerebral palsy is commonly prescribed to improve capabilities, increase functionality, and sustain health in terms of cognitive development, locomotion, social interaction, and independence.¹ Impaired strength, decreased ROM, and abnormal muscle tone may further lead to soft tissue pathology and dysfunction. Muscle spasticity has been shown to affect the integrity of tendon structure and the extracellular matrix.^{4–6} This may lead to breakdown of the tendon tissue resulting in chronic tendinopathy. Treating chronic soft tissue dysfunction, such as tendinopathy, is challenging. The challenges may be even

greater when the soft tissue dysfunction is contributed by a chronic neurologic condition such as cerebral palsy.

An effective treatment for soft tissue dysfunction in a child with cerebral palsy requires a unique treatment approach. Astym therapy is a promising treatment that has been shown to be effective in the management of various soft tissue dysfunctions and conditions such as hamstring tendinopathy,⁷ patellar tendinopathy,⁸ and both mid-portion⁹ and insertional Achilles tendinopathy.¹⁰ Astym therapy was conceived and developed by a multidisciplinary research team with expertise in physiology, as well as the nature of soft tissue degeneration and scar formation. The team reviewed emerging theories on tissue regeneration and developed specific protocols aiming to remodel and regenerate the tissue. A preparatory line of research preceded clinical trials to explore and substantiate the cellular impact of Astym treatment.¹¹ Astym treatment is a noninvasive soft tissue therapy that utilizes handheld instrumentation to topically address soft tissue dysfunction.⁷ The Astym instrumentation is designed to assess the presence of dysfunctional



tissue by amplifying the tactile sensation of the underlying texture of the soft tissues in order to provide the treating clinician with indications where rough or improperly organized tissue is located.¹¹ As the instruments glide over dysfunctional areas, they *catch* on the irregular fibrosis and give the clinician and the patient a sensation of roughness.¹¹ Astym therapy has been shown to improve muscle strength¹² and appears to affect neurologic functioning, as patients frequently report a sense of ease of movement immediately following treatment.¹³ Primary goals of Astym therapy include engaging the regenerative mechanisms of the body and stimulating tissue turnover for reabsorption of inappropriate fibrosis, thereby encouraging functional alignment of the soft tissue and regenerating healthy tissue in the affected areas.⁹ The treatment approach includes an exercise protocol to help stimulate tendon healing at the cellular level.^{7,9,11} Achieving these treatment goals then reduces subjective complaints of restrictions in motion and improves function.^{13,14} Astym therapy has consistently demonstrated safety and effectiveness in the soft tissue conditions studied and is also well tolerated by patients.⁷⁻¹⁰ However, it is important to recognize that instrument-assisted soft tissue mobilization (IASTM) interventions are not showing similar results. Although the IASTM methods use tools to treat the tissue, the methods and results are quite different from those of Astym therapy, and IASTM methods are often not well tolerated by patients.¹⁵ IASTM methods use tooled cross-friction massage to mechanically break apart the tissue,^{16,17} whereas Astym therapy engages the regenerative mechanisms of the body aiming to repair damaged tissue and resorb scar tissue.¹¹ To date, IASTM methods have been shown to (1) result in a significant increase in pain and a significant decrease in the perception of function,¹⁵ (2) have no positive effect in the treatment results for ankle injury,¹⁸ (3) be comparable to no treatment being provided in tendinopathy,¹⁹ and (4) not improve treatment results with tools, when compared with manual therapy alone.²⁰

To date, no publications have documented the use of Astym treatment on a patient with a chronic underlying neurological condition. The purpose of this case report was to describe the incorporation of Astym treatment to improve hamstring flexibility and Achilles tendinopathy in a child with cerebral palsy.

Case Description

This retrospective case report describes a physical therapy intervention utilizing an Astym therapy protocol for an eight-year-old female with a medical diagnosis of cerebral palsy referred to physical therapy for bilateral hamstring tissue tension and Achilles tendinopathy. The patient's primary complaint was pain and tightness in her thighs and calves. Functional limitations reported by the patient included bending/squatting, lifting/carrying, sitting/standing, reaching, pushing, pulling, activities of daily living (ADLs), and sleeping due to pain. Previous treatment interventions included use of

night splints and daytime in-shoe orthotics for several years. The patient had become noncompliant with these interventions due to pain.

Examination. Physical therapy documentation was obtained retrospectively. Upon initial examination, the patient ambulated into the facility independently with in-shoe orthotics. The patient's gait pattern presented with shortened stride length, lack of proper heel strike/toe-off, and weak quadriceps causing hyperextension during mid-stance bilaterally. Posture was observed as decreased lumbar lordosis with increased posterior pelvic tilt. The subject did not present with any abnormal restrictions to active motion of the hips, knees, and first metatarsophalangeal joints. Active ROM and passive ROM of bilateral ankles were restricted (see Table 1). Lower quarter myotomes and dermatomes were normal for bilateral lower extremities. No assessment of lower extremity reflexes was reported. The popliteal angle to assess hamstring flexibility was measured by extending the knee from a position of 90° flexion of the hip joint and measured at AROM 140° bilaterally via goniometric measurement. There was no tenderness to the palpation of tissues surrounding the Achilles tendon bilaterally. The patient subjectively reported her lower extremity pain ranged from 0 to 8 on a 10-point scale (0 being no pain and 10 being worst possible pain) and rated her pain at the time of the initial examination as 0/10. Based on the findings of examination, it was determined that the patient had decreased functional strength and lower extremity flexibility secondary to increased tone of cerebral palsy causing bilateral Achilles tendon pain.

Interventions. The patient was treated for 11 treatment sessions over an eight-week period. Each session followed the guidelines established for Astym therapy. Each treatment session began with a warm-up on a stationary bicycle for four to six minutes. This was followed by topical application of the instruments to the soft tissue structures of both lower extremities. The treatment was performed by applying instruments topically in a systematic pattern in order to deliver particular pressures and shear forces to the underlying dysfunctional tissue (see Fig. 1).¹¹ The speed of the strokes was delivered to optimize muscular tone relaxation. The patient reported that she tolerated the Astym treatments well, reporting after the first treatment that it *helped her legs relax*.

Astym therapy was followed by lower extremity stretching of the quadriceps in prone, hamstrings in supine with the knee, and hips in a 90/90 position, long sitting hamstrings stretch against the wall, standing gastrocnemius/soleus stretch, supine piriformis stretch, hip flexor stretch, and adductor stretch, with a hold time of 30–60 seconds for three sets each. As pain decreased and activity tolerance increased, the physical therapy treatments were progressed to aim toward improving functional strength. Therapeutic exercises were progressed based on pain tolerance and consisted of long arc quad, bear crawl, crab crawl, single leg balance activities while kicking a ball, and running mechanics to improve coordination, fluidity, and speed.

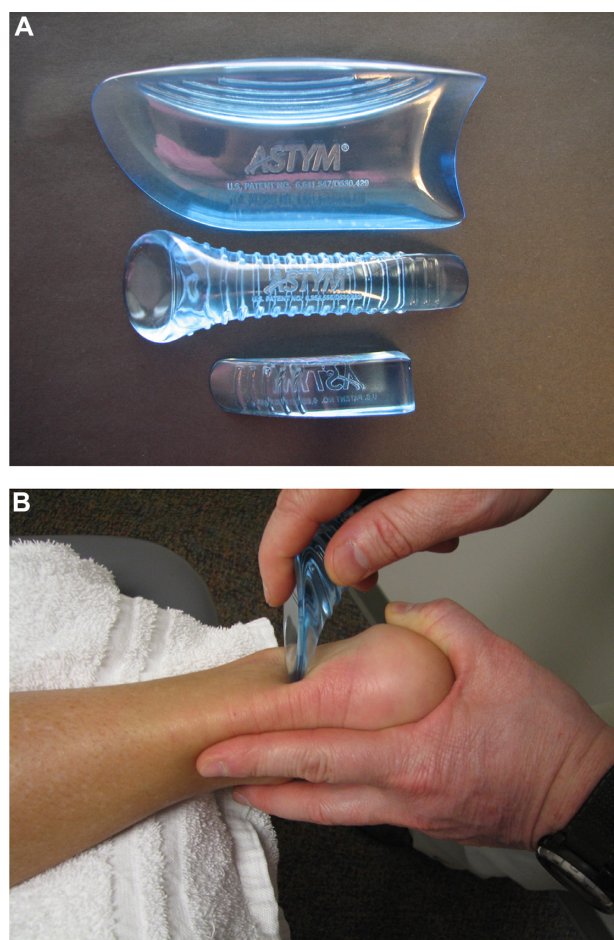


Figure 1. Astym[®] therapy instruments (A) and application (B). **Note:** Images supplied by Performance Dynamics, Inc., and used with their permission.

Outcomes

After eight weeks of physical therapy treatment, the patient demonstrated an improved popliteal angle from 140° to 165°. Bilateral ankle dorsiflexion AROM at 0° knee flexion increased from -5° to 5° and at 90° knee flexion increased from 0° to 5° without pain (see Table 1, discharge). The patient presented

Table 1. Range of motion.

	INITIAL		DISCHARGE	
	RIGHT	LEFT	RIGHT	LEFT
Ankle AROM				
Dorsiflexion at 90° knee flexion	-5°	-5°	5°	-5°
Dorsiflexion at 0° knee flexion	0°	0°	5°	5°
Plantarflexion	WNL	WNL	WNL	WNL
Inversion	WNL	WNL	WNL	WNL
Eversion	WNL	WNL	WNL	WNL
Ankle PROM				
Dorsiflexion at 0° knee flexion	0°	0°	0°	0°
Dorsiflexion at 90° knee flexion	10°	10°	10°	10°
90/90 Hamstring Flexibility	140°	140°	165°	165°

Abbreviation: WNL, within normal limits.

with improved resting muscle tone of the bilateral lower extremities, discontinued use of AFO devices, and improved gait pattern with even stride length and diminished genu recurvatum. Improved coordination with mechanics of running was demonstrated by improved fluidity and increased running speed to increase play with peers. The patient also reported decreased pain with standing and walking for approximately four consecutive hours and improved activity tolerance and overall function for ADLs at home, school, and within the community.

The patient and her mother demonstrated satisfaction with the rehabilitation protocol that was implemented and reported significant improvement in symptoms of decreased flexibility and pain. The improvement no longer necessitated the patient to rely on the use of AFO devices. Improved gait pattern was noted with even stride length, diminished genu recurvatum, and improved resting muscle tone. Enhanced coordination with mechanics of running was demonstrated by improved fluidity and increased running speed to increase play with peers. A subjective telephone follow-up two years after treatment did express continued positive functional status of the patient, suggesting possible long-term carry-over of the treatment intervention. However, there was no physical contact during the time frames between discharge and telephone follow-up to determine if the objective improvements were sustained.

Discussion

This case report demonstrated positive outcomes utilizing Astym therapy administered by an Astym-certified physical therapist for the treatment of decreased hamstring flexibility and Achilles tendinopathy in an eight-year-old female with a medical diagnosis of infantile cerebral palsy. The physical changes achieved following treatment allowed for improvement of gait, running mechanics, sit-to-stand transfers, and peer play. The patient was able to discontinue the use of AFO devices and showed improved quality of gait with equity in stride length and diminished genu recurvatum during ambulation. The results of this case report support the use of Astym therapy for the treatment of hamstring flexibility and Achilles tendinosis in a child with cerebral palsy. This is the first documentation of the clinical use of Astym therapy for the treatment of soft tissue dysfunction and restrictions for an individual with cerebral palsy.

Factors that likely contributed to the patient's positive outcomes include compliance to an appropriate home exercise program carried out by the patient and reinforced by the patient's mother and consistency in administration of the Astym protocol in the clinical environment. All treatment sessions were conducted by an experienced Astym-certified physical therapist, implementing an Astym protocol with optimal stroke speed for muscular relaxation to provide benefit in a child with cerebral palsy. Astym therapy has been previously shown to be effective in the treatment of soft tissue limitations. Literature has shown significant gains in function



for recreational athletes with soft tissue restriction of the hamstrings and Achilles tendinopathy.^{7,9} Astym therapy has been shown to be effective in improving ROM in patients with stiff knee/athrofibrosis following total knee arthroplasty.¹⁴ Studies have demonstrated significant improvements in symptoms within a notably shorter duration with the use of Astym treatment compared to an eccentric program alone in treating hamstring and Achilles tendinopathies.^{7,9,10} The results of this case demonstrate the positive treatment effects of Astym therapy in a young patient with cerebral palsy.

While this case study demonstrates the successful implementation of Astym therapy in a child with soft tissue dysfunction and a chronic neurological disease, several limitations to this research exist. Formal functional evaluation scales, such as lower extremity functional scale and the short-form 36, were not incorporated in the clinical evaluations of this patient, limiting the ability to compare the results of this case with those in the research literature that have used such evaluation criteria. Subjective assessments were made regarding gait characteristics, pain, muscle tone, and strength assessment. While an informal telephone follow-up was performed two years posttreatment, no formal long-term clinical assessment was made of the patient, thus limiting the objective assessment of the effects of Astym treatment. As with any single patient case report, the efficacy of the studied intervention in this case could not be compared to that of other treatment interventions. Future research is needed to objectively assess the long-term effects of an Astym protocol for children with cerebral palsy and compare the efficacy of Astym therapy to other appropriate treatment methods. Such studies should include objective measures of spasticity, strength, functional performance, and pain perception over the course of time to assess the long-term effects of Astym therapy for soft tissue dysfunction. A clinically controlled trial with an adequate sample size may provide results that may be generalizable to populations of various age, sex, and classifications of cerebral palsy.

Conclusions

Following an Astym therapy protocol incorporating eccentric exercise, stretching, strengthening, A/PROM, gait training, and a home exercise program over an eight-week period, the patient demonstrated significant gains in flexibility, functional strength, and discontinued use of AFO devices to allow for improved function of bilateral lower extremities. Upon discharge, the patient demonstrated improved gait pattern with even stride length and diminished genu recurvatum, decreased pain with standing and walking, and improved activity tolerance for ADLs at home, school, and within the community. The findings of this case report suggest that an Astym protocol can enhance the treatment of soft tissue restrictions, improve function in those with cerebral palsy, and ultimately provide improved quality of life. The results of this case study will be useful in future research for alternate and efficient interventions for the treatment of soft tissue dysfunction in individuals with cerebral palsy.

Acknowledgments

The authors wish to thank Tom Sevier, MD, and Benjamin Kivlan, PT, PhD, for their expert review of this article. The case presented in this paper was presented at the 2015 Combined Sections Meeting of the American Physical Therapy Association.

Author Contributions

Conceived and designed the experiments: NAS, LRA, RSV. Analyzed the data: NAS, LRA, RSV. Wrote the first draft of the manuscript: NAS, RSV. Contributed to the writing of the manuscript: NAS, RSV. Agree with manuscript results and conclusions: NAS, LRA, RSV. Jointly developed the structure and arguments for the paper: NAS, RSV. Made critical revisions and approved final version: NAS, LRA, RSV. All authors reviewed and approved of the final manuscript.

REFERENCES

1. Krigger KW. Cerebral palsy: an overview. *Am Fam Physician*. 2006;73(1):91–100.
2. Bailes A, Succop P. Factors associated with physical therapy services received for individuals with cerebral palsy in an outpatient pediatric medical setting. *Phys Ther*. 2012;92(11):1411–8.
3. Sharma R, Purohit A, RajinderaKumar E, Persson S, Sinha A, Tripathy S. Epidemiology of cerebral palsy in Jalandhar. *Indian J Physiother Occup Ther*. 2012;6(3):213–6.
4. Gagliano N, Menon A, Martinelli C, et al. Tendon structure and extracellular matrix components are affected by spasticity in cerebral palsy patients. *Muscles Ligaments Tendons J*. 2013;3(1):42–50.
5. Mathewson MA, Lieber RL. Pathophysiology of muscle contractures in cerebral palsy. *Phys Med Rehabil Clin N Am*. 2015;26(1):57–67.
6. Smith LR, Lee KS, Ward SR, Chambers HG, Lieber RL. Hamstring contractures in children with spastic cerebral palsy result from stiffer extracellular matrix and increased in vivo sarcomere length. *J Physiol*. 2011;589(pt10):2625–39.
7. McCormack JR. The management of bilateral high hamstring tendinopathy with ASTYM® treatment and eccentric exercise: a case report. *J Man Manip Ther*. 2012;20(3):142–6.
8. Wilson JK, Sevier TL, Helfst RH, Honing EW, Thomann AL. Comparison of rehabilitation methods in the treatment of patellar tendinitis. *J Sports Rehabil*. 2000;9(4):304–14.
9. McCormack JR. The management of mid-portion Achilles tendinopathy with Astym® and eccentric exercise: a case report. *Int J Sports Phys Ther*. 2012;7(6):672–7.
10. McCormack JR, Underwood FB, Slaven EJ, Cappaert TA. Eccentric exercise versus eccentric exercise and soft tissue treatment (Astym) in the management of insertional Achilles tendinopathy: a randomized controlled trial. *Sports Health*. May 2016; 8:230–7.
11. Sevier TL, Stegink-Jansen CW. Astym treatment vs eccentric exercise for lateral elbow tendinopathy: a randomized controlled clinical trial. *PeerJ*. 2015;3:e967.
12. Kivlan BR, Garcia CR, Clemente FR, Phelps AL, Martin RL. The effect of Astym® therapy on muscle strength: a blinded, randomized, clinically controlled trial. *BMC Musculoskelet Disord*. 2015;16(1):325.
13. Slaven EJ, Mathers J. Management of chronic ankle pain using joint mobilization and Astym® treatment: a case report. *J Man Manip Ther*. 2011;19(2):108–12.
14. Chughatai M, Mont MA, Cherian C, et al. Non-operative treatment demonstrates success for stiff total knee arthroplasty after failure of conventional therapy. *J Knee Surg*. 2016;29(3):188–93.
15. Vardiman JP, Siedlik J, Herda T, et al. Instrument-assisted soft tissue mobilization effects on the properties of human plantar flexors. *Int J Sports Med*. 2015;36(3):197–203.
16. Daniels CJ, Morrell AP. Chiropractic management of pediatric plantar fasciitis: a case report. *J Chiropr Med*. 2012;11(1):58–63.
17. Solecki TJ, Herbst EM. Chiropractic management of a postoperative complete anterior cruciate ligament rupture using a multimodal approach: a case report. *J Chiropr Med*. 2011;10(1):47–53.
18. Schaefer JL, Sandrey MA. Effects of a 4-week dynamic-balance training program supplemented with Graston instrument-assisted soft tissue mobilization for chronic ankle instability. *J Sports Rehabil*. 2012;21(4):313–26.
19. Blanchette MA, Normand MC. Augmented soft tissue mobilization vs. natural history in the treatment of lateral epicondylitis: a pilot study. *J Manipulative Physiol Ther*. 2011;34(2):123–30.
20. Burke J, Buchberger DJ, Carey-Loghmani MT, Dougherty PE, Greco DS, Dishman JD. A pilot study comparing two manual therapy interventions for carpal tunnel syndrome. *J Manipulative Physiol Ther*. 2007;30(1):50–61.