



# Recovery of Four COVID-19 Patients via Ozonated Autohemotherapy

Junping Wu,<sup>1,2,8</sup> Cherie S. Tan,<sup>3,8</sup> Hongzhi Yu,<sup>1,2,8</sup> Youwei Wang,<sup>3</sup> Yutao Tian,<sup>3</sup> Wenwei Shao,<sup>3</sup> Yifei Zhang,<sup>3</sup> Kuo Zhang,<sup>3</sup> Hongxia Shao,<sup>1,2</sup> Guangjian Ni,<sup>3,4,\*</sup> Jun Shen,<sup>1,\*</sup> Antonio Carlo Galoforo,<sup>5,6,\*</sup> Qi Wu,<sup>1,7,\*</sup> and Dong Ming.<sup>3,4,\*</sup>

<sup>1</sup>Tianjin Key Laboratory of Lung Regenerative Medicine, Haihe Hospital, Tianjin University, Tianjin 300350, China

<sup>2</sup>Department of Infection, Haihe Hospital, Tianjin University, Tianjin 300350, China

<sup>3</sup>Academy of Medical Engineering and Translational Medicine, Medical College, Tianjin University, Tianjin 300072, China

<sup>4</sup>Department of Biomedical Engineering, College of Precision Instruments and Optoelectronics Engineering, Tianjin University, Tianjin 300072, China

<sup>5</sup>University of Pavia, Pavia 271000, Italy

<sup>6</sup>Oxygen-Ozone Therapy Scientific Society (SIOT), Gorle 24020, Italy

<sup>7</sup>School of Clinical Medicine, Medical College, Tianjin University, Tianjin 300072, China

<sup>8</sup>These authors contributed equally

\*Correspondence: [niguangjian@tju.edu.cn](mailto:niguangjian@tju.edu.cn) (G.N.); [13902143866@163.com](mailto:13902143866@163.com) (J.S.); [antonio.galoforo@gmail.com](mailto:antonio.galoforo@gmail.com) (A.G.); [wq572004@163.com](mailto:wq572004@163.com) (Q.W.); [richardming@tju.edu.cn](mailto:richardming@tju.edu.cn) (D.M.)

<https://doi.org/10.1016/j.xinn.2020.100060>

© 2020 The Authors. This is an open access article under the CC BY-NC-ND license (<http://creativecommons.org/licenses/by-nc-nd/4.0/>).

Severe acute respiratory syndrome coronavirus 2 (SARS-CoV-2) is an enveloped RNA betacoronavirus,<sup>1</sup> that has spread globally since December 2019. As of July 22, 2020, more than 14,000,000 confirmed cases and 607,781 deaths from COVID-19 have been reported to the World Health Organization from 216 areas and territories.<sup>2</sup> Patients with more prominent laboratory abnormalities may develop acute respiratory distress syndrome (ARDS), which potentially leads to multiple organ failure and death.<sup>1,3</sup> However, at present, there are no regulatory approved antiviral medicines, vaccines, or specific clinical treatments for COVID-19.

Ozonated autohemotherapy has been reported to improve blood flow and tissue oxygenation to vital organs (Figure 1).<sup>4–6</sup> It also appears to stimulate the innate immune system by inducing the activation of nuclear factor activated T-cells (NFAT) and Activated Protein-1 (AP-1) signaling pathways,<sup>5</sup> besides being a strong anti-inflammatory and antioxidant molecule.<sup>5</sup> Early studies on severe acute respiratory syndrome coronavirus (SARS-CoV) and Middle East respiratory syndrome coronavirus (MERS-CoV) have shown increased amounts of proinflammatory cytokines and extensive lung damage in both SARS-CoV and MERS-CoV patients.<sup>6,7</sup> These findings indicate that ozonated autohemotherapy may be a new strategy to treat patients infected with betacoronaviruses. Therefore, we present, for the first time, a case series of 4 patients with different disease severities for whom ozonated autohemotherapy treatments were designed and implemented by a multidisciplinary team. The ozonated autohemotherapy clinical protocol was approved as a complementary therapy by the institutional review board of Tianjin University Haihe Hospital on February 16, 2020.

Four patients (age range, 56–77 years; 2 women) were treated with ozonated autohemotherapy. Two were smokers, and 3 of the 4 had no preexisting medical conditions (Table S1). All 4 patients received antiviral agents, comprising lopinavir/ritonavir and interferon-alpha, and 3 patients (patients 1, 2, and 3) were treated with steroids (Table S1).

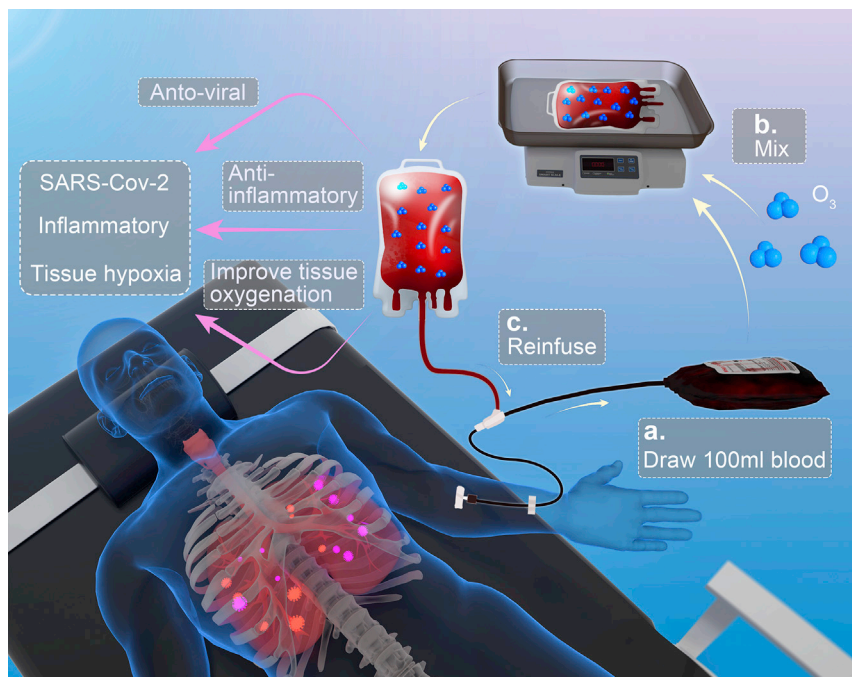
Upon admission, 2 of the 4 patients (patients 1 and 2) had fever, although no patient had a temperature above 39°C. Other symptoms included cough (patients 2 and 3), shortness of breath (patient 1), and diarrhea (patient 2). Patient 4 was asymptomatic; however, her oropharyngeal swab tested positive. Patient 1, after 9 days of hospitalization, developed ARDS with severe refractory hypoxemia and was admitted to the intensive care unit (ICU). Patient 2, on the second day after admission, developed respiratory distress (respiratory rate  $\geq 30$  breaths/min) and was considered to be in a severe medical condition, according to the Chinese Clinical Guidance for COVID-19 Pneumonia Diagnosis and Treatment seventh version by the Chinese Center for Disease Control and Prevention (the Chinese CDC).<sup>8</sup>

Complete blood count analyses, coagulation function assessment, blood biochemistry, and infection biomarkers were tested during hospitalization, and the worst values on the day prior to the ozonated autohemotherapy

were recorded (Table S1). By the time ozonated autohemotherapy treatment was initiated, all patients were receiving oxygen: patient 1 through a high-flow nasal cannula oxygen therapy (HFNC) and the remaining 3 patients with nasal catheter oxygen inhalation (NC) at an O<sub>2</sub> flow rate at 2 L/min. Depending on severity, the ozonated autohemotherapy with an O<sub>3</sub> concentration equal to 40  $\mu\text{g}/\text{mL}$  per 100 mL of blood was administered between 1 and 9 treatment sessions on the 4 patients.

The laboratory results of patient 2, 3, and 4 were assessed 3 days after their last ozonated autohemotherapy treatments. For the critically ill patient 1, the laboratory results on day 8 after the treatments were assessed following stabilization of the condition and a switch from HFNC to NC. The levels of C-reactive protein ranged from 18.3 to 300 mg/L and those of interleukin-6 ranged from 12.1 to 166.4 pg/mL prior to the treatments. These values both decreased substantially, with a range of 1.6–10.2 pg/mL and 1.5–7.1 pg/mL, respectively, after treatment. After treatment, the absolute lymphocyte count of patients 1 and 2 increased from 0.44 to 0.35  $\times 10^9/\text{L}$  to 1.78 and 0.79  $\times 10^9/\text{L}$ , respectively.

Our critically ill patient 1 underwent chest computed tomography (CT) scans on admission, which showed multiple bilateral ground-glass opacities with a total CT lung severity score of 6 out of 20 (Figure S1). Prior to receiving ozonated autohemotherapy, the chest CT and X-ray images of patient 1 showed that the bilateral ground-glass opacities of the lung fields were significantly increased, with thickening of the bronchovascular bundles and pleural effusion. While the patient was resting in bed, arterial blood gas analysis showed a partial pressure of arterial oxygen (PaO<sub>2</sub>) to the fraction of inspired oxygen (FiO<sub>2</sub>) (PaO<sub>2</sub>/FiO<sub>2</sub> [P/F] ratio) of 80 mm Hg. Ozonated autohemotherapy was administered to improve oxygen delivery and correct the hypoxemia. Ten minutes after the ozonated autohemotherapy was initiated, the P/F ratio increased to 192 mm Hg. The arterial blood gas analysis was tested at 2 h and 9 h after the first session of ozonated autohemotherapy, and the measured P/F ratios were 118 mm Hg and 106 mm Hg, respectively. After 3 more treatments on 2 consecutive days, the chest X-ray image showed improvement of the pulmonary lesions, and there were further improvements after all 9 treatment sessions had been completed (Figure S1). In patient 2 (severe) and patients 3 and 4 (moderate disease), P/F ratios were within the normal range. Ozonated autohemotherapy was performed once a day to stimulate antioxidative and antiviral responses. The clinical symptoms of these 3 patients were continually monitored, and the ozonated treatments were stopped and they were switched to oral medication and symptomatic treatment when their symptoms diminished. However, their P/F ratios did not improve markedly with the ozonated autohemotherapy treatments, but they did decrease. The exact therapeutic mechanism, antiviral effects, and the population in which this therapy is suitable for use should be further studied. This may help in



**Figure 1. Scheme of Ozonated Autohemotherapy for COVID-19 Patients** The ozonated autohemotherapy was performed in the form of intravenous infusion of ozonated blood. (A) The protocol consisted of drawing 100 ml of whole blood from the patient's antecubital vein into a standard plastic disposable blood collection bag containing the anticoagulant solution (25ml). (B) The blood was mixed with 100 ml of  $O_2/O_3$ , with an  $O_3$  concentration at  $40 \mu\text{g/ml}$  by Kastner-Praxisbedarf Ozomed® Universal. (C) The ozonated blood was then slowly re-infused into the same vein at 40 gtt/min or less during the first 5-minute infusion, and the infusion rate might rise up to 60~100 gtt/min depending on the patient response.

the complete utilization of ozonated autohemotherapy treatment in COVID-19 patients.

Furthermore, the younger sibling of our critically ill patient 1 (patient 5, a 53-year-old man), was diagnosed with COVID-19 and admitted to our hospital along with patient 1. Like patient 1, patient 5 was also treated with antiviral agents and steroids, but developed severe ARDS with a P/F ratio of 82 and a CT score of 6/20 on hospital day 7 (Figure S2). Patient 5 was then admitted to the ICU and received mechanical ventilation (MV) through an endotracheal tube and was on extracorporeal membrane oxygenation (ECMO) support. After 11 days of ECMO support, the refractory hypoxemia was resolved. Patient 5 continued treatment with MV until it was withdrawn on hospital day 29. After spending 18 days in the ICU, patient 5 was transferred to the COVID-19 general ward. He was then officially discharged to his home after spending a total of 56 days in the hospital. In this case series, these 2 critically ill patients (1 and 5) were siblings. They contracted the virus together and were admitted to the same hospital on the same day and received the same antiretroviral therapy. However, different lung protection treatments, ozonated autohemotherapy and ECMO, respectively, were initiated. The length of stay in the ICU (10 days) and length of stay in the hospital (30 days) were both significantly shorter for patient 1, who was treated with ozonated autohemotherapy. Furthermore, the overall medical cost for patient 1 was \$15,467 USD, but for his younger sibling patient 5 with ECMO and MV treatments, the overall hospitalization cost was \$139,935 USD.

The combination of ozonated autohemotherapy with antiretroviral therapy in this case series of 4 patients with COVID-19 with varied disease severities led to improvement of the expression of infection-related biomarkers, which may have resulted from the stimulation of the innate immune system by ozone. All 4 patients who received ozonated autohemotherapy, including the critically ill patient 1, patient 2 (severe), and patients 3 and 4 (moderate), were discharged from the hospital, and their durations of hospitalization were 30, 18, 13, and 27 days, respectively. All patients revisited the hospital after 1 month, and their CT scans showed that most of the lung lesions had resolved (Figures S1 and S3). Overall, there were no abnormalities in the follow-up visit after ozonated autohemotherapy administration, indicating that it is a safe treatment for COVID-19 patients.

We, thus, report the successful use of ozonated autohemotherapy to treat 4 COVID-19 patients, including 1 critically ill patient. Although the exact mechanism of action of ozonated autohemotherapy is less well characterized, amelioration of inflammation and tissue damage could play critical roles.<sup>9,10</sup>

Furthermore, ozonated autohemotherapy is not only a safe procedure without reperfusion damage but also a much more economical and practical treatment, and this may, thus, benefit the global COVID-19 patient population with refractory hypoxemia.

## REFERENCES

- Huang, C., Wang, Y., Li, X., et al. (2020). Clinical features of patients infected with 2019 novel coronavirus in Wuhan, China. *Lancet* **395**, 497–506.
- World Health Organization (2020). Coronavirus disease 2019 (COVID-19) situation report – 100. [https://www.who.int/docs/default-source/coronaviruse/situation-reports/20200429-sitrep-100-covid-19.pdf?sfvrsn=bbfbf3d1\\_2](https://www.who.int/docs/default-source/coronaviruse/situation-reports/20200429-sitrep-100-covid-19.pdf?sfvrsn=bbfbf3d1_2).
- Guan, W., Ni, Z., Hu, Y., et al. (2020). Clinical characteristics of coronavirus disease 2019 in China. *N. Engl. J. Med.* **382**, 1708–1720.
- Zaky, S., Fouad, E.A., and Kotb, H.I.M. (2011). The effect of rectal ozone on the portal vein oxygenation and pharmacokinetics of propranolol in liver cirrhosis (a preliminary human study). *Br. J. Clin. Pharmacol.* **71**, 411–415.
- Scassellati, C., Ciani, M., Galoforo, A.C., et al. (2020). Molecular mechanisms in cognitive frailty: potential therapeutic targets for oxygen-ozone treatment. *Mech. Ageing Dev.* **186**, 111210.
- Wong, C.K., Lam, C.W.K., Wu, A.K.L., et al. (2004). Plasma inflammatory cytokines and chemokines in severe acute respiratory syndrome. *Clin. Exp. Immunol.* **136**, 95–103.
- Mahallawi, W.H., Khabour, O.F., Zhang, Q., et al. (2018). MERS-CoV infection in humans is associated with a pro-inflammatory Th1 and Th17 cytokine profile. *Cytokine* **104**, 8–13.
- Chinese Center for Disease Control and Prevention (2020). Chinese clinical guidance for COVID-19 pneumonia diagnosis and treatment (2nd ed.). [http://www.chinacdc.cn/jkzt/crb/zl/szkb\\_11803/jszl\\_11815/202001/t20200123\\_211379.html](http://www.chinacdc.cn/jkzt/crb/zl/szkb_11803/jszl_11815/202001/t20200123_211379.html).
- An, W., Feng, H., Jia, X., et al. (2018). Ozone therapy ameliorates inflammation and endometrial injury in rats with pelvic inflammatory disease. *Biomed. Pharmacother.* **107**, 1418–1425.
- Chen, Z., Liu, X., Yu, G., et al. (2016). Ozone therapy ameliorates tubulointerstitial inflammation by regulating TLR4 in adenine-induced CKD rats. *Ren. Fail.* **38**, 822–830.

## ACKNOWLEDGMENTS

We thank the patients; the clinical staff who provided care to the patients; and Dr. Kemei Shi and Ms. Jie Han (Second Affiliated Hospital of Tianjin Medical University) for their helpful discussions. This work was supported by grants from the National Natural Science Foundation of China [No. 81970001], Tianjin Natural Science Foundation [20JCYBJC01250], and the Tianjin University COVID-19 Contingency fund [No. 2020XY-0059].

## SUPPLEMENTAL INFORMATION

Supplemental Information can be found online at <https://doi.org/10.1016/j.xinn.2020.100060>.