

Received: 2020.07.06

Accepted: 2020.09.08

Available online: 2020.09.23

Published: 2020.11.19

Comparison of Anterior and Posterior Decompressions in Treatment of Traumatic Thoracolumbar Spinal Fractures Complicated with Spinal Cord Injury

Authors' Contribution:

Study Design A
Data Collection B
Statistical Analysis C
Data Interpretation D
Manuscript Preparation E
Literature Search F
Funds Collection G

ADG 1 **Yilun Yao***
BCE 1 **Junwei Yan***
DF 2 **Fan Jiang**
BF 2 **Sheng Zhang**
ACE 1 **Junjun Qiu**

1 Department of Orthopedic Surgery, Nanjing First Hospital, Nanjing Medical University, Nanjing, Jiangsu, P.R. China
2 Department of Orthopedics, The First Affiliated Hospital of Nanjing Medical University, Nanjing, Jiangsu, P.R. China

* Yilun Yao and Junwei Yan contributed equally to this work

Corresponding Author: Junjun Qiu, e-mail: rainbowhueq@126.com

Source of support: Departmental sources

Background: For patients with thoracolumbar spinal fractures complicated with spinal cord injury, timely surgery is the first choice. We compared the effects of anterior and posterior decompressions in treatment of these patients.


Material/Methods: A total of 80 male patients with traumatic thoracolumbar spinal fractures and spinal cord injury were prospectively selected and divided into 2 groups. The control group underwent posterior decompression and internal fixation and the observation group underwent real-time anterior decompression.

Results: The observation group had longer operative time and length of postoperative hospital stay, larger intraoperative blood loss, remarkably greater immediate postoperative anterior height and middle column height of the fractured vertebrae, and a notably smaller Cobb's angle than in the control group. The total ASIA score was significantly higher in the observation group than in the control group immediately after surgery and at 6 months and 1 year after surgery. The maximal urine flow, maximal detrusor pressure, and bladder compliance were also evidently higher in the observation group than in the control group during 1 year of follow-up. Compared with the control group, the International Index of Erectile Function-5 (IIEF-5) score in the observation group was significantly higher at 3 months, 6 months, and 1 year after surgery.

Conclusions: Compared with the posterior approach, anterior decompression in patients with thoracolumbar spinal fractures complicated with spinal cord injury can effectually enhance the surgical efficiency, and restore the physiological anatomy of the fractured vertebrae, thereby improving patient quality of life.

MeSH Keywords: **Decompression • Quality of Life • Spinal Cord Injuries**

Full-text PDF: <https://www.medscimonit.com/abstract/index/idArt/927284>

 2779

 6

 2

 20



Background

As the transportation and construction industries are thriving with the progress of societal modernization, the incidence rate of thoracolumbar spinal fractures complicated with spinal cord injury is increasing [1]. Clinically, thoracolumbar fracture mainly refer to fractures of the T₁₁–L₂ spine. Thoracolumbar fractures are extremely common in orthopedic trauma and account for 5–6% of all fractures and 70–80% of spinal fractures. The T₁₁–L₂ spine is prone to burst fractures due to high-strength external forces since there are no supports from the ribs or the thoracic cage [2]. In addition, these vertebrae are also stress inversion points for the movement and fixation of thoracolumbar segments, which have higher risks of neurological injury once thoracolumbar fractures occur [3].

The thoracolumbar spinal cord is anatomically different from the cauda equina in the upper segment (thoracic vertebrae) and the lower segment (lumbar vertebrae) [4]. Both thoracic vertebrae and lumbar vertebrae are vulnerable under the influence of external forces, and have a high risk of cone and cauda equina injury that will cause lower-extremity sensory and motor function impairment, urinary and sexual dysfunction, and even paraplegia [5]. Thoracolumbar spine fracture with spinal injury and its complications, such as bilateral paralysis, urinary tract infection, and sexual dysfunction, have brought great pressure and economic burden to families and society. For these patients, timely surgery is the first choice [6], which includes anterior decompression and posterior decompression in terms of surgical approaches [7].

In this study, we assessed the application of anterior and posterior decompressions in patients with thoracolumbar spinal fractures complicated with spinal cord injury. The primary purpose was to investigate the effects of anterior and posterior decompressions on Cobb's angle, vertebral body height compression rate, and quality of life in patients with traumatic thoracolumbar spinal fractures complicated with spinal cord injury.

Material and Methods

General data

We prospectively enrolled 80 male patients definitively diagnosed with traumatic thoracolumbar spinal fractures and spinal cord injury based on clinical manifestations and imaging examination results before enrollment and treated in our hospital from January 2017 to January 2019. All patients signed informed consent before enrollment. This study was approved by the Ethics Committee of Nanjing First Hospital. The inclusion criteria were: 18–50-year-old male patients with 1 thoracolumbar vertebra fractured and obvious spinal cord injury

and effective cooperation during the 1-year follow-up. The exclusion criteria were: patients with a history of prostate- and urinary system-related diseases, osteoporosis, malignant tumors, ankylosing spondylitis, general multiple injuries, or unstable vital signs, and those complicated with craniocerebral trauma, severe heart, liver or kidney dysfunction, or mental illness, 2 and more than 2 thoracolumbar vertebra fractured. The patients were divided into a control group (n=40) and an observation group (n=40) using a random number table. Control group and observation group were treated with the posterior decompression and internal fixation, and the real-time anterior decompression, respectively. The observation group patients were 18–50 years old, with a mean of 41.5±2.6 years old. The causes of injury included traffic accidents in 11 cases, heavy object crashing in 4 cases, and falling down in 25 cases. In terms of Frankel grade for spinal cord injury, there were 32 cases of grades B and C and 8 cases of grades D and E. The time interval from injury to surgical intervention was 4–24 h, with an average of 10.1±0.3 h. In the control group, the patients were 18–50 years old, with a mean of 41.6±2.5 years old, and the injuries were caused by traffic accidents in 12 cases, heavy object crashing in 4 cases, and falling down in 24 cases. Frankel grades B and C were found in 31 patients, while Frankel grades D and E were detected in 9 patients. The time interval from injury to surgical intervention was 4–24 h, with an average of (10.0±0.4) h. The age, cause of injury, Frankel grade for spinal cord injury, and time interval from injury to surgical intervention showed no statistically significant differences between the 2 groups (*P*>0.05).

Methods

All enrolled patients received surgical intervention following endotracheal intubation under general anesthesia. As to surgical approaches, posterior decompression combined with internal fixation was applied in the control group. Specifically, the patients were kept in the prone position during the operation, with the waist raised, fixed, and suspended. Firstly, the fractured vertebrae were positioned by C-arm fluoroscopy. Then, with the fractured vertebrae as the center, a longitudinal incision was made along the posterior midline in the chest and back, followed by blunt dissection layer-by-layer to expose the fractured vertebrae and the spinous processes of the adjacent upper and lower vertebral bodies. Next, with the pedicle of the adjacent vertebral bodies as the support, pedicle screws were placed through the “people” shape crest method, and the laminae of fractured vertebrae were removed. For patients complicated with spinal cord compression, fractured fragments were properly cleaned to relieve spinal cord compression. Afterwards, rods were placed and connected to the pedicle screws. Thereafter, a retractor was used for reduction to restore the normal physiological curvature of the spine. C-arm fluoroscopy was repeated to confirm the outcomes of

Table 1. Analysis of surgical conditions in the 2 groups.

	Operative time (min)	Intraoperative blood loss (mL)	Length of postoperative hospital stay (d)
Observation group	166.6±31.6	416.9±45.9	9.5±1.3
Control group	135.1±21.1	248.0±32.7	6.7±0.6
t	5.243	18.955	12.368
P	<0.001	<0.001	<0.001

surgeries. In the observation group, real-time anterior decompression was performed. During the operation, the patients were kept in right lateral position. Next, through the extrapleural and extraperitoneal approach, blunt separation was done along the outer margin of paravertebral muscles to expose the fractured vertebrae (partial ribs were removed if necessary). Subsequently, the bone fragments in the spinal canal were carefully cleaned to relieve the compression and injury of the spinal cord. Then, were determined the line between the intervertebral foramen of the fractured vertebrae and adjacent normal vertebral bodies, and the height of the titanium mesh cage to be implanted. Next, a bone slot (8–10 mm) was made at the anterior edge of the fractured vertebrae. After that, with the slot as a reference, screws were inserted into vertebral bodies, and anterior orthopedic internal fixators were planted. Next, reduction through distraction of the interbody space was also carried out, and the titanium mesh cage was implanted after bone grafting to strengthen the internal fixation. Following rigid fixation of all appliances, the surgical efficacy was confirmed by C-arm fluoroscopy.

Observation indexes

The surgical conditions and changes in the immediate postoperative anterior height and middle column height of fractured vertebrae and Cobb's angle were compared between the 2 groups. In addition, the recovery of nerve function of lower extremities and the changes in the total American Spinal Injury Association (ASIA) score were recorded during follow-up. At 1-year follow-up, the autonomous micturition ability indexes and International Index of Erectile Function-5 (IIEF-5) score were compared between the 2 groups of patients. Moreover, the changes in modified Barthel Index score before and after operation and complications during the follow-up were compared between the 2 groups.

Evaluation criteria

The ASIA score was used to assess the overall recovery of lower-extremity function, with a total score ranging from 0 points to 100 points. A higher score indicated better overall function of lower extremities. The time of lower-extremity sensory and

motor function recovery was based on the indicators in the ASIA scale. The autonomous micturition ability indexes include maximal urine flow, maximal detrusor pressure, and bladder compliance. Erectile function in sexual function was evaluated by the IIEF-5 scale, with the highest score of 25 points. Twenty-one points or above indicated normal, while 5 points (the lowest score) implied severe impotence. The higher the score, the more ideal the erectile function. Quality of life was assessed by the modified Barthel Index, with a total score of 0–100 points. A higher score suggests better quality of life.

Statistical analysis

Statistical Product and Service Solutions (SPSS) 20.0 (IBM, Armonk, NY, USA) was used for statistical processing. Measurement data were expressed as mean±standard deviation ($\bar{x}\pm s$). The *t* test was used for comparison of the mean between 2 groups, and the chi-square χ^2 test was used for comparison of the ratio between 2 groups. $P<0.05$ suggested that the difference was statistically significant.

Results

Analysis of surgical conditions in the 2 groups

The operative time and length of postoperative hospital stay were longer in the observation group than in the control group ($P<0.05$), and the intraoperative blood loss was larger in the observation group than in the control group ($P<0.05$) (Table 1).

Comparisons of immediate postoperative anterior height and middle column height of fractured vertebrae and Cobb's angle

The immediate postoperative anterior height and middle column height of fractured vertebrae were significantly greater ($P<0.05$) and the Cobb's angle was remarkably decreased in the observation group compared with the control group ($P<0.05$) (Table 2).

Table 2. Comparisons of immediate postoperative anterior height and middle column height of fractured vertebrae and Cobb's angle.

	Anterior height of fractured vertebrae (mm)	Middle column height of fractured vertebrae (mm)	Cobb's angle (°)
Observation group	24.5±1.8	19.6±1.2	2.5±0.3
Control group	16.6±0.9	8.7±0.8	8.9±1.6
t	24.827	47.800	24.865
P	<0.001	<0.001	<0.001

Table 3. Recovery of lower-extremity nerve functions during hospitalization.

	Time of lower extremity sensory function recovery	Time of lower extremity motor function recovery
Observation group	13.6±1.1	23.1±2.3
Control group	25.7±2.3	43.9±6.6
t	30.016	18.821
P	<0.001	<0.001

Recovery of lower-extremity nerve functions during follow-up

The observation group had a significantly shorter lower-extremity sensory and motor function recovery in comparison with the control group during follow-up ($P<0.05$) (Table 3).

Changes in total ASIA score during 1 year of follow-up

Before the operation, immediately after the operation, and at 6 months and 1 year after the operation, the total ASIA score was (1.9±0.1) points, (33.6±2.8) points, (55.8±5.8) points and (76.8±13.8) points, respectively, in the observation group, and (2.0±0.1) points, (15.7±1.3) points, (38.9±3.9) points, and (49.6±8.3) points, respectively, in the control group. In contrast with the control group, the observation group exhibited a markedly elevated total ASIA score immediately after the operation and at 6 months and 1 year after the operation ($t=36.672$, $t=15.293$, and $t=10.682$, $P=0.000<0.05$) (Figure 1).

Comparisons of autonomous micturition ability indexes during 1 year of follow-up between the 2 groups

The maximal urine flow, maximal detrusor pressure, and bladder compliance were distinctly higher in the observation group than in the control group during 1 year of follow-up ($P<0.05$) (Table 4).

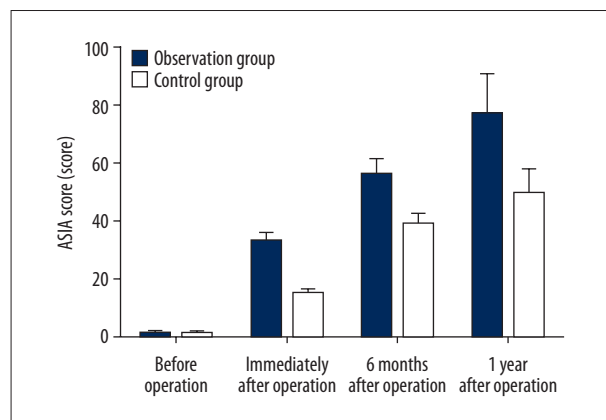


Figure 1. Changes in total ASIA score during 1 year of follow-up.

Changes in IIEF-5 score during 1 year of follow-up in the 2 groups

The IIEF-5 score was significantly higher in the observation group than in the control group at 3 months, 6 months, and 1 year after the operation [(8.8±0.3) points vs. (5.5±0.3) points, (13.2±1.0) points vs. (8.9±0.9) points, and (21.0±1.6) points vs. (12.5±1.1) points] ($t=26.654$, $t=20.214$, and $t=27.687$, $P=0.000<0.05$) (Figure 2).

Comparison of modified barthel index score between the 2 groups before and after the operation

The modified Barthel Index score showed no statistically significant difference between the 2 groups before the operation ($P>0.05$), but it was evidently higher in the observation

Table 4. Comparisons of autonomous micturition ability indexes at 1 year after follow-up between the 2 groups.

	Maximal urine flow (mL/s)	Maximal detrusor pressure (cmH ₂ O)	Bladder compliance (cmH ₂ O)
Observation group	15.1±1.8	36.6±3.5	20.5±2.7
Control group	6.1±0.7	21.6±0.8	13.5±0.7
t	29.472	26.424	15.872
P	<0.001	<0.001	<0.001

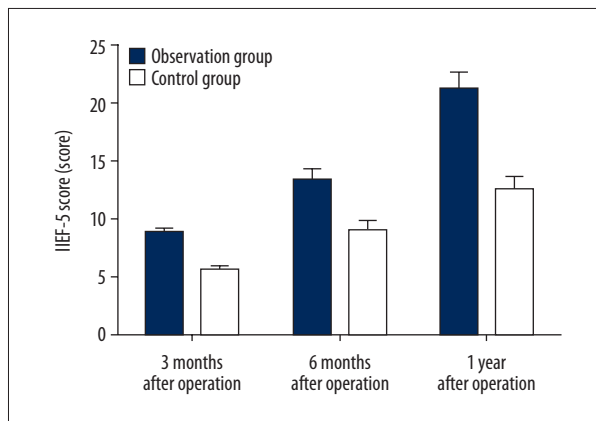


Figure 2. Changes in IIEF-5 score during 1 year of follow-up in the 2 groups.

group than in the control group after the operation ($P<0.05$). Moreover, in the observation group, the modified Barthel Index score was significantly increased after the operation compared with before the operation ($P<0.05$) (Table 5).

Comparisons of complications between the 2 groups during 1 year of follow-up

During the 1-year follow-up, the observation group had a clearly lower total incidence rate of complications (loosening of internal fixation, degeneration of adjacent vertebral bodies and intractable low back pain) than in the control group ($P<0.05$) (Table 6). All patients with those complications were treated appropriately.

Discussion

Thoracolumbar spinal fractures complicated with spinal cord injury severely negatively impact the quality of life of patients [8,9]. The T₁₁-L₂ spine segment is the intersection of physiological curvature of the thoracic and lumbar vertebrae, with concentrated stress, a small range of motion, and a narrow spinal canal, which has a high risk of spinal cord and/or cauda equina injury after fractures [10]. Spinal cord and cauda equina injuries result in limb sensory and motor dysfunction

Table 5. Comparison of modified Barthel Index score between the 2 groups before and after operation.

	Before operation	After operation	t	P
Observation group	11.1±0.3	76.2±5.6	73.418	<0.001
Control group	11.2±0.3	43.6±2.5	81.382	<0.001
t	1.491	33.620	–	–
P	0.140	<0.001	–	–

Table 6. Comparisons of complications between the 2 groups during 1 year of follow-up.

	Loosening of internal fixation	Degeneration of adjacent vertebral bodies	Intractable low back pain	Total incidence rate
Observation group	1	1	2	4 (10.0%)
Control group	5	3	11	19 (47.5%)
χ^2	–	–	–	11.960
P	–	–	–	0.001

or even paralysis [11]. As to treatment, timely surgery is mainly applied to attenuate spinal cord compression, stabilize fractures, and maintain anatomical structure [12]. The efficacy of surgery has been effectively increased with the continuous development of modern medical technology and the improvement of medical equipment. In addition to the cause of injury, the timing of surgery and the choice of surgical approaches also influence the prognosis [13]. Posterior decompression, often used in the past, is mature and results in less trauma, but it cannot efficaciously attenuate the anterior compression of the spinal cord, thereby affecting the prognosis [14]. Anterior decompression, an effective surgery used in clinical practice in recent years, can improve the therapeutic outcomes and prognosis.

In this study, traditional posterior decompression was used for the treatment of thoracolumbar spinal fractures complicated with spinal cord injury in the control group, while anterior decompression was used in observation group. Next, the surgical conditions were compared between the 2 groups, and it was discovered that observation group had longer operative time and length of postoperative hospital stay and larger intraoperative blood loss than in the control group. This indicated that for patients with thoracolumbar spinal fractures complicated with spinal cord injury, anterior decompression is difficult to conduct, requires relatively long operative time, and leads to relatively large blood loss. However, anterior decompression is still recommended by some scholars after the technology is mature. Based on the comparisons of immediate postoperative anterior height and middle column height of fractured vertebrae and Cobb's angle, the immediate postoperative anterior height and middle column height of fractured vertebrae were obviously higher in the observation group than in the control group, while the Cobb's angle was significantly smaller in the observation group than in the control group. Anterior decompression used in patients with thoracolumbar spinal fractures complicated with spinal cord injury performs better in restoring the vertebral body height to equilibrate the proportion of "axial load sharing". In addition, the recovery of lower-extremity nerve functions was compared during follow-up. The results showed that the observation group had a clearly shorter lower-extremity sensory and motor function recovery than in the control group. Comparisons of changes in the total ASIA score during the 1-year follow-up showed that the total ASIA score was clearly higher in the observation group than in the control group immediately after the operation and at 6 months and 1 year after the operation. The above results suggest that anterior decompression can better relieve spinal cord compression and improve lower-extremity nerve functions of patients with thoracolumbar spinal fractures complicated with spinal cord injury.

We compared the autonomous micturition ability indexes and IIEF-5 scores between the 2 groups at during 1 year of follow-up. The results revealed that in comparison with the control group, the observation group had remarkably higher maximal urine flow, maximal detrusor pressure, and bladder compliance, as well as a notably higher IIEF-5 score at 3 months, 6 months, and 1 year after the operation, indicating that anterior decompression significantly improves the autonomous micturition ability and sexual function of patients with thoracolumbar spinal fractures complicated with spinal cord injury. Finally, the changes in modified Barthel Index score before and after the operation and complications were recorded in the 2 groups. The modified Barthel Index score in the observation group was markedly increased after the operation compared with before the operation, and it was also prominently higher than in the control group after the operation. Additionally, the observation group had a dramatically lower total incidence rate of complications (loosening of internal fixation, degeneration of adjacent vertebral bodies, and intractable low back pain) than in the control group. All patients with those long-term complications were treated accordingly. These results further demonstrated that anterior decompression significantly improves the quality of life of patients with thoracolumbar spinal fractures complicated with spinal cord injury and results in fewer complications, thereby achieving reliable outcomes.

In the present study, anterior decompression was carried out in patients in the observation group, during which internal fixation was performed by implantation of titanium mesh filled with cancellous bone of injured vertebrae [15], and combined with a screw-rod system for spine reconstruction [16]. Anterior decompression is characterized by high fusion and strong stability [17]. Moreover, during anterior decompression, bone fragments in the spinal canal can be completely removed under direct vision [18], effectively alleviating spinal cord compression and avoiding the iatrogenic damage to the spinal cord caused by distraction during posterior decompression [19]. Anterior decompression the advantages of clear exposure during surgery, accurate decompression effect, small trauma, and fast fusion of factured vertebrae after surgery [20]. Compared with other similar research [7,11,15], the novelty of our study is that we showed anterior decompression effectually enhances the surgical outcomes, restores the physiological anatomy of fractured vertebrae, improves the postoperative nerve functions, and accelerates the recovery of urinary and sexual functions in patients with thoracolumbar spinal fractures complicated with spinal cord injury, which can improve their quality of life.

Conclusions

Compared with the posterior approach, anterior decompression can effectually enhance surgical outcomes, restore the

physiological anatomy of fractured vertebrae, improve postoperative nerve functions, and accelerate recovery of urinary and sexual functions in patients with thoracolumbar spinal fractures complicated with spinal cord injury, thereby improving their quality of life with less complications. The anterior approach has its own disadvantages, difficulties, and complications, such

as difficult surgical area exposure, protection of the segmental blood supply, and longer learning curve.

Conflict of interests

None.

References:

1. van Den Hauwe L, Sundgren PC, Flanders AE: Spinal trauma and spinal cord injury (SCI). In: *Diseases of the Brain, Head and Neck, Spine 2020–2023: Diagnostic Imaging*. Cham (CH): Springer; 2020; Chapter 19: 231–40
2. Diotalevi L, Bailly N, Wagnac E, Mac-Thiong JM et al: Dynamics of spinal cord compression with different patterns of thoracolumbar burst fractures: Numerical simulations using finite element modelling. *Clin Biomech (Bristol, Avon)*, 2020; 72: 186–94
3. Lai PJ, Liao JC, Chen LH, Lai PL: Tuberculous spondylitis after percutaneous vertebroplasty: A case series of 9 cases. *Biomed J*, 2019; 42: 285–92
4. Ahn Y: Current techniques of endoscopic decompression in spine surgery. *Ann Transl Med*, 2019; 7: S169
5. Vaccaro AR, Nachwalter RS, Klein GR et al: The significance of thoracolumbar spinal canal size in spinal cord injury patients. *Spine (Phila Pa 1976)*, 2001; 26: 371–76
6. Seo Y, Shin WB, Bae HW, Yoon JS: Effects of orbital decompression on lamina cribrosa depth in patients with Graves' orbitopathy. *Korean J Ophthalmol*, 2019; 33: 436–45
7. Jiang Y, Wang F, Yu X et al: A comparative study on functional recovery, complications, and changes in inflammatory factors in patients with thoracolumbar spinal fracture complicated with nerve injury treated by anterior and posterior decompression. *Med Sci Monit*, 2019; 25: 1164–68
8. Heary RF, Salas S, Bono CM, Kumar S: Complication avoidance: Thoracolumbar and lumbar burst fractures. *Neurosurg Clin N Am*, 2006; 17: 377–88
9. Schurch B, Schmid DM, Kaegi K: Value of sensory examination in predicting bladder function in patients with T₁₂–L₁ fractures and spinal cord injury. *Arch Phys Med Rehabil*, 2003; 84: 83–89
10. Head J, Rymarczuk G, Stricsek G et al: Ossification of the posterior longitudinal ligament: Surgical approaches and associated complications. *Neurospine*, 2019; 16: 517–29
11. Yuksel MO, Gurbuz MS, Is M, Somay H: Is the thoracolumbar injury classification and severity score (TLICS) superior to the AO thoracolumbar injury classification system for guiding the surgical management of unstable thoracolumbar burst fractures without neurological deficit? *Turk Neurosurg*, 2018; 28: 94–98
12. Heyer JH, Perim DA, Amdur RL, Pandarinath R: Impact of smoking on outcomes following knee and shoulder arthroscopy. *Eur J Orthop Surg Traumatol*, 2020; 30: 329–36
13. Dhall SS, Wadhwa R, Wang MY et al: Traumatic thoracolumbar spinal injury: An algorithm for minimally invasive surgical management. *Neurosurg Focus*, 2014; 37: E9
14. Shin KJ, Lee SH, Ha TJ et al: Position and size of the sphenoid door jamb in the lateral orbital wall for the orbital decompression. *Anat Cell Biol*, 2019; 52: 242–49
15. Machino M, Yukawa Y, Ito K et al: Posterior/anterior combined surgery for thoracolumbar burst fractures – posterior instrumentation with pedicle screws and laminar hooks, anterior decompression and strut grafting. *Spinal Cord*, 2011; 49: 573–79
16. Sharma S, Singh D, Singh M et al: Single screw-rod anterior instrumentation for thoracolumbar burst fractures with incomplete neurological deficit. *J Orthop Surg (Hong Kong)*, 2013; 21: 71–76
17. Allain J: Anterior spine surgery in recent thoracolumbar fractures: An update. *Orthop Traumatol Surg Res*, 2011; 97: 541–54
18. Casper DS, Schroeder GD, McKenzie J et al: Medicaid reimbursement for common spine procedures: Are compensation rates consistent? *Spine (Phila Pa 1976)*, 2019; 44: 1585–90
19. Smits AJ, Noor A, Bakker FC et al: Thoracoscopic anterior stabilization for thoracolumbar fractures in patients without spinal cord injury: Quality of life and long-term results. *Eur Spine J*, 2018; 27: 1593–603
20. Hurst SA, Gregory TM, Reilly P: Os acromiale: A review of its incidence, pathophysiology, and clinical management. *EFORT Open Rev*, 2019; 4: 525–32