

## Ocular decompression retinopathy following intracameral bevacizumab injection in a case of proliferative diabetic retinopathy with neovascular glaucoma

*Shubakar Reddy, Shreyansh Doshi,  
Avinash Pathengay, Bhavik Panchal*

A 49-year-old diabetic female was diagnosed to have both eyes proliferative diabetic retinopathy (PDR) and neovascular glaucoma (NVG [rubeosis stage in the right

eye and angle-closure stage in the left eye]). The right eye anterior and posterior segment new vessels regressed 2 weeks following intravitreal bevacizumab (IVB) injection. The left eye fundus revealed fibrovascular proliferation (FVP) for which panretinal photocoagulation (PRP) was started and subsequently intracameral bevacizumab (ICB) was injected. Following this intervention, the left eye new vessels of iris regressed but fundus showed multiple peripapillary white-centered intraretinal and subhyaloid hemorrhage suggestive of decompression retinopathy. Ocular decompression retinopathy presents as retinal hemorrhages following the acute lowering of the intraocular pressure (IOP). This case describes the rare occurrence of ocular decompression retinopathy following ICB in a case of PDR with NVG.

**Key words:** Decompression retinopathy, intracameral bevacizumab, neovascular glaucoma

Ocular decompression retinopathy occurs when intraocular pressure (IOP) is lowered suddenly after trabeculectomy and other surgical or medical procedures.<sup>[1-3]</sup> It has also been reported after paracentesis for uveitic glaucoma.<sup>[4]</sup> The sudden lowering of IOP increases the choroidal and retinal blood flow beyond the control of retinal autoregulation causing features

This is an open access journal, and articles are distributed under the terms of the Creative Commons Attribution-NonCommercial-ShareAlike 4.0 License, which allows others to remix, tweak, and build upon the work non-commercially, as long as appropriate credit is given and the new creations are licensed under the identical terms.

**For reprints contact:** reprints@medknow.com

**Cite this article as:** Reddy S, Doshi S, Pathengay A, Panchal B. Ocular decompression retinopathy following intracameral bevacizumab injection in a case of proliferative diabetic retinopathy with neovascular glaucoma. Indian J Ophthalmol 2020;68:1206-9.

| Access this article online  |  |
|---|--|
| <b>Quick Response Code:</b>   | <b>Website:</b><br>www.ijo.in          |
|  | <b>DOI:</b><br>10.4103/ijo.IJO_1401_19 |
|   |  |

LV Prasad Eye Institute, Hanumanthawaka Junction, GMR Varalakshmi Campus, Visakhapatnam, Andhra Pradesh, India

**Correspondence to:** Dr. Shreyansh Doshi, LV Prasad Eye Institute, 11-113/1, Hanumanthawaka Junction, GMR Varalakshmi Campus, Visakhapatnam - 530 040, Andhra Pradesh, India. E-mail: shreyansh.doshi87@gmail.com

Received: 30-Jul-2019

Revision: 03-Oct-2019

Accepted: 25-Dec-2019

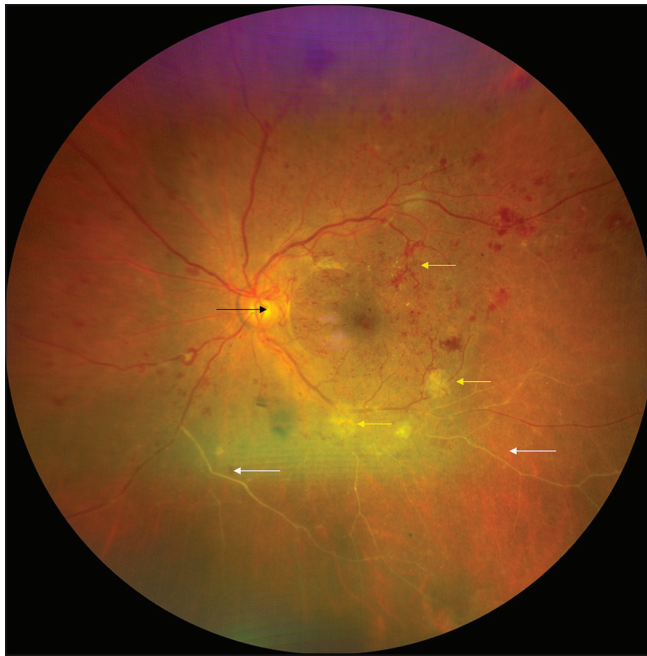Published: 25-May-2020

of decompression retinopathy such as retinal hemorrhages, disc hyperemia, and rarely exudative retinal detachment and choroidal detachment.<sup>[5]</sup> Herein, we would like to report a case of ocular decompression retinopathy following paracentesis

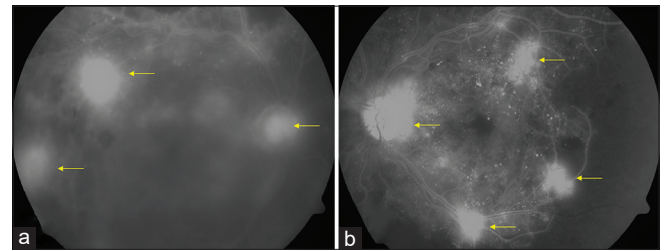
and intracameral bevacizumab (ICB) injection in neovascular glaucoma with PDR.

## Case Report

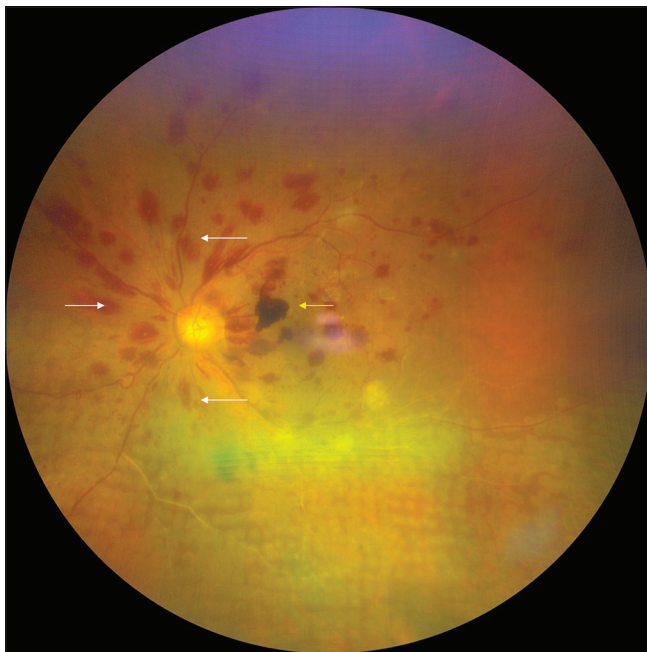
A 49-year-old diabetic female presented with a painful diminution of vision in the left eye for 10 days. On examination, her best-corrected visual acuity was 20/50p N18 in the right eye and 20/40p N6 in the left eye. Both eyes anterior segment examination showed a clear cornea while gonioscopy showed right eye open angles with neovascularization of the angle (NVA) in one quadrant whereas the left eye showed 360° closed angles, florid neovascularization of iris (NVI) with NVA in 2 quadrants. IOP in the right eye was 18 mmHg and in the left eye, it was 42 mmHg. Nuclear and posterior subcapsular cataract was seen in both eyes. Fundus examination of the right eye showed multiple dot-blot hemorrhages and flat neovascularization elsewhere (NVE) while the left eye showed elevated fibrovascular proliferation (FVP) near the disc, multiple flat NVE, multiple dot-blot hemorrhages, and inferior 180° sclerosed vessels [Fig. 1]. Both eyes showed healthy optic discs and no macular edema. Fundus fluorescein angiography



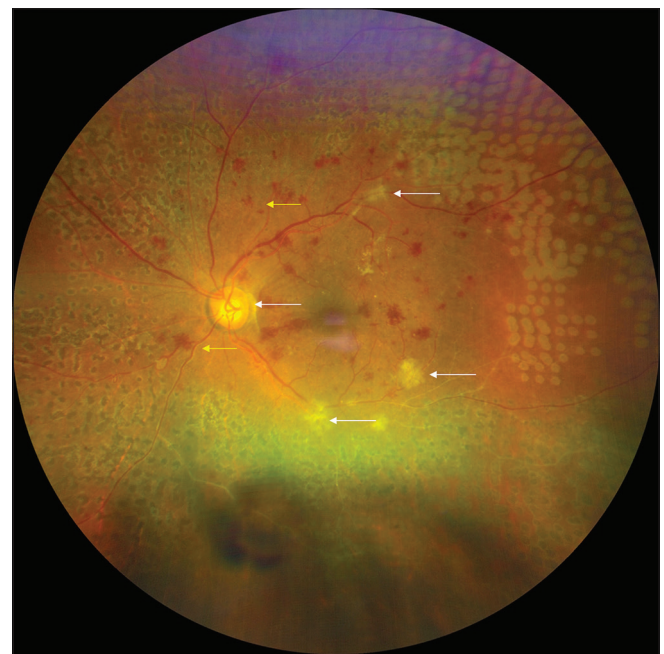
**Figure 1:** The left eye fundus photo shows fibrovascular proliferation at the disc (black arrow), multiple new vessels along inferotemporal and superotemporal arcades (yellow arrows), inferior sclerosed vessels (white arrows), and intraretinal hemorrhages in all quadrants with no macular edema



**Figure 2:** Fundus fluorescein angiography of both eyes performed at the primary visit confirms the presence of new vessels at the disc and elsewhere (yellow arrows). (Right eye: a, Left eye: b)



**Figure 3:** Three days following left eye intracameral bevacizumab injection, left eye fundus shows multiple white-centered intraretinal hemorrhages in the peripapillary area (white arrows) with localized subhyaloid hemorrhage at the fovea (yellow arrow) and inferior 180° laser marks



**Figure 4:** Two months following the initial visit the left eye fundus shows partial resolution of the peripapillary hemorrhages (yellow arrows), 360° laser marks with partial regression of the new vessels (white arrows)

confirmed the presence of new vessels in both eyes Fig. 2]. Thus, a diagnosis of both eyes senile cataract, PDR, and neovascular glaucoma (NVG [rubeosis stage in the right eye and closed-angle stage in left eye]) with left eye inferior old branch retinal vein occlusion was made.

The patient was injected with intravitreal bevacizumab (IVB - 1.25 mg/0.05 mL) in the right eye but in view of the elevated FVP in the left eye, IVB was avoided and left eye first sitting of panretinal photocoagulation (PRP) was done in the inferior quadrant. Subsequently, the patient was started on oral and topical antiglaucoma medications (AGM) in both eyes (a combination of brimonidine tartrate 0.2% with brinzolamide 0.1% two times/day, a combination of travoprost 0.004% and timolol maleate 0.5% at night and oral acetazolamide 250 mg three times/day). Two days later, the left eye IOP was still raised at 38 mmHg and the cornea showed microcystic edema not allowing for further PRP sittings. At this visit, anterior chamber paracentesis with intracameral bevacizumab (ICB - 1.25 mg/0.05 mL) injection was performed for the left eye.

Three days following left eye ICB the visual acuity dropped to 20/200 N36, the corneal edema persisted and IOP was measured as 58 mmHg. The NVI had regressed completely and there was no hyphema but the fundus examination revealed multiple peripapillary white-centered flame-shaped and dot retinal hemorrhages with two patches of subhyaloid hemorrhage at the fovea along with inferior PRP marks [Fig. 3]. These peripapillary hemorrhages were not seen prior to the left eye intraocular intervention suggesting ocular decompression retinopathy following sudden and transient lowering of IOP during anterior chamber paracentesis prior to the ICB injection.

Despite regression of the left eye NVI and keeping the patient on maximum medical antiglaucoma therapy, the IOP was persistently raised. Thus, 6 days following the ICB injection the patient underwent left eye mitomycin C-augmented trabeculectomy with repeat ICB injection (1.25 mg/0.05 mL). Following the surgical intervention, vision improved to 20/125, cornea cleared and IOP normalized to 12 mmHg with no further change in the fundus picture. At 3 weeks follow-up, the left eye vision improved to 20/40, peripapillary hemorrhages reduced and the patient subsequently underwent left eye PRP completion in 2 sittings [Fig. 4].

At the last follow-up, 2 months following the initial visit, right eye had a visually significant cataract, no visible ocular NV and normal IOP on 4 topical AGM. The left eye had a superior conjunctival bleb, clear cornea, normal IOP on 3 topical AGM, senile cataract, no anterior segment NV, regressed FVP, and 360 PRP marks.

## Discussion

Ocular decompression retinopathy may occur after IOP lowering procedures such as glaucoma drainage implant insertion and trabeculectomy but may also occur after anterior chamber paracentesis, cataract surgery, vitrectomy, and silicone oil removal.<sup>[1-3]</sup> The diagnosis of ocular decompression retinopathy is mainly clinically where about 80% of patients are asymptomatic. Clinical features include hemorrhages at multiple levels of optic nerve and peripapillary retina which resolve in as short as 2 weeks. In most of the cases the disease

follows a benign course with visual acuity usually returning to preoperative levels without treatment. However, a few patients may require vitrectomy for nonresolving vitreous hemorrhage.<sup>[6]</sup>

In our patient, the right eye had PDR with multiple flat new vessels along with NVG in the rubeosis stage and normal IOP, thus IVB was preferred as the initial treatment modality. Though the effect of PRP is long-lasting, it often takes several weeks to show effect during which progressive angle closure, raised IOP, and optic nerve damage may ensue resulting in loss of vision.<sup>[7]</sup>

The left eye had PDR with an elevated FVP near the disc along with NVG in the closed-angle stage and raised IOP. In view of this elevated FVP, IVB was avoided as it may lead to development of tractional retinal detachment.<sup>[8]</sup> Thus, as the cornea was clear at presentation despite the raised IOP, PRP 1 was done to the inferior retina on the same day. On subsequent follow-up, the left eye corneal edema developed in view of the raised IOP which prevented PRP completion. Thus, anterior chamber paracentesis along with ICB was done since ICB not only decreases iris neovascularization but also aids as a surgical adjunct for neovascular glaucoma.<sup>[9]</sup> Also the half-life of ICB is considerably less which would prevent any prolonged effect on the posterior segment pathology.<sup>[10]</sup> Hyphema is a common complication in NVG following anterior segment surgeries including anterior chamber paracentesis but it did not occur in our case. In a study by Nakatake *et al.*, only 22% of patients of NVG undergoing an IOP reducing surgery developed hyphema.<sup>[11]</sup> Following the intracameral anti-VEGF injection multiple retinal hemorrhages developed suggesting decompression retinopathy. A differential of central retinal vein occlusion and Valsalva retinopathy was kept but the absence of dilated and tortuous veins, absent hemorrhages up to retinal periphery, and absence of history suggestive of raised intra-abdominal or thoracic pressure with only unioocular changes ruled out these differentials. Subsequently, the patient underwent mitomycin C-augmented trabeculectomy along with a repeat dose of ICB following which the IOP normalized, cornea cleared, and the patient underwent PRP completion.

## Conclusion

To conclude, though not the standard treatment procedure, ICB can be used in cases of PDR with NVG where there is an elevated FVP in the retina. Moreover, ocular decompression retinopathy can occur after anterior chamber paracentesis in cases of NVG where there is a sudden fall of raised IOP.

### Declaration of patient consent

The authors certify that they have obtained all appropriate patient consent forms. In the form the patient(s) has/have given his/her/their consent for his/her/their images and other clinical information to be reported in the journal. The patients understand that their names and initials will not be published and due efforts will be made to conceal their identity, but anonymity cannot be guaranteed.

### Financial support and sponsorship

Nil.

### Conflicts of interest

There are no conflicts of interest.

## References

1. Dianas J, Rosenbaum J, Podos SM. Diffuse retinal hemorrhages (ocular decompression syndrome) after trabeculectomy with mitomycin C for neovascular glaucoma. *Acta Ophthalmol Scand* 2000;78:468-9.
  2. Gupta R, Browning AC, Amoaku WM. Multiple retinal hemorrhages (decompression retinopathy) following paracentesis for macular branch artery occlusion. *Eye* 2004;19:592-3.
  3. Castejon MA, Fagundez MA, Perez P, Calvo MA, Teus MA. Retinal hemorrhages following phacotrabeculectomy. Differential diagnosis. *Arch Soc Esp Ophthalmol* 2001;76:509-10.
  4. Rao SK, Greenberg PB, Macintyre RB, Ducharme JF. Ocular decompression retinopathy after anterior chamber paracentesis for uveitic glaucoma. *Retina* 2009;29:280-1.
  5. Arevalo JF, Mendoza AJ, Fernandez CF, Yépez JB, Krivoy D, Millán FA. Decompression retinopathy after intraocular surgery. *Arch Soc Esp Ophthalmol* 2007;82:629-34.
  6. Mukkamala SK, Patel A, Dorairaj S, McGlynn R, Sidoti PA, Weinreb RN, *et al.* Ocular decompression retinopathy: A review. *Surv Ophthalmol* 2013;58:505-12.
  7. Ehlers JP, Spirn MJ, Lam A, Sivalingam A, Samuel MA, Tasman W. Combination intravitreal bevacizumab/panretinal photocoagulation versus panretinal photocoagulation alone in the treatment of neovascular glaucoma. *Retina* 2008;28:696-702.
  8. Arevalo JF, Maia M, Flynn HW, Saravia M, Avery RL. Tractional retinal detachment following intravitreal bevacizumab (Avastin) in patients with severe proliferative diabetic retinopathy. *Br J Ophthalmol* 2007;92:2136.
  9. Duch S, Buchacra O, Milla E, Andreu D, Tellez J. Intracameral bevacizumab (Avastin) for neovascular glaucoma. *J Glaucoma* 2009;18:140-3.
  10. Rimpelä AK, Kiiski I, Deng F, Kidron H, Urtti A. Pharmacokinetic simulations of intravitreal biologicals: Aspects of drug delivery to the posterior and anterior segments. *Pharmaceutics* 2018;11. doi: 10.3390/pharmaceutics11010009.
  11. Nakatake S, Yoshida S, Nakao S, Arita R, Yasuda M, Kita T, *et al.* Hyphema is a risk factor for failure of trabeculectomy in neovascular glaucoma: A retrospective analysis. *BMC Ophthalmol* 2014;14:55.
-