

Atypical hemolytic uremic syndrome and mutation analysis of factor H gene in two Tunisian families

Imen Habibi¹
Imen Sfar¹
Walid Ben Alaya¹
Jihen Methlouthi²
Abdelkrim Ayadi²
Mounira Brahim²
Jacques Blouin³
Raoudha Dhagbouj¹
Thouraya Ben Rhomdhane¹
Mouna Makhlouf¹
Houda Aouadi¹
Saloua Ayed-Jendoubi¹
Véronique Fremeaux-bacchi³
Tahar Sfar²
Taieb Ben Abdallah¹
Khaled Ayed¹
Yousr Gorgi¹

¹Laboratory of Immunology, Charles Nicolle Hospital, Tunis, Tunisia;
²Paediatric Department, Tahar Sfar Hospital, Mahdia, Tunisia; ³Immunology Department, George Pompidou Hospital, Paris, France

Correspondence: I Sfar
Laboratory of Immunology, Charles Nicolle Hospital, Tunis, Tunisia
Tel +21671578055
Fax +21671561156
Email drsfarimen@yahoo.fr

Abstract: We carried out a protein and genetic investigation of the factor H gene mutations within two families presenting with a diagnostic suspicion of atypical hemolytic uremic syndrome (aHUS). The results within the patients of the first family revealed a factor H-deficiency. Direct sequencing allowed the detection of a 4-nucleotide deletion in the factor H gene. This deletion was found as the homozygote form in the proband and as the heterozygote form in the parents. Protein and functional analyses of the complement system were normal in all members of the second family. However, the molecular investigation for the father showed the presence of an amino acid substitution in the FH gene. Unfortunately, his two affected children died without being investigated for mutations. The functional consequences of these abnormal proteins are still to be demonstrated.

Keywords: atypical hemolytic uremic syndrome, complement, alternative pathway, factor H, deletion, nucleotide substitution

Introduction

Hemolytic uremic syndrome (HUS) is a thrombotic microangiopathy characterized by hemolytic anemia and thrombocytopenia often complicated by acute renal failure in children.¹ Both typical or diarrhea-associated HUS form is associated with infection by *Escherichia coli* and has a good prognosis.² A second less common form, termed atypical, nondiarrhea-associated HUS (aHUS) is a heterogeneous recurrent disorder which displays high mortality and morbidity.³ This form can occur at any age with familial and sporadic cases. HUS is defined as familial when at least two members of the same family are affected by the disease at least 6 months apart. Familial aHUS exists in patterns of both autosomal dominant and recessive inheritance.⁴ Triggers for the sporadic form include infection with human immunodeficiency virus, cancer, use of immunotherapeutic agents, diseases and pregnancy.³ However, approximately 50% of sporadic cases appear to be idiopathic.⁴

It has recently been shown that aHUS is associated with mutations in the complement regulatory protein factor H (FH).⁵⁻⁸ The FH gene is located on chromosome 1q32 within a cluster of genes encoding the regulatory complement components of the activation of C3.⁹ These genes encode proteins, which consist of multiple homologous modules called “complement control protein modules” (CCPs), previously known as short consensus repeats (SCRs).¹⁰ Each SCR is 60 amino acids in length and has four cysteine residues which form two disulphide bridges: Cys1–Cys3 and Cys2–Cys4. These disulfide bridges are important in maintaining the characteristic structure of the SCR module.¹¹

The 155Kd fluid phase glycoprotein FH, is composed of 20 SCRs each encoded by a single exon, with the exception of the second SCR encoded by exon 2a and 2b.¹² It regulates the alternative pathway (AP) by competing with factor B for binding to C3b and acting as a cofactor for factor I, leading to proteolytic inactivation of C3b.^{13,14} Factor H can also interact with polyanionic molecules (sialic acids or glycosaminoglycans) on certain cellular surfaces conferring to them a resistance to damage as a consequence of complement activation through the AP.¹⁵

In order to identify potential FH mutations predisposing to aHUS, we performed a protein and genetic analysis of FH within two Tunisian families presenting a diagnostic suspicion of aHUS.

Materials and methods

Patients

Patients were recruited from the Pediatric department of Mahdia Hospital in Central Tunisia.

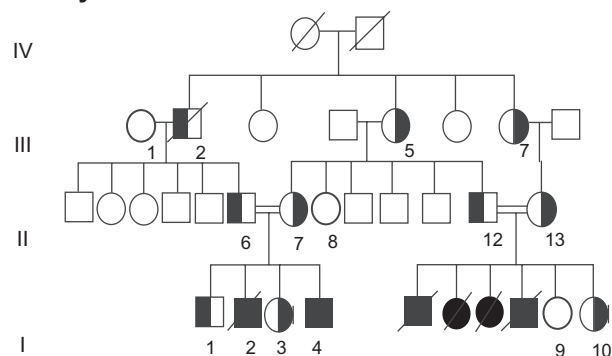
Family A pedigrees and case histories are shown in Figure 1

The family exhibited a high grade of consanguinity.

Patient I-4

A 25-day-old Tunisian boy with a family history of the death of a brother (I-2) and four cousins (I-5, I-6, I-7 and I-8) (Table 1)

Family A



Family B

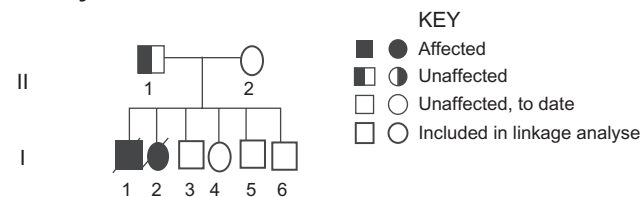


Figure 1 Pedigrees of family 1 and 2: Solid circles and squares represent respectively female and male members.

by HUS confirmed by postmortem renal biopsy presented initially with pallor, fever, refusal to suckle, and vomiting, but without any notion of diarrhea. A clinical examination found tachypnea, lethargy, a temperature of 39.6°C, and hypertension (blood pressure was 120/80 mmHg), with evidence of fluid overload. Initial investigations performed were as follows: a severe anemia with hemoglobin level of 5.9 g/dL, platelet count of 140000/mm³, schistocytosis at 16%, hematuria and proteinuria (3.3 g/day). The blood level of urea was 16 mM/L and the glomerular filtration rate, estimated using the Cockcroft–Gault equation for creatinine clearance (eGFR) was 41 mL/min/1.73 m². A diagnosis of atypical hemolytic uremia (aHUS) was established. A renal biopsy was performed and disclosed a pattern of thrombotic microangiopathy predominantly in the glomeruli with few vascular lesions. At this stage, he was transfused by leukocyte-depleted red blood cells. Administration of 2000 mL fresh frozen plasma (FFP) was undertaken for seven consecutive days associated with intravenous furosemide at maximal dose (2 mg/kg/day) and antihypertensive therapy was achieved with intravenous nicardipine (1 mg/kg/day). An adequate control was gained 20 days later using the same oral drugs with a normal renal function. A relapse occurred 6 months later, with acute renal failure that required peritoneal dialysis and fresh frozen plasma administration for 10 days. The patient regained independent renal function. At the time of writing, 2 years after onset, his renal function has remained normal with twice-monthly plasma infusions and no relapse of hemolysis has occurred.

Patient I-2

This 5-month-old Tunisian boy was referred for anemia (hemoglobin level of 4.9 g/dL), thrombocytopenia (platelet count of 100000/mm³) and acute renal failure (creatinine clearance was 41 mL/min/1.73 m²), leading to death at day 2 despite standard therapy and plasma infusions. Analysis of post-mortem renal biopsy material revealed ischemic glomeruli and fibrotic lesions in arteria and interstitium without deposition of C3.

Patients I-5, I-6, I-7, and I-8

These children, who were brothers and first cousins of patients I-2 and I-4, were referred to pediatric center for rapidly progressive renal failure, hypertension since the age of 52, 15, and 25 days, respectively (Table 1). Although, combining diuretics and angiotensin-converting enzyme inhibitors treatment, the clinical progression was critical with the rapid death of patients I-6, I-7, and I-8 a few days

Table I Case histories of families A and B

Family	Subject	Status/Disease	Onset of disease	Clinical features	Treatments	Disease outcome
A	I-1	Unaffected	–	–	–	–
A	I-2	Affected/HUS	5 months	Severe hypertension dyspnea, anemia Acute pulmonary edema	Plasma infusions Antihypertensives	Death 2 days after onset
A	I-3	Unaffected	–	–	–	–
A	I-4	Affected/HUS	25 days	Severe hypertension edema, anemia Renal failure refusal to suckle, proteinuria, hematuria	Plasma infusions Peritoneal dialysis Antihypertensive agents	Relapse 6 months after diagnosis Currently, normal renal function
A	I-5	Affected/HUS	52 days	Renal failure Severe hypertension Anemia heart failure proteinuria, hematuria	Plasma infusions Antihypertensive agents	One recurrence 15 days after diagnosis Death 4 months after diagnosis
A	I-6	Affected/HUS	15 days	Renal failure Severe hypertension Anemia proteinuria, hematuria	Plasma infusions Antihypertensive agents	Death 3 days after diagnosis
A	I-7	Affected/HUS	25 days	Renal failure Severe hypertension pneumonia Anemia proteinuria, hematuria	Plasma infusions Antihypertensive agents	Death 12 days after diagnosis
A	I-8	Affected/HUS	25 days	Renal failure Severe hypertension Vomiting Anemia proteinuria, hematuria	Plasma infusions Antihypertensive agents	Death 12 days after diagnosis
A	I-9	Unaffected	–	–	–	–
A	I-10	Unaffected	–	–	–	–
A	II-6	Unaffected	–	–	–	–
A	II-7	Unaffected	–	–	–	–
A	II-8	Unaffected	–	–	–	–
A	II-12	Unaffected	–	–	–	–
A	II-13	Unaffected	–	–	–	–
A	III-1	Unaffected	–	–	–	–
A	III-5	Unaffected	–	–	–	–
A	III-7	Unaffected	–	–	–	–
B	I-1	Affected/HUS	6 months	Renal failure Severe hypertension heart failure proteinuria, hematuria	Plasma infusions Antihypertensive agents	Death 24 hours after diagnosis
B	I-2	Affected/HUS	18 months	Renal failure Severe hypertension Vomiting Anemia proteinuria, hematuria	Plasma infusions Antihypertensive agents	Death 12 hours after diagnosis
B	I-3	Unaffected	–	–	–	–
B	I-4	Unaffected	–	–	–	–
B	I-5	Unaffected	–	–	–	–
B	I-6	Unaffected	–	–	–	–
B	II-1	Unaffected	–	–	–	–
B	II-2	Unaffected	–	–	–	–

after admission and before the use of peritoneal dialysis. At the acute phase, patient I-5 had also received a transfusion of packed red blood cells, plasma-exchanges and intravenous antihypertensive therapy. He regained independent renal function (creatinine clearance: 50 mL/min/1.73 m²) ten days after the initial episode. However, a recurrence of HUS 5 days later required weekly administration of FFP for a period of 2 months. Following acute otitis at the age 4 months, the child was referred for another episode of HUS. Despite the standard therapy, he died 48 hours after hospitalization. Analysis of post-mortem renal biopsy specimens revealed the presence of severe thrombotic microangiopathy lesions.

Family B pedigrees and case histories

This second family had the same geographic origin as the first family. No complement exploration could be performed for patient's I-1 and I-2. Only five healthy members were serologically investigated and genotyped (Figure 1).

Patient I-1

A 6-month-old Tunisian boy, born to high grade-consanguineous parents was referred with a history of fever and gross hematuria without diarrhea prodromal. The patient exhibited anemia with hemoglobin level of 7.9 g/dL, thrombocytopenia (platelet count of 140000/mm³), renal insufficiency (creatinine clearance: 38 mL/min/1.73 m²) and hypertension (120/80 mmHg). While receiving diuretics and intravenous antihypertensive therapy, the children died abruptly and the postmortem renal biopsy showed ischemic shrinkage of the capillaries with lesions of thrombotic microangiopathy.

Patient I-2

This Tunisian girl was presented with atypical HUS at the age of 18 months with rapidly critical clinical progression and death just a few hours after admission and before the use of peritoneal dialysis. Analysis of postmortem renal biopsy material revealed the same thrombotic microangiopathy lesions as her brother I-1 (Table 1).

Controls

One hundred fifty healthy controls matched for sex, ethnic, and geographic origin were also studied. Medical examination and a questionnaire were performed for all controls. Exclusion criteria were HUS in the donor or in a first-degree relative.

Patients and controls received detailed information on the purpose of the study. It was approved by the local ethics committee and *a priori* consent was obtained from all subjects.

Materials

Complement assays

Measurement of total hemolytic complement (CH50) and alternative pathway (AP50) activities in EDTA samples were determined using the method of Mayer.¹⁶ Plasma concentrations of C4, C3, and Factor B (FB) antigens were measured by nephelometry (Minineph™; The Binding Site, Birmingham, UK). Plasma levels of the third and/or fourth complement component below the lower limit of normal ranges (Table 2), defined as mean ± 2 standard deviations (SD) were taken to indicate hypocomplementemia.

Serum samples were used to quantify Factor H antigen concentration by enzyme-linked immunosorbent assay (ELISA) assay, described previously by Dragon-Durey.¹⁷ Normal ranges were 100% ± 30% as calculated by the results from 100 healthy individual donors.

Genomic FH DNA sequencing

Genomic DNA was amplified by means of polymerase chain reaction (PCR) using nucleotides flanking each exon. For all patients, all 22 FH exons were sequenced and analyzed. The number of nucleotide or codon referenced is indicated according to Warwicker and colleagues.⁵

Prediction of effects of amino acid substitutions

The PolyPhen server (see <http://www.bork.embl-heidelberg.de/PolyPhen/>) was used to predict the likely impact of non-synonymous amino acid substitutions or deletions, observed in patients and controls.

Results

Complement component assessment

Plasma complement profiles at the time of diagnosis are listed in Table 2. Results of complement investigation were confirmed at least twice.

Family A

Patient I-4 exhibited severe complement consumption through the alternative pathway, as indicated by very low plasma levels of CH50, AP50, C3, and FB. This patient presented a plasma concentration of FH protein below 1%. These results are in concordance with homozygous FH deficiency.

Plasma complement profile measurement showed mildly decreased CH50 and AP50, low C3 and FB plasma levels in patients' I-1, I-3, I-10, II-6, II-7, II-12, II-13, III-5, and III-7. Antigenic plasma levels of FH were between 35% and 50% of normal values, suggesting heterozygous FH deficiency.

Table 2 Results of complement investigations

Family	Subject	CH50 25–61 U/ml	C3 121 ± 36 mg/100 ml	C4 26 ± 12 mg/100 ml	AP50 100%	Factor H 100% ± 30%	Factor B 20 ± 11 mg/100 ml
A	I-1	27	90	26.4	52	50	10
A	I-3	29.4	85	22.3	50	50	8.5
A	I-4	<10	48.3	15.7	5	<1	8
A	I-9	27	100.1	26	80	90	27
A	I-10	24	75.3	14.4	35	35	11
A	II-6	27	85.5	87.7	50	50	8
A	II-7	26.3	82	24	50	35	6.8
A	II-8	28.1	131.9	11.7	100	100	27
A	II-12	15.3	85.8	34.1	50	30	10
A	II-13	28.5	91	34.1	35	30	10
A	III-1	26.6	127.9	24.6	100	95	27
A	III-5	<10	86.9	34.1	50	35	8
A	III-7	14.2	85.1	31.6	50	50	8
B	I-3	25	128.1	24.5	80	100	18
B	I-4	25	128.5	11.8	50	100	15
B	I-5	25	121.4	16.9	52	85	18
B	II-1	25	144.6	56.2	50	100	18
B	II-2	25	129.3	38.9	100	95	18

Family B

In all the investigated healthy members a FH antigenic level and C3 and FB plasma levels were normal.

Characterization of the genetic defect

Family A

Genomic sequencing showed a four-bp TAGA or ATAG deletion in SCR 20 of factor H, between nucleotides of 3767 and 3770, as a homozygous state in the patient (I-4) and a heterozygous state in the parents; and all family members carried heterozygous FH deficiency (Figure 2). This mutation leads to the loss of the normal stop codon (TAG) inducing a frame shift in factor H coding sequence. The predicted protein sequence shows 37 additional amino acid changes induced by this deletion.

Family B

A nucleotide substitution G to C at position 3617 resulting in an arginine/threonine heterozygous nonsense mutation at 1182 codon from SCR 20 was detected in the father (II-1). The predictive translation shows that this nucleotide substitution induced structural change in the hypervariable loop of SCR-20 between strands β 2 and β 3. However, the healthy mother (II-2) and brothers (I-3, I-4, I-5) do not exhibit the same substitution.

Controls

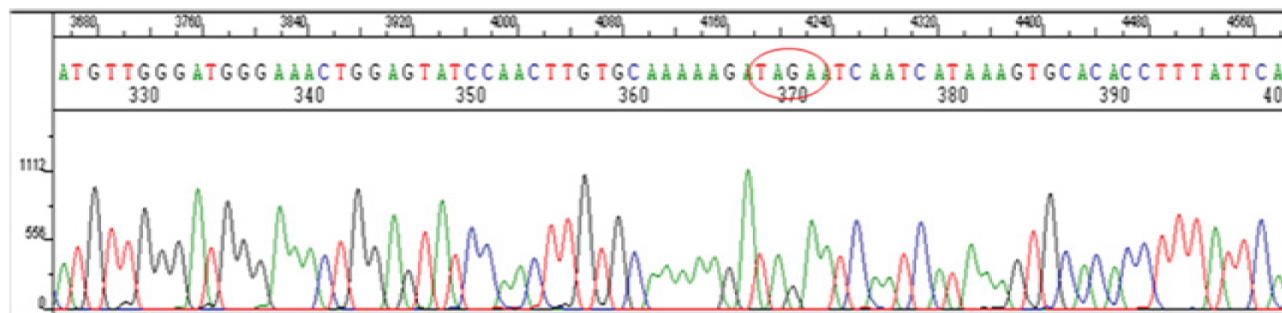
Both molecular deletion and nucleotide substitution were not found in 150 Tunisian healthy controls or reported in

other control populations and thus are unlikely to represent allelic variants.

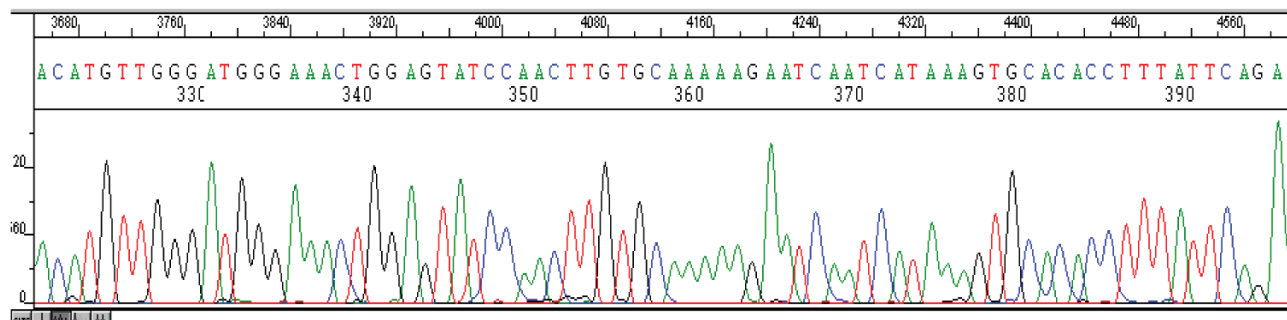
Discussion

FH deficiencies have been reported in both homozygous and heterozygous forms associated with aHUS and other kidney diseases such as type II or III membranoproliferative glomerulonephritis.⁸ Genetic studies have found several missense mutations between SCR16 and SCR20 suggesting a particular role of the C-terminal domains of the FH protein.^{18–22} This region is important for binding to C3b and sialic acid residues on to cell surfaces. Mutations in this region, therefore, impair the ability of factor H to protect against complement-mediated host cell damage which may cause the vascular injury observed in HUS.¹⁸ In a complete FH deficient proband we have identified a molecular abnormality consisting of a 4-bp TAGA or ATAG deletion leading to a normal stop codon loss and inducing a longer protein with 37 additional amino acids. According to the family tree, whoever has a high degree of consanguinity, this deletion is transmitted in an autosomal recessive form. The conformational change could explain the production of a macromolecule unable to be secreted or quickly hydrolyzed. We speculate that this hypothesis explains the total deficiency of the H protein in our present case. It also could explain the partial deficiency of the FH antigen level in heterozygous members. Protein crystallography and immunohistochemical analyses are necessary to clarify the molecular mutant protein synthesis, as well as its cellular secretion.

A)



B)



C)

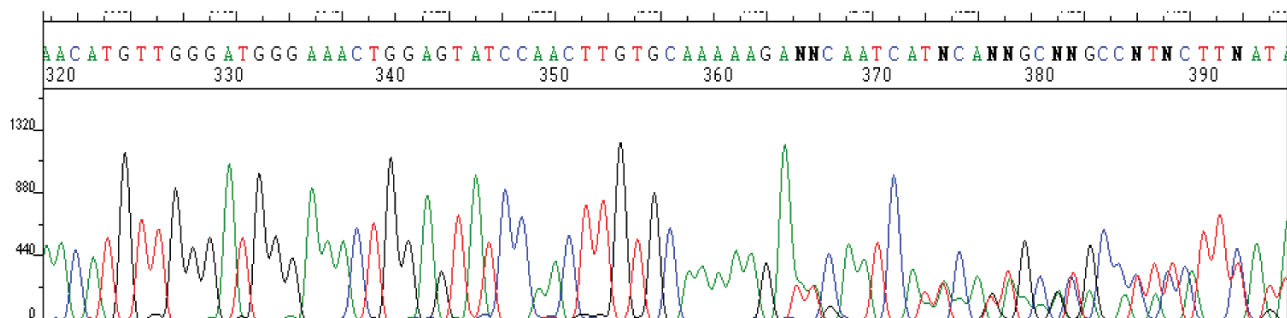


Figure 2 DNA sequencing for a section of factor H SCR20 in family A.

Notes: **A)** Wild type chromatogram, **B)** Chromatogram of I-4 patient: After the nucleotides AAAAAGA, there is a deletion of 4 nucleotides TAGA (3767_3771 delTAGA), **C)** Chromatogram of a heterozygous patient with superposed peaks from the wild-type and mutant alleles.

This genetic abnormality has been previously described by Sellier-Leclerc²³ and Sethi²⁴ who report FH antigenic level at 4% and 10% respectively. Sethi and colleagues²⁴ have not detected by Western blot the abnormal protein in serum, suggesting an impairment of the secretion of this FH protein would be retained in the cytoplasm. Also, Neumann⁷ described a deletion of four nucleotides AGAA at a position 3768 of the nucleotide sequence inducing the same frameshift consequences. Several therapies, such as plasma administration and plasma exchanges were used in patients with aHUS in order to supplement factor H deficiencies.²⁵ However, a combined liver-kidney

transplantation was required in case of the progression to end-stage renal disease.²⁶ In all the cases described by Sellier-Leclerc,²³ Sethi²⁴ and Neumann,⁷ patients exhibited the evolution chronic kidney disease and awaited a renal transplantation.

To date, while the FH antigenic level was below than 1%, the renal function of our present case remains normal under regularly plasma infusions. This clinical course is also extremely different from that observed in his brother and the first cousins both of whom died abruptly, despite standard therapy. The results of our data suggests that the genetic predisposition to complement FH dysregulation was

perhaps due to a trigger event such as infection or a second susceptibility factor which has not yet been identified.

Other genetic abnormalities involved in the impairment of intrachain disulfide bonds leading to the change of the secondary structure of the protein were also described.¹⁷ Similar mutations involving a cysteine in SCR 9 and 16 were previously reported by Ault²⁷ and Schmidt²⁸ and it has been demonstrated that the 150-kD protein was retained in the intracellular fraction. In our data, such mutations were not detected.

Several studies have shown that many patients had a functionally significant mutation in the absence of alternative pathway consumption.²¹ Consequently, and despite the normal C3 and factor H levels, we processed to CFH mutation screening in the family B. A single heterozygous base pair substitution at 1182 codon involving an arginine (Arg) that was changed to a threonine (Thr) was found in the father. Nuclear magnetic resonance and chemical shift mapping indicated that Arg1182 is one of the eight residues involved in heparin binding.^{29,30} The majority of mutations that occur within, or close proximity to, this loop show a type II phenotype (in which serum levels of factor H are normal).^{31,32}

In our data, we report two genetically different abnormalities in aHUS consanguineous families. The mechanisms by which these factor H mutations lead to this disease are not fully understood. Further biochemical and functional studies will provide deeper insights into the pathogenesis of aHUS.

Acknowledgments

This work was supported by grants from the LR03SP01, Tunis, Tunisia. We are deeply indebted to Drs. Veronique Fremaux-Bacchi, Marie Agnes Dragon-Durey and Jacques Blouin for their collaboration in setting up the genetic methods and their technical support. We are grateful to Prof. Ridha Barbouche for his continued support. We thank all the participating family members and their referring clinicians: Dr Ayadi Abdelkrim, Dr Mounira Brahim, Dr Jihen Mathlouthi, and Dr Tahar Sfar.

Disclosure

The authors report no conflicts of interest in this work.

References

- Ruggenti P, Noris M, Remuzzi G. Thrombotic microangiopathy, haemolytic uremic syndrome and thrombotic thrombocytopenic purpura. *Kidney Int.* 2001;60:831–846.
- Zimmerhackl LB. *E. coli*, antibiotics and the haemolytic-uremic syndrome. *N Engl J Med.* 2000;342:1990–1991.
- Constantinescu AR, Bitzan M, Weiss LS et al. Non-enteropathic hemolytic uremic syndrome: Causes and short-term course. *Am J Kidney Dis.* 2004;43:976–982.
- Noris M and Remuzzi G. Atypical haemolytic-uremic syndrome. *N Engl J Med.* 2009;361:1676–1687.
- Warwicker P, Goodship THJ, Donne RL, et al. Genetic studies into inherited and sporadic haemolytic uraemic syndrome. *Kidney Int.* 1998;53:836–844.
- Jozsi M, Heinen S, Hartmann A, et al. Factor H and atypical hemolytic uremic syndrome: mutations in the C-terminus cause structural changes and defective recognition functions. *J Am Soc Nephrol.* 2006;17:170–177.
- Neumann HP, Salzmann M, Bohnert-Iwan B, et al. Haemolytic uraemic syndrome and mutations of the factor H gene: a registry-based study of German speaking countries. *J Med Genet.* 2003;40:676–681.
- Sanchez-Corral P, Perez-Caballero D, Huarte O, et al. Structural and functional characterization of factor H mutations associated with atypical haemolytic uraemic syndrome. *Am J Hum Genet.* 2002;71:1285–1295.
- Skerka C, Zipfel PF. Complement factor H related proteins in immune diseases. *Vaccine.* 2008;26:9–14.
- Hocking HG, Herbert AP, Kavanagh D, et al. Structure of N-terminal region of complement factor H and conformational implications of disease-linked sequence variations. *J Biological Chem.* 2008;283:9475–9487.
- Schmidt BZ, Fowler NL, Hidvegi T, et al. Disruption of disulfide bonds is responsible for impaired secretion in human complement factor H deficiency. *J Biol Chem.* 1999;274:11782–11788.
- Male DA, Ormsby RJ, Ranganathan S, et al. Complement factor H: sequence analysis of 221 kb of human genomic DNA containing the entire FH, FHR-1 and fHR-3. *Mol Immunol.* 2000;37:41–52.
- Whaley K, Ruddy S. Modulation of the alternative complement pathways by beta1 H globulin. *J Exp Med.* 2000;144:1147–1163.
- Pangburn MK, Schreiber RD, Müller-Eberhard HJ. Human complement C3b inactivator: isolation, characterization, and demonstration of an absolute requirement for the serum protein beta1 H for cleavage of C3b and C4b in solution. *J Exp Med.* 2001;146:257–270.
- Pangburn MK, Schreiber RD, Müller-Eberhard HJ. C3b deposition during activation of the alternative complement pathway and the effect of deposition on the activating surface. *J Immunol.* 2000;131:1930–1935.
- Mayer MM. Complement and complement fixation. In: Kabat EA, Mayer MM, editors. *Experimental Immunology*. 2nd ed Springfield, IL: Thomas; 1961:133–140.
- Dragon-Durey MA, Fremaux-Bacchi V, Loirat C, et al. Heterozygous and homozygous factor H Deficiencies associated with Hemolytic Uremic Syndrome or Membranoproliferative glomerulonephritis: Report and genetic analysis of 16 cases. *J Am Soc Nephrol.* 2004;15:787–795.
- Dragon-Durey MA, Blanc C, Marliot F, et al. The high frequency of complement factor H related CFHR1 gene deletion is restricted to specific subgroups of patients with atypical haemolytic uraemic syndrome. *J Med Genet.* 2009;46:447–450.
- Caprioli J, Bettinaglio P, Zipfel PF, et al. Italian Registry of Familial and Recurrent HUS/TTP. The molecular basis of familial haemolytic uremic syndrome: mutation analysis of factor H gene reveals a hot spot in short consensus repeat 20. *J Am Soc Nephrol.* 2001;12:297–307.
- Sanchez-Corral P, Perez-Caballero D, Huarte O, et al. Structural and functional characterization of factor H mutations associated with atypical haemolytic uremic syndrome. *Am J Hum Genet.* 2002;71:1285–1295.
- Perkins SJ, Goodship TH. Molecular modelling of the C-terminal domains of factor H of human complement: a correlation between haemolytic uraemic syndrome and a predicted heparin binding site. *J Mol Biol.* 2002;316:217–24.
- Edey MM, Mead PA, Saunders RE, et al. Association of a factor H mutation with hemolytic uremic syndrome following a diarrheal illness. *Am J Kidney Dis.* 2008;51:487–490.

23. Sellier-Leclerc AL, Fremeaux-Bacchi V, Dragon-Durey MA, et al. Differential Impact of Complement Mutations on clinical characteristics in atypical hemolytic uremic syndrome. *J Am Soc Nephrol.* 2007;18:2392–2400.
24. Sethi SK, Dragon-Durey MA, Thaker N et al. Hemolytic uremic syndrome due to homozygous factor H deficiency. *Clin Exp Nephrol.* 2009;13:526–530.
25. Allford SL, Hunt BJ, Rose P et al. Guidelines on the diagnosis and management of the thrombotic microangiopathic haemolytic anaemias. *Br J Haematol.* 2003;120:556–573.
26. Saland JM, Emre SH, Shneider BL, et al. Favorable long-term outcome after liver–kidney transplant for recurrent hemolytic uremic syndrome associated with a factor H mutation. *Am J Transplant.* 2006;6:1948–1952.
27. Ault B, Schmidt B, Fowler N, et al. Human factor H deficiency: Mutations in framework cysteine residues and block in H protein secretion and intracellular catabolism. *J Biol Chem.* 1997;272:25168–25175.
28. Schmidt BZ, Fowler NL, Hidvegi T, et al. Disruption of disulfide bonds is responsible for impaired secretion in human complement factor H deficiency. *J Biol Chem.* 1999;274:11782–11788.
29. Herbert AP, Ubrin D, Lyon M, et al. Disease-associated sequence variations congregate in a polyanion recognition patch on human factor H revealed in three-dimensional structure. *J Biol Chem.* 2006;281:15512–16520.
30. Saunders RE, Abarrategui-Garrido C, Fremeaux-Bacchi V, et al. The interactive factor H-atypical hemolytic uremic syndrome mutation database and website: update and integration of membrane cofactor protein and factor I mutations with structural models. *Hum Mutat.* 2007;28:222–234.
31. Jokiranta TS, Jaakola VP, Lehtinen MJ, et al. Structure of complement factor H carboxyl-terminus reveals molecular basis of atypical hemolytic uremic syndrome. *EMBO J.* 2006;25:1784–1794.
32. Pickering MC, Goicoechea de Jorge E, Martinez-Barricarte R. Spontaneous hemolytic uremic syndrome triggered by complement factor H lacking surface recognition domains. *J Exp Med.* 2007;204:1249–1256.

International Journal of Nephrology and Renovascular Disease

Dovepress

Publish your work in this journal

The International Journal of Nephrology and Renovascular Disease is an international, peer-reviewed open-access journal focusing on the pathophysiology of the kidney and vascular supply. Epidemiology, screening, diagnosis, and treatment interventions are covered as well as basic science, biochemical and immunological studies. The journal welcomes original

research, clinical studies, reviews & evaluations, expert opinion and commentary, case reports and extended reports. The manuscript management system is completely online and includes a very quick and fair peer-review system, which is all easy to use. Visit <http://www.dovepress.com/testimonials.php> to read real quotes from published authors.

Submit your manuscript here: <http://www.dovepress.com/international-journal-of-nephrology-and-renovascular-disease-journal>