

Original paper

## Comparison of chest X-ray lesion characteristics of multidrug-resistant tuberculosis and non-tuberculous mycobacterial infection

Ana Majdawati<sup>1A,B,D,E,F,G</sup>, Aziza Ghanie Icksan<sup>2C,D,E,F</sup>, Dina Lolong<sup>3C,E,G</sup>

<sup>1</sup>Department of Radiology, Faculty of Medicine Health Sciences, Universitas Muhammadiyah Yogyakarta, Indonesia

<sup>2</sup>Department of Radiology Persahabatan Hospital Jakarta, East Jakarta, Jakarta, Indonesia

<sup>3</sup>National Institute of Health Research and Development – NIHRD, Central Jakarta, Jakarta, Indonesia

### Abstract

**Purpose:** This research aimed to compare chest radiographic characteristics of multidrug-resistant tuberculosis (MDR-TB) and non-tuberculous mycobacteria (NTM) infection, which can be used in early diagnostic screening.

**Material and methods:** The method of this study was cross-sectional to obtain the relationship between radiographic findings.

**Results:** Among 538 subjects who were positive for TB during screening, 11 (2.04%) had MDR-TB, 147 (27.32%) had drug-sensitive TB, and 380 (70.63%) had NTM infection. The radiographic findings that correlated with MDR-TB were infiltrates ( $p = 0.010$ ), cavities ( $p = 0.021$ ), nodules ( $p = 0.001$ ), and fibrosis ( $p = 0.010$ ), with the best predictor of MDR-TB lesions being the presence of a nodule. The lesion locations related to MDR-TB were the upper right and left lung ( $p = 0.00$ ). There were no specific lesions present in NTM infection ( $p < 0.05$ ) because almost all had a meaningful correlation ( $p < 0.05$ ), except the presence of a mass. The lesion location related to NTM infection was the medial aspect of the left lung ( $p = 0.01$ ), and the lesion extent was also correlated ( $p < 0.05$ ).

**Conclusions:** Chest X-ray lesion characteristics of MDR-TB show significant correlation among cavities, nodules, and fibrosis. There were no specific lesions that could differentiate NTM infection from MDR-TB; however, the most common lesion location in NTM infection was the medial aspect of the left lung.

**Key words:** lesion characteristics, *Mycobacterium tuberculosis*, multidrug-resistant tuberculosis, non-tuberculous *Mycobacterium*, radiographic findings.

### Introduction

According to the 2015 Global Tuberculosis Report, Indonesia has the second highest rate of tuberculosis (TB) after India. Some cases of TB develop resistance to anti-tuberculosis drugs, which is called multidrug-resistant TB (MDR-TB), and other cases are caused by non-tuberculous mycobacteria (NTM) [1]. Tuberculosis can affect both humans and animals. *Mycobacterium tuberculosis* infects humans through droplets that are inhaled by humans. Animals can be zoonoses, which are intermediaries for tuber-

culous infection in humans, namely by *M. bovis*. The increase in TB in cattle shows the importance of conducting strict health control of livestock both actively and passively; this is TB which is a high cause of death [2].

The diagnosis of MDR-TB or NTM is time-consuming, expensive, and requires specialist examination facilities. Sputum culture takes 3-4 weeks; the sensitivity test for anti-TB drugs is also relatively complicated and takes a long time to provide information for effective treatment, and the drug of choice for MDR-TB is limited and expensive. This is also the case with NTM, which has an increasing

### Correspondence address:

Ana Majdawati, Department of Radiology, Faculty of Medicine Health Sciences, Universitas Muhammadiyah Yogyakarta, Indonesia, Jalan Brawijaya, Tamantirto, Yogyakarta 55183, Indonesia, e-mail: [anamjdw2@gmail.com](mailto:anamjdw2@gmail.com)

### Authors' contribution:

A Study design · B Data collection · C Statistical analysis · D Data interpretation · E Manuscript preparation · F Literature search · G Funds collection

incidence; however, diagnostic tests for NTM are rarely performed, due to its silent symptoms and the fact that specific displayed symptoms are difficult to distinguish from TB or MDR-TB. Also, NTM cases are usually accidentally diagnosed while the patients are undergoing TB examination or when TB treatment fails [3].

Chest X-ray is still routinely performed in patients with TB or suspected MDR-TB. This examination is considered inexpensive and convenient, is available in almost every hospital or healthcare facility, and allows identification of lesion characteristics. In general, chest X-ray features of TB, MDR-TB, and NTM vary widely and each has its specific characteristics. Some overseas studies have shown that in MDR-TB cases, chest X-ray displays characteristic lesions such as cavities, consolidation, nodular-infiltrates, pleural effusions, pleural thickening, hilar lymphadenopathy, and even destroyed lung/loss of volume [4,5]. Some characteristic NTM lesions on chest X-ray are cavities (thin-walled compared with TB infection) in the superior lobes of the lung, large nodular bronchiectasis (size greater than 0.5 cm), and consolidation [6,7].

The present study examined the correlation between chest X-ray lesion characteristics of MDR-TB, based on GeneXpert MTB/RIF, and NTM, based on the immunochromatographic assay MPT64 and niacin tests. GeneXpert MTB/RIF is a molecular examination technique introduced by the World Health Organisation (WHO) in 2010 for the detection of rifampicin-resistant *M. tuberculosis*, based on a nucleic acid amplification test (NAAT). Several studies have shown that GeneXpert MTB/RIF has a higher sensitivity (83.7%) and specificity (100%) than sputum smear microscopy or chest X-ray. GeneXpert MTB/RIF requires a much smaller sputum specimen than the sputum smear test (131 CFU/ml for *M. tuberculosis*), and the time required for this test is only 90 minutes, which is relatively short compared with sputum culture examination (six weeks) [8,9].

MPT64 is one of 33 proteins secreted by *M. tuberculosis* and is encoded by the RD1, RD2, and RD3 genes, the presence of which is used for the differentiation between the *M. tuberculosis* complex and NTM bacilli. Niacin/nicotinic acid is produced by *Mycobacteria* spp. As an essential oxidation-reduction reaction during metabolic synthesis. Niacin reagent strips are used as a qualitative identification of niacin-producing mycobacteria; *M. tuberculosis* is a bacterium that produces a significant amount of niacin, but NTM tests negative [10,11].

Studies comparing chest X-ray lesion characteristics of MDR-TB and NTM remain very limited in Indonesia, and most of the related overseas studies are descriptive. The present study evaluated the correlation between specific chest X-ray lesion characteristics and MDR-TB or NTM infection, based on GeneXpert MTB/RIF for the diagnosis of MDR-TB and the MPT64 and niacin tests for the diagnosis of NTM. The results of the present study can be used as an early screening test for the diagnosis

of MDR-TB and NTM, which will shorten the time and cost of MDR-TB diagnosis. Characteristics of MDR-TB and NTM lesions on chest X-ray will be useful for primary screening of patients with suspected MDR-TB before subsequent, more expensive secondary screening using GeneXpert and MPT64/niacin tests for NTM. Expectations include the suppression of MDR-TB and NTM morbidity and mortality, in addition to more effective treatment.

## Material and methods

### Experimental subject

The present study used a cross-sectional retrospective design to obtain the correlation between chest X-ray lesion characteristics and MDR-TB and NTM infection. Experimental subjects were individuals aged 15 years or older, who had lived in the cluster area for at least one month, had clinically positive TB, had a cough for more than 14 days or were coughing up blood, or had a chest X-ray in provinces throughout Indonesia. The subjects met the inclusion and exclusion criteria. Inclusion criteria were: 1) chest X-ray diagnosis of MDR-TB; 2) chest X-ray diagnosis of NTM; 3) the final results of an MDR-TB sample, or 4) the final results of an NTM sample. Exclusion criteria were: 1) chest X-ray results with abnormalities in the pulmonary parenchyma, for instance, bronchitis, emphysematous, or a lung mass; 2) chest X-ray with massive pleural effusion; or 3) chest X-ray with extensive pneumothorax, from which pulmonary parenchyma could not be assessed.

### Procedures

Figure 1 showed the scheme of the present study. This study used research subjects based on 15-year-old individuals who were selected based on medical records. Subsequently, chest X-ray images from *M. tuberculosis* bacteria (MTB) patients including drug-susceptible tuberculosis bacteria (DS-TB) and MDR-TB, also from NTM patients, were obtained. The images were investigated for lesion characteristics as well as clinical tests of culture or GeneXpert tests for MDR-TB and MPT64 or niacin tests for NTM. All data were acquired and analysed using the  $\chi^2$  test followed by multivariate logistic regression using the backward stepwise method for determination of correlation and differentiation between variables.

### Data acquisition

Data were obtained both primarily and secondarily. Primary data were obtained from research measured variables, both independent and dependent. The independent variables were lesion type, lesion location, and lesion extent. Lesion types on chest X-ray were: infiltrated, cavities, nodules, masses, consolidation, pleural effusion,

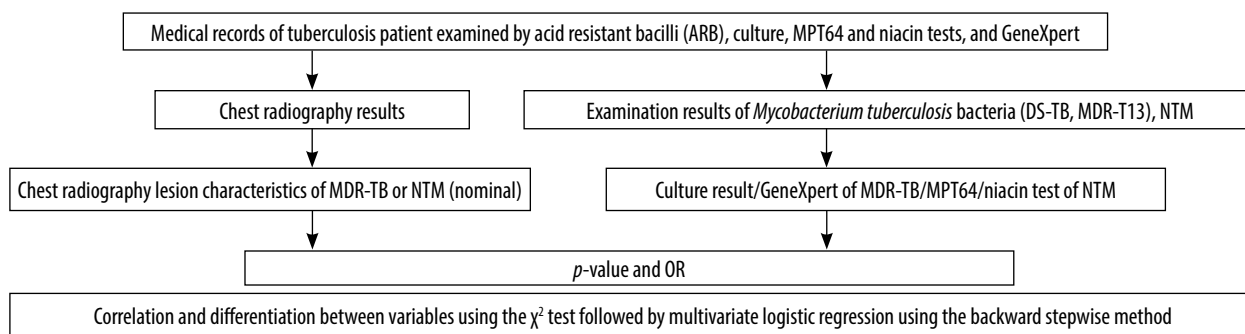


Figure 1. Research scheme of this present study

pleural thickening, fibrosis, and calcification. Lesion locations were right upper lung, right medial lung, right lower lung, left upper lung, left medial lung, left lower lung. The lesion extent was: minimal lesions, intermediate lesions, and extensive lesions (advanced). The dependent variables were MDR-TB diagnosis including acid resistant bacilli (ARB), culture, and GeneXpert, as well as NTM diagnosis when the results showed MDR-TB and culture and subsequently MPT64 followed by niacin.

Secondary data were chest X-ray diagnosis of MDR-TB and NTM obtained from the Indonesian Tuberculosis Research Survey 2013-2014 by the National Institutes of Health Research and Development – NIHRD (ethical clearance number: KE.01.10/EC/651/2012).

### Parameters

The parameters used to calculate the sample size with a certain degree of accuracy were:

1. Estimated TB prevalence (p): 156 per 100,000 people;
2. The proportion of the population that is 15 years old and over (a): 71.1%;
3. A 95% confidence level or  $\alpha$  of 5%;
4. Relative precision (d): 20% based on WHO recommendations;
5. Minimum participation rate (r): 85% based on WHO recommendations;
6. The magnitude of the cluster (M): 500 considering the weekly operating cycle and WHO recommendations (400-800);
7. Design effect (deff): 1.5 ( $k > 0.6$ , approximate high cluster variation based on 2004 experience).

Based on parameters above, number of samples (were calculated using Equation 1.

$$n_0 = \frac{1.96^2 \times (1 - p)}{d^2 p} \times deff = 9202.09 \tag{1}$$

Because the survey covers only adults as the eligible population, the sample size was calculated using Equation 2:

$$n_a = n_0 \times a = 65555.69 \tag{2}$$

Considering the expected participation rate of 85%, the number of samples adjusted for the participation rate was calculated using Equation 3.

$$n = \frac{n_a}{r} = 77124.34 \tag{3}$$

The number of clusters (C) needed was calculated using Equation 4.

$$C = \frac{n}{M} = 156 \tag{4}$$

The estimated number of participants aged 15 years and over by the 2010 census is 82,155 in 156 clauses; thus, an estimated 527 participants per cluster.

### Statistical analysis

Stats Direct version 2.7.8 (Stats Direct Ltd., Cheshire, UK) and SPSS Version 22.0 for Windows (SPSS, Chicago, IL) software were used to perform statistical analysis. Normality of the data was assessed using bivariate analysis to obtain a significant correlation between chest X-ray lesion characteristics, which is a nominal/categorical scale as an independent variable, and the results of GeneXpert/sputum culture/MPT64 and niacin tests for the incidence of MDR-TB and NTM incidence, which is a nominal/categorical scale as a dependent variable (outcome). Chest X-ray correlation (lesion type, lesion location, and lesion extent) was compared with MDR-TB and NTM laboratory results using the  $p$ -value and bivariate  $\chi^2$  statistical analysis followed by multivariate logistic regression using the backward stepwise method to determine lesion characteristics [7,8]. Research data, such as patient identity, was kept confidential. Data collection from the research patients was performed after obtaining a permit from the Head of the National Institutes of Health Research and Development – NIHRD. The following is the research scheme of the present study.

## Results

### Research subjects' details

Research subjects' details obtained from the national TB survey during 2013-2014 were shown in Table 1.

**Table 1.** Distribution of national tuberculosis research subjects in 2014

Laboratory diagnosis	Amount	Percentage	Research subjects	Percentage
Negative results	13.836	91.47		
MTB	426	2.82		
MDR-TB			11	2.04
DS-TB			147	27.32
Other	268			
NTM	405	2.68	380	70.63
Other	460	3.06		
Screened (+)	15.127	100.00	538	

**Table 2.** Basic characteristics of the research subjects concerning age, gender, province of origin, urban/rural area, and educational level

Adjective	NTM (n = 380)		MDR-TB (n = 11)	
<b>Age (years)</b>				
15-24	27	7.40%		
25-34	48	1.59%	6	54.55%
35-44	76	20.00%	4	36.36%
45-54	63	16.54%		
55-64	67	17.78%	1	9.09%
> 65	99	25.68%		
<b>Gender</b>				
Male	216	56.79%	2	18.18%
Female	164	43.21%	9	81.82%
<b>Area</b>				
Rural	159	41.95%	7	63.64%
Urban	221	58.05%	4	36.36%
<b>Educational level</b>				
Uneducated	140	36.79%		
Elementary/Jr. High School	158	41.73%	6	54.55%
Sr. High School	68	18.02%	4	36.36%
College/University	12	3.21%	1	9.09%
Postgraduate	2	0.25%		

Among the 15,127 participants who met the research inclusion and exclusion criteria, 11 individuals were diagnosed with MDR-TB and 380 with NTM.

Table 2 describes in detail the basic characteristics of the research subjects concerning age, gender, province of origin, urban/rural area, and educational level. The age bracket of the study subjects with the highest rate of NTM diagnosis was > 65 years old (25.68%), while that of those with the highest rate of MDR-TB diagnosis was 25-34 years old (54.55%). The majority of NTM cases were in individuals from urban areas (58.05%) as compared with those from rural areas (41.95%). MDR-TB is more common in rural areas (63.64%) than in

**Table 3.** Clinical symptoms of non-tuberculous mycobacteria patients

Clinical symptom	Amount (n = 380)		Percentage	
	Yes	No	Yes	No
Cough	290	90	76.30	23.70
> 14 days	213		56.05	
< 14 days	77		20.25	
Phlegm cough	227	153	59.75	40.25
Fever	128	252	33.83	66.17
Chest pain	167	213	43.95	56.05
Night sweats	103	277	27.16	72.84
Weight loss	130	250	34.21	65.79
Shortness of breath	175	230	43.21	56.79

urban areas (36.36%). Concerning the educational level of subjects with NTM, 78.52% had a relatively low educational level (uneducated/primary school/junior high school). Subjects with MDR-TB were too few (11) to be used as valid information; nevertheless, their educational level appeared to be slightly higher (junior high school and senior high school).

### Clinical symptoms of non-tuberculosis mycobacterium

Table 3 shows some of the clinical symptoms present at the highest percentage in NTM. All patients partly showed clinical symptoms with varying percentage values. Cough and phlegm cough were the most common clinical symptoms suffered by patients but not for other symptoms. However, the clinical symptoms of most cases of laboratory-based positive NTM are a cough (76.30%), and productive cough for a duration > 14 days (50%).

### Non-tuberculous mycobacterial and multidrug-resistant tuberculosis lesions based on chest X-ray images

Chest X-ray images were showing the variation in NTM and MDR-TB lesions. Figure 2A and 2B show that NTM diagnosis was a consolidated feature, thin-walled

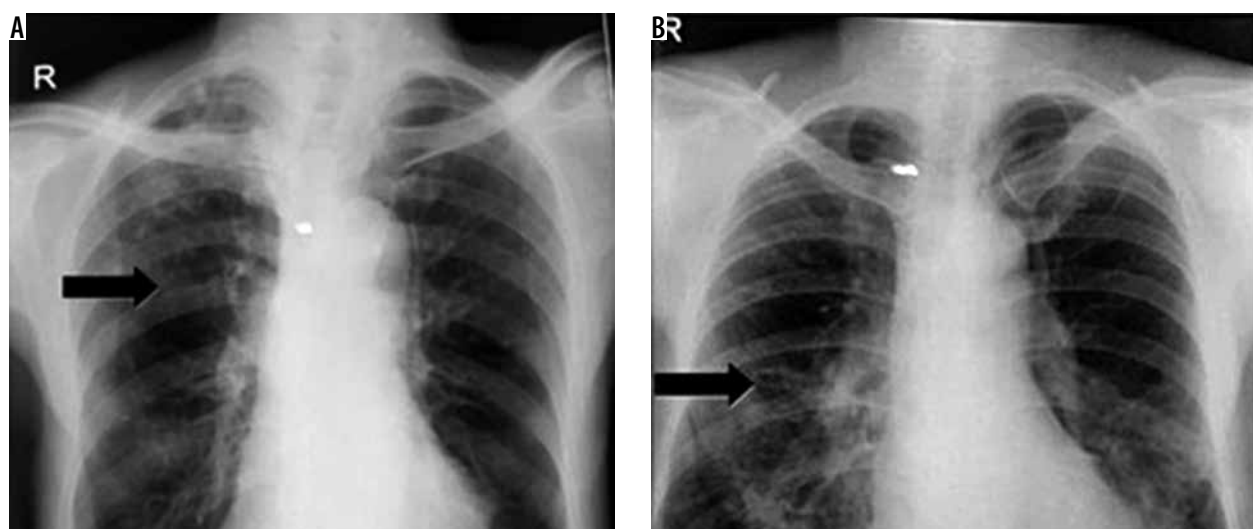
**Table 4.** Chest X-ray lesion characteristics of non-tuberculous mycobacteria (NTM) and multidrug-resistant tuberculosis (MDR-TB) infection

Variable	NTM						MDR-TB					
	Amount (380)		X <sup>2</sup> square		Multivariate		Amount (11)		X <sup>2</sup> square		Multivariate	
	F	%	p	OR	p	OR	F	%	p	OR	p	OR
<b>Lesion type</b>												
Infiltrates	39	7.65	0.000*	0.044	–	–	7	5.0	0.010*	5.053*	0.281	2.147
Cavities	11	2.16	0.000*	0.065	–	–	4	7.1	0.021*	5.110*	0.232	2.428
Nodule < 3 cm	13	2.55	0.000*	0.118	–	–	5	11.1	0.001*	9.338*	0.003*	18.812*
Mass	8	1.57	0.456	3.072	–	–	0	0.0	1.000	–	0.999	0.000
Consolidation	17	3.33	0.000*	0.066	–	–	4	5.3	0.057	3.590	0.194	0.255
Pleural effusion	7	1.37	0.000*	0.131	–	–	1	4.0	0.417	2.054	0.866	1.234
Pleural thickening	7	1.37	0.000*	0.161	–	–	2	9.5	0.067	5.825	0.435	2.224
Fibrosis	40	7.84	0.000*	0.218	–	–	5	5.7	0.010*	4.357*	0.149	2.871
Calcification	19	3.73	0.024*	0.451	–	–	1	3.1	0.501	1.568	0.589	0.524
<b>Lesion location</b>												
Right superior	57	11.18	0.133	0.396			10	5.6	0.000*	20.774*		
Right medial	26	5.10	0.500	2.653			0	0.0	0.384	–		
Right inferior	16	3.14	0.195	0.949			1	2.9	0.533	1.421		
Left superior	35	6.86	0.052	0.279			9	8.3	0.000*	19.000*		
Left media	27	5.29	0.001*	5.571*			0	0.0	1.000	–		
Left inferior	5	0.98	0.080	–			0	0.0	1.000	–		
<b>Lesion extent</b>												
None	33	6.47					1	0.3	0.000*			
Minimal	51	10					1	1.3				
Advanced	7	1.37	0.645	0.081			9	6.2				

\*Denotes significant value

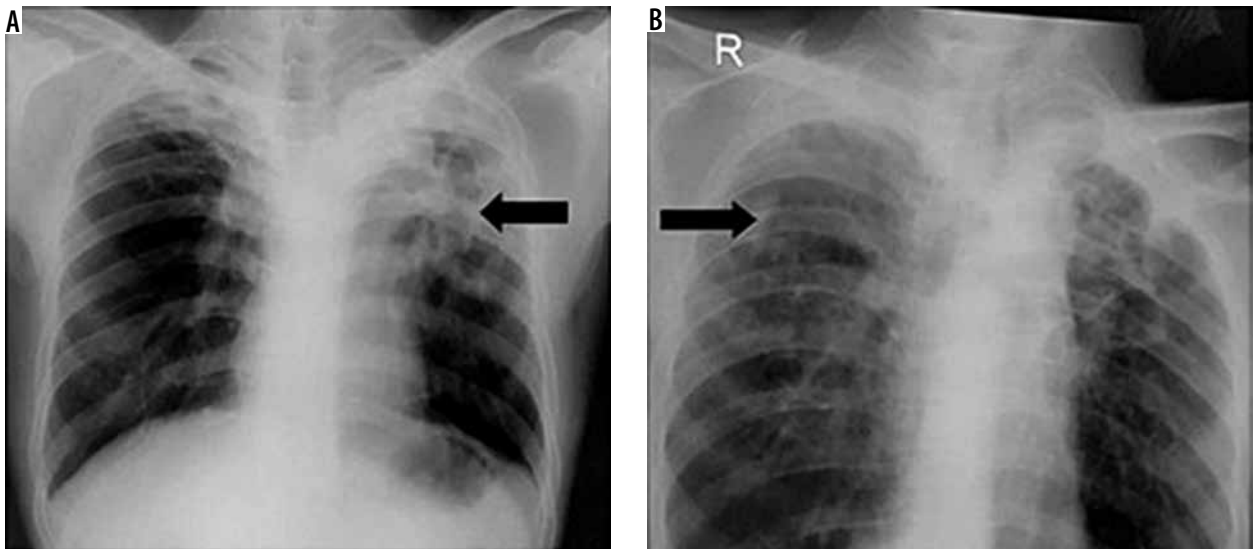
cavities of less than 2.5 cm in diameter, and fibrosis in the right lung lobe. Figure 3A for MDR-TB diagnosis shows consolidation of nodules, cavities, and pleural thickening, but Figure 3B shows infiltrates and nodules. Figure 4A

shows in NTM the presence of consolidated lesions located in the middle field of the right and left lung. Figure 4B shows thin-walled cavity lesions in the right medial lobe and infiltrate lesions in the left ventricular/lingula.

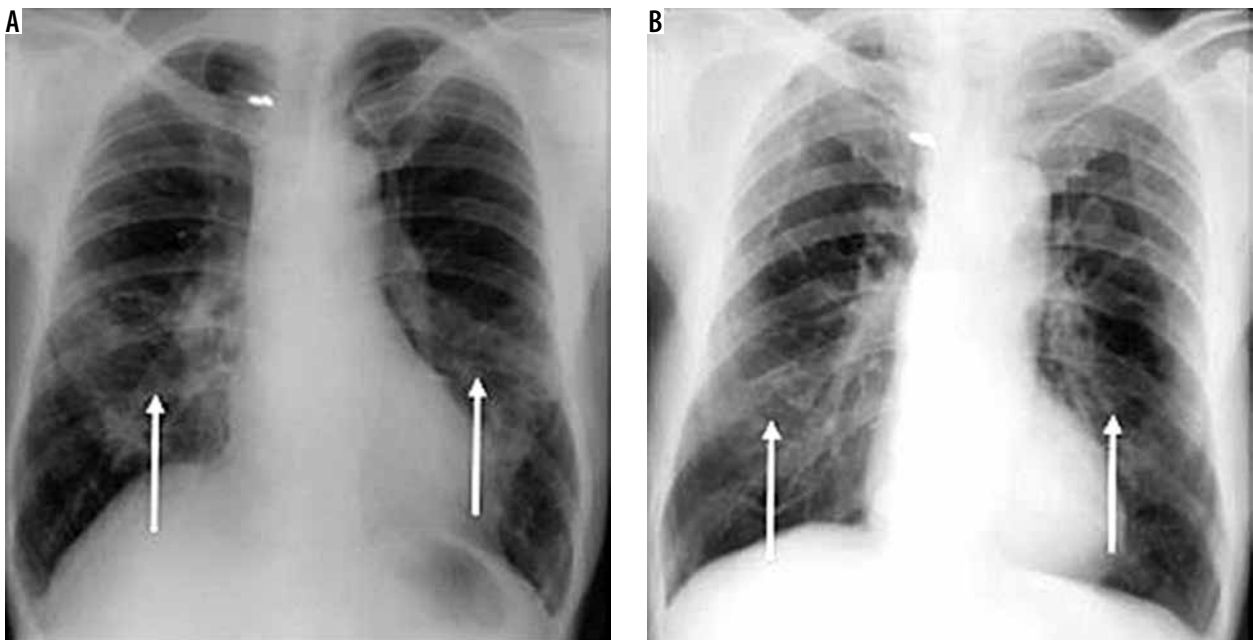


**Figure 2.** Chest X-ray images of non-tuberculous mycobacteria lesion (indicated by black arrow). Barcode number: (A) 143137, (B) 124475





**Figure 3.** Chest X-ray images of multidrug-resistant tuberculosis lesion (indicated by black arrow). Barcode number: (A) 203004, (B) 223046



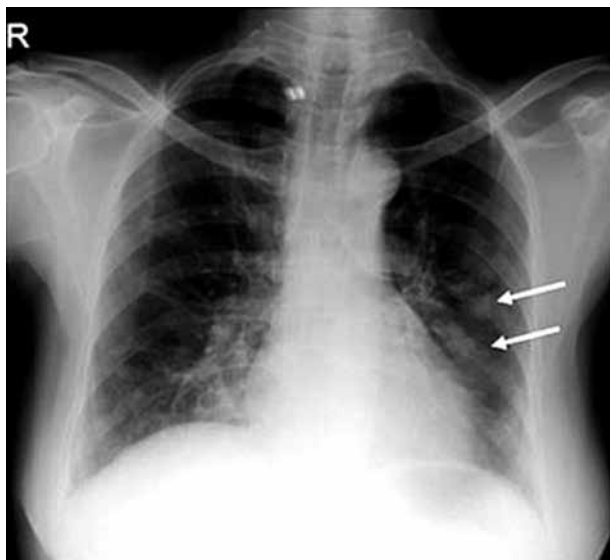
**Figure 4.** Chest X-ray of non-tuberculous mycobacteria diagnosis: consolidation and fibrosis in medium lobe of the lung (white arrow). A) Barcode number: 124475 and B) 120143

Figure 5 shows multiple nodular lesions in the lingula or left ventricular.

Table 4 shows in detail the results of the correlation analysis of lesion type, lesion location, and lesion extent on chest X-rays of NTM and MDR-TB infection. Chest X-ray lesion characteristics of NTM infection are not sufficiently specific to be a predictor of NTM occurrence because all lesions, except a mass, had a significant correlation with NTM occurrence. The lesion location that was a significant predictor of NTM infection was the left ventricular/medial field, with an OR value of 5.571, indicating that the left medial lung had a six-fold higher predictive value for NTM than the other lung sites; however, the lesion area was unrelated to NTM occurrence.

## Discussion

The National TB Survey by the National Institutes of Health Research and Development – NIHRD in 2013–2014 showed the incidence of MDR-TB to be 2.04% and that of NTM to be 70.63% (Table 1). A 1980 US laboratory survey found that approximately 60% of *Mycobacterium* species are non-tuberculous mycobacteria (NTM), in particular, *M. avium* followed by *M. fortuitum* and *M. kansasii* [12]. Some of the clinical symptoms of NTM are the presence of cough for > 2 weeks, fever, and chest pains [11]. From this national TB surveillance data, it can be seen that MDR-TB cases are minimal as compared with NTM cases (2.68%). The probability of a minimum



**Figure 5.** Chest X-ray of multidrug-resistant tuberculosis diagnosis: nodules (white arrow). Barcode number: 1221317

number of MDR-TBs is due to the fact that the research was conducted among a specific target population with a minimum age of 15 years, who had lived in a cluster area for at least one month, had a history of a cough for > 14 days, and had no risk of MDR-TB.

Participants in this research were dominated by people aged above 65 years for NTM and 25-34 years for MDR-TB. This is from the Zambian studies by Ali [12], Park *et al.* [13], and Pascalina *et al.* [14] showing that the highest number of NTM cases were among the elderly (> 65 years old). Age risk factors have a significant correlation with NTM incidence because the elderly have decreased immunity and a higher occurrence of chronic lung disease (COPD) [12-15]. In the present study, NTM cases were more common in males (56.79%) than in females (43.21%); however, gender factors had no significant correlation with NTM occurrence.

Several studies have shown that most MDR-TB cases occur in people between 25 and 34 years of age, which is consistent with other studies that have shown a significant correlation between age (39.0 ± 17.3 years old) and MDR-TB incidence. In general, studies have shown that the age of NTM occurrence is higher than that of MDR-TB occurrence, and several other studies have found that there is no significant correlation between age or gender concerning either NTM or MDR-TB occurrence [16]. Several studies have found that NTM cases occur at an equal rate in both rural and urban areas [17,18]. However, in the present study, MDR-TB is more common in rural than in urban areas. The results of the present study and those from other studies indicate that residing in an urban or rural area does not affect the incidence of MDR-TB or NTM, while a low educational level appears to affect the incidence of MDR-TB and NTM.

Cough was the most common clinical symptom in NTM. This is from a Zambian study by Pascalina *et al.* [14],

**Table 5.** Differences in chest X-ray lesion characteristics of multidrug-resistant tuberculosis (MDR-TB) and non-tuberculous mycobacteria (NTM) between the present and previous studies

Radiographic finding	Present research	Previous research [4,11-13,18-20]
<b>MDR-TB</b>		
Significant lesions/frequent	Infiltrates Cavities Nodules Pleural thickening	Small nodules Multiple cavities with thick walls Bronchiectasis (BE)
Lesion location	Right superior and left superior	All over the lungs (diffuse)
<b>NTM</b>		
Significant lesions/frequent	Varied, non-specific	Thin-walled cavities (MAC) Fibrocavitary lesions Bronchiectasis (BE) Reticulonodular cavities
Lesion location	Left medial lung lobe	Right medial lung lobe Lingula Medial lung lobes (left or right)

which found that the most common clinical symptoms that had a significant correlation with NTM incidence were a cough followed by chest pain, fever at night, and weight loss. In another study, the most common clinical symptoms that had a significant correlation with NTM infection were cough, phlegm cough (91-93%), and shortness of breath [13,16].

Chest X-ray lesion characteristics were highly variable, and no specific lesion could predict NTM infection. A plethora of studies have been conducted in several countries including Korea, China, the US, India, and other Asian countries showing that chest X-ray lesion characteristics of NTM are highly variable, non-specific, and highly dependent on the NTM species [6,12,19,20]. Research correlation between lesion type, lesion location, and lesion extent on chest X-ray and NTM occurrence has mostly been derived from descriptive studies that obtained the most common lesion type in NTM infection in percentage form. Analytical studies regarding the significant correlation between lesion type on chest X-ray and NTM are insufficient.

Several studies have suggested that the chest X-ray lesion with the highest prevalence in NTM infection is the reticulonodular lesion (40%) [13,21,22]. Research by Ali [12] showed that the most common lesion in NTM is the fibrocavitary lesion (90%). Other studies found that the most common lesion in NTM is the nodular lesion [12,14]. According to Piersimoni and Scarparo [20], different lesions exist in NTM infection depending on the species. The cavity and bronchiectasis lesions are most commonly found in *M. avium* complexes, cavities in *M. kansasii*, and cavities

and nodules in *M. celatum*, *M. simiae*, and *M. xenopi*. It was previously reported that the locations of the most common lesions that have predictive power for the occurrence of NTM are the right medial lobe and the left lingula; with some studies mentioning only the medial lobes [12,13].

The studies mentioned above conclude that most chest X-ray lesions in NTM cases are fibrocavitary, bronchiectasis (BE), thin-walled, and reticulonodular cavities, with the most common location being the right medial lobe and lingula or the right and left medial lobes [10,11,15]. However, in the present study, specific/significant lesions on chest X-rays of NTM cases did not exist because infiltrates, cavities, nodules, consolidations, pleural thickening, pleural effusions, fibrosis, and calcification were all significant ( $p < 0.05$ ).

Table 5 shows chest X-ray lesion characteristics of MDR-TB, and NTM incidence is explained in greater detail concerning the differences between the present and previous studies. In contrast to previous studies, the significant lesion of NTM in the present study was varied and non-specific (indistinguishable). The lesion in this study was only located in left medial lung lobe whereas there were three other types in previous studies. Thus, there were a novel information of lesion's characteristics either NTM or MDR-TB.

## Conclusions

This research concluded that chest X-ray lesion characteristics of MDR-TB show significant correlation among cavities, nodules, and fibrosis. Of these three MDR-TB lesion characteristics, the presence of a nodule is the best predictor. Location in the right superior and left superior lungs shows a significant correlation with MDR-TB incidence, while the lesion extent on chest X-ray shows no significant correlation. Chest X-ray lesion characteristics of NTM do not indicate a specific lesion because all lesions except a mass indicate a meaningful correlation. The most common lesion location in NTM incidence is the left medial lung, although statistically, the location of the lesion did not indicate a significant relationship with the incidence of NTM.

## Acknowledgement

The authors thank to the Head of the National Institute of Health Research and Development (NIHRD) for retrieving the data.

## Conflict of interest

The authors report no conflict of interest.

## References

1. World Health Organization. Global tuberculosis report. World Health Organization, Geneva 2015.
2. Wedzina KM, Kopec EA, Weiner M, et al. Tuberculosis in polish zoo as health risc for human. *Health Prob Civil* 2017; 11: 233-238.
3. Cassidy PM, Hedberg K, Saulson A, et al. Nontuberculous mycobacterial disease prevalence and risk factors: A changing epidemiology. *Clin Infect Dis* 2009; 49: e124-129.
4. Kahkouee S, Esmi E, Moghadam A, et al. Multidrug-resistant tuberculosis versus non-tuberculous mycobacterial infections: a CT-scan challenge. *Braz J Infect Dis* 2013; 17: 137-142.
5. Brust JCM, Berman AR, Zalta B, et al. Chest radiograph findings and time to culture conversion in patients with multidrug-resistant tuberculosis and HIV in Tugela Ferry, South Africa. *PLoS One* 2013; 8: e73975.
6. Cherry K, So HP, Sang YO, et al. Comparison of chest CT findings in nontuberculous mycobacterial diseases vs. *Mycobacterium tuberculosis* lung disease in HIV-negative patients with cavities. *PLoS One* 2017; 12: e0174240.
7. Johnson MM, Odell JA. Nontuberculous mycobacterial pulmonary infections. *J Thorac Dis* 2014; 6: 210-220.
8. World Health Organization. Xpert MTB/RIF implementation manual, Technical and operational 'how-to': practical considerations. GPS Publishing, France 2014.
9. Zeka AN, Tasbakan S, Cavusoqlu C. Evaluation of the GeneXpert MTB/RIF assay for rapid diagnosis of tuberculosis and detection of rifampin resistance in pulmonary and Extrapulmonary specimens. *J Clin Microbiol* 2011; 49: 4138-4141.
10. Kumar AJU, Srinivasa H. Fast and accurate identification of *M. tuberculosis* complex using an immunochromatographic MPT64 antigen detection test. *J Tuberc Res* 2015; 3: 149-156.
11. Murray PR, Baron JH, Jorgensen MA, et al. Manual of clinical microbiology. 8<sup>th</sup> ed. American Society for Microbiology, Washington 2003.
12. Ali J. Nontuberculous mycobacterial infection: focus on pulmonary disease. *J Clin Outcomes Manag* 2009; 16: 431-439.
13. Park HY, Suh GY, Chung MP, et al. Comparison of clinical and radiographic characteristics between nodular bronchiectatic form of nontuberculous mycobacterial lung disease and diffuse panbronchiolitis. *J Korean Med Sci* 2009; 24: 427-432.
14. Chanda-Kapata P, Kapata N, Klinkenberg E, et al. Non-tuberculous mycobacteria (NTM) in Zambia: prevalence, clinical, radiological and microbiological characteristics. *BMC Infect Dis* 2015; 15: 500.
15. Shin HW, Cheng MH, Jang JL. Diagnosis of tuberculosis by PCR-based amplification of Mpt64 gene from peripheral blood. *Int J Biomed Lab Sci* 2013; 2: 25-30.
16. Chung MJ, Lee KS, Koh WJ, et al. Drug-sensitive tuberculosis, multidrug-resistant tuberculosis, and nontuberculous mycobacterial pulmonary disease in nonAIDS adults: comparisons of thin-section CT findings. *Eur Radiol* 2006; 16: 1934-1941.



17. Adjemian J, Oliver KN, Seitz AE, et al. Spatial clusters of nontuberculous mycobacterial lung disease in the United States. *Am J Respir Crit Care Med* 2012; 186: 553-558.
18. Lin C, Russell C, Soll B, et al. Increasing prevalence of nontuberculous mycobacteria in respiratory specimens from US-Affiliated Pacific island jurisdictions. *Emerging Infect Dis* 2018; 24: 48491.
19. Dholakia YN, D'souza DTB, Tolani MP, et al. Chest X-rays and associated clinical parameters in pulmonary tuberculosis cases from the National Tuberculosis Program, Mumbai, India. *Infect Dis Rep* 2012; 4: e10.
20. Piersimoni C, Scarparo C. Pulmonary infections associated with nontuberculous mycobacteria in immunocompetent patients. *Lancet Infect Dis* 2008; 8: 323-334.
21. Han D, Lee KS, Koh WJ, et al. Radiographic and CT findings of nontuberculous mycobacterial pulmonary infection caused by *Mycobacterium abscessus*. *Am J Roentgenol* 2003; 181: 513-517.
22. Icksan AG, Napitupulu MRS, Nawas MA, et al. Chest X-Ray findings comparison between multi-drug-resistant tuberculosis and drug-sensitive tuberculosis. *J Nat Sci Biol Med* 2018; 9: 42-46.