

Spontaneous Resolution of Epidural Hematoma: A Rare Case

Abstract

An epidural hematoma is a life-threatening condition which necessitates early surgical intervention. Conservative management is undertaken in smaller hematomas; rarely, a massive hematoma may show spontaneous resolution which can be picked up only by a repeat computed tomography before surgery. Here, we report one such case where we noted a surprisingly rapid resolution of an epidural hematoma, which was relatively a large clot and where the last minute call to have a repeated computed tomography scan changed the line of management altogether from a surgical one to conservative. The patient in this particular case is a 20-year-old male, with a history of fall from height. The initial scan showed a large epidural hematoma which requires surgical evacuation, whereas the subsequent scans showed near-complete resolution and hence was managed conservatively. Rare cases like these should always be kept in mind, and the importance of a repeat scan should never be disregarded.

Keywords: *Computed tomography, epidural hematoma, spontaneous resolution*

Introduction

An epidural hematoma is an emergency which is never neglected by any neurosurgeon all around the world. It is probably the most common emergency encountered by a neurosurgeon. For an epidural hematoma with significant mass effect, surgical evacuation is the standard norm. Hematomas without mass effect can be watched closely, and a call is taken regarding surgery. The neurological status of the patient and the volume of the hematoma are considered, and emergency craniotomy and evacuation are also taken up. Spontaneous resolution of hematomas has been reported in the past, which usually takes days to weeks. We have come across an epidural hematoma which showed rapid spontaneous resolution within 7 h of the injury.

Case Report

A 20-year-old male patient, with an alleged history of accidental fall from a height of about 20 feet, presented to the emergency department on May 30, 2018. Initially, he was taken to a local hospital where computed tomography of the head was done which revealed an extra-axial hyperdense collection of hemorrhagic attenuation with

few air pockets within and along the right parietal and anterior temporal convexity with mass effect in the form of compression of right lateral ventricle and minimal midline shift to left [Figures 1b and 2] along with fracture of right parietal bone extending up to squamous and mastoid parts of right temporal bone [Figure 1a]. Hemorrhage was noted along the falx. The initial scan was done at a primary center where no neurosurgeon was available, and hence, he was shifted to our tertiary care center 7 h after the initial scan. On general examination, the patient was in a state of unconsciousness, with stable vital signs. Right otorrhagia was noted which can be attributed to the fracture described above. On neurological examination, Glasgow Coma Scale score was E1V2M3, and anisocoria was noted with right pupil size of 5 mm and left pupil size of 2 mm. Both pupils were sluggishly reacting to light. The patient was intubated and a computed tomography of the brain was repeated which, to our astonishment, revealed no epidural hematoma but showed hemorrhage along the falx, and the same fracture details described above and an increased epicranial soft-tissue thickening were also noted [Figures 1c and 3]. Another scan was taken after 4 h, and no change in the status was noted. After 2 days of admission and intensive neurological care, the patient

**Srikrishnaditya Manne,
Siddhartha Reddy Musali,
Prakash Rao Gollapudi,
Ravi Karla**

*Department of Neurosurgery,
Gandhi Medical College
and Hospital, Secunderabad,
Telangana, India*

Address for correspondence:

*Dr. Srikrishnaditya Manne,
12-13-677/113, Street
No. 1, Lane No. 2,
Kimtee Colony, Tarnaka,
Secunderabad - 500 017,
Telangana, India.
E-mail: aditya.6356@gmail.com*

Access this article online

Website: www.asianjns.org

DOI: 10.4103/ajns.AJNS_173_18

Quick Response Code:



How to cite this article: Manne S, Musali SR, Gollapudi PR, Karla R. Spontaneous resolution of epidural hematoma: A rare case. *Asian J Neurosurg* 2019;14:292-4.

This is an open access journal, and articles are distributed under the terms of the Creative Commons Attribution-NonCommercial-ShareAlike 4.0 License, which allows others to remix, tweak, and build upon the work non-commercially, as long as appropriate credit is given and the new creations are licensed under the identical terms.

For reprints contact: reprints@medknow.com

succumbed to sudden cardiopulmonary arrest due to ventricular arrhythmias.

The initial intention was not to go for a conservative management. However, the first scan was done at a rural center where no neurosurgeon was available and hence referred to our hospital which is a tertiary care center. By the time the patient reached us, it was almost 6–7 h since the first scan was taken. Hence, an emergency repeat scan was done to assess the current status and take up for surgery, which, to our astonishment, revealed a resolution of the epidural hematoma. Moreover, this changed our plan of management from surgical to conservative.

Discussion

Conservative management for epidural hematoma has been proposed by few authors in selected patients with small hematomas and intact neurological status with the availability of close monitoring along with repeated computed tomography scans. In general, the epidural hematoma results from a complicated form of skull bending, generally from a fracture. In this case, dural vessels are torn as the fracture propagates and travels past a vessel. The mechanical failure of these vessels can also occur without fracture, in as much as skull deformation and bending may be sufficient to cause vascular tears. Spontaneous resolution of epidural hematomas has varying theories. Some of those include the transfer of the clot into the diploic spaces of

the overlying bone, clot getting evacuated itself into the extracranial space through a fracture, and granulation tissue acting as an absorbing structure through sinusoid vessels. Elevated intracranial pressure creates a pressure gradient between epidural hematoma and epicranial soft tissues so that hematoma is forced out of epidural space through fracture line. Although there are few cases which were reported without a fracture.^[1] Malek *et al.*^[2] proposed another theory that it may be due to an elevated epicranial subgaleal interstitial pressure after injury, in which extracranial blood could seep into epidural space through a fracture due to a pressure difference. When interstitial subgaleal pressure decreased, blood leaks back. This process described by Malek *et al.* typically takes about 18 h, which does not hold good for cases which show much earlier resolutions. In our case, the time lag between the first and second scans was just 6 h, and the second scan showed near-complete

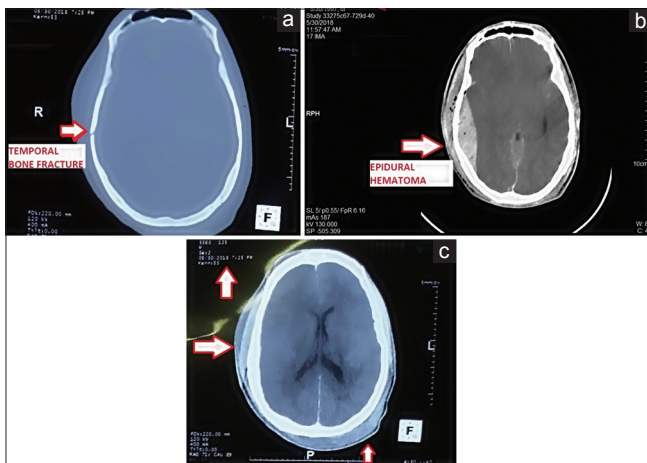


Figure 1: (a) The fracture in the temporal bone, (b) the epidural hematoma, and (c) the absence of epidural hematoma along with a corresponding increase in the epicranial hematoma

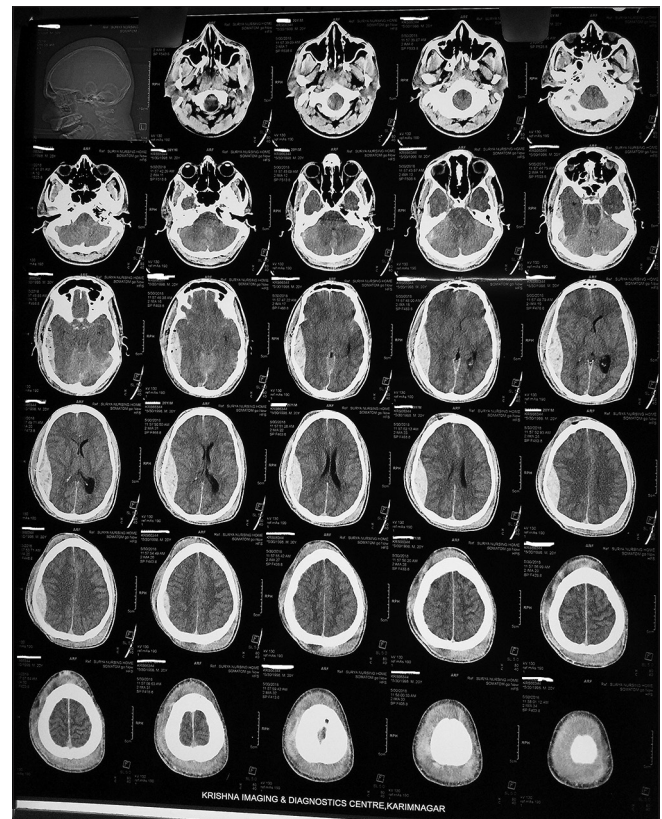


Figure 2: The initial scan was done at a rural center where no neurosurgeon was available, showing a large epidural hematoma approximately 60 ml in volume

Table 1: Previous case reports of spontaneous EDH resolution and their duration to resorption

Authors	Site and side	Age/sex	Skull fracture	Year	Time to resorption
Aoki ^[9]	Left temporal	17/male	Yes	1988	5 h
F. Servadei	Right parietal	65 years/male	Yes	1989	Unknown
H. Dolgun	Right temporal	27 years/male	Yes	2011	3 h
Kang <i>et al.</i> ^[10]	Bilateral posterior fossa	34 years/male	Yes	2005	21 h
Gulsen <i>et al.</i>	Right temporal	4 years/female	No	2013	12 h
Present case	Right temporoparietal	20 years/male	Yes	2018	7 h

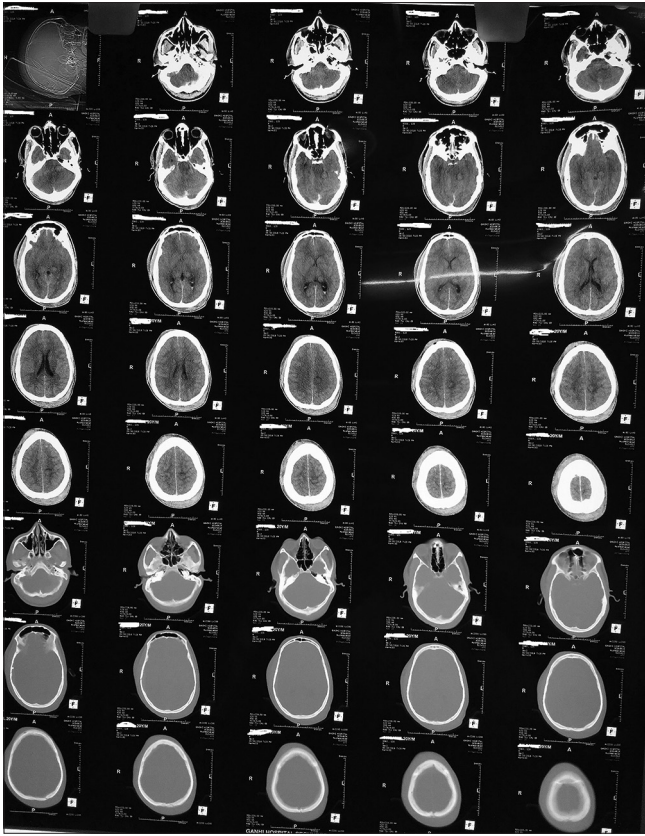


Figure 3: The second scan done at our tertiary care center, showing the resolution of epidural hematoma

resolution of a 60 ml epidural hematoma. The initial cases of spontaneous resolutions of epidural hematomas were described by Weaver *et al.*^[3] The literature research reveals nine pediatric cases^[4,5] and five adult cases.^[6] The oldest patient reported in the literature was 65 years.^[7] Bullock *et al.* reported that epidural hematoma <30 ml with <15 mm thickness and with <5 mm midline shift in patients with a Glasgow Coma Score >8 without focal deficit could be managed nonoperatively with serial computed tomographic scanning and close observation.^[8] In our case [Table 1], we repeated a scan when the patient presented to us in the emergency just for a double confirmation before shifting the patient for emergency craniotomy and evacuation, and to our surprise, we found a near-total resolution, due to which we had to change our plan of management from a surgical one to conservative. Another scan was done 4 h later which revealed no change from the second scan, and we planned to continue our line of conservative management.

Conclusion

Repeat computed tomography scans are often neglected in an obvious case of surgically correctable pathology. A confirmation scan just before a final call for surgery is taken is of utmost importance, especially in cases of traumatic brain injuries, where a neurosurgeon's swift actions decide the prognosis of a patient. In cases of

epidural hematomas, rapid intervention is of utmost importance to prevent cerebral herniation. However, rarely, we may come across cases where there is rapid spontaneous resolution of the hematoma, thus altering our initial plans completely. Hence, one final repeat scan should be done, especially in cases which are referred from other centers. This scan acts as a first-hand confirmation scan, and any change of management plans can be considered thereafter.

Declaration of patient consent

The authors certify that they have obtained all appropriate patient consent forms. In the form the patient(s) has/have given his/her/their consent for his/her/their images and other clinical information to be reported in the journal. The patients understand that their names and initials will not be published and due efforts will be made to conceal their identity, but anonymity cannot be guaranteed.

Financial support and sponsorship

Nil.

Conflicts of interest

There are no conflicts of interest.

References

1. Onal MB, Civelek E, Kırçelli A, Yakupoğlu H, Albayrak T. Re-formation of acute parietal epidural hematoma following rapid spontaneous resolution in a multitraumatic child: A case report. *Turk J Trauma Emerg Surg* 2012;18:524-6.
2. Malek AM, Barnett FH, Schwartz MS, Scott RM. Spontaneous rapid resolution of an epidural hematoma associated with an overlying skull fracture and subgaleal hematoma in a 17-month-old child. *Pediatr Neurosurg* 1997;26:160-5.
3. Weaver D, Pobereskin L, Jane JA. Spontaneous resolution of epidural hematomas. Report of two cases. *J Neurosurg* 1981;54:248-51.
4. Tataryn Z, Botsford B, Riesenburger R, Kryzanski J, Hwang S. Spontaneous resolution of an acute epidural hematoma with normal intracranial pressure: Case report and literature review. *Childs Nerv Syst* 2013;29:2127-30.
5. Gülşen I, Ak H, Sösüncü E, Yavuz A, Kıymaz N. Spontaneous rapid resolution of acute epidural hematoma in childhood. *Case Rep Med* 2013;2013:956849.
6. Dolgun H, Türkoğlu E, Kertmen H, Yılmaz ER, Ergun BR, Sekerci Z. Rapid resolution of acute epidural hematoma: Case report and review of the literature. *Turk J Trauma Emerg Surg* 2011;17:283-5.
7. Servadei F, Staffa G, Pozzati E, Piazza G. Rapid spontaneous disappearance of an acute extradural hematoma: Case report. *J Trauma* 1989;29:880-2.
8. Bullock MR, Chesnut R, Ghajar J, Gordon D, Hartl R, Newell DW, *et al.* Surgical management of acute epidural hematomas. *Neurosurgery* 2006;58:S7-15.
9. Aoki N. Rapid resolution of acute epidural hematoma. Report of two cases. *J Neurosurg* 1988;68:149-51.
10. Kang SH, Chung YG, Lee HK. Rapid disappearance of acute posterior fossa epidural hematoma. *Neurol Med Chir (Tokyo)* 2005;45:462-3.