



ELSEVIER

Contents lists available at [ScienceDirect](https://www.sciencedirect.com)

Trauma Case Reports

journal homepage: www.elsevier.com/locate/tcr

Anterograde venous bullet embolism from the left facial vein to the right ventricle

Hang Yu^{a,*}, China-Li Hillman^a, Adam Globberman^a, Meagan Wiebe^b,
Stephanie Dyck^a

^a Department of Radiology, GA216-820 Sherbrook Street, University of Manitoba, Winnipeg, MB R3T 2N2, Canada

^b Department of Surgery, AE101-820 Sherbrook Street, University of Manitoba, Winnipeg, MB R3A 1R9, Canada

ARTICLE INFO

Keywords:

Bullet
Embolism
Interventional
Radiology
Gunshot
Vascular

ABSTRACT

A young man presented to the emergency department reporting he had been recently shot in the face and chest with an unknown weapon. Initial physical examination only found bruising by the left hemimandible, but CT angiography of the thorax revealed a BB in the right ventricle. A subsequent CT angiography of the head and neck showed no major arterial injury but noted stranding and irregularity of the left facial vein directly deep to the injury site. The findings favoured anterograde venous bullet embolism from the left facial vein to the right ventricle. To our knowledge, this is the first report of a relatively small diameter and superficial vein of the face resulting in this phenomenon.

Case presentation

A young man presented to the emergency department after reporting being shot to the chest and face an hour ago at close range with an unknown weapon.

The patient was hemodynamically stable and had no obvious signs of hemorrhage or injury. Routine bloodwork yielded no significant findings. EKG showed normal sinus rhythm. Physical examination was unremarkable aside from a small area of bruising and equivocal fluctuance overlying the left hemimandible. A face and neck radiograph revealed no radio-opaque foreign body. Despite the reassuring clinical picture, the care team opted for a CT of the head, neck, and thorax to further rule out occult injury.

The non-enhanced CT head and neck revealed no acute intracranial abnormalities. A small area of subcutaneous fat stranding was seen by the left angle of the mandible associated with mild platysmal thickening (Fig. 1), corresponding to the area of bruising. No fractures or additional soft tissue abnormalities were noted, and no foreign bodies were seen.

The CT angiography (CTA) of the thorax, however, revealed a 5 mm spherical metallic foreign body in the right ventricle (Fig. 2), having the classic appearance of a BB. An entry wound was not appreciated, and there were no findings to suggest intrathoracic penetration such as pneumothorax, hemothorax, hemopericardium, or pneumomediastinum. The lungs were clear and there was no major vascular injury.

The patient was re-examined and was found to also have a tiny, thrombosed area by the left angle of the mandible. No thoracic abnormality was again appreciated, and the question was raised regarding bullet embolism from a possible penetrating neck wound. A CTA of the head and neck was pursued to assess for vascular injury.

* Corresponding author at: GA216-820 Sherbrook Street, University of Manitoba, Winnipeg, MB R3T 2N2, Canada.
E-mail address: henry.yu@medportal.ca (H. Yu).

<https://doi.org/10.1016/j.tcr.2021.100552>

Accepted 7 November 2021

Available online 8 November 2021

2352-6440/© 2021 Published by Elsevier Ltd. This is an open access article under the CC BY-NC-ND license

(<http://creativecommons.org/licenses/by-nc-nd/4.0/>).

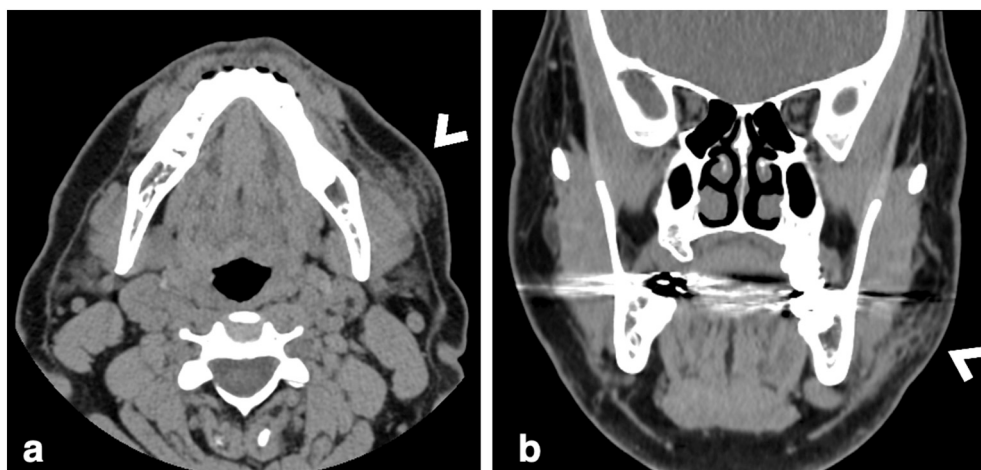


Fig. 1. Nonenhanced CT images of the head and neck in axial (a) and coronal (b) reformats revealed a focal area of platysmal thickening and subcutaneous fat stranding by the left angle of the mandible (arrowhead “<”). The remainder of the scan was unremarkable.

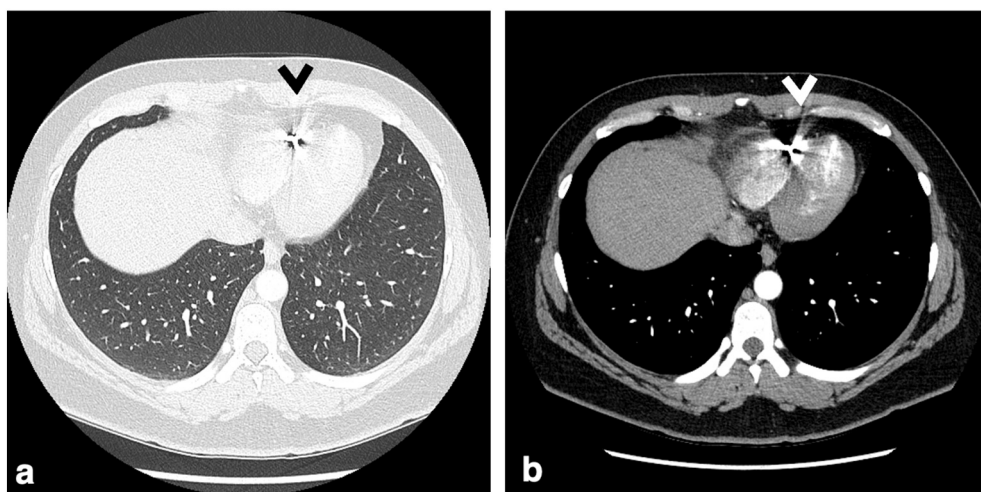


Fig. 2. Axial CT angiography images of the thorax in lung (a) and soft tissue (b) windows showed a 5 mm foreign body in the right ventricle (arrowhead “<”). The remainder of the scan was unremarkable and there was no pneumothorax, hemothorax, hemopericardium, vascular injury, soft tissue or osseous injury, or pulmonary injury to suggest intrathoracic penetration.

CTA of the head and neck revealed no significant arterial injury or contrast extravasation. The left facial vein was directly deep to the area of subcutaneous fat stranding seen by the left mandible with focal vessel wall irregularity and adjacent stranding (Fig. 3). The vessel measured 6 mm in maximum diameter in the region. The clinical and imaging findings suggested a penetrating injury overlying the left hemimandible with antegrade venous bullet embolism from the left facial vein to the right ventricle.

Interventional radiology was consulted for endovascular extraction. The right ventricle was accessed using a right internal jugular approach. The BB was freely mobile and was grasped several times by an EN Snare® endovascular snare device, but ultimately fell out each time (Fig. 4). Additional attempts using a CAT8 mechanical thrombectomy/aspiration catheter adjacent to the BB were also unsuccessful. The procedure was ultimately aborted.

Discussion

Bullet embolism is a rare complication following penetrating gunshot injury with only around 300 cases having been reported in the literature [1]. A review of 7500 gunshot wounds during the Vietnam war had found an incidence of 0.3% [2]. Small and low kinetic energy projectiles such as bullets ≤ 0.38 calibre make up the overwhelming majority of cases [1].

Venous bullet embolism makes up around 20–25% of known cases [1,3]. Sites of initial venous penetration include the transverse sinus, external jugular vein, brachiocephalic vein, superior vena cava, subclavian vein, axillary vein, internal iliac vein, external iliac

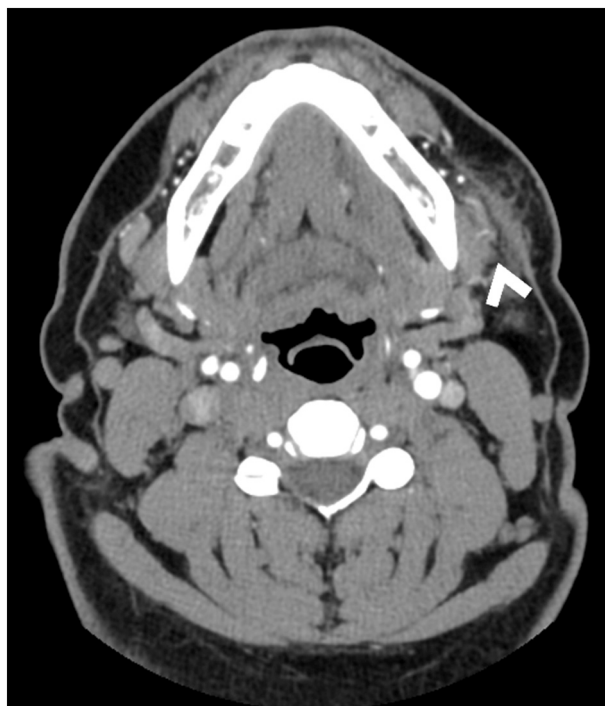

Fig. 3. Axial CT angiography image of the head and neck at the site of injury. No major arterial injury or focus of contrast extravasation was seen. It was noted that the left facial vein (arrowhead “<”) was directly deep to the area of injury and demonstrated focal vessel irregularity and surrounding fat stranding.

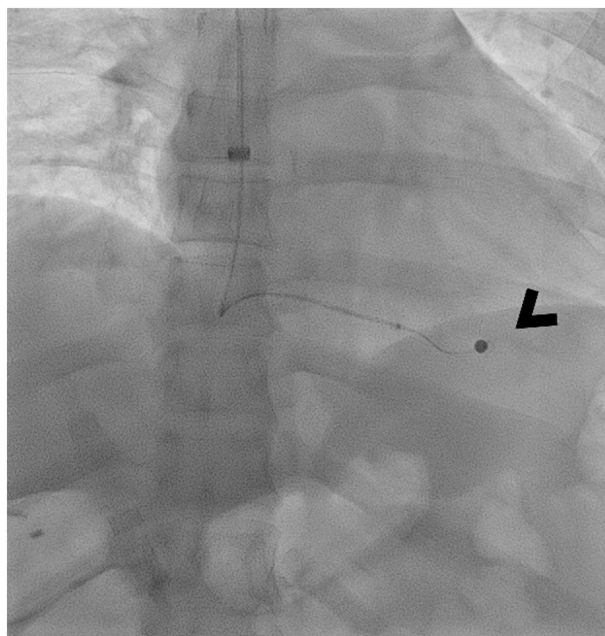


Fig. 4. Fluoroscopic image during endovascular retrieval attempt of the bullet embolus in the right ventricle (arrowhead “<”). Through a right internal jugular vein approach, an EN Snare® endovascular snare device was used for retrieval, which was unsuccessful despite several attempts.

vein, common iliac vein, and inferior vena cava [1,3–7]. Most venous bullet emboli migrate in an antegrade fashion (i.e., in the direction of blood flow) and up to 83% eventually travel to the right heart chambers, where they can become trapped in the myocardium or lodged in the distal branches of the pulmonary arterial tree [3].

The facial vein, also known as the anterior facial vein, is a vein close to the skin surface, which joins the anterior branch of the retromandibular vein to form the common facial vein. This then drains into the internal jugular vein, the brachiocephalic vein, the superior vena cava, and then finally into the right atrium and ventricle. The typical anterograde blood flow path is likely how the BB travelled to the patient's heart. Compared to the initial sites of injury of other venous bullet emboli found in the literature, the facial vein is a relatively small diameter and superficial vein. Our patient's left facial vein measured 6 mm at the site of injury and was just large enough to accommodate the 5 mm BB. In contrast to the high-velocity bullets and shrapnel found in other cases, BBs are typically fired from low-velocity airguns. This made it likelier that the BB had low enough kinetic energy to just penetrate skin and only injure one wall of the left facial vein before coming to rest intraluminally.

Management of venous bullet embolism remains controversial. Treatment options include conservative watchful waiting, or retrieval through thoracotomy and embolectomy or endovascular extraction. While the majority of venous bullet emboli are asymptomatic, severe complications can develop months to years post-injury [1]. These include arrhythmias, infection, pulmonary embolism, valvular dysfunction, thrombosis, myocardial infarction, myocardial erosion, and lead toxicity [1,3,8]. A case review of 45 venous bullet embolism cases between 1987 and 2010 found that 14 out of 45 patients were successfully treated conservatively [3]. However, it has also been found that when treated conservatively, right heart retained missiles have a complication rate of 13% [8]. Given the risks, some authors have advocated for attempted evacuation whenever possible especially those discovered less than six weeks from initial trauma [9]. However, others have argued that select patients can be safely observed, including those with bullet embolus less than 5 mm and bullet embolus firmly lodged in the myocardium as the risk of median sternotomy and cardiopulmonary bypass may be too high to justify retrieval attempt [1,10]. We decided to proceed with extraction given the relatively low complication rate of endovascular intervention and the potential for devastating complications. There was also concern for a possible increased risk of infection as the low-velocity BB would not have been sterilized by heat before penetrating the skin. A repeat attempt with a magnetic endovascular wire was arranged as BBs are typically made of steel and given the BB's mobility during initial retrieval. The attempt was not performed as the patient was unwilling to return for a reattempt at retrieval. We would have likely opted for conservative management had the second attempt failed; further lodging of the BB into the myocardium and reactive fibrosis would have made additional attempts even less likely to succeed and increased the risk of injuring the right ventricle.

In conclusion, our case highlights the potential of anterograde venous bullet embolism from the facial vein into the right ventricle. The possibility of bullet embolism should be considered following penetrating gunshot injury, particularly if no exit wound is found.

References

- [1] T.R. Wojda, S.D. Dingley, S. Wolfe, Terzian WTH, P.G. Thomas, D. Vazquez, Foreign Intravascular Object Embolization and Migration: Bullets, Catheters, Wires, Stents, Filters, and More [Internet]. *Embolic Diseases - Unusual Therapies and Challenges* [cited 2021 Jun 1]. Available from, IntechOpen, 2017, <https://www.intechopen.com/books/embolic-diseases-unusual-therapies-and-challenges/foreign-intravascular-object-embolization-and-migration-bullets-catheters-wires-stents-filters-and-m>.
- [2] K.L. Mattox, A.C. Beall, C.L. Ennix, M.E. DeBakey, Intravascular migratory bullets, *Am. J. Surg.* 137 (2) (1979 Feb) 192–195.
- [3] K.R. Miller, M.V. Bennis, J.D. Sciarretta, B.G. Harbrecht, C.B. Ross, G.A. Franklin, et al., The evolving management of venous bullet emboli: a case series and literature review, *Injury* 42 (5) (2011 May 1) 441–446.
- [4] Y. Yordanov, D. Pateron, A. May, An unusual aetiology of abdominal pain: the forgotten bullet, *Case Rep.* 2014 (2014 Dec 15), bcr2014208268–bcr2014208268, 2014(dec15 1), <https://casereports-bmj-com.uml.idm.oclc.org/content/2014/bcr-2014-208268.info>.
- [5] V. Martí, J.M. Augé, F. Carreras, M.L. Cámara, J.M. Caralps, Bullet embolism of the right ventricle following gunshot wound, *Rev. Esp. Cardiol.* 45 (7) (1992 Sep) 489–491.
- [6] V. Schmelzer, G. Mendez-Picon, A.S. Gervin, Case report: transthoracic retrograde venous bullet embolization, *J. Trauma* 29 (4) (1989 Apr) 525–527.
- [7] V.S. Kaushik, A.K. Mandal, Non-surgical retrieval of a bullet embolus from the right heart 47 (1) (1999 May) 55–57.
- [8] J.B. Lundy, E.K. Johnson, J.M. Seery, T. Pham, J.D. Frizzi, A.B. Chasen, Conservative management of retained cardiac missiles: case report and literature review 66 (4) (2009 Jul) 228–235.
- [9] F.L. Shannon, B.L. McCroskey, E.E. Moore, F.A. Moore, Venous bullet embolism: rationale for mandatory extraction, *J. Trauma* 27 (10) (1987 Oct) 1118–1122.
- [10] K.K. Nagy, M. Massad, J. Fildes, H. Reyes, Missile embolization revisited: a rationale for selective management, *Am. Surg.* 60 (12) (1994 Dec) 975–979.