



Echinostoma macrorchis (Digenea: Echinostomatidae): Metacercariae in *Cipangopaludina chinensis malleata* Snails and Adults from Experimental Rats in Korea

Woon-Mok Sohn*, Byoung-Kuk Na

Department of Parasitology and Tropical Medicine, and Institute of Health Sciences, Gyeongsang National University College of Medicine, Jinju 52727, Korea

Abstract: A survey was performed to know the infection status of echinostome metacercariae in *Cipangopaludina chinensis malleata* snails from Korea. Total 75 snails collected in 5 localities, i.e., Imsil-gun, Jeollabuk-do, Hwasun-gun and Shinan-gun (Aphae and Jido), Jeollanam-do, and Jinju-si, Gyeongsangnam-do, were examined for metacercariae by the artificial digestion method. Infection rates of metacercariae were 80.0%, 66.7%, 100%, 60.0%, and 73.3%, and their densities were 39, 32, 183, 19, and 30 per snail infected, respectively. The metacercariae were round, 105-118 × 105-118 μm in size, with a thin cyst wall, collar spines on the head collar, and excretory granules in 2 canals of excretory tube. Adult flukes were elongated, ventrally curved, and 5,167 × 939 μm in average size. Head collar distinct, bearing 45 collar spines with 5 end groups on each side. Oral sucker subterminal, pharynx well developed, and esophagus somewhat short. Cirrus sac well developed, with a saccular seminal vesicle, and ventral sucker very large. Ovary elliptical and on the median line of the body. Testes tandem and slightly lobed. Eggs operculated, elliptical, and 90-103 × 55-60 μm in size. By scanning electron microscopy, the head collar was prominent with 45 collar spines resembling horns of younger stags. Scale-like tegumental spines were densely distributed on the body surface between the head collar and ventral sucker. Conclusively, it has been first confirmed that the life cycle of *E. macrorchis* is indigenously maintained in Korea, and *C. chinensis malleata* snails are popularly infected with the metacercariae of this echinostome.

Key words: *Echinostoma macrorchis*, *Cipangopaludina chinensis malleata*, metacercaria, adult, Korea

INTRODUCTION

Echinostomes (fluke members of the family Echinostomati- dae) are medically important because they can cause severe epigastric or abdominal pain accompanied by diarrhea, mal- nutrition, and fatigue. A total of 20 species belonging to 8 gen- era, i.e., *Echinostoma*, *Echinochasmus*, *Acanthoparyphium*, *Arty- fechinostomum*, *Episthmium*, *Himasthla*, *Hypoderaeum*, and *Isthmiophora*, are known to infect humans worldwide. Among these 8 genera, *Echinostoma* is the type genus and the largest group. More than 6 species, i.e., *Echinostoma angustitestis*, *E. ci- netorchis*, *E. echinatum*, *E. ilocanum*, *E. macrorchis*, and *E. revolu- tum* are known to infect humans [1,2]. *E. macrorchis* was origi- nally described from naturally infected house rats in Japan [3].

After then, this echinostome has been found in humans, birds, and other rodent species in Japan [4-8]. In Taiwan and Lao PDR, the presence of this fluke species was also confirmed by the detection of adults and larval stages [9-12].

In the Republic of Korea (= Korea), total 21 echinostome species in 14 genera, i.e., *Acanthoparyphium marilae*, *A. tyose- nense*, *Chaumocephalus ferox*, *Echinochasmus japonicus*, *E. perfolia- tus*, *Echinoparyphium recurvatum*, *Echinostoma cinetorchis*, *E. gotoi*, *E. miyagawai*, *E. revolutum*, *Euparyphium murinum*, *Him- asthla alincia*, *H. kusasigi*, *H. megacotyle*, *Isthmiophora hortensis*, *Nephrostomum ramosum*, *Patagifer bilobus*, *Pegosomum bubulcum*, *Petasiger neocomense*, *Saakotrema metatestis*, and *Stephanoprora* sp., have been reported in the literature [1,13-16]. Only 4 of these species, i.e., *A. tyosenense*, *E. japonicus*, *E. cinetorchis*, and *I. hortensis*, are known to be the causative agents of human echi- nostomiasis in Korea [1]. Especially, *I. hortensis* has been re- ported as the dominant species with several endemic foci [17- 20], and clinical cases which have been sporadically diagnosed by recovery of adult worms in gastroduodenal endoscopy [21- 25]. Meanwhile, the presence of *E. macrorchis* had not been re-

•Received 7 May 2017, revised 2 July 2017, accepted 2 August 2017.

*Corresponding author (wmsohn@gnu.ac.kr)

© 2017, Korean Society for Parasitology and Tropical Medicine

This is an Open Access article distributed under the terms of the Creative Commons Attribution Non-Commercial License (<http://creativecommons.org/licenses/by-nc/4.0>) which permits unrestricted non-commercial use, distribution, and reproduction in any medium, provided the original work is properly cited.

ported in Korea. Therefore, we seriously needed to describe the infection status of metacercariae of this species in snail second intermediate hosts as well as the morphological characteristics of adults recovered from experimental rats to support its taxonomic validity in the faunistic view point.

MATERIALS AND METHODS

We collected *Cipangopaludina chinensis malleata* snails (Fig. 1) in irrigation ditches, ponds, and paddies in 5 localities, i.e., Imsil-gun (gun = county), Jeollabuk-do (do = province), Hwasun-gun and Shinan-gun (Aphae-myeon and Jido-myeon) (myeon = township), Jeollanam-do, and Jinju-si (si = city), Gyeongsangnam-do, Korea. They were transferred to our laboratory with ice, and digested with pepsin-HCl solution at 36°C for 2 hr after crushing their shells with a mortar. The digested material was filtered with 1 × 1 mm of mesh, and washed with 0.85% saline until the supernatant is clear. The sediment was



Fig. 1. Two *Cipangopaludina chinensis malleata* snails, the second intermediate host of *Echinostoma macrorchis*, collected from a pond in Jinju-si, Gyeongsangnam-do, Korea.

carefully examined under a stereomicroscope. The echinostome metacercariae were identified by the general morphological features, and they were counted to get hold of infection rates (%) and densities (no. of metacercariae per snail infected) by the surveyed areas. Collected metacercariae by the surveyed areas were morphologically observed and measured under a light microscope equipped with a micrometer (OSM-4, Olympus, Tokyo, Japan), and they were orally infected to rats to obtain the adult worms. Adult worms were recovered from the small intestines of rats at 15-30 days after the infection. In animal experiments, the guidelines of animal experiments from Gyeongsang National University School of Medicine were followed.

Recovered adults were fixed with 10% neutral buffered formalin under the cover glass pressure, stained with Semichon's acetocarmine, and observed under a light microscope. To observe the surface ultrastructure, some of them were washed several times with 0.2 M cacodylate buffer (pH 7.2) and fixed with 2.5% glutaraldehyde at 4°C. After washing 3 times with the buffer, they were dehydrated through a graded alcohol series (50, 70, 80, 90, 95%, and absolute), dried with hexamethyldisilazane, coated (JFC-1100E ion sputtering device, Tokyo, Japan) with gold, and observed with a scanning electron microscope (Philips XL-30S, Eindhoven, the Netherlands) at a 15 kV accelerating voltage.

To observe morphological characteristics and differential indices by the ages of worms, each of 10 *E. macrorchis* specimens recovered from experimental rats at 15, 20, 25, and 30 days after infection were analyzed in this study. We basically measured the body length (BL) and width (BW), the size of oral (OS) and ventral suckers (VS), pharynx, esophagus, head collar, cirrus sac, ovary, and 2 testes, and additionally the forebody length (FBL: from the anterior end to the anterior margin of the ventral sucker), hindbody length (HBL: from the posterior margin of the posterior testis to the posterior end) and

Table 1. Infection status of *Echinostoma macrorchis* metacercariae in *Cipangopaludina chinensis malleata* collected from 5 localities of Korea

Locality examined	No. of snails examined	No. (%) of snails infected	No. of metacercariae detected		
			Total	Range	Average
Jeollabuk-do Imsil-gun	15	12 (80.0)	464	8-86	39
Jeollanam-do Hwasun-gun	15	10 (66.0)	322	5-107	32
Shinan-gun (Aphae)	15	15 (100)	2,741	38-412	183
Shinan-gun (Jido)	15	9 (60.0)	14	2-48	19
Gyeongsangnam-do Jinju-si	15	11 (73.3)	325	10-115	30

uterus length (UL: from the posterior margin of the ventral sucker to the anterior margin of the ovary). Then, we also calculated the ratios of BL/BW, VS/OS, the length/width in ovary and 2 testes, and percentage (%) of FBL/BL, HBL/BL, and UL/BL as the differential indices of this fluke. Measurements and scales are in micrometres (μm).

RESULTS

Infection status with metacercariae in *Cipangopaludina chinensis malleata*

The metacercariae of *E. macrorchis* were detected in 80.0, 66.7, 100, 60.0, and 73.3% of *Cipangopaludina chinensis malleata* snails collected from Imsil-gun, Hwasun-gun, Shinan-gun (Aphae and Jido), and Jinju-si, and their densities were 39, 32, 183, 19, and 30 per snail infected, respectively (Table 1).

Morphology of metacercariae (Fig. 2)

The metacercariae ($n=20$) were round, 105-118 (110) \times 105-

118 (108) in size, with a thin cyst wall, collar spines distributed in the head collar and excretory granules in 2 descending canals of the main excretory tube.

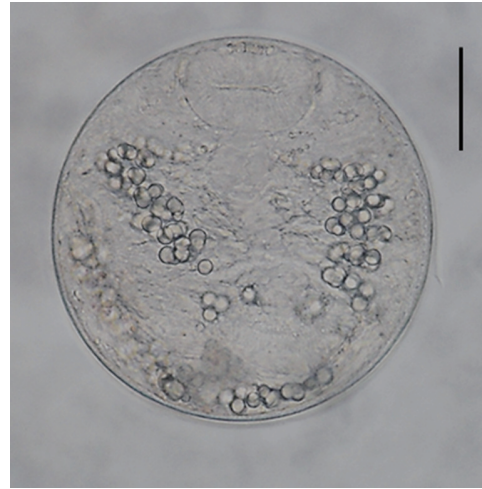


Fig. 2. A metacercariae of *Echinostoma macrorchis* detected in a snail from Jinju-si, Gyeongsangnam-do, Korea. Scale bar = 30 μm .

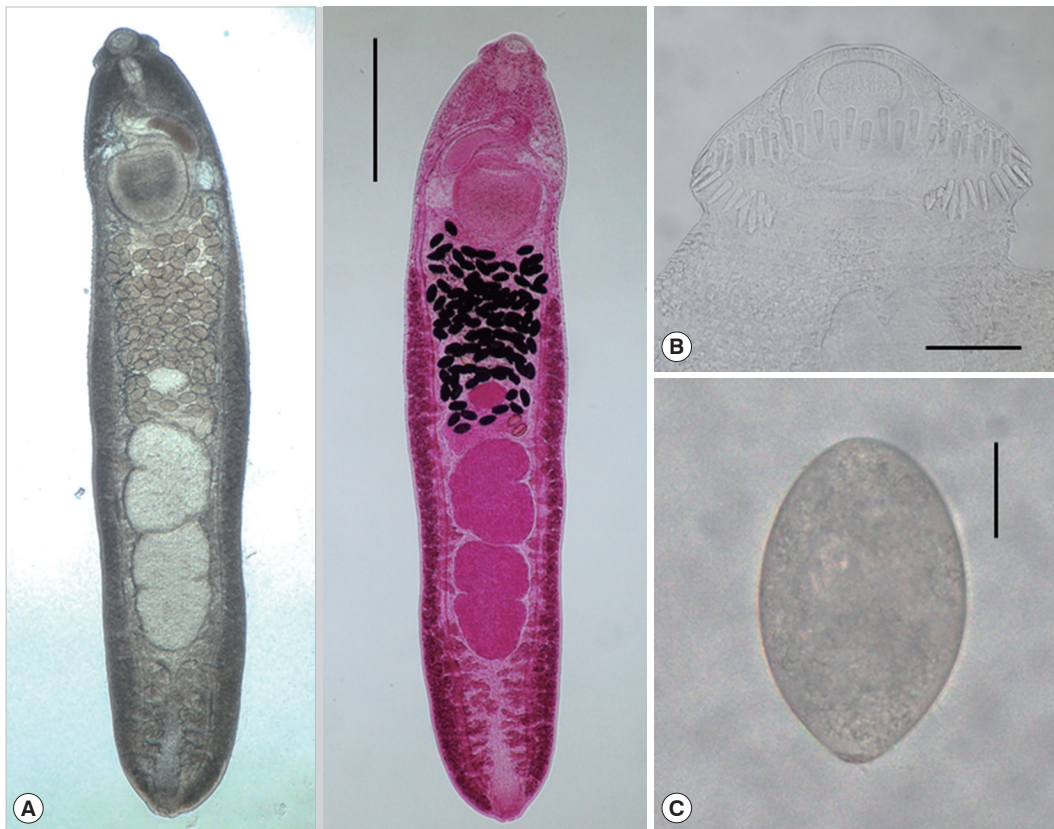


Fig. 3. Adult worm of *E. macrorchis* (ventral view: fresh unstained and dorsal view: Semichon's acetocarmine stained) recovered from an experimental rat at 18 days after infection (A). Scale bar = 1,000 μm . Head collar with 45 collar spines, including 5 end groups on each side (B). Scale bar = 100 μm . An egg discharged in the feces of a rat experimentally infected with metacercariae (C). Scale bar = 30 μm .

Morphological characteristics of adult worms (Fig. 3)

Total 40 adults recovered from rats experimentally infected with the metacercariae from snails in Imsil-gun, Hwasun-gun, Shinan-gun (Aphae), Jinju-si, were measured and morphologically observed (Table 2). They were elongated, ventrally curved, 3,950-6,000 (5,167) long and 700-1,175 (939) wide. Head collar distinct, 300-375 (334) in width, bearing 45 collar

spines with 5 end group ones on each side. Oral sucker subterminal, 105-150 (123) × 150-185 (167) in size. Prepharynx very short. Pharynx well developed, 130-165 (150) × 95-130 (115) in size. Esophagus relatively short, 95-175 (135) long. Cirrus sac well developed, with a saccular seminal vesicle, 220-550 (410) × 85-225 (163) in size. Ventral sucker very large, 395-490 (441) × 405-490 (447) in size. Ovary elliptical, 150-290 (227)

Table 2. Dimensions^a of *Echinostoma macrorchis* adults recovered from rats experimentally infected with metacercariae from *Cipango-paludina* snails from 4 localities of Korea

Organs	Imsil-gun ^b , Jeollabuk-do	Hwasun-gun ^c , Jeollanam-do	Shinan-gun ^d , Jeollanam-do	Jinju-si ^e , Gyeongsangnam-do	Total
Body (L)	4,075-5,700 (4,718)	3,950-5,750 (5,178)	4,550-6,000 (5,363)	4,850-5,950 (5,408)	3,950-6,000 (5,167)
(W)	700-1,175 (818)	750-1,175 (1,013)	825-1,000 (948)	925-1,050 (978)	700-1,175 (939)
Oral sucker (L)	105-135 (121)	110-135 (123)	105-135 (121)	115-150 (125)	105-150 (123)
(W)	150-175 (160)	150-180 (168)	160-185 (172)	155-180 (168)	150-185 (167)
Head crown (W)	300-355 (321)	300-355 (333)	315-375 (343)	315-355 (337)	300-375 (334)
Pharynx (L)	135-150 (142)	130-165 (154)	135-160 (151)	145-165 (154)	130-165 (150)
(W)	100-125 (113)	95-130 (117)	105-115 (112)	105-130 (117)	95-130 (115)
Esophagus (L)	100-160 (135)	95-150 (131)	110-160 (136)	105-175 (139)	95-175 (135)
Ventral sucker (L)	395-485 (438)	400-490 (458)	410-460 (433)	425-440 (434)	395-490 (441)
(W)	405-455 (433)	425-490 (455)	425-485 (455)	425-470 (445)	405-490 (447)
Cirrus sac (L)	220-375 (294)	330-475 (412)	410-525 (462)	425-550 (471)	220-550 (410)
(W)	85-160 (119)	140-225 (176)	155-225 (174)	150-225 (181)	85-225 (163)
Ovary (L)	150-250 (188)	180-275 (223)	200-275 (231)	225-290 (264)	150-290 (227)
(W)	160-335 (211)	160-325 (275)	220-275 (238)	250-305 (276)	160-335 (250)
Anterior testis (L)	460-870 (588)	540-990 (765)	630-900 (740)	590-850 (710)	460-990 (701)
(W)	270-630 (360)	320-550 (464)	400-470 (443)	390-470 (439)	270-630 (427)
Posterior testis (L)	550-950 (715)	640-1,080 (917)	760-1,000 (826)	700-900 (826)	550-1,080 (821)
(W)	280-550 (332)	300-480 (431)	400-450 (419)	370-460 (422)	280-550 (401)

^a(L): length; (W): width; unit is μm . Each 10 worms recovered from rats at 18^b, 20^{c,d}, and 21^e days after infection were measured.

Table 3. Dimensions^a of *Echinostoma macrorchis* adults recovered from rats experimentally infected with metacercariae from *Cipango-paludina* snails of Shinan-gun, Jeollanam-do

Organs	15-day-old (n=10)	20-day-old (n=10)	25-day-old (n=10)	30-day-old (n=10)
Body (L)	4,300-4,775 (4,495)	4,550-6,000 (5,363)	4,400-6,325 (5,303)	5,500-6,800 (6,265)
(W)	725-950 (848)	825-1,000 (948)	850-1,200 (920)	1,050-1,250 (1,135)
Oral sucker (L)	100-125 (113)	105-135 (121)	110-135 (119)	120-140 (132)
(W)	140-170 (155)	160-185 (172)	155-180 (170)	155-200 (178)
Head crown (W)	285-325 (311)	315-375 (343)	315-360 (348)	325-400 (354)
Pharynx (L)	125-150 (141)	135-160 (151)	150-160 (154)	150-175 (160)
(W)	85-110 (99)	105-115 (112)	105-125 (119)	105-145 (126)
Esophagus (L)	105-160 (129)	110-160 (136)	115-160 (131)	110-160 (134)
Ventral sucker (L)	380-420 (399)	410-460 (433)	435-470 (449)	455-525 (482)
(W)	390-440 (412)	425-485 (455)	430-500 (470)	460-515 (494)
Cirrus sac (L)	350-465 (407)	410-525 (462)	325-525 (458)	450-550 (508)
(W)	130-165 (148)	155-225 (174)	150-200 (177)	175-210 (190)
Ovary (L)	150-225 (199)	200-275 (231)	190-325 (232)	210-325 (273)
(W)	200-225 (214)	220-275 (238)	210-300 (246)	225-325 (282)
Anterior testis (L)	480-660 (560)	630-900 (740)	600-750 (664)	700-1,060 (893)
(W)	300-400 (356)	400-470 (443)	310-500 (387)	400-530 (472)
Posterior testis (L)	550-690 (653)	760-1,000 (826)	670-970 (748)	860-1,120 (964)
(W)	290-390 (347)	400-450 (419)	330-500 (378)	370-500 (456)

^a(L): length; (W): width; unit is μm .

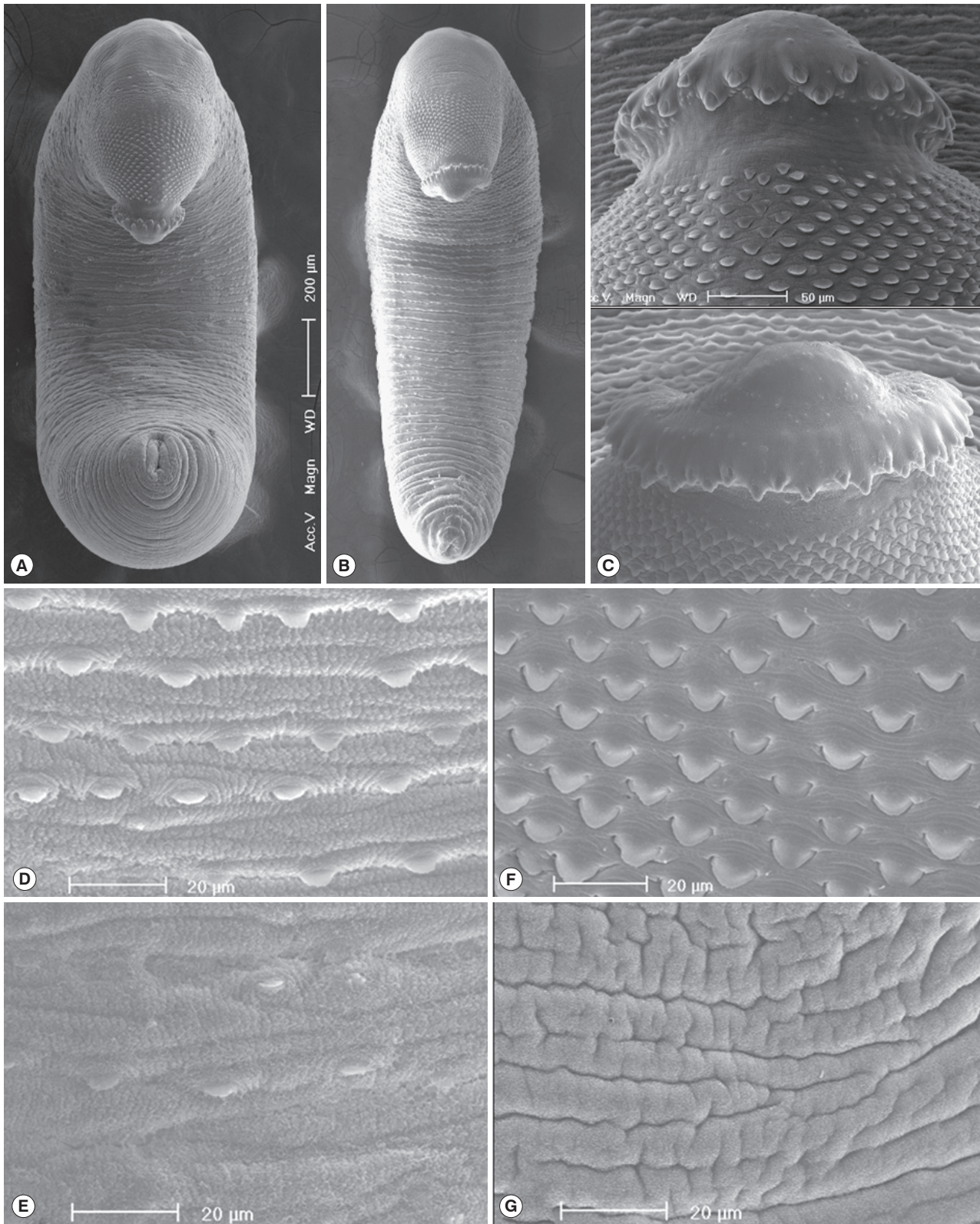


Fig. 4. Scanning electron microscopic (SEM) view of *E. macrorchis* adults. Whole ventral view of the worms originated from Hwasung-gun (A) and Jinju-si (B). Dorsal views of the head collar with collar spines alternatively arranged (C). Tegument with numerous scale-like spines on the ventro-anterior surface, just behind the ventral sucker (D), and dorso-anterior body surface (F), with spines sparsely distributed on the ventro-middle surface (E), and no spines on the dorso-middle body surface (G).

Table 4. Differential indices of *Echinostoma macrorchis* adults recovered from rats experimentally infected with metacercariae from *Cipangopaludina* snails of Shinan-gun, Jeollanam-do

Organs	15-day-old	20-day-old	25-day-old	30-day-old	Range
Body (L)/(W)	5.30	5.66	5.76	5.52	5.30-5.76 (5.56)
Ventral sucker/Oral sucker	3.03	3.03	3.18	3.15	3.03-3.18 (3.10)
Ovary (L)/(W)	0.93	0.97	0.94	0.97	0.93-0.97 (0.95)
Anterior testis (L)/(W)	1.57	1.67	1.72	1.89	1.57-1.89 (1.71)
Posterior testis (L)/(W)	1.88	1.97	1.98	2.11	1.88-2.11 (1.99)
FBL/BL ^a × 100	13.40%	12.70%	12.50%	11.30%	11.3-13.4 (12.5)%
HBL/BL ^b × 100	20.40%	21.90%	21.00%	18.90%	18.9-21.9 (20.6)%
UL/BL ^c × 100	27.50%	25.40%	28.30%	31.50%	25.4-31.5 (28.2)%

^aForebody length/Body length; ^bHindbody length/Body length; ^cUterus length/Body length.

× 160-335 (250) in size, and on the median line of the body. Testes tandom slightly lobed, 460-990 (701) × 270-630 (427) (anterior testis) and 550-1,080 (821) × 280-550 (401) (posterior testis). Vitelline follicles bilaterally distributed from the anterior 1/3 level of uterine field to the posterior end. Numerous eggs contained in the uterus located between the posterior margin of ventral sucker and ovary. Eggs operculated, elliptical and 93-105 (99) × 53-64 (58) in size. Dimensions of *E. macrorchis* by the age of worms are revealed in Table 3.

In SEM observations, adult worms were elongated, ventrally curved and had the largest width near the middle portion of the body (Fig. 4A, B). The head collar was well-developed and prominent bearing total 45 collar spines. A dorsal view of the head collar showed 2 alternating rows of collar spines. Sensory papillae were distributed mainly on the tegument around the 2 suckers and head collar (Fig. 4C). Scale-like tegumental spines were densely distributed on the body surface between the head collar and ventral sucker level (Fig. 4F), and their densities decreased posteriorly on the ventral surface (Fig. 4D, E). However, the dorsal tegument behind the ventral sucker level was devoid of spines (Fig. 4G).

Differential indices of adult worms

The ratio of body length (BL) to body width (BW) was 5.30-5.76 (5.56 in average). That of ventral sucker (VS) to oral sucker (OS) was 3.03-3.18 (3.10). The ratio of length (L)/width (W) in the ovary was 0.93-0.97 (0.95), that in the anterior testis was 1.57-1.89 (1.71), and in the posterior testis was 1.88-2.11 (1.99). The percentage of forebody length (FBL) to BL was 11.3-13.4 (12.5), and that of hindbody length (HBL) to BL was 18.9-21.9 (20.6). The percentage of uterine field (U) to BL was 25.4-31.5 (28.2) (Table 4).

DISCUSSION

By the present study, it has been confirmed for the first time that the life cycle of *E. macrorchis* is indigenously maintained in Korea. Thus, this echinostome species is added among the list of Korean echinostome fauna.

Various species of molluscs, including *Assimineae*, *Biomphalaria*, *Bulinus*, *Cipangopaludina*, *Corbicula*, *Gyraulus*, *Hippeutis*, *Lymnaea*, *Physa*, *Segmentina*, and *Thiara*, and amphibians, such as frogs (*Rana* spp.) and salamanders (*Hynobius* sp.), have been reported as the second intermediate hosts of *E. macrorchis* in Japan and Taiwan [11,26-29]. Recently, *Cipangopaludina* sp. snails from Vientiane Municipality, Lao PDR, was also confirmed to be the second intermediate host of *E. macrorchis* [12]. In the present study, it was revealed that *C. chinensis malleata* are popularly infected with the metacercariae of this echinostome in Korea. Accordingly, *Cipangopaludina* spp. snails are regarded as a suitable second intermediate host of *E. macrorchis* in Japan, Taiwan, Lao PDR, and Korea. On the other hand, 2 species of freshwater snails, i.e., *Segmentina hemisphaerula* and *Gyraulus chinensis*, are known to be the first intermediate host of *E. macrorchis* in Japan and Taiwan [11,29]. To complete the life history of this echinostome in Korea, studies on the first intermediate hosts should be accomplished in near future.

Adults of *E. macrorchis* have been collected naturally in the rodent definitive hosts (*Apodemus* spp., *Microtus montebelli*, *Mogera* spp., and *Rattus* spp.), avian host (*Capella gallinago gallinago*), and even in humans [3-10]. They were also recovered experimentally in rats, mice, and cats infected with the metacercariae [12,26,30-32]. In the present study, we used albino rats of Sprague-Dawley strain as the experimental definitive host. The recovered worms were well developed in the small intestines of these rats. Therefore, albino rats are considered a

suitable experimental animal model for *E. macrorchis* infection. In addition, it is seriously needed to trace the presence of human infections and natural definitive hosts through further studies in Korea.

The metacercariae of *E. macrorchis* were 105-118 (110) × 105-118 (108) in size in the present study. They were smaller than those from other countries, i.e., Taiwan (122 × 118), Lao PDR (121 × 120), and Japan (139-159 × 99-120). The metacercariae from Taiwan were almost the same in size as those from Lao PDR. Then, the metacercariae from 3 countries were nearly round shape, whereas those from Japan were elliptical in shape [11,12,33]. Whether these differences were originated from the geographical variation and whether they are of taxonomical significance should be analyzed through further studies, including comparative morphological and molecular genetic ones with each isolate from 4 countries.

Total 40 adult worms recovered from the small intestines of rats infected with the metacercariae from 4 surveyed areas were more or less elongated body, and 3.95-6.0 (5.17) × 0.70-1.18 (0.94) mm in size. They had a well-developed head collar with 45 collar spines, including 5 end groups on each side, and their uterine tubules are long with numerous eggs. The ratio of BL/BW was about 5.50. The morphological characteristics of our specimens were almost similar with those of Sohn et al. [12]: 3,900-6,300 (5,100) × 730-1,050 (900) in size, the ratio of BL/BW about 5.67, and the number of collar spines. However, the size of eggs was more or less larger in our specimens (93-105 × 53-64) than in Sohn et al. [12] (88-98 × 55-61). However, we were able to assign our specimens to *E. macrorchis* among the members of *Echinostoma* with 43-45 collar spines, i.e., *E. academica*, *E. aegyptiaca*, *E. attenuatum*, *E. australasianum*, *E. azerbaijanicum*, *E. coromandum*, *E. coronale*, *E. dietzi*, *E. gotoi*, *E. macrorchis*, and *E. phasianina* [34-40].

On the basis of data from 40 worms, which were recovered from experimental rats at 15, 20, 25, and 30 days after infection in the present study, the following diagnostic features are considered as the differential indices for *E. macrorchis*. The worm body is long and slender (the ratio of BL/BW: 5.30-5.76); the ventral sucker is larger about 3 times than the oral sucker (the ratio of VS/OS: 3.03-3.18); the ovary is transversely elliptical (the ratio of L/W in the ovary: 0.93-0.97); the anterior testis has a long vertical axis (the ratio of L/W in the anterior testis: 1.57-1.89); the posterior testis has a more longer vertical axis than anterior one (the ratio of L/W in the posterior testis: 1.88-2.11); short forebody (% of FBL/BL: 11.3-13.4); short

hindbody (% of HBL/BL: 18.9-21.9); long uterine field (% of UL/BL: 25.4-31.5); the head collar with 45 collar spines, including 5 end groups on each side.

Conclusively, through the present study, the presence of *E. macrorchis* has been confirmed for the first time in Korea, and it has also been confirmed that *C. chinensis malleata* snails are popularly infected with the metacercariae of this echinostome as a suitable second intermediate host. Additionally, the morphological characteristics with differential indices derived from numerous age-controlled worm samples were described to support the taxonomic validity of *E. macrorchis*.

ACKNOWLEDGMENTS

We thank Jung-A Kim and Hee-Joo Kim, Department of Parasitology, Gyeongsang National University College of Medicine, Jinju, Korea, for their help in collection and examination of the snails, and recovery of adult worms from rats experimentally infected with the metacercariae.

CONFLICT OF INTEREST

The authors have no conflicts of interest concerning the work reported in this paper.

REFERENCES

1. Chai JY. Echinostomes in Humans. In Fried B, Toledo R, eds, *The Biology of Echinostomes: from the Molecule to the Community*. New York, USA. Springer. 2009, pp 147-183.
2. Huffman JE, Fried B. *Echinostoma* and echinostomiasis. *Adv Parasitol* 1990; 29: 215-269.
3. Ando R, Ozaki Y. On four new species of trematodes of the family Echinostomatidae. *Dobutsugaku Zasshi* 1923; 35: 108-119 (in Japanese).
4. Majima M. *Echinostoma macrorchis* found in a man. *Tokyo Iji Shinshi* 1927; 2552: 2260-2263 (in Japanese).
5. Shibue H. Studies on the trematodes of birds in Kyushu. *Kurume Igakkai Zasshi* 1954; 17: 178-183 (in Japanese).
6. Okabe N, Okabe K. On a human case infected with three species of trematodes. *Nippon Iji Shimpo* 1972; 2531: 46-48 (in Japanese).
7. Yokohata Y, Abe H, Jiang YP, Kamiya M. Gastrointestinal helminth fauna of Japanese moles, *Mogera* spp. *Jpn J Vet Res* 1989; 37: 1-13.
8. Ito M, Itagaki T. Survey on wild rodents for endoparasites in Iwate Prefecture, Japan. *J Vet Med Sci* 2003; 65: 1151-1153.
9. Fischthal JH, Kuntz RE. Some digenetic trematodes of mammals

- from Taiwan. *Proceed Helminthol Soc Washington* 1975; 42: 149-157.
10. Fischthal JH, Kuntz RE. Additional records of digenetic trematodes of mammals from Taiwan. *Proceed Helminthol Soc Washington* 1981; 48: 71-79.
 11. Lo CT. *Echinostoma macrorchis*: life history, population dynamics of intramuscular stages, and the first and second intermediate hosts. *J Parasitol* 1995; 81: 569-576.
 12. Sohn WM, Chai JY, Na BK, Yong TS, Eom KS, Park H, Min DY, Rim HJ. *Echinostoma macrorchis* in Lao PDR: Metacercariae in *Cipangopaludina* snails and adults from experimentally infected animals. *Korean J Parasitol* 2013; 51: 191-196.
 13. Choe S, Lee D, Park H, Oh M, Jeon HK, Lee Y, Na KJ, Kim Y, Lee H, Eom KS. Three echinostome species from wild birds in the Republic of Korea. *Korean J Parasitol* 2014; 52: 513-520.
 14. Choe S, Lee D, Park H, Jeon HK, Lee Y, Kim E, Na KJ, Eom KS. Two echinostome species, *Pegosomum bubulcum* and *Nephrostomum ramosum* (Digenea: Echinostomatidae), from an Eastern cattle egret, *Bubulcus ibis coromandus*, in Republic of Korea. *Korean J Parasitol* 2016; 54: 485-496.
 15. Choe S, Lee D, Park H, Jeon HK, Lee Y, Na KJ, Park SR, Eom KS. A case of chaunocephalosis by *Chaunocephalus ferox* (Digenea: Echinostomatidae) in an oriental white stork, *Ciconia boyciana*, in Korea. *Korean J Parasitol* 2016; 54: 659-665.
 16. Lee YI, Chung OS, Seo M. Recovery of *Oswaldotrema nacinovici* from whimbrels (*Aves*) in Korea. *Korean J Parasitol* 2016; 54: 809-812.
 17. Ryang YS. Studies on *Echinostoma* spp. in the Chungju Reservoir and upper stream of the Namhan River. *Korean J Parasitol* 1990; 28: 221-233 (in Korean).
 18. Son WY, Huh S, Lee SU, Woo HC, Hong SJ. Intestinal trematode infections in the villagers in Koje-myon, Kochang-gun, Kyongsangnam-do, Korea. *Korean J Parasitol* 1994; 32: 149-155.
 19. Ahn YK, Ryang YS. Experimental and epidemiological studies on the life cycle of *Echinostoma hortense* Asada, 1926 (Trematoda: Echinostomatidae). *Korean J Parasitol* 1986; 24: 121-136 (in Korean).
 20. Lee SK, Chung NS, Ko IH, Sohn WM, Hong ST, Chai JY, Lee SH. An epidemiological survey of *Echinostoma hortense* infection in Chongsong-gun, Kyongbuk province. *Korean J Parasitol* 1988; 26: 199-206 (in Korean).
 21. Chai JY, Hong ST, Lee SH, Lee GC, Min YI. A case of echinostomiasis with ulcerative lesions in the duodenum. *Korean J Parasitol* 1994; 32: 201-204.
 22. Lee OJ, Hong SJ. Gastric echinostomiasis diagnosed by endoscopy. *Gastrointest Endosc* 2002; 55: 440-442.
 23. Cho CM, Tak WY, Kweon YO, Kim SK, Choi YH, Kong HH, Chung DI. A human case of *Echinostoma hortense* (Trematoda: Echinostomatidae) infection diagnosed by gastroduodenal endoscopy in Korea. *Korean J Parasitol* 2003; 41: 117-120.
 24. Chang YD, Sohn WM, Ryu JH, Kang SY, Hong SJ. A human infection of *Echinostoma hortense* in duodenal bulb diagnosed by endoscopy. *Korean J Parasitol* 2005; 43: 57-60.
 25. Park CJ, Kim J. A human case of *Echinostoma hortense* infection diagnosed by endoscopy in area of southwestern Korea. *Korean J Med* 2006; 71: 229-234.
 26. Takahashi S. The life cycles of *Echinostoma cinetorchis* and *E. macrorchis*, particularly on their first and second intermediate hosts. *Fukuoka Ika Daigaku Zasshi* 1927; 20: 712-723 (in Japanese).
 27. Kurisu S. Study on trematodes who take *Viviparus* as their intermediate host. *Seikai Zasshi* 1930; 49: 65-73 (in Japanese).
 28. Kurokawa T. Studies on trematodes taking *Bulinus (Parafossarulus) striatus* (Pilsbry) as their intermediate host and on their metacercariae. *Tokyo Iji Shinshi* 1935; 2937: 1795-1800 (in Japanese).
 29. Yamashita J. Echinostome. *Progr Med Parasitol Japan* 1964; 1: 289-313.
 30. Ochi S. Studies on the life cycle of *Echinostoma macrorchis*. *Tokyo Joigaku Zasshi* 1931; 1: 12-32 (in Japanese).
 31. Ando R, Tsuyuki H. Studies on intestinal parasites taking rats as their final host (II) On *Echinostoma* in Nagoya city and its second intermediate host. *Tokyo Iji Shinshi* 1923; 2340: 1487-1499 (in Japanese).
 32. Ishii N. Studies on rat trematodes. *Jikken Igaku Zasshi* 1935; 19: 1122-1128 (in Japanese).
 33. Komiya Y. Metacercariae in Japan and adjacent territories. *Progr Med Parasitol Japan* 1965; 2: 1-328.
 34. Yamaguti S. Studies on the helminth fauna of Japan. Part. 27. Trematodes of mammals, II. *Jpn J Med Sci* 1939; 1: 131-151.
 35. Yamaguti S. Genus *Echinostoma* Rud., 1809. In *Synopsis of Digenetic Trematodes of Vertebrates (Vol. I & II)*. Tokyo, Japan. Keigaku Publishing Co. 1971, pp 529-533.
 36. Bashikirova E. Family Echinostomatidae Dietz, 1909. In *Skrjabin KI ed, Trematodes of Animals and Man. Vol. I. Moscow-Leningrad, Russia. Academy of Sciences of the USSR. 1947, pp 246-305 (English translated version)*.
 37. Skrjabin KI, Petrov AM, Bashikirova E. Echinostomes of domestic and wild birds in USSR. In *Skrjabin KI ed, Trematodes of Animals and Man, Vol. I. Moscow-Leningrad, Russia. Academy of Sciences of the USSR. 1947, pp 306-407 (English translated version)*.
 38. Skrjabin KI, Bashikirova E. Family Echinostomatidae Dietz, 1909. In *Skrjabin KI ed, Trematodes of Animals and Man. Vol. XII. Moscow, Russia. Academy of Sciences of the USSR. 1956, pp 53-930*.
 39. Odening K. Trematoda from Indian birds in the Berlin zoological gardens. *Z Parasitenkd* 1962; 21: 381-425.
 40. Kanev I, Fried B, Radev V. Collar spine models in the genus *Echinostoma* (Trematoda: Echinostomatidae). *Parasitol Res* 2009; 105: 921-927.