

Safety and efficacy of the oblique-axis plane in ultrasound-guided internal jugular vein puncture: A meta-analysis

Journal of International Medical Research

2018, Vol. 46(7) 2587–2594

© The Author(s) 2018

Reprints and permissions:

sagepub.co.uk/journalsPermissions.nav

DOI: 10.1177/0300060518765344

journals.sagepub.com/home/imr



Shuai Miao^{1,*} , Xiuli Wang^{1,*}, Lan Zou¹,
Ye Zhao¹, Guanglei Wang¹, Yuepeng Liu²
and Su Liu¹

Abstract

Objective: This meta-analysis was performed to evaluate the safety and efficacy of the oblique-axis plane in ultrasound-guided internal jugular vein puncture.

Methods: We searched Embase, PubMed, the Cochrane Library, Web of Science, and China National Knowledge Infrastructure for relevant randomized clinical trials comparing the oblique axis with the short axis in ultrasound-guided internal jugular vein puncture.

Results: Five randomized clinical trials were included in this meta-analysis. The pooled meta-analysis showed that the incidence of arterial puncture in the oblique-axis group was significantly lower than that in the short-axis group. No significant difference was found in the first-pass success rate between the oblique-axis group and short-axis group. Additionally, there were no significant differences in the puncture success rate or number of attempts required between the two groups.

Conclusion: Ultrasound-guided internal jugular vein puncture using the oblique-axis plane reduced the risk of arterial puncture, but no difference was found in the first-pass success rate, puncture success rate, or number of attempts required.

*These authors contributed equally to this work.

Corresponding author:

Su Liu, Department of Anesthesiology, The Affiliated Hospital of XuZhou Medical University, 99 Huaihai West Road, XuZhou, Jiangsu 221002, China.
Email: 150040009@qq.com

¹Department of Anesthesiology, The Affiliated Hospital of XuZhou Medical University, XuZhou, Jiangsu, China

²Center Of Clinical Research and Translational Medicine, Lianyungang Oriental Hospital, Lianyungang, Jiangsu, China



Keywords

Oblique axis, short axis, ultrasound-guided internal jugular vein puncture, meta-analysis, arterial puncture, randomized controlled trial

Date received: 18 January 2018; accepted: 23 February 2018

Introduction

Internal jugular vein puncture is widely used in the operating room and intensive care unit. The traditional puncture method is based on anatomical landmarks and may therefore lead to several complications such as arterial puncture, hematoma formation, and others.^{1–3} Ultrasound is used to display the blood vessels and surrounding tissues of the neck and accurately locate the internal jugular vein.⁴ Several randomized clinical trials and meta-analyses have shown that ultrasound-guided internal jugular vein puncture not only increases the first-pass success rate but also reduces the risk of complications.^{5–8}

The ultrasonic positioning method commonly involves use of the short- and long-axis planes. The former can only show the cross section of the puncture needle,⁹ while the latter can only display the internal jugular vein. The oblique-axis plane, a new method of localization that combines the advantages of the short- and long-axis planes, can show both the internal jugular vein and internal carotid artery.^{10,11} However, the safety and efficacy of the oblique-axis plane are still controversial. This meta-analysis was performed to determine the safety and efficacy of the oblique-axis plane in ultrasound-guided internal jugular vein puncture.

Materials and methods

This meta-analysis was conducted according to the recommendations of the

Cochrane Handbook for Systematic Reviews of Interventions and the recommendations of PRISMA.^{12,13} All analyses were based on previously published studies; thus, no ethical approval was required.

Inclusion criteria

Studies were included if they met the following criteria: the study was a randomized controlled trial (RCT), the study involved adult participants, and ultrasound-guided internal jugular vein puncture was evaluated. For interventions, the experimental group involved ultrasound examination with the oblique-axis plane, while the control group involved ultrasound examination with the short-axis plane. The following outcomes were included in this meta-analysis: the incidence of arterial puncture, the first-pass success rate, the puncture success rate, and the number of attempts required.

Exclusion criteria

Studies were excluded for the following reasons: the study design was a non-RCT, retrospective study, review, or case report or the study had no target outcomes.

Search strategy

We searched Embase, PubMed, the Cochrane Library, Web of Science, China National Knowledge Infrastructure, and other Chinese databases for relevant randomized clinical trials that compared the oblique axis with the short axis in

ultrasound-guided internal jugular vein puncture up to 31 October 2017 without language restriction. The references of the identified studies were also searched to identify any additional relevant studies. The English search terms were “ultrasound,” “internal jugular vein,” and “oblique axis.”

Assessment of study quality

The quality of the included studies was independently assessed by two investigators according to the Jadad scale.¹⁴ The following items were evaluated: whether randomization was performed and whether the method was correct, whether allocation concealment was used and whether the method was correct, whether blinding was performed and in whom the method was used, and whether there were withdrawals or dropouts.

Data extraction

The following data were extracted by two authors using standard data tables: first author, year of publication, country, number of participants, target outcomes, intervention details, and study characteristics. The primary end point of this meta-analysis was the incidence of arterial puncture, and the secondary end points were the first-pass success rate, the puncture success rate, and the number of attempts required.

Statistical analysis

We used Review Manager version 5.3 (The Cochrane Collaboration, The Nordic Cochrane Centre, Copenhagen, Denmark) to conduct all statistical analyses. Heterogeneity¹⁵ was assessed with the I^2 statistic, and $I^2 > 50\%$ was regarded as significant. The following analytical methods were used: an *a priori* fixed-effects model was used, and we selected a random-effects model to perform the meta-analysis when I^2 was $\geq 50\%$.

Subgroup and sensitivity analyses were performed on factors that may contribute to the heterogeneity of the primary outcome.

Dichotomous outcomes are reported using the Mantel–Haenszel risk ratio (RR) with 95% confidence interval (CI), and continuous outcomes are reported as the mean difference with 95% CI.

Results

Trial selection

Figure 1 shows the results of the search process. In total, 70 studies were included in the initial search in accordance with the search strategy. After excluding non-relevant literature and non-original studies by reading titles and abstracts, 14 articles were selected. Finally, only five studies^{16–20} were included.

Characteristics and quality of included studies

The details of the studies included in the meta-analysis are shown in Table 1. Two authors independently evaluated the quality of the RCTs reported in these studies using the Jadad scale for randomization, allocation concealment, blinding, and withdrawals or dropouts of all enrolled studies. Only one of the studies¹⁶ was classified as low-quality (Jadad score of ≤ 2); all other studies^{17–20} were all classified as high-quality studies (Jadad score of ≥ 3).

Outcomes of pooled studies

Four studies reported the incidence of arterial puncture.^{16–18,20} No arterial puncture was reported in the study by Wang.¹⁷ No significant heterogeneity was found between studies ($I^2 = 0$), and a fixed-effects model was used to analyze the outcome. The data extracted from relevant studies

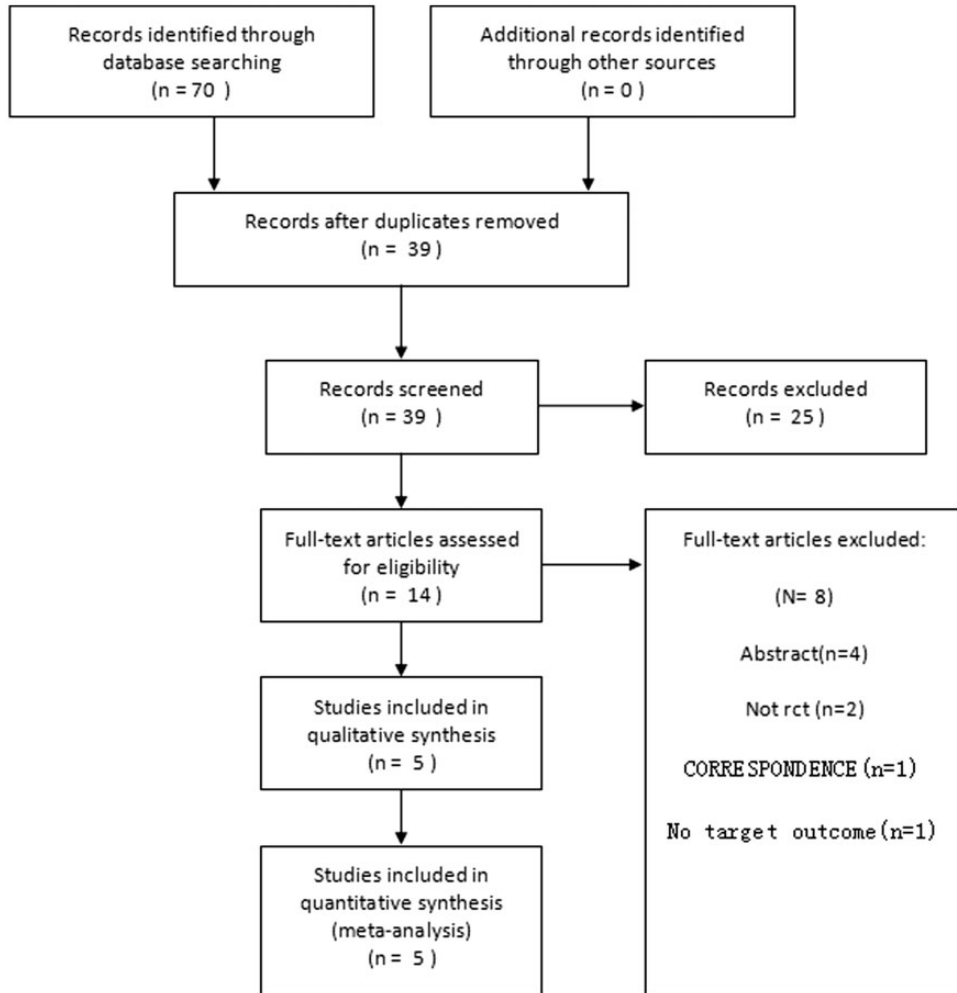


Figure 1. PRISMA flowchart of the included studies. RCT, randomized controlled trial.

indicated that the oblique-axis plane in ultrasound-guided internal jugular vein puncture leads to a significantly lower incidence of arterial puncture than the short-axis plane (RR, 0.13; 95% CI, 0.02–0.70; $P = 0.02$) (Figure 2).

Four studies involving 391 participants reported the first-pass success rate.^{16,17,19,20} Significant heterogeneity was found between studies ($I^2 = 56\%$), and a random-effects model was used to analyze the outcome. The pooled meta-analysis

showed no difference in the first-pass success rate between the two groups (RR, 1.11; 95% CI, 0.97–1.28) (Figure 3).

Four studies involving 391 participants reported the puncture success rate.^{16,17,19,20} There was significant heterogeneity between studies ($I^2 = 59\%$), and a random-effects model was used to analyze the outcome. No significant difference was found in the success rate of puncture between the two groups (RR, 1.03; 95% CI, 0.96–1.11) (Figure 4).

Table 1. Study characteristics of all randomized trials included in the meta-analysis

Study	Country	Patients (n)	Groups (planes)	Target outcomes*	Jadad score	Blinding	Concealment allocation	Randomized	Follow-up
Kang and Wang, 2017	China	159	oblique-axis, short-axis	1, 2, 3, 4	2	I	0	0	I
Wang and Wen, 2016	China	120	oblique-axis, short-axis	1, 2, 3, 4	5	I	I	2	I
Wu et al., 2016	China	180	oblique-axis, short-axis	4	5	I	I	2	I
Batllore et al., 2016	Spain	220	oblique-axis, short-axis	1, 2, 3	6	I	2	2	I
Ma et al., 2016	China	60	oblique-axis, short-axis	1, 3, 4	4	I	I	I	I

*1: first-pass success rate, 2: number of attempts required, 3: puncture success rate, 4: arterial puncture.

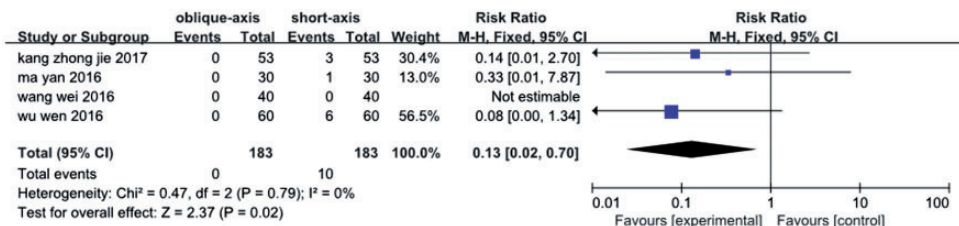


Figure 2. Forest plot for incidence of arterial puncture in oblique versus short axis. M-H, Mantel–Haenszel; CI, confidence interval.

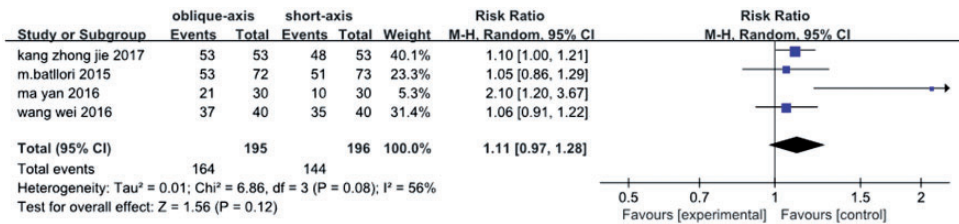


Figure 3. Forest plot for first-pass success rate in oblique versus short axis. M-H, Mantel–Haenszel; CI, confidence interval.

Data on the number of attempts required were reported in three studies.^{16,17,19} The heterogeneity test showed that $I^2 = 91\%$, and a random-effects model was used to analyze the outcome. The oblique-axis plane did not reduce the number of attempts required (mean difference, -0.28 ; 95% CI, $-0.06-0.11$) (Figure 5).

Sensitivity and subgroup analyses

Only five studies were identified for inclusion in the present review, and no heterogeneity was found in the primary outcome; therefore, we did not perform subgroup or sensitivity analyses in the present review.

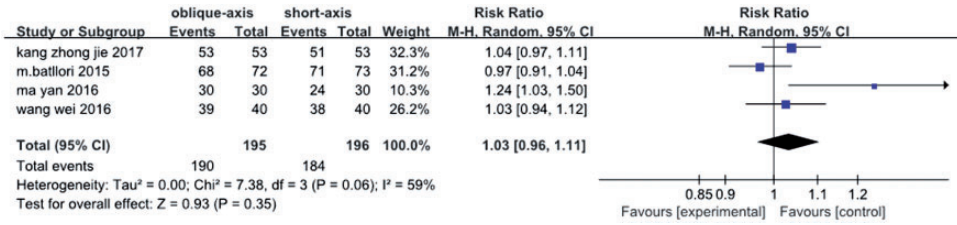


Figure 4. Forest plot for puncture success rate in oblique versus short axis. M-H, Mantel–Haenszel; CI, confidence interval.

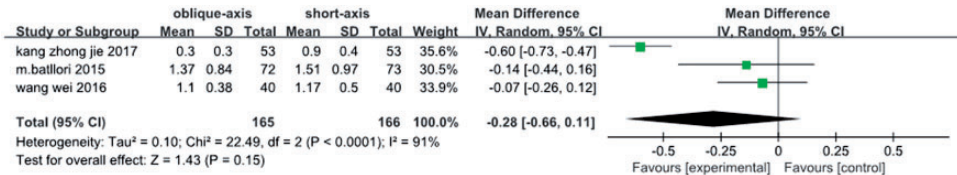


Figure 5. Forest plot for number of attempts required in oblique versus short axis. SD, standard deviation; CI, confidence interval; IV, inverse variance.

Discussion

In the present study, we retrieved five RCTs to demonstrate the safety and efficacy of the oblique-axis plane in ultrasound-guided internal jugular vein puncture. The results showed that the oblique-axis plane may reduce the incidence of arterial puncture in ultrasound-guided internal jugular vein puncture. However, no significant difference was found in the first-pass success rate, the puncture success rate, or the number of attempts required between the two groups.

Several clinical trials^{18–23} have indicated that compared with the anatomical landmarks technique, ultrasound-guided internal jugular vein puncture could lead to a higher first-pass success rate and puncture success rate with fewer attempts required and a lower incidence of arterial puncture. However, the present meta-analysis showed no significant difference in the first-pass success rate, the puncture success rate, or the number of attempts required between the oblique-axis plane and short-axis

plane. Indeed, ultrasound can display the blood vessels and surrounding tissues of the neck with both the oblique- and short-axis approaches, and the number of studies and samples are too small to show a significant difference. We also found that between different studies, the first-pass success rate and the puncture success rate were different between the two groups. Different ultrasound machines (SonoSite, Bothell, WA, USA and GE Healthcare, Chicago, IL, USA) and ultrasonic frequencies ranging from 4 to 13 MHz may be two of the factors resulting in these differences.

The common carotid artery is located below or inside the internal jugular vein, and these two vessels are partially or completely overlapped in the short-axis plane;²⁴ thus, needle tip visualization may be more difficult.²⁵ Arterial injury may occur when the line intensity is too large. The oblique-axis plane not only shows the anatomical position of the internal carotid artery and vein but also the anatomical position of the internal carotid artery and vein; therefore, the puncture process can be better

observed. The present meta-analysis showed the same result as reported in previous clinical trials;^{16–20} namely, that the oblique axis plane leads to a low risk of arterial puncture. Like the first-pass success rate in ultrasound-guided internal jugular vein puncture, the risk of arterial puncture was also based on the operator's experience. We found that skillful operators were involved in the study by Wang,¹⁷ which may explain why no arterial puncture was observed.

In all RCTs of the present meta-analysis,^{16–20} ultrasound-guided internal jugular vein puncture was performed by experienced experts; however, the most useful method for less-experienced operators remains unclear. Additionally, no study has been conducted to determine which method is best in patients for whom internal jugular vein puncture is expected to be difficult. Future studies should focus on less-experienced operators and patients with presumed difficult puncture to confirm the present findings.

Several limitations of this meta-analysis should be considered. First, the quality of the included trials was uneven. Second, the number of included RCTs was small. Third, four of the studies included in the present meta-analysis were conducted in China; more studies involving different races and countries are still needed to estimate whether the present findings represent the global practice of internal jugular vein puncture. Because we only included published literature, the search strategy could have affected the meta-analysis results.

Conclusion

The results of the present study show that ultrasound-guided internal jugular vein puncture using the oblique-axis plane may reduce the risk of arterial puncture, but there was no difference in the first-pass success rate, puncture success rate, or number of attempts required. Thus, large-sample, multicenter randomized clinical trials are

still needed to confirm the present conclusions.

Declaration of conflicting interest

The authors declare that there is no conflict of interest.

Funding

The author(s) disclosed receipt of the following financial support for the research, authorship, and/or publication of this article: This work was financially supported by grants from the National Natural Science Foundation of China (NSFC-81371242, 81671084), the Qing Lan Project of Jiangsu Province, the Nature Science Foundation of Jiangsu Province (BK20161175), the “Six One” Project of Jiangsu Province (LGY2016039), and the Social Development Project from Lianyungang Science and Technology Bureau (SH1544).

ORCID iD

Shuai Miao  <http://orcid.org/0000-0002-8327-4351>

References

1. Schummer W, Schummer C, Rose N, et al. Mechanical complications and malpositions of central venous cannulations by experienced operators. A prospective study of 1794 catheterizations in critically ill patients. *Intensive Care Med* 2007; 33: 1055–1059.
2. Augoustides JG, Horak J, Ochroch AE, et al. A randomized controlled clinical trial of real-time needle-guided ultrasound for internal jugular venous cannulation in a large university anesthesia department. *J Cardiothorac Vasc Anesth* 2005; 19: 310–315.
3. Eisen LA, Narasimhan M, Berger JS, et al. Mechanical complications of central venous catheters. *J Intensive Care Med* 2006; 21: 40–46.
4. Ortega R, Song M, Hansen CJ, et al. Videos in clinical medicine. Ultrasound-guided internal jugular vein cannulation. *N Engl J Med* 2010; 362: e57.

5. Lau CS. Ultrasound-guided central venous catheter placement increases success rates in pediatric patients: a meta-analysis. *Pediatr Res* 2016; 80: 178–184.
6. Shime N and Hosokawa K. Ultrasound imaging reduces failure rates of percutaneous central venous catheterization in children. *Pediatr Crit Care Med* 2015; 16: 718–725.
7. Brass P, Hellmich M, Kolodziej L, et al. Ultrasound guidance versus anatomical landmarks for subclavian or femoral vein catheterization. *Cochrane Database Syst Rev* 2015; 1: CD011447.
8. Randolph AG, Cook DJ and Gonzales CA. Ultrasound guidance for placement of central venous catheters: a meta-analysis of the literature. *Crit Care Med* 1996; 24: 2053–2058.
9. Gray AT. Ultrasound-guided regional anaesthesia: current state of the art. *Anesthesiology* 2006; 104: 368–373.
10. Phelan M and Hagerty D. The oblique view: an alternative approach for ultrasound-guided central line placement. *J Emerg Med* 2009; 37: 403–408.
11. Baidya DK, Chandralekha, Darlong V, et al. Comparative sonoanatomy of classic “short axis” probe position with a novel “medial-oblique” probe position for ultrasound-guided internal jugular vein cannulation: a crossover study. *J Emerg Med* 2015; 48: 590–596.
12. Higgins JPT and Green S. *Cochrane handbook for systematic reviews of interventions* version 5.1.0 [updated March 2011]. The Cochrane Collaboration 2011.
13. Moher D, Liberati A, Tetzlaff J, et al. Preferred reporting items for systematic reviews and meta-analysis: the PRISMA statement. *Int J Surg* 2010; 8: 336–341.
14. Clark HD, Wells GA, Hut C, et al. Assessing the quality of randomized trials: reliability of the Jadad scale. *Control Clinical Trials* 1999; 20: 448–452.
15. Higgins JP, Thompson SG, Deeks JJ, et al. Measuring inconsistency in meta-analysis. *BMJ* 2003; 327: 557–560.
16. Kang ZJ and Wang XQ. Comparison of the effect of internal jugular vein puncture and catheterization under different ultrasonic image guidance axis plane. *Journal of Xinxiang Medical University* 2017; 34: 139–142.
17. Wang W and Wen XH. Ultrasound guided internal jugular vein catheterization on oblique axial plane. *Shanghai Med J* 2016; 39: 482–484+515.
18. Wu W, Nie W, Xia J, et al. Optimal axis plane for ultrasound-guided approach for internal jugular vein catheterization. *J Clin Anesthesiology* 2016; 32: 449–452.
19. Batllori M, Urria M, Uriarte E, et al. Randomized comparison of three transducer orientation approaches for ultrasound guided internal jugular venous cannulation. *Br J Anaesth* 2016; 116: 370–376.
20. Ma Y, Han F, Zhang Y, et al. Clinical study of oblique-axis view ultrasound-guided internal jugular vein puncture compared with short-axis view. *Chinese Journal of Medicine* 2016; 51: 57–59.
21. Karakitsos D, Labropoulos N, De Groot E, et al. Real-time ultrasound-guided catheterisation of the internal jugular vein: a prospective comparison with the landmark technique in critical care patients. *Crit Care* 2006; 10: R162.
22. Milling TJ Jr, Rose J, Briggs WM, et al. Randomized, controlled clinical trial of point-of-care limited ultrasonography assistance of central venous cannulation: the Third Sonography Outcomes Assessment Program (SOAP-3) Trial. *Crit Care Med* 2005; 33: 1764–1769.
23. Leung J, Duffy M and Finckh A. Real-time ultrasonographically guided internal jugular vein catheterization in the emergency department increases success rates and reduces complications: a randomized, prospective study. *Ann Emerg Med* 2006; 48: 540–547.
24. Theodoro D, Krauss M and Kollef M. Risk factors for acute adverse events during ultrasound-guided central venous cannulation in the emergency department. *Acad Emerg Med* 2010; 17: 1055–1061.
25. Ball R, Scouras N, Orebaugh S, et al. Randomized, prospective, observational simulation study comparing residents’ needle-guided vs free-hand ultrasound techniques for central venous catheter access. *Br J Anaesth* 2012; 108: 72–79.