

# Intramural hematoma of the esophagus mimicking hemorrhaging esophageal cancer

Yeng Kwang Tay<sup>a</sup>, Jia Yin Tay<sup>b</sup>, Lachlan Dandie<sup>a</sup>, John Gribbin<sup>a</sup>

Monash Medical Centre, Southern Health; University of Melbourne, Victoria, Australia

## Abstract

Intramural hematoma of the esophagus (IHE) is an uncommon esophageal injury. Diagnosis requires high index of suspicion as it can mimic various other cardiovascular, pulmonary, mediastinal or esophageal diseases. Although multiple imaging modalities have been reported to be useful, CT with intravenous contrast should be the imaging modality of choice if not contraindicated. Treatment of IHE is mainly supportive; complete resolution in several weeks is the expected outcome. It is crucial that this condition is recognized and considered in the differential diagnosis of any patients who present with chest pain or dysphagia.

**Keywords** Intramural hematoma of esophagus, esophageal apoplexy, esophageal dissection

*Ann Gastroenterol* 2013; 26 (1): 74-76

## Introduction

Intramural hematoma of the esophagus (IHE) is an uncommon esophageal injury most frequently occurring in anticoagulated elderly patients. Although it has a clinically benign course with no long-term complications, iatrogenic complications from misdiagnosis or over-aggressive treatment can impact on patients with significant morbidity and mortality. It is crucial for physicians to recognize this condition and be able to differentiate it among various other benign or malignant cardiac, pulmonary, aortic and esophageal diseases. We present a case of IHE and discuss presentation, investigations and treatment of this uncommon disease.

epigastric pain, there was no recent history of dysphagia, weight loss or anorexia. His past history includes a previous stroke, for which he took clopidogrel regularly. He was intubated for ventilatory support immediately. Blood products were also administered. Physical examination was unremarkable except for bibasal crackles. Gastroscopy was performed to achieve hemostasis. It revealed marked luminal occlusion by diffuse mucosal ulceration with active ooze, suspected to be malignancy (Fig. 1). A biopsy was taken for histological examination. After stabilization, a computed tomography (CT) scan with intravenous contrast revealed a thickened esophagus extending from T1 down to the stomach near to

## Case report

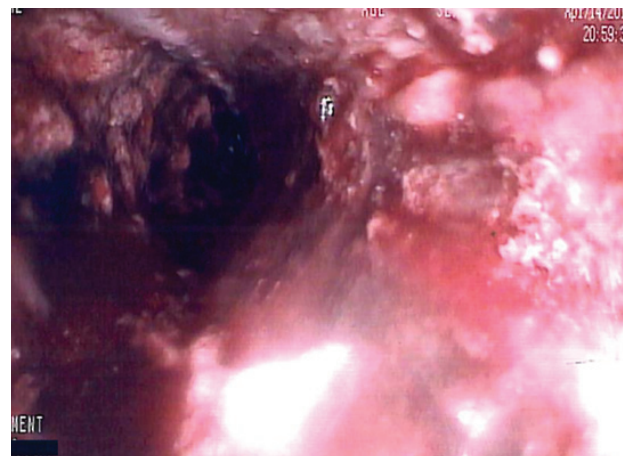A 77-year-old male presented with severe epigastric pain, hematemesis, hemorrhagic shock and respiratory failure due to aspiration. Apart from a two-week history of intermittent

<sup>a</sup>Department of Upper Gastrointestinal Surgery, Southern Health (Yeng Kwang Tay, Lachlan Dandie, John Gribbin); <sup>b</sup>Faculty of Medicine, Dentistry and Health Sciences, University of Melbourne (Jia Yin Tay), Victoria, Australia

Conflict of Interest: None

Correspondence to: Mr. John Gribbin, Upper Gastrointestinal Surgery Unit, Monash Medical Centre, 246 Clayton Road, Clayton, 3168 Victoria, Australia, Tel.: +61 3 9594 6666, Fax: +61 3 9594 6053, e-mail: john.gribbin@med.monash.edu.au

Received 5 June 2012; accepted 8 July 2012



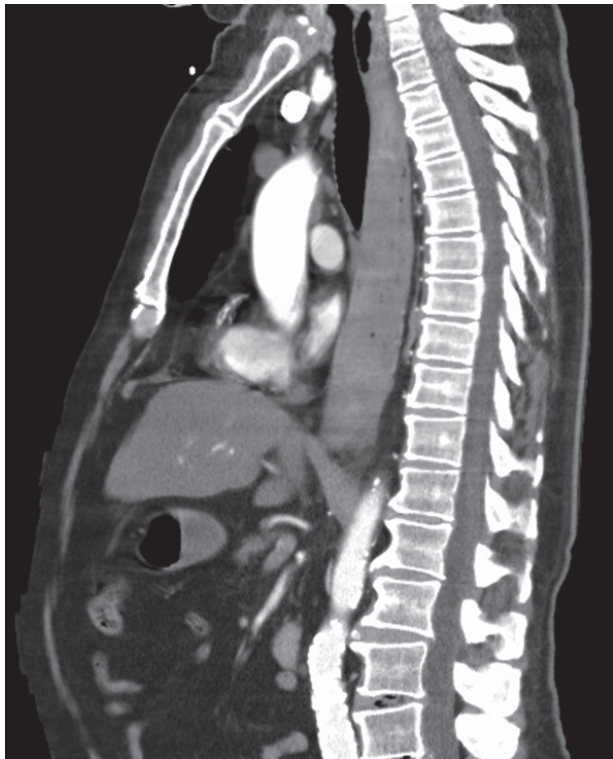
**Figure 1** Initial gastroscopy showing diffuse abnormality with areas of active bleeding

the gastro-esophageal junction (Fig. 2). The esophageal lumen was almost completely obliterated.

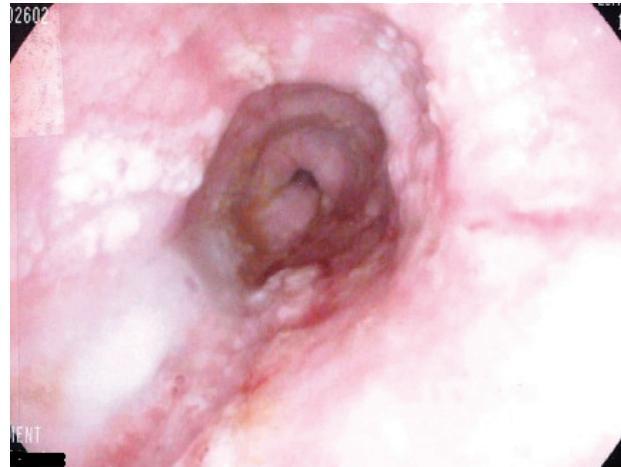
The diagnosis of intramural hematoma of esophagus (IHE) was made based on the history of anti-coagulant use and CT finding of esophageal wall thickening without any evidence of perforation. This was further supported by histological confirmation of esophagitis. He was conservatively managed; nutrition was provided parenterally, and continued to remain stable. He recovered from aspiration pneumonia over the next few days and was extubated. Repeat gastroscopy demonstrated an intact esophagus with small areas of linear superficial ulceration and scarring consistent with healing tear (Fig. 3). He was discharged on soft pureed diet for two weeks and remained asymptomatic at twelve-week follow up.

## Discussion

Rather confusingly, this well-described condition is also known as “intramural rupture of the esophagus”, “esophageal apoplexy” and “esophageal dissection”, in the literature [1]. Among different types of esophageal injuries, IHE is regarded as an intermediate stage between Mallory-Weiss and Berhaave’s syndrome [2,3]. Mallory-Weiss syndrome classically presents with hematemesis due to a mucosal



**Figure 2** Sagittal view of CT thorax showing long segment of heterogeneous esophageal wall thickening with almost complete luminal occlusion



**Figure 3** Repeat gastroscopy showing almost complete resolution of intramural hematoma of the esophagus

tear at the gastro-esophageal junction [3]. It is commonly preceded by severe retching, coughing or vigorous vomiting [4]. Conservative treatment is usually effective, but endoscopic management is occasionally required to achieve hemostasis [4]. Boerhaave’s syndrome, classically presents with vomiting, severe retrosternal pain and subcutaneous emphysema followed rapidly by sepsis and shock [4]. It is defined as transmural rupture of the esophagus usually secondary to acute increase in intra-esophageal pressure [3,4]. The only mainstay of treatment is surgical repair and drainage.

IHE is defined as hemorrhage between the esophageal layers of mucosa and muscularis propria, often involving a long segment of the esophagus [4]. Breach of the mucosa confining the hematoma occurs later, presenting as hematemesis [5]. IHE has been etiopathologically categorized into five groups: 1) suboptimal hemostasis, 2) emetogenic, 3) traumatic, 4) aortic disease-related, and 5) idiopathic [3]. IHE more commonly occurs in elderly females, with females twice as likely to be diagnosed [5,6]. At least 50% of IHE has two of the triad of retrosternal chest pain, hematemesis and dysphagia or odynophagia [5]. The initial presenting symptom of retrosternal chest pain is produced by an expanding hematoma distending the esophagus and is followed by hematemesis when the hematoma ruptured intraluminally [5,6].

Multiple imaging modalities have been reported to diagnose IHE [1,5]. CT scan with intravenous contrast is the modality of choice as it is fast, readily accessible, non-invasive and able to investigate and delineate the relationship between the esophagus, aorta and other mediastinal structures [5]. Typical CT signs suggestive of IHE include thickened esophageal wall with luminal compression or complete obliteration [7]. Intramural hematoma could be of variable length, proximal or distal, single or multifocal [5]. It has been reported that multifocal or proximal involvement is more commonly seen in anticoagulation associated IHE [8]. Intramural hematoma has CT appearance of high attenuation, but does not enhance with intravenous contrast administration, apart from IHE due

to aorto-esophageal fistula [5]. In cases where transmural perforation is not confirmed but suspected, oral contrast can be administered with contrast extravasation extraluminally diagnostic and showing the location of the perforation [5].

Other investigative modalities are plain films, contrast esophagogram, gastroscopy, endoscopic ultrasound and magnetic resonance imaging (MRI). Plain films are usually non-revealing in IHE but the presence of pneumothorax, pneumomediastinum and pleural effusion is strongly suggestive of transmural perforation [4]. Water-soluble iodinated contrast medium, for example gastrograffin, should be used in contrast esophagogram [1]. The finding of “double barrel esophagus”, confirming the communication between esophageal lumen and hematoma cavity is diagnostic of IHE [1]. The use of gastroscopy should be limited for its invasive nature and it does not visualize the mucosal tear in 50% of IHE [5,7]. It may inadvertently worsen the situation by transforming IHE into transmucosal perforation mechanically or through gas insufflation [7]. Endoscopic ultrasound carries the same invasive risks as gastroscopy. Superior to gastroscopy, endoscopic ultrasound is able to demonstrate submucosal lesions and evaluate adjacent mediastinal structures and exclude any fistulous communication [5]. MRI could be of value to differentiate IHE from aortic dissection when CT is not conclusive or contraindicated. IHE can be confirmed on MRI with images showing clear soft tissue planes around the aorta and esophagus as well as intramural hematoma of intermediate signal intensity on T1 and T2 weighted images [9].

Once the diagnosis of IHE is confirmed, conservative management of the condition with reversal of anticoagulation, parenteral nutrition and analgesia should be undertaken [3-6,10]. Spontaneous complete recovery of the mucosal tear and absorption of hematoma usually takes 1-3 weeks [4,5]. Although IHE does not carry any long-term sequelae, repeat imaging should be considered to confirm resolution of IHE and exclude underlying malignant pathology [7].

The only type of IHE that cannot be conservatively managed is IHE secondary to aorto-esophageal fistula (AEF). AEF is generally caused by ruptured aneurysm of descending thoracic aorta, foreign body, advanced esophageal cancer or related to preceding aortic or esophageal surgeries [11]. AEF presenting with massive hematemesis requires urgent surgical intervention. However, in atypical circumstances, arterial phase CT demonstrating intramural hematoma of high attenuation or gastroscopy showing pulsatile lesion

support the diagnosis of AEF [11,12]. If not recognized and treated promptly, aorto-esophageal fistula almost always results in death. Treatment methods include endovascular aortic stent-graft with esophageal stent, to open operations such as midline sternotomy or left thoracotomy [11,12].

Although IHE is a well-documented condition in the literature, it is rare and therefore not widely recognized by physicians. IHE can mimic multiple other cardiac, pulmonary or esophageal diseases [3,5,7,8]. It is important for physicians to be aware of IHE as misdiagnosis could lead to mismanagement and avoidable complications in an otherwise benign disease.

## References

1. Clark W, Cook IJ. Spontaneous intramural haematoma of the oesophagus: radiologic recognition. *Australas Radiol* 1996;**40**:269-272.
2. Sen A, Lea RE. Spontaneous oesophageal haematoma: a review of the difficult diagnosis. *Ann R Coll Surg Engl* 1993;**75**:293-295.
3. Chiu YH, Chen JD, Hsu CY, How CK, Yen DH, Huang CI. Spontaneous esophageal injury: esophageal intramural hematoma. *J Chin Med Assoc* 2009;**72**:498-500.
4. Katzka DA. Chapter 45: Esophageal disorders caused by medications, trauma, and infection. In: Feldman M, Friedman LS, Brandt LJ (editors): *Sleisenger and Fordtran's Gastrointestinal and Liver Disease*. Saunders Elsevier: Philadelphia; 2010, pp 735-743.
5. Restrepo CS, Lemos DF, Ocazonez D, Moncada R, Gimenez CR. Intramural hematoma of the esophagus: a pictorial essay. *Emerg Radiol* 2008;**15**:13-22.
6. Meulman N, Evans J, Watson A. Spontaneous intramural haematoma of the oesophagus: a report of three cases and review of the literature. *Aust N Z J Surg* 1994;**64**:190-193.
7. Tong M, Hung WK, Law S, Wong KH, Kwok KF, Wong J. Esophageal hematoma. *Dis Esophagus* 2006;**19**:200-222.
8. Shay SS, Berendson RA, Johnson LF. Esophageal hematoma. Four new cases, a review and proposed etiology. *Dig Dis Sci* 1981;**26**:1019-1024.
9. Kamphuis AG, Baur CH, Freling NJ. Intramural hematoma of the esophagus: appearance on magnetic resonance imaging. *Magn Reson Imaging* 1995;**13**:1037-1042.
10. Ivekovic H, Ivekovic MP. Intramural esophageal hematoma: an unusual complication of endotracheal intubation. *J Emerg Med* 2012 (in press)
11. Kieffer E, Chiche L, Gomes D. Aortoesophageal fistula: value of in situ aortic allograft replacement. *Ann Surg* 2003;**238**:283-290.
12. Bakhshandeh AR, Salehi M, Radmehr H, Riahi GR. A case of aortoesophageal fistula. *Asian Cardiovasc Thorac Ann* 2011;**19**:419-421.