


## Biography of Camran Nezhat, MD, FACOG, FACS

James E. Carter, MD, PhD



Camran Nezhat, MD

Camran Nezhat has influenced almost every aspect of our laparoscopic lives. His vision, perseverance, and humanistic focus have propelled our field away from the established yet awkward “single eye” and mostly diagnostic laparoscopy to his method of operative laparoscopy, which has revolutionized modern

day surgery. Also, his prediction and claim that almost all open surgeries could be and should be avoided is increasingly becoming a reality.<sup>1–6</sup> Indeed, he has paved the way through the years by his pioneering work of successful management of many complex surgical pathologies laparoscopically for the first time and proving that it is possible and probably preferable.<sup>4–6</sup>

Of equal importance, Camran on a personal level has positively affected many of us as well. His sincerity, clarity of thought, and faith that the future can be made better than the present—if only we apply ourselves to the unsolved problems of medicine—remain a source of continual inspiration.

I recall vividly the experience of Camran inspiring me to strive for broader frontiers, when, at the 2nd European Congress in Gynecological Endoscopy in Heidelberg, Germany, a packed audience sat transfixed on uncomfortably hard folding chairs as he unveiled his uncannily prescient vision for the field of laparoscopy, foretelling of a time years into the future when large incisions would eventually become obsolete. This was in 1993, ten years ahead of the curve, when operative laparoscopy was still considered quite limited and dangerous, especially since the technology did not exist to match this futuristic view.

I would like to thank Farr and Ceana Nezhat for sharing family memories and especially to Camran Nezhat for opening his heart for this article.

Address reprint requests to: James E. Carter, MD, PhD, 26732 Crown Valley Parkway, Ste 541, Mission Viejo, CA 92691, USA. Telephone: 949 364 5802, Fax: 949 364 2871

© 2006 by JLS, *Journal of the Society of Laparoendoscopic Surgeons*. Published by the Society of Laparoendoscopic Surgeons, Inc.

Despite this technological lag, Camran demonstrated via video footage of his collaborative work with colleagues from other disciplines that laparoscopic techniques could be integrated into therapy for the abdominal and pelvic cavity, heart, brain, lungs, vessels, endocrine system, and to every aspect of surgery where a cavity existed or a cavity could be created. For, in these situations, he found that the anatomy could be magnified and therefore better visualized.<sup>4–5</sup>

As with so many pioneers in our profession, Camran indeed attracted numerous negative reviews, in the category of “medical heresy.”<sup>7</sup> Yet today, we see that his early commitment to advancing medicine has helped pave the way for laparoscopic specialists the world over to provide patients with the option of speedier recoveries and improved outcomes. That day in Heidelberg, I was enthralled and felt challenged by him to participate more fully in expanding the frontiers to help with his vision.

Camran introduced the technique of operating in an upright position off the television monitor and on the images rather than on the tissue! By doing so, he changed the “single eye” world of endoscopy forever.<sup>1,6</sup> Second, he is the forerunner of successful laparoscopic reparative management of many diseases of the pelvic and abdominal organs including laparoscopic bladder, ureter, bowel and diaphragm resection, laparoscopic paraaortic lymph node dissection, radical hysterectomy, vesicovaginal fistulas, rectovaginal fistulas; and laparoscopic treatment of ovarian remnant. Sacral colpopexy and laparoscopy during advanced pregnancy and repair of major vessels were also first reported by Camran and his team.<sup>1–6,8–34</sup> Thus, Camran opened the road for those in other surgical disciplines to approach almost all surgical pathologies laparoscopically. Third, his claims are becoming increasingly evident that advantages of laparoscopic surgery are not only shorter hospital stays, smaller incisions, and faster recovery, but also that laparoscopic surgery when performed by an experienced surgeon is associated with fewer complications and better results than laparotomy is.<sup>30–38</sup>

So where did such a man come from?

Camran was born in Iran (Persia). His interest in medicine started very early and became his desire when his mother

became ill and required a great deal of medical care. The doctors involved in her care saved her life.

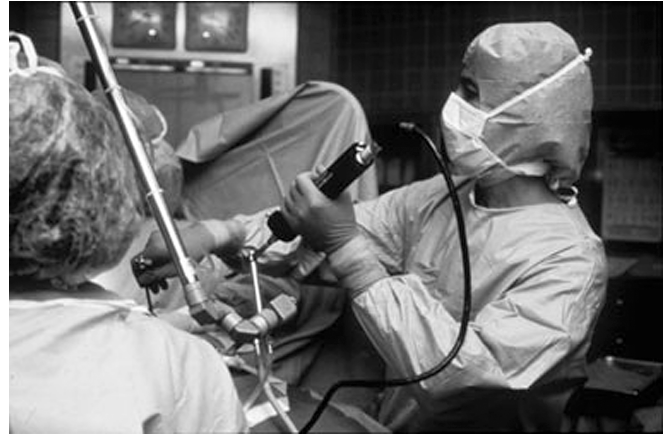After this incident, Camran's father praised the doctors as saviors of their mother. The Nezhat brothers therefore grew up with the knowledge that doctors were highly valued in their family and in the world for their life-saving services. This fueled the desire in the Nezhat brothers to enter medicine. On reflection, because of the significant role that Mrs Nezhat had in the life of her children and because of her steadfast devotion, 3 of the Nezhat brothers did in fact become gynecological surgeons.

During internship and residency at the State University of New York, under the tutelage of Dr Ronald Batt, Camran was exposed to laparoscopy as a diagnostic tool for infertility patients and for those suffering from pelvic pain. During those days, laparotomies were performed even for mild endometriosis. After observing so much postoperative distress suffered by laparotomy patients compared with patients who had diagnostic laparoscopy, Camran thought to himself, "Why shouldn't we treat more surgical pathologies laparoscopically?" The hindrance to expanding from diagnostic to operative laparoscopy, it seemed to him, was not a question of anatomical or physical constraints, but rather was a question of conceptualizing new technologies and methodologies. He learned that other investigators around the world, aware of this potential, were trying to expand the application of laparoscopy. Visualization difficulties from peering crouched over through the endoscope with only one eye seemed the most crucial impediment to overcome. Thus, in recognizing this need and inspired by the earlier pioneers' work, this crucial moment of realization led to a turning point for operative laparoscopy as Camran embarked on refining laparoscopic procedures to assist both patients and the operating team to achieve greater results.

At the forefront and important juncture of the discovery of the advantages of operating on the images (videolaparoscopy), Camran performed endoscopic surgery off the monitor starting in the late 1970s, using very heavy and awkward video camera equipment that had been produced for other uses and which instead he customized—rigged actually—for use with the laparoscope<sup>1-6</sup> (**Figure 1**).

Due to the poor intensity of light sources, at times he used an extra laparoscope connected to the light source only to bring "more light to the subject."

Operating directly from the visual field utilizing only the monitor transformed the operating room from a "one man band" into an "orchestra," so that assisting surgeons,



**Figure 1.** Camran Nezhat, MD, performs endoscopic surgery off the monitor.

nurses, anesthesiologists, students, and others could fully view and therefore more readily assist in and learn the surgery.

After residency, Dr Harold Feldman, one of Camran's professors at that time, recommended him for a fellowship in reproductive endocrinology and infertility under the mentorship of Drs Robert Greenblatt, Don Gambrell, and Virenda Mahesh, PhD, in Augusta, Georgia, who were themselves leaders in reproductive endocrinology and immunology. During this time especially, he confirmed his interest in helping couples suffering from infertility as he saw their overwhelming joy in experiencing parenthood after successful treatment. He was also motivated to assist those women suffering from other debilitating reproductive disorders.

Following this fellowship in 1980, he started his own infertility practice in Atlanta. It was at this time that Camran was able to concentrate more fully on improving and expanding the use of the videolaparoscopy technique and designing new instrumentation. Soon he became one of the most skilled surgeons. Word of mouth began to spread of this approach and soon his practice began to thrive. Patients started arriving from all over the country and abroad.

The videolaparoscopy technique was working extraordinarily well for his infertility patients, many of whom had endometriosis. With these excellent clinical results confirmed, Camran set out to share this technique with other colleagues. Along with Dr Scott Crowgey, a pediatrician teaching physics at the Georgia Institute of Technology, he started teaching postgraduate courses in operative laparoscopy in 1983. It was not until 1986 that he was

finally able for the first time to publish about successful laparoscopic treatment of extensive endometriosis.<sup>2</sup>

Camran has always shared his experiences with his colleagues around the world and has continued to present his methods, results, and his experiences at different medical societies and congresses to explain the benefits of this technique.

He demonstrated that even the most advanced pelvic and abdominal pathologies including advanced stages of endometriosis involving bowel, bladder, ureter, diaphragm, and liver can be successfully treated by videolaparoscopy.<sup>2,4,5,8-34</sup> Camran, his brothers, and others also engaged in research to better understand the origin of endometriomas.<sup>39</sup>

After achieving clinical success numerous times with videolaparoscopy, Camran stated early on, that “if advanced stages of endometriosis can be successfully treated by videolaparoscopy, with the results at least as good as [those of] laparotomy, we can perform practically all the surgical procedures by videolaparoscopy.” In his opinion, videolaparoscopy was the method of choice for an operation whenever a cavity exists in the body or when a cavity can be created.<sup>4,39</sup>

Camran is fortunate to have the support of his family. All of his brothers, including a psychologist, an industrial engineer, and 2 physicians, have encouraged and inspired him. His mother, who passed on 5 years ago, also joined them in Atlanta and was an especially significant source of inspiration. Their father had passed on earlier. Farr and Ceana later joined Camran in his practice.

In collaboration with their colleagues, such as urologists, colorectal surgeons, oncologists, cardiothoracic, vascular and neurosurgeons, the 3 brothers were the forerunners to perform some of the most advanced procedures laparoscopically.<sup>5,8-34</sup>

As they were being recruited by different universities in different parts of the country to teach their techniques, Stanford University Medical Center was the winner!

Ms Linda Meier chairman of the board at Stanford Medical Center and Kenneth Bloom, CEO of the Stanford Medical Center at that time, and Claire Mailhot traveled to Atlanta to convince Camran and his brothers to move to Palo Alto and start teaching and sharing their experience with persons in other surgical disciplines for the purpose of proliferation of endoscopic surgery and teaching future generations of surgeons.

Upon arriving at Stanford, they did collaborate with phy-

sicians in different surgical disciplines and propelled Stanford University to the forefront of endoscopic surgery. In fact, in September 1993, Stanford was one of the few universities to embrace endoscopic surgery. The chairman of surgery at that time was Dr John Niederhauber, an open-minded surgeon, specializing in oncological surgery. After seeing Camran demonstrate the new techniques in the operating room, Dr Niederhauber became a true convert and subsequently collaborated with Camran and other colleagues to perform many general surgical procedures laparoscopically.

Shortly thereafter, Dr Niederhauber honored Camran with a clinical professorship in the Department of Surgery at Stanford. Thus, as a result of these initial leaps of faith and in collaboration with those in different disciplines of surgery, endoscopic surgery at Stanford bound forward.

In 1995, Dr Mary Lake Pollan, OB/GYN Department Chairman at Stanford said:

Nezhat’s contribution was and is unique. He has developed such facility with the technique in the operating room that he serves as a mentor for other physicians, challenging us to learn the new technique by showing us not only the art of the possible, but the tremendous advantage minimal access surgery offers. When you watch him operate, you have to cast off the excuse, ‘this procedure can’t be done using video laparoscopy.’<sup>37</sup> The introduction of videolaparoscopy and videolaseroscopy by Nezhat allowed the involvement of the entire operating team in the surgery. Camran along with his brothers not only performed these procedures elegantly, but he was also willing to teach any- and everyone who expressed an interest. They are very freely and unselfishly willing to share their experience and knowledge with the world.<sup>37</sup>

In 2000, the late Kurt Semm<sup>35</sup> said:

With his genius, he widened the operative field, creating new techniques, employing new instruments, and apparatuses. In my opinion, with the cooperation of his 2 brothers, Camran enriched the entire field of surgical laparoscopy. On June 30, 1980, I performed a laparoscopic appendectomy, which ultimately opened the door for surgeons to perform endoscopic surgery, especially since the appendix was a holy grail of surgery. Today, Dr Nezhat’s book opens a new door to a whole new era of endoscopic surgery.<sup>35</sup>

In 1995, Alan DeCherney, MD, Professor, Department of Obstetrics and Gynecology, UCLA, said:

In the past decade, gynecologic surgery, because of endoscopic surgery, has undergone a tremendous revolution. There are few cases in the gynecologist's surgical armamentarium that cannot be carried out through an endoscopic approach. Many of these changes are due to the courage, innovativeness, and technical skill of Dr Camran Nezhat. Just as in *Star Trek*, he dared to go where no man had gone before and, by doing this, he opened up unimagined vistas to endoscopic surgeons all over the world. For his courage, Camran over the years has suffered but persevered.<sup>34,35</sup>

Like Bozzini, Semm, and others, Camran too was subjected to undue ridicule.<sup>7</sup> For centuries, there has been resistance to accepting novel ideas, even for concepts as simple as washing hands before an operation. It cost Semmelweis his life, while Louis Pasteur was challenged to a duel by a general surgeon. Camran too had to suffer years of struggle and hardship.<sup>7</sup>

For example, when in the mid 1980's Camran presented at the annual meeting of the American Society of Reproductive Medicine, (then American Fertility Society) laparoscopic management of extensive endometriosis and endometriomas, he was faced with disbelief and according to one observer, the audience was ready to "throw tomatoes" at him. In another instance, when Camran and his colleagues first performed and stated that bowel surgery could be accomplished with the laparoscope in the late 1980's, many were ready to crucify them for making such claims. It was not until 2004 that *New England Journal of Medicine* recommended and encouraged laparoscopic bowel resection.<sup>40</sup>

Camran is testament to the fact that being a pioneer is often a very lonely place until our beliefs are tested and proven. It took 20 years, but we are grateful that Camran preserved and held steadfast to his dreams.

We take operating directly off the video monitor or managing advanced surgical pathology laparoscopically for granted, but Camran paid dearly for it. His declaration that "almost all laparotomies can be avoided" was not popularly received at the time, but created such a shift in the thinking that it sparked a whole new generation of surgical specialists to become inspired, opening the door for all disciplines.<sup>35-37</sup>

Camran has been sharing his experiences by teaching postgraduate courses in advanced laparoscopy and hys-

teroscopy since September 1983, and thousands of physicians have been exposed to his teachings.

He especially enjoys being a mentor to young physicians and scientists, who inspire him immensely with their optimism and enthusiasm.

Today, Camran continues to contribute to the Art and Science of Surgery. He is the immediate past president and sits on the Board of Trustees of the Society of Laparoendoscopic Surgeons, is the Director of the Center for Special Minimally Invasive Surgery, and is Clinical Professor of Surgery and OB/GYN at Stanford University School of Medicine. He has published more than 500 articles, book chapters, abstracts, letters to the editor, and video presentations. He is coauthor of 2 textbooks and has won numerous awards and honors from prestigious societies like ACOG, ACS, ASRM, and the Excel Award from the Society of Laparoendoscopic Surgeons. More recent awards include the ACOG 2004, ASRM 2004, and ACOG 2005. He is on the editorial board of the *Journal of Fertility and Sterility* and is an associate editor for *the Journal of Society of Laparoendoscopic Surgeons*.

To Camran Nezhat, we give our thanks for his hard work in sharing with all of us his vision and helping all of us to help our patients and improve our skills. He has expanded our reach and allowed us to provide better care for our patients. He has unselfishly shared his knowledge with us so we could integrate what he knows and does into our work. No wonder he has been called the "Father of Modern Laparoscopy."<sup>41</sup>

And yet, one of the fondest memories is my image of him walking with his brothers on a crowded New York City street, so much just the older brother providing love and support to his family. He has expanded that familial bond to many who have become part of his laparoscopic family through our work with him, especially in that extended family known as the Society of Laparoendoscopic Surgeons.

I have to this day on my desk a picture of Paul Wetter, Camran Nezhat, Farr Nezhat, and Ceana Nezhat standing with me in front of the *JLS* display to remind me of the collegiality, the honor, and the challenge of being a caring physician in the spirit of our SLS family. He has challenged all of us to do better for our patients, and we gratefully accept that challenge.

#### References:

1. Nezhat C. Laser laparoscopy for the treatment of endometriosis. Paper presented at: Conjoint Meeting of the American

- Society for Reproductive Medicine and the Canadian Fertility and Andrology Society; 1985; Toronto, Canada.
2. Nezhat C, Crowgey SR, Garrison CP. Surgical treatment of endometriosis via laser laparoscopy. *Fertil Steril.* 1986;45:778–783.
  3. Nezhat C, Nezhat FR. Safe laser endoscopic excision or vaporization of peritoneal endometriosis. *Fertil Steril.* 1989;52:149–151.
  4. Nezhat C, Nezhat F, Nezhat C. Operative laparoscopy (minimally invasive surgery). State of the art, *J Gynecol Surg.* 1992; 8:111–141.
  5. Nezhat C, Nezhat F, Silfen SL. Videolaseroscopy: the CO<sub>2</sub> laser for advanced operative laparoscopy. *Obstet Gynecol Clin North Am.* 1991;18:585–604.
  6. Cowley G. Hanging up the knife. A novel surgical technique promises to save patients time, money and blood. *Newsweek.* February 12, 1990;58–59.
  7. Nezhat F. Triumphs and controversies in laparoscopy: the past, the present, and the future. *JLSLS.* 2003;7:1–5.
  8. Nezhat F, Nezhat C, Silfen S, Fehnel S. Laparoscopic treatment of ovarian cyst during pregnancy. *J Laparoendosc Surg.* 1991;1:161–164.
  9. Nezhat C, Pennington E, Nezhat F, Silfen S. Laparoscopically assisted anterior rectal wall resection and reanastomosis for deeply infiltrating endometriosis. *Surg Laparosc Endosc.* 1991; 1(2):106–108.
  10. Nezhat C, Winder WK, Nezhat F. Laparoscopic removal of dermoid cysts, *Obst Gynecol.* 1989;73(2):278–281.
  11. Nezhat F, Nezhat C, Pennington E. Laparoscopic proctectomy for infiltrating endometriosis of the rectum. *Fertil Steril.* 1992;57:1129–1132.
  12. Nezhat C, Nezhat F, Green B. Laparoscopic treatment of obstructed ureter due to endometriosis by resection and ureteroureterostomy. *A case report. J Urol.* 1992;148:865–868.
  13. Nezhat C, Burrell M, Nezhat F, Benigno B, Welander CE. Laparoscopic radical hysterectomy with paraaortic and pelvic node dissection. *Am J Obstet Gynecol.* 1992;166:864–865.
  14. Nezhat F, Nezhat C, Levy JS. Laparoscopic treatment of symptomatic diaphragmatic endometriosis: A case report. *Fertil Steril.* 1992;58:614–616.
  15. Nezhat F, Nezhat C, Nezhat CH. Laparoscopic sacral colpopexy for vaginal wall prolapse. *Obstet Gynecol.* 1994;84:885–888.
  16. Nezhat CR, Nezhat FR, Ramirez CE, et al. Laparoscopic radical hysterectomy and laparoscopic assisted vaginal radical hysterectomy with pelvic and para aortic node dissection, *J Gynecol Surg.* 1993;9:105–120.
  17. Nezhat C, Nezhat F, Burrell M. Laparoscopically assisted hysterectomy for the management of borderline ovarian tumor: A case report. *J Laparoendosc Surg.* 1992;2:167–169.
  18. Nezhat C, Nezhat F. Laparoscopic segmental bladder resection for endometriosis: a report of two cases. *Obstet Gynecol.* 1993;81:882–884.
  19. Nezhat C, Nezhat F, Pennington E, et al. Laparoscopic disk excision and primary repair of the anterior rectal wall for the treatment of full thickness bowel endometriosis. *Surg Endosc.* 1994;8:682–685.
  20. Nezhat CH, Nezhat F, Nezhat C, Rottenberg H. Laparoscopic repair of a vesicovaginal fistula: a case report. *Obstet Gynecol.* 1994;83:899–901.
  21. Nezhat CH, Bastidas A, Pennington E, Nezhat F, Raga F, Nezhat C. Treatment of type IV rectovaginal fistula treatment. *J Am Assoc Gyn Lap.* 1998;5:297–299.
  22. Jacobson M, Oesterling S, Milki A, Nezhat CR. Laparoscopic control of a leaking inferior mesenteric vessel secondary to trocar injury. *JLSLS.* 2002;6:389–391.
  23. Jacobson M, Osias J, Velasco A, Charles R, Nezhat C. Laparoscopic repair of a uteroperitoneal fistula. *JLSLS.* 2003;7:367–369.
  24. Nezhat C, Kazerooni T, Berker B, LaShay N, Susan Fernandez S, Marziali M. Laparoscopic management of hepatic endometriosis: report of Two Cases and review of literature. *J Min Invas Gynecol.* 2005;12:196–200.
  25. Nezhat F, Nezhat C, Pennington E, Ambroze W Jr. Laparoscopic segmental resection for infiltrating endometriosis of the recto sigmoid colon: a preliminary report. *Surg Laparosc Endosc.* 1992;2:212–216.
  26. Nezhat C, Nezhat F, Pennington E. Laparoscopic treatment of lower colorectal and infiltrating rectovaginal septum endometriosis by the technique of videolaseroscopy. *Br J Obstet Gynaecol.* 1992;99:664–667.
  27. Nezhat CH, Malik S, Nezhat F, Nezhat C. Laparoscopic ureteroneocystostomy and vesicopsoas hitch for infiltrative endometriosis. *JLSLS.* 2004;8:3–7.
  28. Nezhat CH, Nezhat F, Freiha F, Nezhat C. Laparoscopic vesicopsoas hitch for infiltrative ureteral endometriosis. *Fertil Steril.* 1999;71:376–379.
  29. Nezhat C, Nezhat F. Incidental appendectomy during videolaseroscopy. *Am J Obstet Gynecol.* 1991;165:559–564.
  30. Nezhat C, Childers J, Nezhat F, et al. Major retroperitoneal vascular injury during laparoscopic surgery. *Hum Reprod.* 1997; 12:480–483.
  31. Nezhat C, Nezhat F, Nezhat CH. Laparoscopic Burch procedure. *Operative laparoscopy (minimally invasive surgery): state of the art. J Gynecol Surg.* 1992;8:111–141.

32. Nezhat F, Nezhat C, Bess O, Nezhat CH. Laparoscopic amputation of a non-communicating rudimentary horn after a hysteroscopic diagnosis: a case study. *Surg Laparosc Endosc.* 1994; 4:155–156.
33. Nezhat C, Nezhat F, Silfen SL, et al. Laparoscopic myomectomy. *Int J Fertil.* 1991;36:275–280.
34. Nezhat C, Siegler A, Nezhat F, Nezhat C, Metzger D, Luciano A. Complications. In: *Operative Gynecologic Laparoscopy Principles and Techniques.* New York, NY: McGraw-Hill; 1995;287–310.
35. Nezhat C, Siegler A, Nezhat F, Nezhat C, Seidman D, Luciano A. Complications. In: *Operative Gynecologic Laparoscopy Principles and Techniques.* 2nd ed. New York, NY: McGraw-Hill; 2000;365–390.
36. Nezhat C, Nezhat FR, Nezhat CH, Admon D. Endometriosis of the intestine and genitourinary tract. In: Nezhat CR, ed. *Endometriosis: Advanced Management and Surgical Techniques.* Springer-Verlag; 1995.
37. Nezhat C, Berger GS, Nezhat FR, Buttram, VC, Nezhat C, eds. Operative laparoscopy: preventing and managing complications. In: Nezhat CR, ed. *Endometriosis: Advanced Management and Surgical Techniques.* Springer-Verlag; 1995.
38. Nezhat F, Nezhat C, Allan CJ, Metzger DA, Sears DL. Clinical and histologic classification of endometriomas: implications for a mechanism of pathogenesis. *J Repro Med.* 1992;37:771–776.
39. Nezhat C. Operative endoscopy will replace almost all open procedures. *JSLs.* 2004;8:101–102.
40. Pappas TN, Jacobs DO. Laparoscopic resection for colon cancer—the end of the beginning. *N Engl J Med.* 2004;350(20): 2091–2092.
41. Stanford News Services. Media Monitor. *Stanford Report.* February 9, 2005;9.