

Thoracic endometriosis masquerading as Meigs' syndrome in a young woman: A case report and literature review

Vishal Bahall^{*}, Lance De Barry, Keevan Singh

Department of Obstetrics and Gynaecology, San Fernando General Hospital, South-West Regional Health Authority, Trinidad and Tobago

ARTICLE INFO

Keywords:

Endometriosis
Thoracic endometriosis
Hormonal therapy
Ascites
Pleural effusion

ABSTRACT

Thoracic endometriosis is an exceedingly rare condition characterized by the presence of endometriotic deposits on the diaphragm, lungs or pleural space. Patients may present with massive hemothorax, pneumothorax, hemoptysis or pulmonary nodules. It is a complex condition that often proves to be a diagnostic challenge, resulting in under-diagnosis, delays in treatment and significant morbidity in women of reproductive age. We report a case of endometriosis causing massive pleural effusion and ascites, with a left adnexal fibroid mass mimicking Meigs' syndrome in a nulliparous woman in her late 30s. The patient was successfully managed with hormonal therapy following fertility-sparing surgical treatment. This case highlights the diagnostic and therapeutic challenges associated with thoracic endometriosis because of its close resemblance to more sinister gynecological conditions. Hormonal therapy is the long-term treatment of choice in patients with thoracic endometriosis to reduce the risk of symptom recurrence and preserve fertility.

1. Introduction

Endometriosis is a benign inflammatory condition defined by the presence of endometrial-like tissue (glands and stroma) outside the endometrial cavity that respond to hormonal stimuli and undergo cyclical bleeding [1]. Endometriosis is a significant cause of morbidity in the reproductive age group. It affects up to 10% of women and it is diagnosed in approximately 30% of patients evaluated for infertility [2]. Endometriosis is associated with a myriad of complications, including chronic pelvic pain, dyspareunia, infertility, and ovarian endometriomas; however, thoracic endometriosis remains an exceedingly rare form of extra-pelvic endometriosis [3,4].

Thoracic endometriosis occurs when endometriotic lesions deposit on the diaphragm, lungs or pleural space. This condition is characterized by four clinical entities: catamenial pneumothorax, catamenial hemothorax, pulmonary nodules and hemoptysis [5]. Patients may present with shortness of breath, pleuritic chest pain and massive pleural effusions [6]. The combination of pleural effusion, ascites, an ovarian mass and elevated serum CA-125 levels in a young woman raises the suspicion of a malignant ovarian tumour or Meigs' syndrome [7]. However, these findings may also reflect thoracic endometriosis – a diagnosis that clinicians ought to consider when patients present with this constellation

of symptoms. Despite the diagnostic challenges, thoracic endometriosis can be effectively controlled with hormonal treatment options, which means that patients desiring fertility preservation can avoid surgical menopause [8]. Herein, we report a case of thoracic endometriosis occurring in a woman in her late 30s successfully managed with hormonal therapy following fertility-sparing surgical treatment. In addition, we highlight the perioperative, diagnostic and therapeutic challenges associated with this unusual presentation.

2. Case Presentation

A nulliparous female in her late 30s presented to the gynaecology clinic with complaints of menorrhagia, dysmenorrhea, and increasing abdominal distension for one year. The patient also reported recent onset of shortness of breath on exertion, early satiety, nausea and indigestion. She denied experiencing weight loss, vomiting, constipation, and urinary or constitutional symptoms. She had no medical conditions, and her past gynecological and surgical history was unremarkable. Additionally, the patient had no personal or familial history of cancer.

On clinical examination, the abdomen was distended, firm and tense with a positive fluid thrill, indicating the presence of abdominal free

Abbreviations: CT, Computed tomography; MRI, Magnetic resonance imaging; VATS, Video-assisted thoracoscopy.

^{*} Corresponding author.

E-mail address: vbahall@gmail.com (V. Bahall).

<https://doi.org/10.1016/j.crwh.2022.e00452>

Received 25 September 2022; Received in revised form 28 September 2022; Accepted 29 September 2022

Available online 4 October 2022

2214-9112/© 2022 The Authors. Published by Elsevier B.V. This is an open access article under the CC BY-NC-ND license (<http://creativecommons.org/licenses/by-nc-nd/4.0/>).

fluid. On auscultation of her chest, breath sounds were appreciated at the apex of the right lung and were not present at the mid-to-basal right lung zones. A chest X-ray (Fig. 1A-1B) revealed a massive right-sided pleural effusion extending into the upper lobe of the right lung. Contralaterally, blunting of the left costophrenic and cardiophrenic angles was noted. Pelvic ultrasonography demonstrated an eight-week-sized uterus, the presence of free abdominal fluid and a 6 cm × 6 cm left adnexal mass. Blood investigations denoted microcytic anemia (hemoglobin 8.5 g/dl, mean corpuscular volume 73.2 fl) and normal liver and renal function tests. Her serum cancer antigen CA-125 was elevated (70 U/ml) whilst other tumour markers such as CA19-9, carcinoembryonic antigen (CEA), and alpha-fetoprotein (AFP) were within normal parameters.

A computed tomography (CT) scan of the chest, abdomen and pelvis demonstrated a large volume of right-sided pleural effusion with a secondary collapse of the right middle and lower lung lobes and partial upper lobe collapse (Fig. 2A, B). Additionally, the mediastinum was shifted towards the left while the heart and great vessels appeared unremarkable. Large-volume abdominopelvic ascites were observed within the abdomen's visceral spaces (Fig. 2C). The uterus measured 9.0 cm and contained an innumerable uterine leiomyomas. A left adnexal mass 6 cm in diameter, suggestive of an ovarian fibroma, was observed (Fig. 2D). A 1 cm omental nodule was noted with no lymphadenopathy or peritoneal or pleural lesions. A tentative diagnosis of ovarian fibroma with Meigs' syndrome was considered.

A right thoracostomy tube was placed and approximately 3500 ml of blood-stained pleural fluid was drained over 3 days. Biochemical analysis of the pleural fluid (Table 1) was consistent with an exudative origin while cytology demonstrated the presence of hemosiderin-laden macrophages and atypical cells. A therapeutic paracentesis was also performed and approximately 1400 ml of blood-stained ascites was drained. The biochemical and cytological analysis of the ascitic fluid showed similar findings to the pleural fluid (Table 1). These findings presented a diagnostic dilemma as they were not in keeping with Meigs' syndrome, which is typically associated with a straw-colored exudative-type pleural effusion and ascites. The patient's symptoms markedly improved after the pleural and ascitic tap. A decision was made to undergo an exploratory laparotomy. Although the patient desired fertility preservation, she was counseled extensively on the possibility of ovarian malignancy and the potential for radical surgery, which included a possible total hysterectomy, bilateral salpingo-oophorectomy, infracolic omentectomy and pelvic lymph node dissection. The patient's blood count was optimized to 10.4 g/dl preoperatively with one blood transfusion.

Intraoperatively, the abdomen was opened in layers via a midline incision. Approximately 2 litres of blood-stained ascitic fluid was

evacuated. There was extensive evidence of intra-abdominal pelvic endometriosis. Gross lesions were observed on the uterine serosa, bladder peritoneum, pouch of Douglas, omentum, and peritoneal surfaces of the abdominal wall. Peritoneal nodules were also palpated on the under-surface of the right hemidiaphragm above the liver. Appearances were consistent with endometriotic deposits. The uterus was approximately 12 weeks in size and contained many intramural and submucosal uterine leiomyomas. The left adnexal mass observed on presurgical imaging was a 6 cm × 6 cm subserosal leiomyoma that was adherent to the left ovary. Considering these intraoperative findings, a diagnosis of symptomatic uterine fibroids and stage 4 endometriosis with thoracic involvement was considered. The planned total abdominal hysterectomy, bilateral salpingo-oophorectomy, peritoneal washings, omentectomy and peritonectomy were abandoned. A myomectomy, adhesiolysis, left ovarian cystectomy and infra-colic omentectomy were performed. Multiple subserosal and intramural uterine leiomyomas were removed with the largest myoma measuring 6 cm × 6 cm.

Histopathology of the surgical specimen demonstrated benign leiomyomas and a hemorrhagic corpus luteal ovarian cyst with no evidence of malignancy. The omental specimen demonstrated numerous nodular deposits of endometriosis comprising cystically dilated endometrial-type glands and stroma with foci of hemorrhage and no evidence of malignancy (Fig. 3). These findings confirmed the diagnosis of stage 4 endometriosis. The thoracostomy tube was removed on postoperative day 1 and a repeat chest X-ray demonstrated 95% resorption of the right hemothorax. The patient's postoperative hemoglobin level was 9.9 g/dl. Her postoperative course was unremarkable, and she was discharged on postoperative day 2. She was started on the fourth-generation progestogen dienogest 2 mg tablet daily and was counseled on the importance of adherence to the medication to reduce the risk of symptom recurrence. At her postoperative follow-up visits 10 days, 6 weeks and 3 months later, she was well and reported no recurrence of her symptoms. A chest X-ray and abdominopelvic ultrasound scan at this time revealed no residual pleural fluid or ascites.

3. Discussion

Extrapelvic endometriosis, traditionally considered to be uncommon, has been identified in a significant number of cases. Extrapelvic endometriosis typically affects four anatomic sites: the lungs, bowel and omentum, urinary tract, and central nervous system [9]. A systematic review done by Andres et al. in 2019 demonstrated that the thorax is the most common site of extrapelvic endometriosis with approximately 628 cases of thoracic endometriosis reported out of 920 cases of extrapelvic endometriosis [10].

Notwithstanding, thoracic endometriosis is a rare condition associated with significant morbidity. Thoracic endometriosis primarily affects nulliparous women of African descent, in the reproductive age group [11]. A retrospective analysis involving 110 patients demonstrated that the mean age at presentation is 35 years with a peak incidence occurring between 30 and 34 years of age [5]. Notably, the peak incidence of pelvic endometriosis in this sample of patients occurred between the ages of 24 and 29 while the peak incidence of thoracic endometriosis occurred around 5 years later [5]. The overall prevalence of thoracic endometriosis is unknown, largely because this condition is often underdiagnosed [6].

The etiological mechanisms of thoracic endometriosis are not well understood; however, three theories have been proposed to explain the presence of endometriotic implants in the thorax. These include coelomic metaplasia, lymphatic or hematogenous embolization of endometrial tissue, and retrograde menstruation with transperitoneal and transdiaphragmatic migration of endometrial tissue [12]. The notion of coelomic metaplasia is based on the idea that endometrium, pleural and peritoneal mesothelium share the same embryologic origin [5]. In this regard, pathogenic stimuli may be responsible for inducing endometrial cellular differentiation in pleural or peritoneal precursor

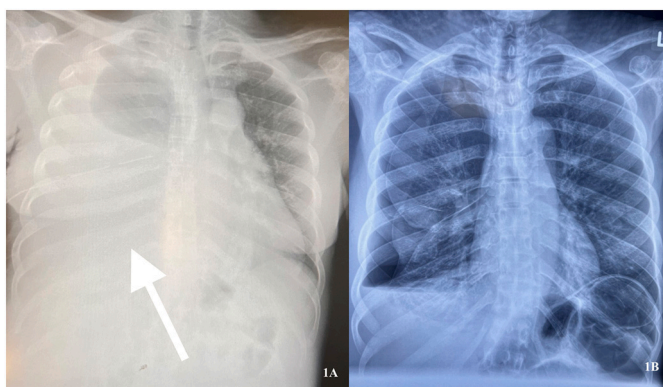


Fig. 1. Chest radiographs: (1A) Erect chest X-ray demonstrates massive right-sided pleural effusion extending to the apex of the right lung. (1B) Erect chest X-ray demonstrates 85% resolution of hemothorax following thoracentesis and initiation of hormonal therapy.

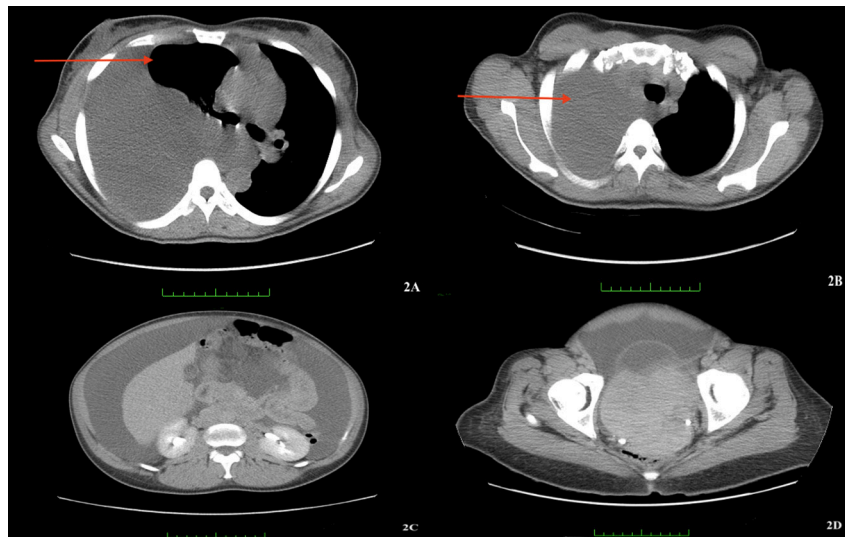


Fig. 2. Computed tomography (CT) scan of the chest and abdomen. (2A) Axial thoracic scan demonstrates the collapse of the right lung. (2B) Axial thoracic scan demonstrates massive right-sided pleural effusion. (2C) Axial abdominal scan reveals massive ascites around the liver. (2D) Pelvic scan demonstrates 6 cm adnexal mass, likely an ovarian fibroma.

Table 1
Biochemical and cytological analysis of pleural and ascitic fluid.

	Serum	Pleural fluid	Ascitic fluid
Albumin (g/ dl)	3.1	1.8	3.1
Protein (g/ dl)	5.6	3.3	5.8
Lactate dehydrogenase (LDH) (u/l)	216	631	1298
Cytological features	–	-Blood stained -Hemosiderin-laden macrophages -Endometrial cells	-Blood stained -Hemosiderin-laden macrophages -Endometrial cells

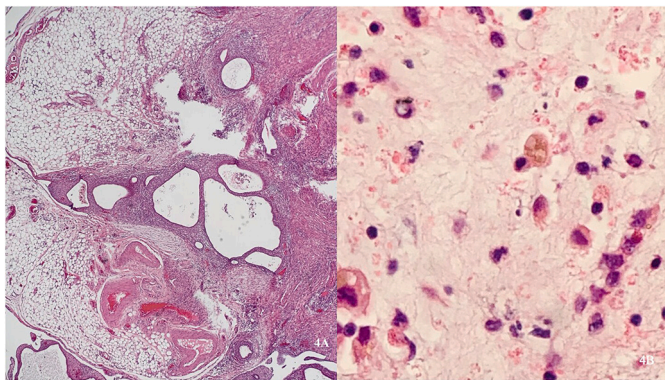


Fig. 3. Histopathology. (3A) Histopathology of the omental specimen demonstrates numerous nodular deposits of endometriosis comprising cystically dilated endometrial-type glands and stroma with foci of hemorrhage. (3B) Pleural fluid cytology demonstrates the presence of hemosiderin-laden macrophages and atypical cells likely of gynecological origin.

cells [5]. However, this theory does not explain the observed right-sided predominance of thoracic disease. Transdiaphragmatic migration of endometrial tissue through congenital diaphragmatic defects or acquired fenestrations is the leading theory proposed for the etiology of thoracic endometriosis [13]. The thoracoabdominal pressure gradient, augmented by the presence of the liver, may promote migration and colonization of the diaphragm or pleural space by ectopic endometrial tissue and explains the right-sided predominance of thoracic

endometriosis [5,13]. Unfortunately, these theories cannot account for all the clinical presentations of thoracic endometriosis.

Patients with thoracic endometriosis typically present with catamenial pneumothorax (73%), catamenial haemothorax (14%), haemoptysis (7%), and pulmonary nodules (6%) [4]. In almost all cases, the right lung is involved [5]. Patients often report chest pain, shortness of breath, and cough, and in some cases symptoms are cyclical, occurring within 72 h after the onset of menstruation [6]. Patients may also experience conventional signs and symptoms of endometriosis, including chronic pelvic pain, dyspareunia, dysmenorrhea, menorrhagia, infertility, and ovarian endometriomas [3]. In rare instances, blood-stained ascites may coexist with thoracic endometriosis – a manifestation likely arising from peritoneal implantation of endometriotic lesions [14]. The clinical presentation of massive pleural effusion involving the entire pleural cavity, ascites and an ovarian mass in a young woman may raise the suspicion of Meigs' syndrome or ovarian cancer [7]. Similar to our case, the presence of blood-stained pleural and ascitic fluid and unequivocal imaging and laboratory investigations may indicate a diagnosis of extensive endometriosis with thoracic and peritoneal involvement.

Thoracic endometriosis poses a unique diagnostic challenge as it resembles more sinister gynecological conditions, like ovarian malignancy or Meigs' syndrome. Video-assisted thoracoscopy (VATS) is currently the preferred method for the surgical assessment of patients with thoracic endometriosis [15]. VATS can identify the presence of endometriotic implants on the diaphragm or pleura, assess the diaphragm for perforations or larger defects and allow biopsy or excision of suspicious lesions [12,15]. Although VATS provides a definitive diagnosis of thoracic endometriosis, most cases are diagnosed clinically, utilizing a combination of radiologic modalities such as chest radiography, computed tomography (CT) scans or magnetic resonance imaging (MRI), cytological and biochemical analysis of pleural fluid, and laparoscopic evidence of pelvic endometriosis [4]. CT scans may reveal nodular pleural or pulmonary lesions, multiloculated effusions, and bulky pleural masses or may demonstrate evidence of ovarian endometriomas [12,16]. A pleurocentesis and/or paracentesis specimen may appear haemorrhagic or serosanguinous and cytological analysis may reveal the presence of hemosiderin-laden histiocytes, and endometrial cells [17]. Biochemical analysis of the pleural sample usually confirms an exudative-type fluid characterized by an elevated pleural-to-serum protein ratio and lactate dehydrogenase (LDH) concentration [14,17]. In some cases, concentrations of the serum cancer antigen CA-125, may be elevated – a non-specific finding associated with endometriosis and

ovarian malignancy [14].

Medical management is the mainstay of therapy to control symptoms and reduce recurrence. Medical treatment options include the combined oral contraceptive pill, progestins, gonadotrophin-releasing hormone (GnRH) analogues and danazol. New progestins are the recommended first-line hormonal treatment option. Daily treatment with 2 mg dienogest is linked to a decreased recurrence of both thoracic and pelvic endometriosis symptoms [14,18]. Dienogest, unlike GnRH analogues, does not reduce estradiol levels to postmenopausal levels and can therefore be administered continuously until pregnancy is desired or negative effects arise [19]. Though effective, the use of GnRH analogues is limited to only up to six months as these agents simulate menopause and lead to bone loss, hot flashes, and vaginal dryness with extended use [20]. Patients who are refractory to medical treatment or experience recurrent disease may require surgical treatment with postoperative hormonal therapy [8]. Fertility-sparing surgical treatment options include VATS with excision of endometriotic lesions followed by hormonal treatment to reduce the risk of recurrence [8]. Definitive surgical intervention in the form of bilateral salpingo-oophorectomy and hysterectomy is an effective therapeutic option with low recurrence rates and is particularly worthwhile in women who no longer desire fertility [4].

In conclusion, thoracic endometriosis causing a pleural effusion that fills the entire pleural cavity is rare. This case posed a diagnostic challenge due to the left adnexal fibroid mass, ascites and pleural effusion resembling ovarian cancer or Meigs' syndrome. The most common manifestation of thoracic endometriosis is catamenial pneumothorax followed by catamenial haemothorax. Microembolization through pelvic veins and peritoneal-pleural migration of endometrial tissue through diaphragmatic defects are the most likely explanations for the pathogenesis of thoracic endometriosis. In most cases, the diagnosis is based on clinical evidence. Fertility preservation utilizing hormonal therapy is currently the standard of care for women diagnosed with thoracic endometriosis, as it averts the need for surgical menopause. Early detection and treatment of thoracic endometriosis significantly reduce the disease morbidity in women during their reproductive years.

Contributors

Vishal Bahall conceived, supervised and drafted the manuscript and performed the abdominal myomectomy.

Lance De Barry drafted and revised the manuscript, performed the literature review, and was involved in perioperative patient care.

Keevan Singh drafted, edited, and revised the manuscript and was involved in perioperative patient care.

All authors revised the draft and approved the final manuscript.

Funding

No funding from an external source supported the publication of this case report.

Patient consent

Written informed consent was obtained from the patient for the publication of this case report and accompanying images.

Provenance and peer review

This article was not commissioned and was peer reviewed.

Acknowledgements

The authors would like to thank all anonymous reviewers and editors for their helpful suggestions for the improvement of this paper.

Conflict of interest statement

The authors declare that they have no conflict of interest regarding the publication of this case report.

References

- [1] L.C. Giudice, L.C. Kao, *Endometriosis*, *Lancet* 364 (9447) (2004) 1789–1799.
- [2] C. Bulletti, M.E. Coccia, S. Battistoni, A. Borini, *Endometriosis and infertility*, *J. Assist. Reprod. Genet.* 27 (8) (2010) 441–447.
- [3] S.E. Bulun, *Endometriosis*, *N. Engl. J. Med.* 360 (3) (2009) 268–279.
- [4] M. Singh, R.B. Singh, A.B. Singh, A.L. Carballo, A. Jain, *Thoracic endometriosis: still a diagnostic dilemma*, *Cureus*. 13 (6) (2021) e15610-e.
- [5] J. Joseph, S.A. Sahn, *Thoracic endometriosis syndrome: new observations from an analysis of 110 cases*, *Am. J. Med.* 100 (2) (1996 Feb) 164–170, [https://doi.org/10.1016/s0002-9343\(97\)89454-5](https://doi.org/10.1016/s0002-9343(97)89454-5) (PMID: 8629650).
- [6] H. Huang, C. Li, P. Zarogoulidis, K. Darwiche, N. Machairiotis, L. Yang, et al., *Endometriosis of the lung: report of a case and literature review*, *Eur. J. Med. Res.* 18 (1) (2013) 13.
- [7] S. Saha, M. Robertson, *Meigs' and Pseudo-Meigs' syndrome*, *Australas J. Ultrasound Med.* 15 (1) (2012 Feb) 29–31, <https://doi.org/10.1002/j.2205-0140.2012.tb00140.x>. Epub 2015 Dec 31. PMID: 28191137; PMCID: PMC5025132.
- [8] M. Alifano, T. Roth, S.C. Broët, O. Schussler, P. Magdeleinat, J.F. Regnard, *Catamenial pneumothorax: a prospective study*. (0012–3692 (Print)), *Chest.*, 2003.
- [9] A. Augoulea, I. Lambrinouadaki, G. Christodoulakos, *Thoracic endometriosis syndrome*, *Respiration*. 75 (1) (2008) 113–119.
- [10] M.P. Andres, F.V.L. Arcoverde, C.C.C. Souza, L.F.C. Fernandes, M.S. Abrão, R. M. Kho, *Extrapelvic Endometriosis: A Systematic Review*, *J Minim Invasive Gynecol.*, 2019 (1553-4669 (Electronic)).
- [11] D. Chooljian, J. Ng, T. Murakami, T. Miyai, C.-H. Chang, J. Chung, et al., *Endometriosis as a cause of massive ascites and pleural effusion*, *CHEST*. 142 (4) (2012) 501A.
- [12] M. Alifano, R. Trisolini, A. Cancellieri, J.F. Regnard, *Thoracic endometriosis: current knowledge*, *Ann. Thorac. Surg.* 81 (2) (2006) 761–769.
- [13] P.A. Kirschner, *Porous diaphragm syndromes*, *Chest Surg. Clin. N. Am.* 8 (2) (1998 May) 449–472 (PMID: 9619316).
- [14] V. Bahall, L. De Barry, S.S. Harry, M. Bobb, *Gross Ascites Secondary to Endometriosis: A Rare Presentation in Pre-Menopausal Women*. (2168–8184 (Print)), *Cureus*, 2021.
- [15] S. Korom, H. Canyurt, A. Missbach, D. Schneiter, M.O. Kurrer, U. Haller, P.J. Keller, et al., *Catamenial pneumothorax revisited: clinical approach and systematic review of the literature*. (0022–5223 (Print)), *J Thorac Cardiovasc Surg.*, 2004.
- [16] T.M. Ziedalski, V. Sankaranarayanan, R.K. Chitkara, *Thoracic endometriosis: a case report and literature review*, *J. Thorac. Cardiovasc. Surg.* 127 (5) (2004 May) 1513–1514, <https://doi.org/10.1016/j.jtcvs.2003.12.016> (PMID: 15116017).
- [17] M. Chan-Tiopianco, W.-T. Chao, P.R. Ching, L.-Y. Jiang, P.-H. Wang, Y.-J. Chen, *Clinical presentation and management of endometriosis-related hemorrhagic ascites: a case report and systematic review of the literature*, *Cureus*. 13 (6) (2021) e15828-e.
- [18] A. Murji, K. Biberoglu, J. Leng, M.D. Mueller, T. Römer, M. Vignali, et al., *Use of dienogest in endometriosis: a narrative literature review and expert commentary*, *Curr. Med. Res. Opin.* 36 (5) (2020) 895–907.
- [19] S.Y. Park, S.H. Kim, H.D. Chae, C.-H. Kim, B.M. Kang, *Efficacy and safety of dienogest in patients with endometriosis: a single-Centre observational study over 12 months*, *Clin. Exp. Reproduct. Med.* 43 (4) (2016) 215–220.
- [20] P. Kumar, A. Sharma, *Gonadotropin-releasing hormone analogs: understanding advantages and limitations*, *J. Human Reproduct. Sci.* 7 (3) (2014) 170–174.