



A 360° Labral Repair Using Two Portals and a Percutaneous Cannula

James Gwosdz, M.D., Moyukh Chakrabarti, M.B.B.S., Alexander Rosinski, M.S.,
Patrick J. McGahan, M.D., and James L. Chen, M.D., M.P.H.

Abstract: Pan-labral tears are relatively uncommon, but they present significant challenges to arthroscopists. The difficulty lies in the need to access the glenoid rim circumferentially for proper anchor placement. Traditionally, this requires that multiple portals and percutaneous access be established as needed. Additionally, proper preoperative planning is needed to accurately reduce the labrum. In this Technical Note, we demonstrate a technique that accomplishes circumferential access and a well-planned approach with 2 portals and a percutaneous cannula.

Introduction

The shoulder labrum is a complex structure that provides static stability to the shoulder joint. It increases the depth of the glenoid socket by 50% and acts via a concavity–compression mechanism to prevent displacement of the humerus.^{1,2} Given the dynamic nature of the shoulder joint, an injury to this structure can have a significant effect on patients. Patients with labral pathology may be asymptomatic or exhibit a variety of symptoms depending on the location and severity of the lesion. The range of symptoms includes pain, weakness, and instability.³ Labral tears are classified by location, which correlates with mechanism of injury.² Tears at the anteroinferior glenoid rim are called Bankart lesions, tears of the posteroinferior labrum are called reverse Bankart lesions, and separations of the superior labrum that extend anteriorly and posteriorly are called SLAP tears.⁴ More extensive labral tears consist

of combined anterior, superior, and posterior lesions called “triple labral lesions,” and complete tears that encompass the entire glenoid are referred to as circumferential, pan-labral, or 360° tears.^{4,5} Some studies refer to triple labral lesions, 270° tears, and 360° tears as pan-labral tears, leading to some inconsistency with this terminology⁶; however, the current classification system refers to a circumferential labral tear as a type IX SLAP lesion or pan-labral tear (Table 1).^{4,5,7}

Whether the injury is a true pan-labral tear or a triple labral lesion, the preferred surgical treatment is to restore native labral anatomy and function with suture anchor fixation (Fig 1). Studies report the use of an average of 7 to 7.9 anchors to repair this injury.⁴⁻⁶ The number of portals used varies per study but generally

Table 1. SLAP Tear Classification⁴

Type	SLAP tear description
I	Fraying of the superior labrum
II	Superior labrum detached from supraglenoid tubercle
III	Superior labrum bucket-handle tear, biceps tendon intact at supraglenoid tubercle
IV	Superior labrum bucket-handle tear, biceps tendon detached from supraglenoid (still attached to labral tear)
V	Superior labrum detached with extension to anteroinferior labrum (Bankart)
VI	Unstable flap tear with detached biceps anchor
VII	Superior labrum detached with extension anteriorly below the middle glenohumeral ligament, biceps detached
VIII	Superior labrum detached with posteroinferior extension (as far as 6 o'clock)
IX	Pan-labral tear extending the entire circumference of the glenoid
X	Superior labrum detached, associated posteroinferior tear (reverse Bankart)

From *Advanced Orthopaedics and Sports Medicine*, San Francisco, California, U.S.A.

The authors report that they have no conflicts of interest in the authorship and publication of this article and that no funding or financial remuneration was received. Full ICMJE author disclosure forms are available for this article online, as [supplementary material](#).

Received February 4, 2019; accepted March 13, 2019.

Address correspondence to James Gwosdz, M.D., *Advanced Orthopaedics and Sports Medicine*, 450 Sutter St., Suite 400, San Francisco, CA 94108, U.S.A. E-mail: jagwosdz@gmail.com

© 2019 by the Arthroscopy Association of North America. Published by Elsevier. This is an open access article under the CC BY-NC-ND license (<http://creativecommons.org/licenses/by-nc-nd/4.0/>).

2212-6287/19142

<https://doi.org/10.1016/j.eats.2019.03.014>

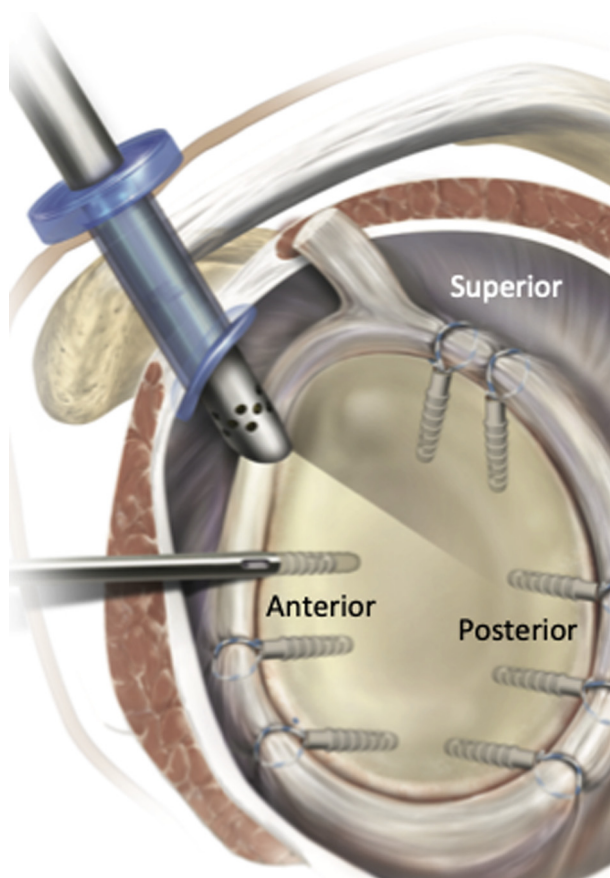


Fig 1. Graphic of the left shoulder demonstrating circumferential repair of the labrum with a total of 8 anchors.

consists of 3 or more portals with percutaneous portals created as needed.⁵⁻⁹ In this Technical Note, we describe a circumferential repair using only 2 portals and a percutaneous cannula to place 6 anchors (2 anterior, 2 superior, and 2 posterior). Our aim was to describe a highly efficient and reproducible technique that minimizes the number of portals needed, thus reducing the risk of iatrogenic injury and decreasing surgical time.

Surgical Technique

Patient Setting

An interscalene block is placed, followed by the induction of general anesthesia (Video 1). With the patient under anesthesia, both shoulders are examined, including passive range of motion, load and shift tests, and sulcus sign testing. Next, the patient is positioned in a modified lateral position with the use of a wedge bump. The operative extremity is then prepped and draped in normal sterile fashion. A sterile traction sleeve is placed over the arm and secured with the use of 3M Coban Self-Adherent Wrap (3M, St Paul, MN).

Ten pounds of skeletal traction is then applied to the arm.

Diagnostic Arthroscopy

A posterior portal is placed in the soft spot of the shoulder, approximately 2 cm inferior and 1 cm medial to the posterolateral corner of the acromion (Table 2). The glenoid and humeral head articular cartilage is examined, along with the labrum and biceps tendon. If the biceps tendon is inflamed, an arthroscopic biceps tenodesis is performed. The subscapular and axillary recess is also examined. An anterior portal is placed anterior to the acromioclavicular joint and lateral to the coracoid in the rotator interval. It is needle localized just superior to the subscapularis tendon to facilitate anchor placement later in the procedure. An 8.25-mm cannula is placed into the anterior portal over a switching stick. A probe is then used to determine the extent of separation of the labrum from the glenoid rim.

Repair of Anterior Labrum (Left Shoulder)

An elevator is used to mobilize the labrum from the glenoid (Fig 2). A 45° curve right ReelPass SutureLasso (Arthrex, Naples, FL) is placed through the anterior portal and guided through capsule and labrum in the 8 o'clock position (Fig 3). A generous amount of PDS (polydioxanone) suture is unreeled, and the suture passer is removed. A suture grasper is placed through the anterior portal and used to retrieve the PDS suture. A piece of 2-0 FiberWire (Arthrex) is threaded through the middle of a half hitch knot that is thrown in the retrieved end of PDS suture. The half hitch is secured and the FiberWire is pulled through the anterior portal by pulling the ReelPass SutureLasso away from the patient. The PDS suture is removed from the FiberWire, and a racking hitch suture is placed by threading the 2 free ends of FiberWire through the looped end of the FiberWire and cinching it down to the labrum. A drill guide is inserted into the anterior portal and placed in the desired location at the edge of the glenoid, 45° to the bony surface. To prevent skiving, the guide is tapped gently with a mallet and a pilot hole is drilled with the included drill for the 2.9-mm PushLock (Arthrex). The free ends of FiberWire are then threaded through the islet of a 2.9-mm PushLock and placed through the portal while the surgeon holds tension on the suture. The PushLock is malleted into the pilot hole, securing the racking hitch suture to bone. A closed suture cutter is used to safely cut the excess FiberWire. The process is

Table 2. Portal Use

Repair Location	Viewing Portal	ReelPass	Anchor Insertion
Anterior labrum	Posterior	Anterior	Anterior
SLAP	Posterior	Anterior	Superolateral
Posterior labrum	Anterior	Posterior	Posterior

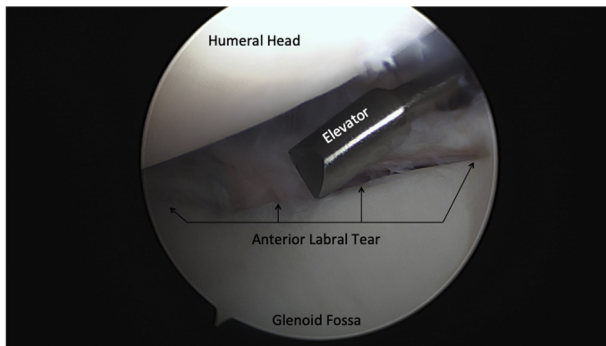


Fig 2. Arthroscopic image of the left glenohumeral joint viewed from the posterior portal with the patient in a right modified lateral decubitus position. The humeral head and glenoid are labeled. An anterior labral tear is present. An elevator is used to freshen the labrum and glenoid rim.

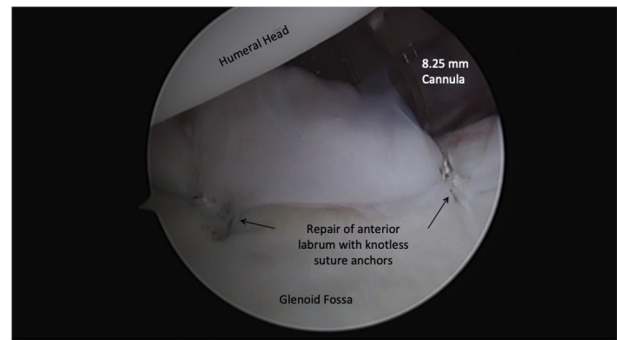


Fig 4. Arthroscopic image of the left glenohumeral joint viewed from the posterior portal with the patient in a right modified lateral decubitus position. The anterior labrum has been repaired with knotless suture anchors in the 8 o'clock and 10 o'clock positions.

then repeated at the 10 o'clock position (Fig 4). This is the technique used to place all PushLocks, with the main exception being which portal is used.

Repair of SLAP Tear

With use of the anterior portal, a 45° curve right ReelPass SutureLasso is used to place a racking hitch suture with FiberWire in the 1 o'clock position. At this point, a superolateral 5.4-mm percutaneous cannula is placed anterior and lateral to the acromion to facilitate optimal anchor placement. With a Percutaneous Insertion Kit (Arthrex), a spinal needle is inserted posterior to the biceps tendon under direct visualization through the posterior portal. A nitinol wire is placed through the needle, and the needle is removed. A dilator is placed over the nitinol wire, and then the wire is removed. The final step is to place the cannula over the dilator and remove the dilator. A drill guide is then placed through the percutaneous cannula, a pilot hole

is drilled, and a 2.9-mm PushLock is impacted. Once the 1 o'clock PushLock anchor is secured, a 2 o'clock anchor is placed using the same technique and portals (Figs 5 and 6).

Move Arthroscope to Anterior Portal

With the use of 2 switching sticks, the 8.25-mm cannula is removed from the anterior portal, and the scope sheath is moved from the posterior portal. The scope sheath is placed into the anterior portal over the switching stick, the switching stick is removed, and the arthroscope is inserted. The cannula is then placed into the posterior portal over the switching stick under direct visualization.

Repair of the Posterior Labrum

With a view from the anterior portal, the posterior inferior labral tear is identified. The labrum is probed and mobilized with an elevator through the posterior portal. A 45° curve right ReelPass is then used to pass suture around the labrum at the 5:30 position, a racking hitch

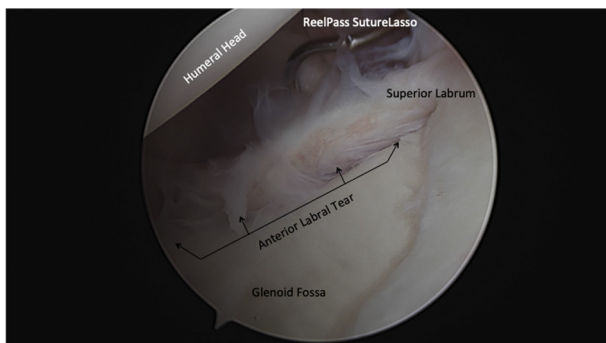


Fig 3. Arthroscopic image of the left glenohumeral joint viewing from the posterior portal with the patient in a right modified lateral decubitus position. The anterior labral tear can be appreciated. A ReelPass SutureLasso (Arthrex) has been introduced into the glenohumeral joint through the anterior portal and is in position to be looped around the anterior labrum in the 10 o'clock position.

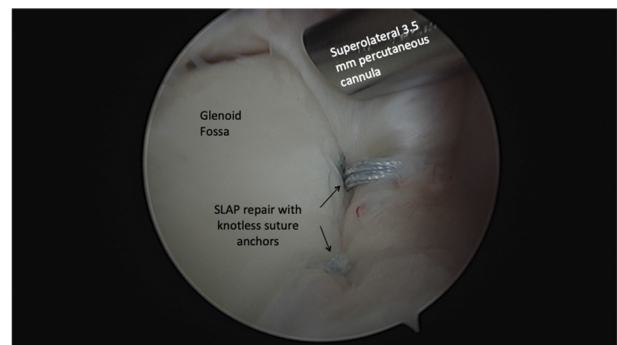


Fig 5. Arthroscopic image of the left glenohumeral joint viewing from the posterior portal with the patient in a right modified lateral decubitus position. The superior labrum has been repaired posterior to the biceps tendon with knotless suture anchors in the 1 o'clock and 2 o'clock positions.

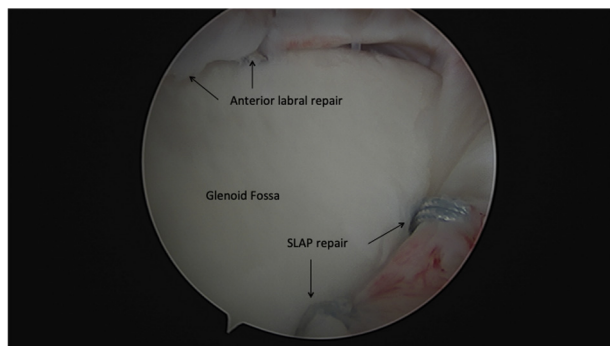


Fig 6. Arthroscopic image of the left glenohumeral joint viewing from the posterior portal with the patient in a right modified lateral decubitus position. The anterior labral repair is visualized with knotless suture anchors at 10 o'clock and 8 o'clock. The SLAP repair is visualized with knotless suture anchors at 1 o'clock and 2 o'clock. Note the labrum is anatomically reduced at each point of fixation.

suture is placed, a pilot hole is drilled, and a posterolateral anchor is impacted. These steps are repeated for the sixth and final anchor in the 4:30 position (Fig 7).

Discussion

Although not well documented in the literature, initial reports supporting primary arthroscopic repair of pan-labral tears are promising. Burkhart and Lo⁵ followed 7 patients with combined superior, anterior, and posterior labral tears termed "triple labral lesions," but only 2 of these tears were complete 360° tears. Overall, 6 of the 7 patients were satisfied with the procedure and had no recurrent pain or instability. In Tokish et al.'s⁷ series of 41 shoulders (39 patients), they reported significant improvement in average scores for pain, instability, and function after arthroscopic labral repair with an average of 7.1 anchors used per procedure. Visual-analog scale scores improved from 4.3 to 1.1, instability scores

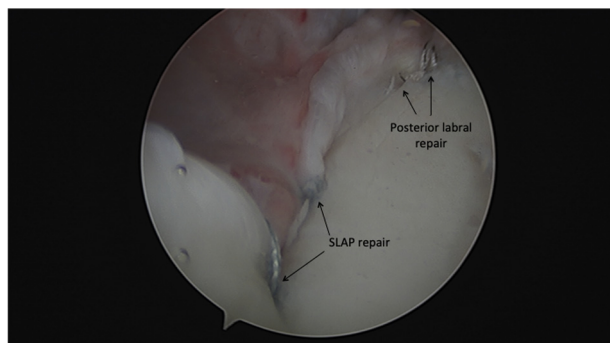


Fig 7. Arthroscopic image of the left glenohumeral joint viewing from the anterior portal with the patient in a right modified lateral decubitus position. The SLAP repair is visualized with knotless suture anchors at 1 o'clock and 2 o'clock, as well as the posteroinferior labral repair with suture anchors at the 4:30 and 5:30 positions. Note the labrum is anatomically reduced at each point of fixation.

Table 3. Advantages and Disadvantages

Advantages

- Decreased surgical time
- Lower risk of iatrogenic injury from portal placement
- No anteroinferior portal needed
 - Decreased risk of injury to axillary and musculocutaneous nerves¹⁰
 - Decreased risk of perforating inferior cortex of the glenoid rim¹¹
- Systematic and sequential approach minimizes steps and portal changes

Disadvantages

- Technically difficult to place anteroinferior anchors in some cases
- May not have optimal angle for drilling into anteroinferior glenoid rim.
- Use of knotless sutures does not allow delayed suture tying, which some authors recommend to avoid overconstraint of the labrum⁸

improved from 7.3 to 0.2, the modified American Shoulder and Elbow Surgeons score improved from 55.5 to 89.6, and all patients returned to their preinjury activity level. Ricchetti et al.'s⁶ series of 44 shoulders defined pan-labral tears as combined superior, anterior, and posterior tears with at least 270° of the labrum torn. In this series, outcomes following arthroscopic repair of the labrum with an average of 7.9 anchors were also positive. At final follow-up, the average American Shoulder and Elbow Surgeons and Penn shoulder scores were >90, and 69% of patients had returned to their preinjury level of function.

Most documented techniques involve a minimum of 3 portals with additional percutaneous portals established as needed.⁵⁻⁹ The technique described in this report offers a number of advantages compared with the traditional strategy (Table 3). The standard arthroscopic approach to the shoulder is used, eliminating the need for anteroinferior and posteroinferior portals, which inherently carry greater risk. Anteroinferior portals place the axillary nerve, musculocutaneous nerve, and cephalic vein at risk.^{10,11} In addition, this portal is known to carry an increased risk of perforating the inferior glenoid cortex when anchors are placed.¹¹ A posteroinferior portal places the suprascapular nerve and artery, axillary artery, and posterior circumflex artery at risk.¹⁰ Access to the glenohumeral joint via a superolateral percutaneous cannula is also

Table 4. Technical Pearls

- Accurately restoring the anatomic position of the labrum minimizes overconstraint of the shoulder.
- Working anterior to posterior minimizes the need to change portals.
- Needle localizing the anterior portal just superior to the subscapularis tendon allows for access to the anteroinferior glenoid rim.
- Lateralizing the posterior portal allows access for anchor placement in the posterior labrum.
- Minimizing portals decreases risk for iatrogenic injury and decreases surgical time.

common and relatively safe.^{10,12} The need for only 2 portals allows for efficient sequential repair of the labrum. When moving from anterior to posterior, the arthroscope only needs to change portals once during the entire procedure (Table 4). This technique simplifies a complex procedure and can be safely and efficiently replicated by surgeons.

A possible disadvantage of this technique is the technical difficulty in placing certain anchors. In particular, the anteroinferior anchors are placed through the standard anterior portal, which is more superior than ideal for these anchors. Usually, a more risky anteroinferior is created for placing anteroinferior anchors. To facilitate optimal trajectory through this portal, the anterior portal is needle localized just superior to the subscapularis tendon when it is created. In some locations, a slightly less ideal anchor angle is accepted to minimize the creation of additional portals. Additionally, some authors recommend tying sutures after all anchors have placed to prevent overconstraint of the labrum.⁸ The use of knotless suture anchors in this technique does not allow delayed suture tying. This risk can be mitigated by taking care to anatomically reduce the labrum as accurately as possible when each anchor is placed.

In summary, pan-labral tears can be difficult to treat, but with proper technique, patients can expect good to excellent outcomes. Given the complexity of repairing this injury, it is important to have a well-planned systematic approach. Additionally, minimizing the risk of iatrogenic injury and decreasing surgical time are achieved by using the 2-portal and 1-percutaneous cannula technique described.

References

1. Matsen FA, Chebli C, Lippitt S. American Academy of Orthopaedic Surgeons. Principles for the evaluation and management of shoulder instability. *J Bone Joint Surg Am* 2006;88:648-659. <http://www.ncbi.nlm.nih.gov/pubmed/16541527>. Accessed December 5, 2018.
2. Knesek M, Skendzel JG, Dines JS, Altchek DW, Allen AA, Bedi A. Diagnosis and management of superior labral anterior posterior tears in throwing athletes. *Am J Sports Med* 2013;41:444-460.
3. Van Blarcum GS, Svoboda SJ. Glenohumeral instability related to special conditions: SLAP tears, pan-labral tears, and multidirectional instability. *Sports Med Anthrosc Rev* 2017;25:e12-e17.
4. Powell SE, Nord KD, Ryu RKN. The diagnosis, classification, and treatment of SLAP lesions. *Oper Tech Sports Med* 2004;12:99-110.
5. Lo IKY, Burkhart SS. Triple labral lesions: Pathology and surgical repair technique—report of seven cases. *Arthrosc J Arthrosc Relat Surg* 2005;21:186-193.
6. Ricchetti ET, Ciccotti MC, O'Brien DF, et al. Outcomes of arthroscopic repair of panlabral tears of the glenohumeral joint. *Am J Sports Med* 2012;40:2561-2568.
7. Tokish JM, McBratney CM, Solomon DJ, LeClere L, Dewing CB, Provencher MT. Arthroscopic repair of circumferential lesions of the glenoid labrum: Surgical technique. *J Bone Joint Surg Am* 2010;92:130-144 (suppl 1, pt 2).
8. Wilson MR, Field AC, Field LD. Arthroscopic 360° shoulder labral reconstruction: A stepwise approach. *Arthrosc Tech* 2018;7:e951-e956.
9. Rao AJ, Cvetanovich GL, Zuke WA, Low Q, Forsythe B. Arthroscopic repair of a circumferential 360° labral tear. *Arthrosc Tech* 2017;6:e1131-e1136.
10. Paxton ES, Backus J, Keener J, Brophy RH. Shoulder arthroscopy: Basic principles of positioning, anesthesia, and portal anatomy. *J Am Acad Orthop Surg* 2013;21:332-342.
11. Lim TK, Koh KH, Lee SH, et al. Inferior anchor cortical perforation with arthroscopic bankart repair: A cadaveric study. *Arthrosc J Arthrosc Relat Surg* 2013;29:31-36.
12. Laurencin CT, Deutsch A, O'Brien SJ, Altchek DW. The superolateral portal for arthroscopy of the shoulder. *Arthroscopy* 1994;10:255-258.