

The Stop and Press Technique; an Occlusion Free Stop-and-Chop Technique in Cataract Patients with Soft to Moderate Nuclei

Kazuki Matsuura ^{1,2}, Nao Takanashi²

¹Department of Ophthalmology, Nojima Hospital, Kurayoshi-city, Japan; ²Department of Ophthalmology and Visual Science, Tottori University, Yonago-city, Japan

Correspondence: Kazuki Matsuura, Nojima Hospital, 2714-1, Sesaki-machi, Kurayoshi-city, Tottori Prefecture, 6820863, Japan, Tel +81-858-22-6231, Fax +81-858-22-6843, Email matsuura.kzk@gmail.com

Abstract: The stop-and-chop technique, which involves occlusion and chopping using vacuum to stabilize the nucleus, is an excellent combination of the divide-and-conquer and phaco-chop techniques. However, effectively chopping an un-solid (soft to moderate) nucleus is not easy, since the optimal vacuum to hold an un-solid nucleus is often associated with breaking of occlusion and aspiration of the nucleus. We modified the stop-and-chop technique such that occlusion and tight nucleus holding using ultrasound (US) power is not necessary. After completing the central groove and cracking the nucleus into two hemi-sections, the right nucleus half is chopped without nucleus rotation and occlusion. The right hemi-nucleus is stabilized by pressing against the right sac with the US tip without occlusion. Since this technique can reduce the risk of nucleus perforation and posterior capsular rupture, the surgeons can place the US tip firmly in a deep position, which provide safe and efficient nucleus division.

Keywords: cataract surgery, divide-and-conquer technique, stop-and-chop technique, power free phacoemulsification, stop-and-press technique

Introduction

Several variations of phacoemulsification techniques have been described. Of these, the divide-and-conquer, stop-and-chop, and phaco-chop are the most popular techniques. In divide-and-conquer, ultrasound (US) power is used to produce a central groove. The nucleus is then divided into two hemi-sections by cracking. The hemi-sections are rotated 90° so that the two halves lie at the 6 and 12 o'clock positions. Next, another longitudinal groove is produced and the nucleus is divided into four quadrants by cracking. The US power required throughout the procedure tends to increase.¹

Compared to the divide-and-conquer, the use of a chopper decreases the US power required for sculpting the nucleus.² The nucleus is mechanically divided into small fragments with a chopper in the stop-and-chop and Nagahara's phaco-chop techniques. Both techniques involve occlusion using high vacuum to stabilize the nucleus.¹⁻³ The main difference between the phaco-chop and stop-and-chop techniques is the creation of a central groove at the start of the procedure. The stop-and-chop technique begins by creating a central groove. Next, the chopper is inserted into the groove and a horizontal movement is performed to crack the nucleus in half. The cracking procedure is then stopped and the US tip is impaled into one hemi-nucleus. The chopper is used to create two or more smaller fragments, which are then emulsified and aspirated. The initial central groove aids the surgeon to ensure the phaco tip reaches the correct depth to hold the nucleus.

The chopping technique is appropriate for moderate to hard nuclei. The hemi-section is embedded at mid-depth and chopped into two or more pieces while maintaining foot pedal position 2. Each piece is impaled, brought into the AC, and emulsified. In cases with solid nuclei, it is efficient to chop using occlusion because maintaining the occlusion is relatively easy.^{1,2} However, it can be technically difficult to achieve and sustain occlusion to hold an un-solid (soft to moderate) nucleus since the US tip tends to aspirate and perforate soft nuclear matter^{4,5} (Figure 1, [Supplementary Video 1](#)).

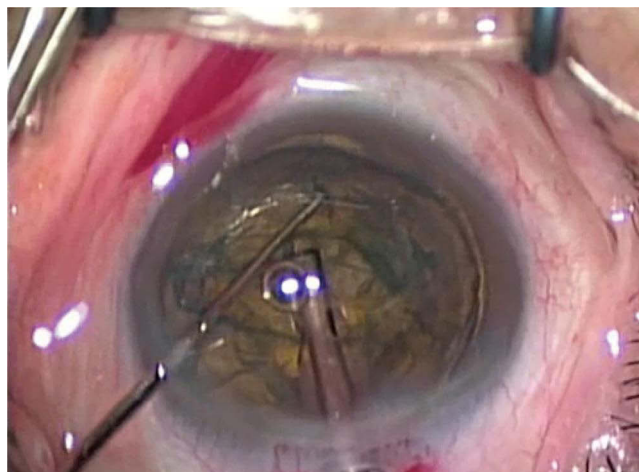


Figure 1 Technical difficulty in an ordinary Stop-and-Chop technique in a case with soft to moderate nucleus. After cracking the nucleus into two hemi-sections, the nucleus is rotated 90° clockwise. Then, the surgeon tried to hold the nucleus for chopping. However, effectively holding the nucleus using US power with an optimal vacuum is not easy.

We consider the stop-and-chop technique to be an excellent combination of the divide-and-conquer and Nagahara's phaco-chop techniques. We therefore modified the stop-and-chop technique to allow effective nuclear division even in cases with un-solid nuclei. The focus of this technique is to stabilize the nucleus and perform the chopping procedure without occlusion using US power.

Surgical Technique

Fundamental Technical Procedure: Un-Solid (Soft to Moderate) Nuclei

After completing the continuous circular capsulorhexis (CCC) and hydrodissection, the surgeon makes a central groove in the nucleus and cracks it into two hemi-sections (Figure 2A). Next, instead of proceeding to nucleus rotation and further grooving as in the conventional divide-and-conquer approach, chopping is performed on the right hemi-nucleus. A force is required to hold the nucleus, similar to a vise holding a piece of wood, while the right hemi-nucleus is chopped and split. The right hemi-nucleus is stabilized by gently pressing the right half against the right sac with the US tip and sleeve without occlusion using US power (Figure 2B).

The chopper is placed beyond the edge of the right nucleus through the CCC edge at the 9 o'clock position and moved horizontally from the nuclear periphery toward the US tip to split the nucleus. As a result, the right hemi-section is cut into two segments without occlusion and nucleus rotation (Figure 2C). After emulsifying and aspirating the right front (far) quarter segments (Figure 2D), the right rear (near) quarter can be easily brought into the anterior chamber (Figure 2E). The remaining left hemi-nucleus is then rotated 90° clockwise. Next, by gently pressing the US tip against the hemi-nucleus at 6 o'clock without occlusion, the nucleus is stabilized between the tip and capsule. Notably, the phaco tip does not impale the nucleus and the phaco tip is not occluded using US power; rather, the phaco tip only leans against the nucleus and presses it gently toward the 6 o'clock position. Without US power, there is no fear of nucleus perforation and posterior capsular rupture. Accordingly, the US tip can be placed firmly in a deep position. The chopper is placed beyond the edge of the nucleus through the CCC edge at the 6 o'clock position and horizontally moved from the nucleus periphery toward the phaco tip. The hemi-nucleus located at 6 o'clock is then cut into two or more segments, which are easily brought into the anterior chamber and phacoemulsified (Figure 2F, [Supplementary Video 2](#)).

In cases where chopping the first (right) hemi-nucleus at the 9 o'clock position is technically challenging, the nucleus can be rotated 90° counter-clockwise after fracture such that the two nucleus halves lie at 6 and 12 o'clock. When the first (6 o'clock) nucleus is chopped, occlusion is not necessary, and the phaco tip only leans against the nucleus and press it gently toward the 6 o'clock position.

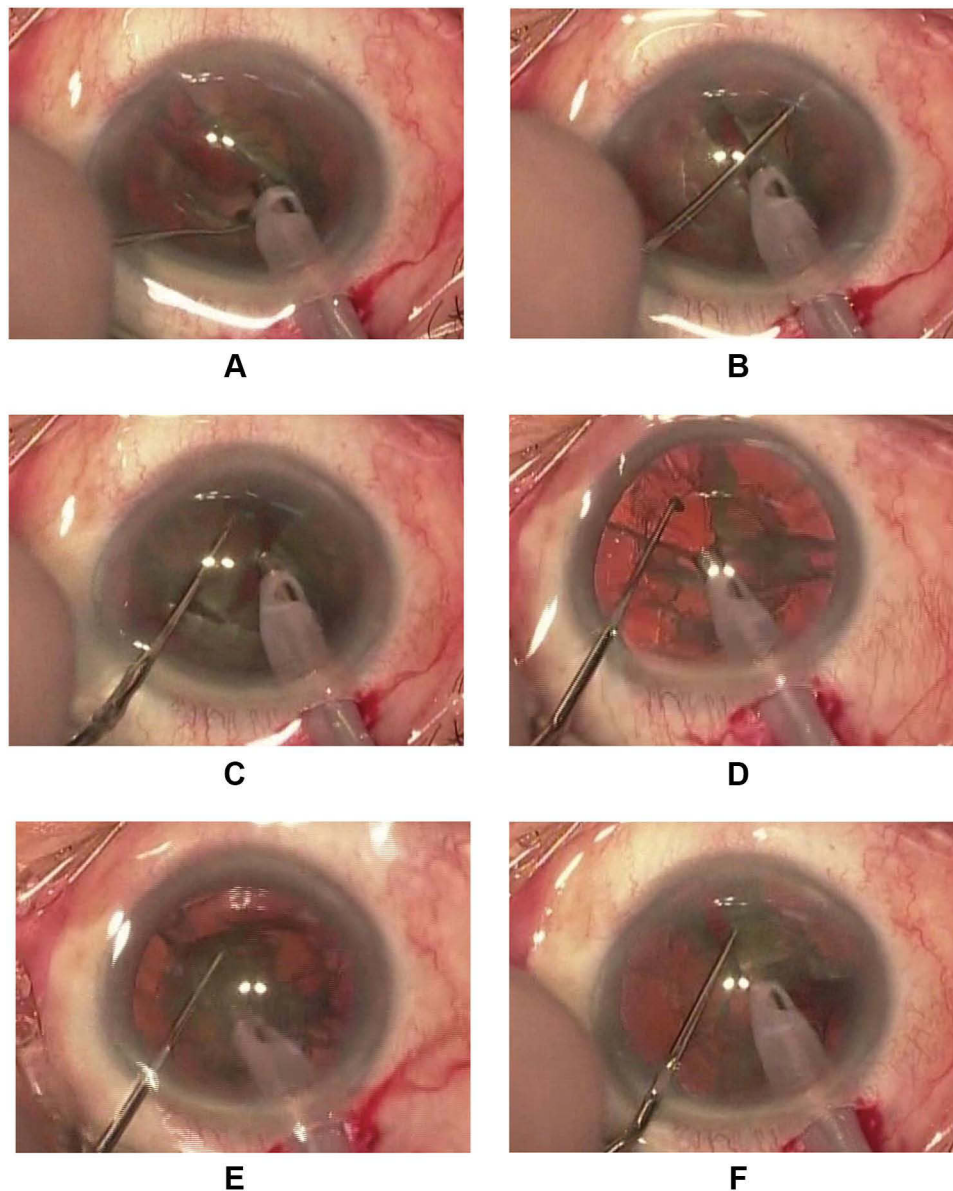


Figure 2 Stop-and-Press technique in a case with moderate nucleus. **(A)** A central groove is made in the nucleus. The nucleus is cracked into two hemi-sections as with the Stop & Chop technique. **(B)** The right hemi-nucleus is stabilized by gently pressing the right half against the right sac with the US tip and sleeve without occlusion using US power. **(C)** The chopper is placed beyond the edge of the right nucleus through the CCC edge at the 9 o'clock position and moved horizontally from the nuclear periphery toward the US tip to split the nucleus. The right nuclear half is chopped and split into 2 fragments without nucleus rotation. **(D)** The right front (far) quarter segment is brought into the anterior chamber and emulsified and aspirated. **(E)** The right rear (near) quarter can be easily brought into the anterior chamber. **(F)** The remaining left hemi-nucleus is rotated 90° degrees clockwise. The hemi-nucleus can be stabilized by gently pressing the nucleus against the lower sac with the US tip. The hemi-nucleus located in the 6 o'clock is cut into two or more segments. US power and occlusion are not necessary in this step either.

Discussion

Nagahara's phaco-chop technique can decrease US time and corneal endothelial cell loss compared to the stop-and-chop and divide-and-conquer techniques.⁶⁻⁹ For experienced surgeons, Nagahara's phaco-chop technique is simple and safe for any cataract cases. However, surgeons in training often experience difficulties in dealing with soft to moderate nuclei since occlusion breaks may occur more easily and stabilization of the nucleus can be technically challenging.

In addition, as the pieces are closely wedged together like a jigsaw puzzle in Nagahara's phaco-chop technique, it is sometimes difficult to extract nuclear pieces from the capsular bag into the anterior chamber. In contrast, in the stop-and-chop technique, longitudinal sculpting creates a space that facilitates subsequent nuclear manipulation. Yen et al reported

that the stop-and-chop technique is the second most common technique used to teach phacoemulsification.¹⁰ However, effectively chopping and splitting an un-solid nucleus is technically challenging as the optimal vacuum required to hold the un-solid nucleus is often associated with breaking of occlusion and aspiration of the nucleus. In most treatises and textbook descriptions, it is presumed that occlusion is essential for nucleus division with chopping. This blind brief makes soft to moderate nucleus division technically challenging for many surgeons. All that is required prior to chopping is to stabilize the nucleus, and occlusion using US power is not essential.

In Nagahara's phaco chop technique, the phaco tip impales the nucleus deeply using US power without central sculpting. The tip is kept occluded to hold the nucleus while maintaining foot pedal position 2. The chopper is pulled directly toward the phaco tip in the horizontal plane as in our occlusion-free-technique.

Yao et al described the efficacy of the power-free-chop technique, which is a modification of Nagahara's phaco-chop technique for soft to moderate nuclei.⁴ In their technique, central sculpting is not attempted and fragmentation using a chopper is completed without occlusion using US power. However, we believe that sculpting the nucleus is an important step of phacoemulsification as it allows better intraoperative assessment of the hardness and depth of the nucleus. Therefore, we developed the occlusion-free-chop technique, which was derived from modification of the stop-and-chop technique.

Very soft nuclei are associated with difficulty in nuclear fragmentation. Complete division of a very soft nucleus is not necessary, and the non-chopping technique is recommended for emulsification of very soft nuclei.¹¹⁻¹⁴ However, surgeons often experience technical difficulties when treating cataract cases with soft and un-solid nuclei that are not amenable to the non-chopping technique. Accordingly cataract cases that are not so soft - but also not really nuclear cataract cases - are often challenging.

The stop-and-press technique; our occlusion-free modified stop-and-chop technique has several advantages for nucleus fragmentation compared with the conventional technique.

First, our technique allows for safer and more effective nuclear fragmentation in cases with un-solid nuclei and does not increase the risk of surgical complications compared to the standard stop-and-chop technique. Without US power, the phaco tip will not penetrate the nucleus during the chopping process, thereby reducing the risk of posterior capsular rupture. In cases with soft nuclei, surgeons are cautious of penetrating the nucleus and causing posterior rupture, which can result in the phaco tip being embedded too superficially (ie, insufficiently deep) during the chopping procedure. This often leads to an undivided bowl of the nucleus (posterior plate), which makes safe emulsification technically challenging.

Second, the stop-and-press technique does not require occlusion in the nucleus with precise pedal control. This can eliminate difficulties related to the chopping procedure, especially for phaco beginners. As a result, the occlusion-free-chop technique is easier to learn than the ordinary stop-and-chop and phaco-chop techniques.

Third, US power and time are reduced compared to the divide-and-conquer and standard stop-and-chop techniques.

Conclusion

Our modified stop-and-chop technique has several advantages-especially in cases with a soft to moderate nucleus that are liable to collapse at the time of occlusion and chopping using US power. With nuclear fragmentation using the chopper, it is possible to stabilize an un-solid nucleus without occlusion using US power. The stability of an un-solid nucleus is more reliable without occlusion.

What is Known

The stop-and-chop technique, which involves occlusion and chopping using high a vacuum to stabilize the nucleus, is an excellent combination of the divide-and-conquer and Nagahara's phaco-chop techniques.

Compared to the divide-and-conquer technique, the use of a chopper decreases the use of US power to sculpt the nucleus. However, it can be difficult to achieve and maintain the occlusion to hold an un-solid (soft to moderate) nucleus because the US tip tends to aspirate and perforate soft nuclear matter.

What This Paper Adds

We modified the stop-and-chop technique such that occlusion and tight nucleus holding using US power are not necessary. The stability of an un-solid nucleus is more reliable without occlusion, thereby reducing the risk of posterior capsular rupture.

Using this technique, US power and time are saved compared to the divide-and-conquer and standard stop-and-chop techniques. Moreover, this technique can be easily mastered by beginners.

Abbreviations

US, ultrasound; CCC, continuous circular capsulorhexis.

Disclosure

The authors report no conflicts of interest in this work.

References

1. Coppola M, Marchese A, Rabiolo A, Cicinelli MV, Knutsson KA. Comparison of two popular nuclear disassembly techniques for cataract surgeons in training: divide and conquer versus stop and chop. *Int Ophthalmol*. 2019;39:2097–2102. doi:10.1007/s10792-018-1046-4
2. Can I, Takmaz T, Cakici F, Ozgöl M. Comparison of Nagahara phaco-chop and stop-and-chop phacoemulsification nucleotomy techniques. *J Cataract Refract Surg*. 2004;30:663–668. doi:10.1016/j.jcrs.2003.06.006
3. Koch PS, Katzen LE. Stop and chop phacoemulsification. *J Cataract Refract Surg*. 1994;20:566–570. doi:10.1016/S0886-3350(13)80239-8
4. Yao L, Bai H. Comparison of power-free-chop and phaco-chop techniques for moderate nuclei. *BMC Ophthalmol*. 2020;20:174. doi:10.1186/s12886-020-01455-4
5. Om Parkash R, Mahajan S, Om Parkash T, Vajpayee RB, Om Parkash T. A rapid technique for en masse soft cataract phacoemulsification. *Clin Ophthalmol*. 2019;13:755–762. doi:10.2147/OPHTH.S197359
6. Wong T, Hingorani M, Lee V. Phacoemulsification time and power requirements in phaco chop and divide and conquer nucleofractis techniques. *J Cataract Refract Surg*. 2000;26:1374–1378. doi:10.1016/S0886-3350(00)00538-1
7. Park J, Yum HR, Kim MS, Harrison AR, Kim EC. Comparison of phaco-chop, divide-and-conquer, and stop-and-chop phaco techniques in microincision coaxial cataract surgery. *J Cataract Refract Surg*. 2013;39:1463–1469. doi:10.1016/j.jcrs.2013.04.033
8. Vajpayee RB, Kumar A, Dada T, Titiyal JS, Sharma N, Dada VK. Phaco-chop versus stop-and-chop nucleotomy for phacoemulsification. *J Cataract Refract Surg*. 2000;26:1638–1641. doi:10.1016/S0886-3350(00)00544-7
9. Park JH, Lee SM, Kwon JW, et al. Ultrasound energy in phacoemulsification: a comparative analysis of phaco-chop and stop-and-chop techniques according to the degree of nuclear density. *Ophthalmic Surg Lasers Imaging*. 2010;41:236–241. doi:10.3928/15428877-20100303-13
10. Yen AJ, Ramanathan S. Advanced cataract learning experience in United States ophthalmology residency programs. *J Cataract Refract Surg*. 2017;43:1350–1355. doi:10.1016/j.jcrs.2017.10.014
11. Zeng M, Liu X, Zhang X, et al. A comparative study of non-chopping rotation and axial rotation versus quick chop phacoemulsification techniques. *Ophthalmic Surg Lasers Imaging*. 2009;40:222–231. doi:10.3928/15428877-20090430-01
12. Güell JL, Vázquez M, Lucena J, Velasco F, Manero F. Phaco rolling technique. *J Cataract Refract Surg*. 2004;30:2043–2045. doi:10.1016/j.jcrs.2004.05.005
13. Vasavada A, Singh R. Surgical techniques for difficult cataracts. *Curr Opin Ophthalmol*. 1999;10:46–52. doi:10.1097/00055735-199902000-00009
14. Gomas A, Liu C. Bowl-and-snail technique for soft cataract. *J Cataract Refract Surg*. 2011;37:8–10. doi:10.1016/j.jcrs.2010.10.027

Clinical Ophthalmology

Dovepress

Publish your work in this journal

Clinical Ophthalmology is an international, peer-reviewed journal covering all subspecialties within ophthalmology. Key topics include: Optometry; Visual science; Pharmacology and drug therapy in eye diseases; Basic Sciences; Primary and Secondary eye care; Patient Safety and Quality of Care Improvements. This journal is indexed on PubMed Central and CAS, and is the official journal of The Society of Clinical Ophthalmology (SCO). The manuscript management system is completely online and includes a very quick and fair peer-review system, which is all easy to use. Visit <http://www.dovepress.com/testimonials.php> to read real quotes from published authors.

Submit your manuscript here: <https://www.dovepress.com/clinical-ophthalmology-journal>