

ORIGINAL RESEARCH

Clipping versus coiling for the treatment of oculomotor nerve palsy induced by posterior communicating artery aneurysms: A comparison of effectiveness

Zidong Wang¹ | Xiaokui Kang¹ | Qingdong Wang² 

¹ Department of Neurosurgery, Liaocheng People's Hospital, Liaocheng, Shandong, P.R. China

² Department of Neurology, Liaocheng People's Hospital, Liaocheng, Shandong, P.R. China

Correspondence

Qingdong Wang, MD, Department of Neurology, Liaocheng People's Hospital, 67 Dongchang West Road, Liaocheng, Shandong 252000, P.R. China.

Email: wangqingdongdr@126.com

[Correction added on 30 August 2021, after first online publication: Peer review history statement has been added.]

Abstract

Background: A long debate has been going on in the clinical effectiveness to determine whether surgical clipping or coiling more favorable for oculomotor nerve palsy (ONP) caused by PcomAA. We aimed to perform a study, focusing on the effectiveness of ONP induced by PcomAA after treatment of surgical clipping and endovascular coiling.

Method: Potential studies were searched on PubMed, EMBASE, Web of Science, and Cochrane Library from database inception to February 2021, and STATA version 12.0 was exerted to process the pooled data.

Results: A total of 16 articles are included in the study, hailing from the United States, South Korea, the United Kingdom, France, Germany, Korea, China, Japan, Britain, and Singapore. The results showed that the clipping group was related to a higher incidence of complete ONP recovery at follow-up (OR = 5.808, 95% CI 2.87 to 11.76, $p < 0.001$), the lower rates of partial ONP recovery (OR = 0.264, 95% CI 0.173 to 0.402, $p < .001$) and no improvement of ONP at follow-up (RD = -0.149, 95% CI -0.247 to -0.051, $p = .003$). In the subgroup of complete ONP recovery based on the condition of patients, clipping was associated with a higher incidence of complete ONP recovery in patients with the incomplete initial ONP (OR = 3.579, $p = .020$) and ruptured aneurysm (OR = 5.38, $p = .020$). Regarding the subgroup of complete ONP recovery based on the quality of studies, similar results also appeared.

Conclusion: Surgical clipping was more favorable to the recovery from ONP caused by PcomAA endovascular coiling due to a higher rate of recovery and recovery degree of ONP. Besides that, more evidence-based performance is necessary to supplement this opinion.

KEYWORDS

clip, coil, oculomotor nerve palsy, posterior communicating artery aneurysms

Abbreviations: CIs, confidence intervals; non-RCTs, nonrandomized controlled trials; NOS, Newcastle–Ottawa scale; ONP, oculomotor nerve palsy; ORs, odds ratios; PcomAA, posterior communicating artery aneurysm; PRISMA, Preferred Reporting Items for Systematic Reviews and Meta-Analyses; RDs, rate differences

This is an open access article under the terms of the [Creative Commons Attribution](https://creativecommons.org/licenses/by/4.0/) License, which permits use, distribution and reproduction in any medium, provided the original work is properly cited.

© 2021 The Authors. *Brain and Behavior* published by Wiley Periodicals LLC

1 | INTRODUCTION

Posterior communicating artery aneurysm (PcomAA) ranked the second most common intracranial aneurysm, accounting for 25% of all cerebral aneurysms (Golshani et al., 2010). Oculomotor nerve palsy (ONP) was a pretty common complication of PcomAA; it was reported that ONP occurred in more than one-third of patients with PcomAA because of the adjacent anatomical relationships, pulsating effect from aneurysms, and direct nerve stimulation caused by subarachnoid hemorrhage (Giombini et al., 1991; Kh et al., 2010; Patel et al., 2014). It could be complete or incomplete and be related to ophthalmoplegia, diplopia, and ptosis (Gaberel et al., 2016). Recovery and the degree of recovery of ONP caused by PcomAA often showed a profound effect on the patient's physical health and quality of life. Surgical clipping and coiling were the two most common therapy for ONP caused by PcomAA. Clipping was a recommended treatment for ONP induced by PcomAA, which was a straightforward treatment by placing a metal clip at the lesion of the vessel and associated with good results in the majority of patients by achieving immediately relieves mass effect (Golshani et al., 2010; Lq & Qx, 2020). As the treatment of coiling, the spring-shaped coil was placed at the lesion of aneurysms by adopting a catheter via the groin artery (Lq & Qx, 2020). The endovascular treatment could remove aneurysmal pulsation and tended to promote the atrophy of aneurysm over time (Mc et al., 2008; Panagiotopoulos et al., 2011; Sh et al., 2010; Sz et al., 2010). Therefore, given that the controversy between the endovascular coiling and surgical clipping for ONP induced by PcomAA remained unresolved, we aimed to perform a study, focusing on the effectiveness of ONP induced by PcomAA after treatment of surgical clipping and endovascular coiling.

2 | METHODS

This review works fully followed the checklist of PRISMA (Preferred Reporting Items for Systematic Reviews and Meta-Analyses) (Wq et al., 2019).

2.1 | Ethical review

All analyses were conducted according to available published studies, thus no ethical approval or patient consent was required.

2.2 | Literature search

The analysis of all literature that compared surgical clipping with endovascular coiling for patients with ONP induced by PcomAA was searched by two authors through four medical publication databases, namely PubMed (up to October 2020; updated February 2021), Cochrane Central Register of Controlled Trials (up to October 2020; updated February 2021), EMBASE (up to October 2020; updated February 2021), and Web of Science (up to October 2020; updated

February 2021). The search strategy adopted both keywords and the MeSH term searches about "aneurysm," "clip," "oculomotor nerve palsy," and "coiling," which were also in combination with Boolean logic. Two authors conduct an initial search independently, and controversy was discussed and deal with by the third author. The search was limited to English-language articles, and a manual search of the reference lists of the included studies was performed as well.

2.3 | Selection criteria

Publications were selected on the basis of the PICOS criteria (population, intervention, comparison, outcome, and study design) as follows: (I) P: limited to participants with ONP induced by PcomAA; (II) I: adopted endovascular coiling or surgical clipping as the intervention; (III) C: the comparative studies between coiling and surgical clipping; (IV) O: Included one or more endpoints mentioned above; (V) S: randomized controlled trial (RCT) or non-RCT.

Conversely, the exclusion criteria were exhibited below: (I) studies without comparison between coiling and surgical clipping; (II) animal model and basic science studies; (III) conference, case reports or/and series, editorials, letters to the editor, systematic reviews.

2.4 | Data extraction

Two authors independently extracted the data, and a third author could join the process of in this part in case of discrepancy. The basic demographic information (the mean age, gender, study design, the number of patients) was extracted based on a preplanned form.

2.4.1 | The extracted outcomes included

Primary outcome measures: complete ONP recovery at follow-up, the subgroup of patients with good or nongood control of confounding factors, the subgroup of study based on NOS scores, the subgroup of patients with complete or incomplete initial ONP, and the subgroup of patients with the ruptured or unruptured aneurysm.

Secondary outcome measures: partial ONP recovery, no ONP improvement at follow-up, and postoperative complications.

2.5 | Statistical analysis

Our statistical analyses were conducted using STATA 12.0 software (Stata Corporation, College Station, TX, USA). The pooled odds ratios (ORs) or risk differences (RDs) and their corresponding 95% confidence intervals (CIs) were assessed using a fixed-effect model or random-effect model. Statistical heterogeneity was assessed using Cochran Q test and I^2 statistic, to evaluate the degree of inconsistency among all included studies. The $I^2 > 50%$ and $< 50%$ were considered to have significant heterogeneity or not, respectively. The random-effect model was adopted for variables with values of $I^2 > 50%$.

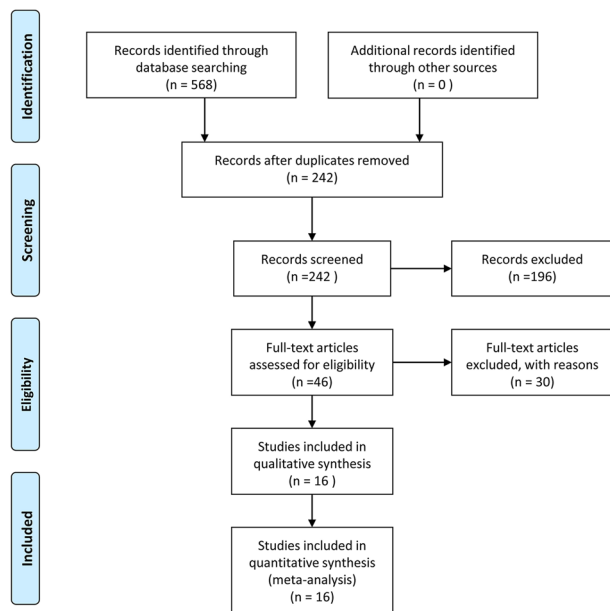


FIGURE 1 Flowchart of the study selection process

Otherwise, the fixed-effect model was used. Two-sided p values $< .05$ were regarded to have statistical significance.

3 | RESULTS

3.1 | Search results

In total, 568 publications were initially identified by searching the electronic database. Among the initial 568 candidate articles, 326 duplicates were removed. Following the first-round reviewing of titles and abstracts, 46 articles were eligible for second-round evaluation of full-text. Finally, 16 publications met predetermined eligibility criteria and were included in this meta-analysis. **Figure 1** revealed more details about the search process.

3.2 | Study characteristics

A total of 16 articles (Brigui et al., 2014; Engelhardt et al., 2015; Gao et al., 2017; Gresir et al., 2011; Hall et al., 2017; Jy et al., 2006; Kh et al., 2010; Liu et al., 2020; Lq & Qx, 2020; Patel et al., 2014; Pr et al., 2006; Sa et al., 2013; Signorelli et al., 2020; Skd et al., 2018; Tan et al., 2015; Yanaka et al., 2003) are included in the study, hailing from the United States, South Korea, the United Kingdom, France, Germany, Korea, China, Japan, Britain, and Singapore. The 16 studies with a total of 687 patients that underwent clipping or coiling and reported the complete ONP recovery as the primary outcome were included in this pooled analysis. Of these 687 patients with ONP induced by PcomAA, there were 279 patients from the surgical clipping group versus 408 patients from the endovascular coiling group. At the same time, all 16 articles were single-center, retrospective studies. More details are shown in **Table 1**.

3.3 | Methodological quality

The methodological quality of included studies was evaluated independently by two authors through the Newcastle–Ottawa Quality Assessment Scale (NOS) for nonrandomized controlled trials (non-RCTs). Briefly, a maximum of 9 points was assigned to each study: 4 for selection, 2 for comparability, and 3 for outcomes. Studies with scores of 7 or more were defined as high methodological quality. Those with scores of 6 or less were defined as poor quality.

Meanwhile, we also used a specific quality aspect to assess the studies such as control of confounding factors according to six criteria, including the items of age, cases with complete initial ONP, the period between ONP onset and therapy, patients with ruptured aneurysm before treatment, size of the aneurysm, and follow-up period. Studies with scores of 5 or more of control of confounding factors were defined as good. Those with scores of 3 to 4 were defined as an adequate control. The specific score for each study was shown in **Table 2**.

4 | OUTCOMES

4.1 | Complete ONP recovery at follow-up

Complete ONP recovery was reported in 15 of the 16 included studies comprising 632 (91.85%) of 687 patients. 384 (60.76%) of the 632 patients received clipping, of which 248 (39.24%) patients received coiling. The total complete ONP recovery rate was 68.5% (433 of 632 patients) at follow-up. A random-effects model was used to assess it owing to the significant heterogeneity ($p = .006$, $I^2 = 54.5%$). The pooled evaluation of the overall proportions demonstrated a significantly higher rate of complete ONP recovery that appeared in the clipping group (OR = 5.808, 95%CI 2.87 to 11.76, $p < .001$, **Figure 2**).

4.2 | Partial ONP recovery

We adopted meta-analytical techniques to assess the incidence of postoperative partial ONP recovery. Reviewing the data of the included studies, 13 articles (368 in clipping and 227 in coiling) reported on the partial ONP recovery. We selected the fixed effects model because the heterogeneity was not significantly different ($p = .084$, $I^2 = 37.4%$). The coiling group was related to a higher incidence of partial ONP recovery (OR = 0.264, 95% CI 0.173 to 0.402, $p < .001$, **Figure 3**).

4.3 | No ONP improvement at follow-up

Twelve publications (358 in endoscopic, 227 in clipping) reported no ONP improvement. A random-effects model was used to assess it due to the significant heterogeneity ($p = .003$, $I^2 = 61.7%$). The pooled evaluation of the overall proportions demonstrated a significantly higher rate of no ONP improvement appeared in the coiling group (RD = -0.149 , 95% CI -0.247 to -0.051 , $p = .003$, **Figure 4**).

TABLE 1 Characteristics of publication year, country, study type, cases, and gender in each group for included studies

Author	Country	Type of study	Sample Size (n)		Gender (F/M)		Age (mean ± standard)		NOS
			Clip	Coil	Male	Female	Clip	Coil	
Ahn et al. 2016	South Korea	Retrospective	7	10	0	17	52.6 years	52.6 years	7
Brigui et al. 2014	France	Retrospective	7	13	5	15	60.7 years	49 years	8
Chen et al. 2006	USA	Retrospective	7	6	1	12	53.8 years	57.3 years	7
Engelhardt et al. 2015	France	Retrospective	9	14	4	19	49.5 years	46.6 years	8
Guresir et al. 2011	Germany	Retrospective	4	7	ND	ND	ND	ND	6
Khan et al. 2013	USA	Retrospective	8	9	1	16	48.14 years	55.87 years	8
Nam et al. 2010	Korea	Retrospective	8	6	1	13	ND	ND	7
Patel et al. 2013	UK	Retrospective	9	9	3	15	52.3 years	67.6 years	7
Tan et al. 2015	China	Retrospective	132	43	80	95	51.73 years	54.65 years	8
Yanaka et al. 2003	Japan	Retrospective	11	1	1	11	60.4 years	60.4 years	5
Tian et al. 2020	China	Retrospective	31	39	35	35	60	75	8
Gao et al. 2017	China	Retrospective	23	29	8	44	53.9 ± 11.5	54.1 ± 10.0	7
Hall et al. 2017	Britain	Retrospective	93	86	29	124	54.1 (23–86)	58.0 (25–82)	6
Liu et al. 2020	China	Retrospective	40	112	82	70	55.6 ± 7.9	56.2 ± 8.2	7
Signorelli et al. 2020	France	Retrospective	24	31	22	33	ND	ND	7
Mak et al. 2018	Singapore	Retrospective	11	11	16	6	57.9	59.6	8

ND = not discussed; F = female; M = male; NOS = Newcastle–Ottawa scale.

TABLE 2 The literature quality assessment

Author, year	Design	Newcastle–Ottawa scale (NOS)				Control of confounding factors
		Selection	Comparability	Exposure	Total scores	
Ahn et al. 2016	Non-RCT	3	1	3	7	Adequate (4/6)
Brigui et al. 2014	Non-RCT	4	2	2	8	Good (5/6)
Chen et al. 2006	Non-RCT	3	2	2	7	Adequate (4/6)
Engelhardt et al. 2015	Non-RCT	4	2	2	8	Good (6/6)
Guresir et al. 2011	Non-RCT	3	1	2	6	Adequate (3/6)
Khan et al. 2013	Non-RCT	3	2	3	8	Good (6/6)
Nam et al. 2010	Non-RCT	3	1	3	7	Good (5/6)
Patel et al. 2013	Non-RCT	3	2	2	7	Good (5/6)
Tan et al. 2015	Non-RCT	3	2	3	8	Good (5/6)
Yanaka et al. 2003	Non-RCT	2	1	2	5	Adequate (3/6)
Tian et al. 2020	Non-RCT	3	2	3	8	Good (5/6)
Gao et al. 2017	Non-RCT	3	2	2	7	Good (5/6)
Hall et al. 2017	Non-RCT	3	1	2	6	Adequate (4/6)
Liu et al. 2020	Non-RCT	4	1	2	7	Good (5/6)
Signorelli et al. 2020	Non-RCT	3	2	2	7	Good (5/6)
Mak et al. 2018	Non-RCT	3	2	3	8	Good (5/6)

NOS = Newcastle–Ottawa scale; RCT = randomized controlled trials.

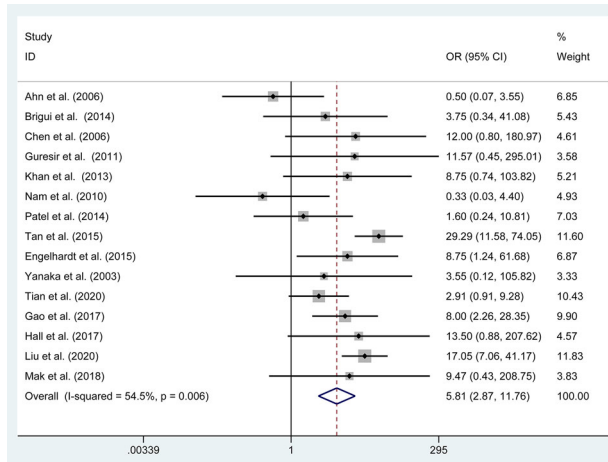


FIGURE 2 Forest plot of the odds ratio of the complete oculomotor nerve palsy recovery

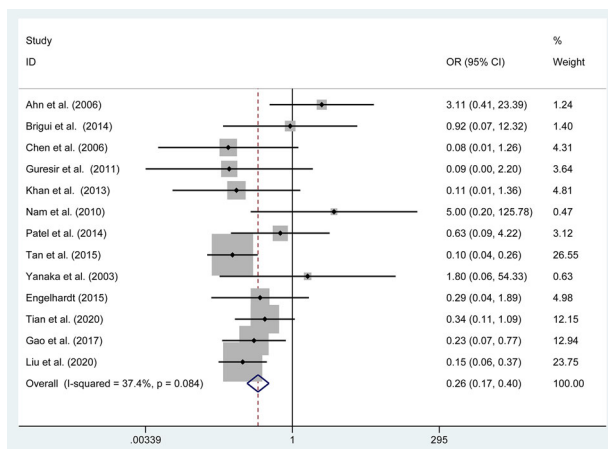


FIGURE 3 Forest plot of the odds ratio of the partial oculomotor nerve palsy recovery

4.4 | Postoperative complications

Eight studies reported on complications. No significant heterogeneity was found, then the fixed effects model was selected ($p = .368$, $I^2 = 8\%$). We revealed the endoscopic treatment was not related to a lower rate of complications than the clipping group (RD = -0.070 , 95% CI -0.146 to 0.006 , $p = .071$).

4.5 | Subgroups of complete ONP recovery based on the condition of patients

4.5.1 | Patients with ruptured or unruptured aneurysm

The pooled estimates of the overall proportions showed no significant difference in the incidence of complete ONP recovery in patients with unruptured aneurysm (OR = 0.950 , 95% CI 0.506 to 1.783 , $p = .872$); however, a significant difference was revealed in the complete ONP

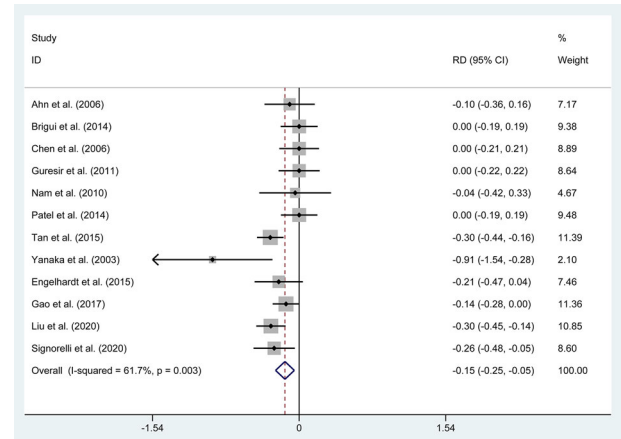


FIGURE 4 Forest plot of the rate differences of no oculomotor nerve palsy improvement

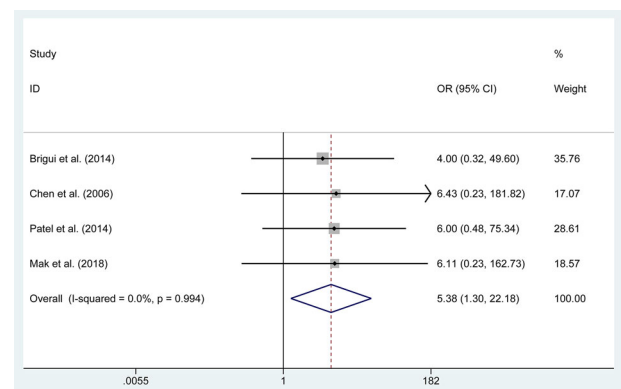


FIGURE 5 Forest plot of the odds ratio of the complete oculomotor nerve palsy recovery in patients with a ruptured aneurysm recovery in patients with ruptured aneurysm (OR = 5.38 , 95% CI 1.304 to 22.181 , $p = .020$, Figure 5).

4.5.2 | Patients with complete or incomplete initial ONP

The pooled estimates of the overall proportions showed no significant difference in the incidence of complete ONP recovery in patients with the incomplete initial ONP (RD = 0.266 , 95% CI -0.12 to 0.450 , $p = .266$); however, a significant difference was revealed in the complete ONP recovery in patients with the complete initial ONP (OR = 3.579 , 95% CI 1.632 to 7.851 , $p = .020$, Figure 6)

4.6 | Subgroups of complete ONP recovery based on the quality of studies

4.6.1 | Studies with good or nongood control of confounding factors

A significant difference was revealed in the complete ONP recovery in studies with the good (OR = 6.565 , $p < .001$) and nongood control of confounding factors (OR = 3.254 , $p = .028$)

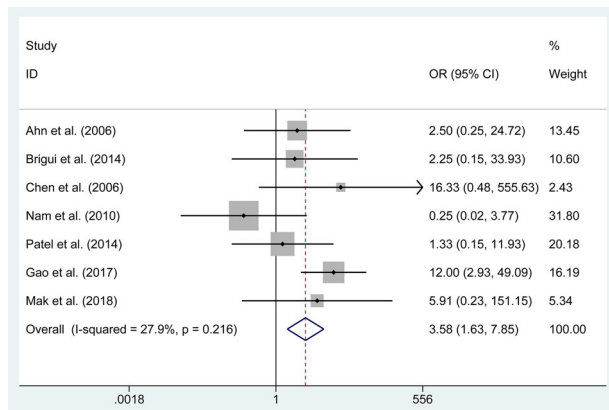


FIGURE 6 Forest plot of the odds ratio of the complete oculomotor nerve palsy recovery in patients with complete initial ONP

4.6.2 | Studies with good or poor quality based on NOS

A significant difference was revealed in the complete ONP recovery in studies with the good (OR = 5.371, $p < .001$) and poor (OR = 8.730, $p = .017$) quality based on NOS. More details about the results are shown in Table 3.

5 | DISCUSSION

Although ONP is a common clinical complication of PcomAA, the mechanism between PcomAA and ONP remains unknown (Gao et al., 2017). The differences in the incidence of recovery of ONP induced by PcomAA according to various methods of therapy increase the contro-

versy about OPN's pathogenesis. Previously, it seems that the ONP is induced by direct anatomical compression of PcomAA, which can result in a nerve distortion and impairment of circulation of blood vessels (Stiebel-Kalish et al., 2003). Currently, the aneurysmal pulsations are also regarded as a mechanism for the ONP induced by PcomAA (Hall et al., 2017).

In the wider controversy on the relative their own pros and cons of clipping and coiling treatment for intracranial aneurysms, there was a more violent debate about whether the clipping or coiling was better for treating ONP caused by PcomAA (Zheng et al., 2017). Although the clipping was associated with a larger trauma compared to coiling (Gaberel et al., 2016), it could directly decline compression of aneurysms to ONP, suppress rebleeding of a lesion, promote the recovery of ONP. In addition, theoretically, endovascular intervention could promote the recovery of ONP by reducing the pulsation of the aneurysm. Because the thrombosis formation in the lesion and contraction of the vessel wall could reduce the pulsation (Brigui et al., 2014). In this study, we performed a meta-analysis to evaluate whether there was an advantage in terms of ONP caused by PcomAA between surgical method and endovascular coiling.

A systematic review conducted by Guresir et al. (2011) gathered a total of 26 studies and analyzed their findings to found the rate of complete recovery of ONP was 55% and 32% in the surgical and coiling groups respectively. Chen et al. (2006) also demonstrated a significant increment in the rate of complete ONP recovery after the surgical (6/7) method compared to endovascular intervention (2/6). First, we also analyzed the rates of recovery of ONP caused by PcomAA after the treatment of clipping and coiling respectively, and it was divided into complete ONP recovery at follow-up, partial ONP recovery at follow-up, and no ONP improvement at follow-up. We

TABLE 3 The postoperative outcomes of this meta-analysis

Outcomes	Studies numbers	Group's size		Overall effect			Heterogeneity	
		Clipping	Coiling	Effect estimates	95% CIs	p Value	I ² (%)	p Value
Comparison of two interventions for oculomotor nerve palsy induced by posterior communicating artery aneurysms								
Complete ONP recovery	15	384	248	OR (5.808)	2.869 to 11.759	<.001	54.5%	.006
Partial ONP recovery	13	368	227	OR (0.264)	0.173 to 0.402	<.001	37.4%	.084
Postoperative complications	8	363	227	RD (-0.070)	-0.146 to 0.006	.071	8%	.368
No ONP improvement	12	358	227	RD (-0.149)	-0.247 to -0.051	.003	61.7%	.003
Subgroups of complete ONP recovery based on the condition of patients								
Ruptured aneurysm	4	22	24	OR (5.379)	1.304 to 22.181	.020	0.0%	.994
Unruptured aneurysm	10	97	112	OR (0.950)	0.506 to 1.783	.872	12.2%	.331
Complete initial ONP	7	52	61	OR (3.579)	1.632 to 7.851	.001	27.9%	.216
Incomplete initial ONP	7	19	23	RD (0.163)	-0.124 to 0.450	.266	0.0%	.901
Subgroups of complete ONP recovery based on the methodological quality of studies								
Good control of factors	10	350	214	OR (6.565)	2.989 to 14.422	<.001	59.3%	.009
Nongood control of factors	5	34	34	OR (3.254)	1.137 to 9.318	.028	33.7%	.197
Good quality based on NOS	12	364	230	OR (5.371)	2.412 to 11.956	<.001	63.8%	.001
Poor quality based on NOS	3	20	18	OR (8.730)	1.469 to 51.883	.017	0.0%	.820

CI = confidence intervals; RD = rate difference; OR = odds ratio; ONP = oculomotor nerve palsy; NOS = Newcastle-Ottawa scale. The bold values represent $P < 0.05$.

demonstrated that the clipping group was related to a higher incidence of complete ONP recovery at follow-up (OR = 5.808, 95% CI 2.87 to 11.76, $p < .001$), the lower rates of partial ONP recovery at follow-up (OR = 0.264, 95%CI 0.173 to 0.402, $p < .001$), and no ONP improvement at follow-up (RD = -0.149, 95% CI -0.247 to -0.051, $p = .003$).

Meanwhile, we conducted the subgroups of complete ONP recovery according to the condition of patients and the quality of studies. In the subgroup of patients with ruptured or unruptured aneurysms, a significant difference was revealed in the rate of complete ONP recovery in patients with ruptured aneurysms (OR = 5.38, $p = .020$). Similarly, in the subgroup of patients with the complete or incomplete initial ONP, the treatment of clipping was associated with a higher incidence of complete ONP recovery in patients with the incomplete initial ONP (OR = 3.579, $p = .020$). Besides that, in the subgroups of studies with good or nongood control of confounding factors, the clipping group also was related to a higher rate of the complete ONP recovery in studies with the good ($p < .001$) and nongood control of confounding factors ($p = .028$). Similar results also appeared in the subgroup of studies with good or poor quality based on NOS ($p < .05$).

In this study, the overall rates of the complete ONP recovery are 85.42% and 42.34% in the clipping and coiling group respectively. With regard to the reason for the higher rates of complete ONP recovery in the clipping group, we have a couple of guesses. First, although the surgical method and coiling could decline blood flow and then reduce the pulsation of the aneurysm, clipping could directly prevent the decompression of the aneurysm to the oculomotor nerve. Meanwhile, an aneurysm can have a temporary expansion after the treatment of endovascular intervention because of the formation of thrombosis in the cavity of the aneurysm, and the temporary expansion of aneurysm could lead to a direct decompression on the oculomotor nerve. Although the expanded aneurysm was not eliminated after the treatment of coiling, the OPN could also be solved in some patients. That is to say, coiling could promote the recovery of OPN mainly by reducing pulsation of the aneurysm, which stemming from aneurysmal shrinkage and fibrosis induced by the formation of thrombosis. Finally, in patients with a ruptured aneurysm, clipping could remove the intracranial hematoma directly and rinse the blood on the surface of the vessel, then prevent the stimulation of blood on the oculomotor nerve, while blood could only be absorbed by itself in patients receiving coiling (Liu et al., 2020).

Several limitations should be noted in this meta-analysis. First, the present analysis is mainly limited by the poor quality of the retrospective and small studies, which prevents from drawing definitive conclusions. Second, it is important to take into account the heterogeneity of the patient population studied when interpreting the results of a meta-analysis, but this meta-analysis is of the high heterogeneity of the statistical results. Finally, the follow-up of included studies is not the same. Therefore, although many meaningful conclusions could be revealed about the trends in the recovery of ONP, further high-quality studies are necessary to determine which procedure is optimal for treating ONP caused by PcomAA.

6 | CONCLUSION

Surgical clipping was more favorable to the recovery from ONP caused by PcomAA endovascular coiling due to a higher rate of recovery and recovery degree of ONP. Besides that, more evidence-based performance is needed to supplement this opinion.

PEER REVIEW

The peer review history for this article is available at <https://publons.com/publon/10.1002/brb3.2263>.

AVAILABILITY OF DATA AND MATERIALS

The datasets used and/or analyzed during this study are available from the corresponding author upon reasonable request.

COMPETING INTERESTS

The authors declare that they have no competing interests.

ORCID

Qingdong Wang  <https://orcid.org/0000-0001-6175-7558>

REFERENCES

- Golshani, K., Ferrell, A., Zomorodi, A., Smith, T. P., & Britz, G. W. (2010). A review of the management of posterior communicating artery aneurysms in the modern era. *Surgical Neurology International*, 1, 88
- Patel, K., Guilfoyle, M. R., Bulters, D. O. et al. (2014). Recovery of oculomotor nerve palsy secondary to posterior communicating artery aneurysms. *British Journal of Neurosurgery*, 28(4), 483–487 <https://doi.org/10.3109/02688697.2013.857007>
- Giombini, S., Ferraresi, S., & Pluchino, F. (1991). Reversal of oculomotor disorders after intracranial aneurysm surgery. *Acta Neurochirurgica*, 112, 19–24 <https://doi.org/10.1007/BF01402449>
- Nam, K. H., Choi, C. H., Lee, J. I., Ko, J. G., Lee, T. H., & Lee, S. W. (2010). Unruptured intracranial aneurysms with oculomotor nerve palsy: Clinical outcome between surgical clipping and coil embolization. *Journal of Korean Neurosurgical Society*, 48(2), 109–114
- Gaberel, T., Borha, A., Di Palma, C., & Emery, E. (2016). Clipping versus coiling in the management of posterior communicating artery aneurysms with third nerve palsy: A systematic review and meta-analysis. *World Neurosurgery*, 87, 498–506.e4.e494 <https://doi.org/10.1016/j.wneu.2015.09.026>
- Tian, L. Q., & Fu, Q. X. (2020). Recovery of posterior communicating artery aneurysm induced oculomotor nerve palsy: A comparison between surgical clipping and endovascular embolization. *BMC Neurology*, 20(1), 351
- Kassis SZ, Jouanneau, E., Fb T., Salkine, F., Perrin, G., & Turjman, F. (2010). Recovery of third nerve palsy after endovascular treatment of posterior communicating artery aneurysms. *World Neurosurgery*, 73(1), 11–16; discussion e12
- Zhang, S. H., Pei, W., Cai, X. S., & Cheng, G. (2010). Endovascular management and recovery from oculomotor nerve palsy associated with aneurysms of the posterior communicating artery. *World Neurosurgery*, 74, 316–319
- Panagiotopoulos, V., Ladd SC, Gizewski, E. et al. (2011). Recovery of ophthalmoplegia after endovascular treatment of intracranial aneurysms. *American Journal of Neuroradiology*, 32(2), 276–282 <https://doi.org/10.3174/ajnr.A2281>
- Hanse, M. C., Gerrits, M. C., Van Rooij, W. J., Houben, M. P., Nijssen, P. C., & Sluzewski, M. (2008). Recovery of posterior communicating artery aneurysm-induced oculomotor palsy after coiling. *American Journal of Neuroradiology*, 29(5), 988–990

- Xin WQ, Xin, Q. Q., & Yang XY. (2019). Meta-analysis of clipping versus coiling for the treatment of unruptured middle cerebral artery aneurysms: Direct comparison of procedure-related complications. *Neuropsychiatric Disease and Treatment*, 15, 3387–3395
- Gao, G., Gu DQ, Zhang, Y. et al. (2017). Comparison of the efficacy of surgical clipping and embolization for oculomotor nerve palsy due to a posterior communicating artery aneurysm. *European Review for Medical and Pharmacological Sciences*, 21(2), 292–296
- Hall, S., Sadek, A. R., Dando, A. et al. (2017). The resolution of oculomotor nerve palsy caused by unruptured posterior communicating artery aneurysms: A cohort study and narrative review. *World Neurosurgery*, 107, 581–587 <https://doi.org/10.1016/j.wneu.2017.07.123>
- Liu, J., Peng, C., Zhu, G. et al. (2020). Comparison of surgical clipping and endovascular coiling in the treatment of oculomotor nerve palsy caused by posterior communicating artery aneurysm. *Medicine*, 99(47), e22969 <https://doi.org/10.1097/MD.00000000000022969>
- Signorelli, F., Pop, R., Ganau, M. et al. (2020). Endovascular versus surgical treatment for improvement of oculomotor nerve palsy caused by unruptured posterior communicating artery aneurysms. *Journal of Neurointerventional Surgery*, 12(10), 964–967 <https://doi.org/10.1136/neurintsurg-2020-015802>
- Ahn, J. Y., Han, I. B., Yoon, P. H. et al. (2006). Clipping vs coiling of posterior communicating artery aneurysms with third nerve palsy. *Neurology*, 66(1), 121–123
- Brigui, M., Chauvet, D., Clarençon, F. et al. (2014). Recovery from oculomotor nerve palsy due to posterior communicating artery aneurysms: Results after clipping versus coiling in a single-center series. *Acta Neurochirurgica*, 156(5), 879–884
- Chen, P. R., Amin-Hanjani, S., Albuquerque, F. C., McDougall, C., Zabramski JM, & Spetzler, R. F. (2006). Outcome of oculomotor nerve palsy from posterior communicating artery aneurysms: Comparison of clipping and coiling. *Neurosurgery*, 58(6), 1040–1046; discussion 1040–1046
- Engelhardt, J., Berge, J., Cuny, E., & Penchet, G. (2015). Oculomotor nerve palsy induced by internal carotid artery aneurysm: Prognostic factors for recovery. *Acta Neurochirurgica*, 157(7), 1103–1111 <https://doi.org/10.1007/s00701-015-2440-6>
- Güresir, E., Schuss, P., Setzer, M., Platz, J., Seifert, V., & Vatter, H. (2011). Posterior communicating artery aneurysm-related oculomotor nerve palsy: Influence of surgical and endovascular treatment on recovery: Single-center series and systematic review. *Neurosurgery*, 68(6), 1527–1534; discussion 1533–1524 <https://doi.org/10.1227/NEU.0b013e31820edd82>
- Khan, S. A., Agrawal, A., Hailey, C. E. et al. (2013). Effect of surgical clipping versus endovascular coiling on recovery from oculomotor nerve palsy in patients with posterior communicating artery aneurysms: A retrospective comparative study and meta-analysis. *Asian Journal of Neurosurgery*, 8(3), 117–124
- Tan, H., Huang, G., Zhang, T., Liu, J., Li, Z., & Wang, Z. (2015). A retrospective comparison of the influence of surgical clipping and endovascular embolization on recovery of oculomotor nerve palsy in patients with posterior communicating artery aneurysms. *Neurosurgery*, 76(6), 687–694; discussion 694 <https://doi.org/10.1227/NEU.0000000000000703>
- Yanaka, K., Matsumaru, Y., Mashiko, R., Hyodo, A., Sugimoto, K., & Nose, T. (2003). Small unruptured cerebral aneurysms presenting with oculomotor nerve palsy. *Neurosurgery*, 52(3), 553–557; discussion 556–557 <https://doi.org/10.1227/01.NEU.0000047816.02757.39>
- Mak, S. K. D., Qiu, L., & Ng, Y. P. (2018). Recovery of oculomotor nerve palsy after endovascular and surgical treatment of posterior communicating artery aneurysms: A single institutional experience. *Asian Journal of Neurosurgery*, 13(3), 555–559
- Stiebel-Kalish, H., Maimon, S., Amsalem, J., Erlich, R., Kalish, Y., & Rappaport, H. Z. (2003). Evolution of oculomotor nerve paresis after endovascular coiling of posterior communicating artery aneurysms: A neuro-ophthalmological perspective. *Neurosurgery*, 53(6), 1268–1274; discussion 1273–1264 <https://doi.org/10.1227/01.NEU.0000093495.70639.AE>
- Zheng, F., Dong, Y., Xia, P. et al. (2017). Is clipping better than coiling in the treatment of patients with oculomotor nerve palsies induced by posterior communicating artery aneurysms? A systematic review and meta-analysis. *Clinical Neurology and Neurosurgery*, 153, 20–26 <https://doi.org/10.1016/j.clineuro.2016.11.022>

How to cite this article: Wang, Z., Kang, X., & Wang, Q. (2021). Clipping versus coiling for the treatment of oculomotor nerve palsy induced by posterior communicating artery aneurysms: A comparison of effectiveness. *Brain and Behavior*, 11, e2263. <https://doi.org/10.1002/brb3.2263>