

He was referred to haematology for treatment and following cycle 4 of chemotherapy, a follow up Computed Tomography scan of his Chest, Abdomen and Pelvis showed a significant reduction in size of the Primary Pancreatic Lymphoma.

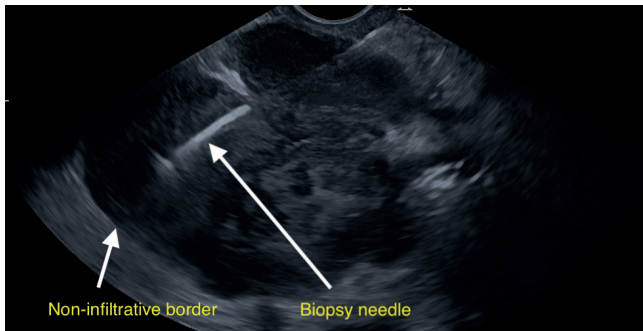


Figure 2

DISCUSSION

Primary Pancreatic Lymphoma (PPL) is a rare subtype of primary pancreatic malignancy, consisting of <0.5% of all pancreatic cancers, usually found in males aged 35-75.^{1,2}

The diagnostic criteria for PPL are:

- 1) Neither superficial lymphadenopathy nor enlargement of mediastinal lymph nodes on chest radiography.
- 2) Normal leucocyte count in peripheral blood.
- 3) Main mass in the pancreas with lymph-nodal involvement confined to the peri-pancreatic region.
- 4) No hepatic or splenic involvement.³

They present in similar ways to the head of pancreas adenocarcinoma, with symptoms such as jaundice, pancreatitis, abdominal pain, abdominal mass and diarrhoea, though rarely have typical B-symptoms of Non-Hodgkin's Lymphoma such as night sweats or fevers.²

Serum tumour markers are not particularly useful in PPL as they are not always raised, and CT scan can confirm presence of distal node involvement therefore pointing away from a PPL.

Endoscopic ultrasound (EUS) combined with fine needle biopsy (FNB) improves diagnostic accuracy on top of an FNA alone.² EUS is less invasive and can characterise the lesions present. Once a FNB has been obtained from EUS, it will be sent for Flow Cytometry (FC) and immunohistochemistry in order to aid diagnosis and treatment.

The treatment for PPL is cycles of chemotherapy under the guidance of a haematologist, without evidence for surgical resection.⁴

The prognosis for PPL is much better than that for pancreatic adenocarcinoma. A case series from 2005 showed a mean survival rate of 69-80 months for patients who received chemotherapy as a first line treatment for PPL.⁵

CONCLUSION

As shown in this case, histological sampling of a pancreatic mass must always be made given the difference in treatment and prognosis between adenocarcinoma and PPL. Given the small amount of tissue involved, samples should be sent for immunohistochemistry and flow cytometry to aid diagnosis and treatment.

Dr. Darragh McCullagh LAT4 Gastroenterology Craigavon Area Hospital, Dr. Andrew McNeice ST6 Gastroenterology Mater Infirmorum Hospital, Dr. Paul Rice Consultant Radiologist Craigavon Area Hospital, Dr. Inder Mainie Consultant Gastroenterologist Belfast City Hospital.

Correspondence to: Dr Darragh McCullagh

E-mail: dmccullagh05@qub.ac.uk

REFERENCES

1. Baylor SM, Berg JW. Cross-classification and survival characteristics of 5,000 cases of cancer of the pancreas. *J Surg Oncol.* 1973; 5(4) 335-58.
2. Nayer H, Weir EG, Sheth S, Ali SZ. Primary pancreatic lymphomas; a cytopathologic analysis of a rare malignancy. *Cancer.* 2004; 102(5):315-21.
3. Dawson IM, Cornes JS, Morson BC. Primary malignant lymphoid tumours of the intestinal tract. Report of 37 cases with a study of factors influencing prognosis. *Br J Surg.* 1961; 4:80-9.
4. Grimison P, Chin MT, Harrison ML, Goldstein D. Primary pancreatic lymphoma – pancreatic tumours that are potentially curable without resection, a retrospective review of four cases. *BMC Cancer.* 2006; 6: 117.
5. Arcari A, Anselmi E, Bernuzzi P, Berta R, Lazzaro A, Moroni CF, et al. Primary pancreatic Lymphoma. A report of five cases. *Haematologica.* 2005; 90(1): ECR09.

FEASIBILITY OF COLOUR DOPPLER ULTRASOUND FOR DETECTION OF INTRAARTICULAR SACROILIAC JOINT INJECTION: A CASE SERIES.

Editor,

We would like to share our experience of colour Doppler ultrasound (CDU) in the detection of correct needle placement for sacroiliac joint (SIJ) injection during interventional procedures for management of low back pain (LBP).

Injection of steroid mixed with local anaesthetic (LA) is a well-recognised method for both diagnostic and therapeutic management of SIJ pain. Several imaging modalities have been used to guide such interventions in SIJ.¹ Fluoroscopic guidance is still considered as gold standard to confirm needle placement and spread of the dye. The majority of such imaging techniques involve use of ionising radiation. Ultrasound is however being used increasingly.² In many interventional pain procedures it is replacing ionising modalities because of the portability allowing the procedure to be performed at bedside without such hazards.³ However, ultrasound has a potential limitation in viewing the needle trajectory and the spread of the injectate inside the bony SIJ. CDU can overcome this problem by allowing visualisation of the flow of the injectate.⁴ We thus decided to conduct this case study to find out the utility of CDU.



UMJ is an open access publication of the Ulster Medical Society (<http://www.ums.ac.uk>).

The Ulster Medical Society grants to all users on the basis of a Creative Commons Attribution-NonCommercial-ShareAlike 4.0 International Licence the right to alter or build upon the work non-commercially, as long as the author is credited and the new creation is licensed under identical terms.

After obtaining approval from ethical committee and informed consent, 10 adult patients scheduled to undergo SIJ injection were included. After positioning the patients in prone position and using proper aseptic cleaning and draping, a low frequency curvilinear ultrasound transducer was used to localise the target SIJ anatomy. After skin infiltration with LA, a 22-gauge Quincke spinal needle was advanced towards the SIJ under ultrasound guidance. Once the needle was seen to enter the SIJ, colour Doppler mode was activated. A 1.5 mL mixture of steroid and LA was then injected. Positive Doppler signal suggesting the flow within the SIJ along with absence of any overflow outside the bony landmarks were noted (Fig 1). Then an independent observer who was blinded about the study methodology, confirmed the intra-articular placement of the needle fluoroscopically by injecting radioopaque contrast. Efficacy of the injection in providing pain relief, was assessed at follow up.

Demographic details of the patients are depicted in Table 1. CDU flow pattern indicated correct intra-articular injection without any extra-articular flow pattern in all our patients. Subsequent fluoroscopy and dye injection also confirmed correct needle placement. Preprocedural visual analog score (VAS) (6.7±1.05) reduced significantly after the injection

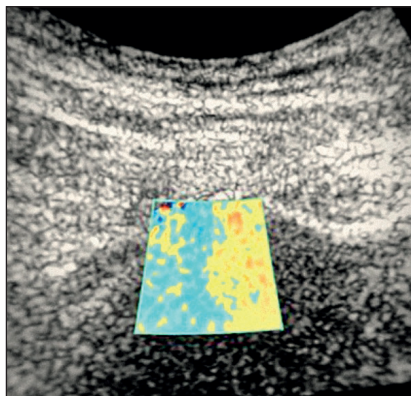


Fig 1: Use of color Doppler flow to locate needle placement.

(2.3±1.03) ($p < 0.0001$) (Table 2) confirming the efficacy of the procedure.

In this case series, we found that CDU can be used successfully to confirm correct intra-articular placement of

Table 1: Demographic data and Pain scores.

		p value
Age (Years)	55.7±11.81	NA
Male	4	NA
Female	6	NA
Pre-Procedure VAS score	6.7±1.05	<0.0001
Post-Procedure VAS Score	2.3±1.03	

VAS: Visual Analog Score. Data expressed as mean±standard deviation or discrete variables wherever application.

needle and subsequent injectate in SIJ.

This utility of CDU has not been reported to date. Arslan *et al.* used duplex and colour Doppler ultrasound to demonstrate vascularity inside and around the SIJ to diagnose sacroiliitis and to monitor the therapeutic response, but they did not perform any SIJ injection using ultrasound.⁵

Table 2: Techniques used for needle placement and confirmation of that.

	Intra-articular Doppler Flow Signal	Extra-Articular Doppler Flow Signal	Subsequent Fluoroscopic Confirmation of Needle Placement
US Doppler Guided Needle placement	Detected in all cases	Not detected in any case	Intra-articular needle placement confirmed in all cases using radioopaque dye.

We thus strongly propose a well powered randomised controlled trial on this.

Financial support: No funding other than personal was used in conducting the audit as well as writing the manuscript. We declare that we have no financial and/or personal relationships with other people or organizations that could inappropriately influence (bias) our work.

Conflict of Interest: The authors report no conflicts of interest.

Pradipta Bhakta¹, Dominic Harmon², Shailendra Mishra³

1. Department of Anaesthesia and Intensive Care, Temple Street Children’s University Hospital, Dublin, Ireland.

2. Department of Anaesthesia and Pain medicine, University Hospital Limerick, Ireland.

Department of Anaesthesia and Pain Medicine, Beaumont University Hospital, Dublin, Ireland.

Correspondence to: Dr. Pradipta Bhakta

Email: bhaktadr@hotmail.com

REFERENCES

1. Artner J, Cakir B, Reichel H, Lattig F. Radiation dose reduction in CT-guided sacroiliac joint injections to levels of pulsed fluoroscopy: a comparative study with technical considerations. *J Pain Res.* 2012;5:265-9.
2. Harmon D, O’Sullivan M. Ultrasound-guided sacroiliac joint injection technique. *Pain Physician.* 2008;11(4):543-7.
3. Korbe S, Udoji EN, Ness TJ, Udoji MA. Ultrasound-guided interventional procedures for chronic pain management. *Pain Manag.* 2015;5(6):465-82.
4. Choi S, Brull R. Is ultrasound guidance advantageous for interventional pain management? A review of acute pain outcomes. *Anesth Analg.* 2011;113(3):596-604.
5. Arslan H, Sakarya ME, Adak B, Unal O, Sayarlioglu M. Duplex and color Doppler sonographic findings in active sacroiliitis. *AJR Am J Roentgenol* 1999;173(3):677-80.

