





Surface mapping demonstrates compatibility of implantable loop monitor with a continuous-flow left ventricular assist device

Angela Li* , Gourg Atteya , Sirish Vullaganti  and Ramanak Mitra 

Department of Cardiology, Sandra Atlas Bass Heart Hospital, North Shore University Hospital, Donald and Barbara Zucker School of Medicine at Hofstra/Northwell, 300 Community Drive, 1 Cohen, Manhasset, NY 11030, USA

Abstract

Syncope in patients with continuous-flow left ventricular assist device may be associated with arrhythmia and difficult to determine without an implantable cardioverter defibrillator. We present a patient with continuous-flow left ventricular assist device, no implantable cardioverter defibrillator, and recurrent syncope. An implantable loop recorder was successfully implanted with surface mapping without noise interference.

Keywords LVAD; Syncope; Ventricular tachycardia; Implantable loop recorder

Received: 20 January 2021; Revised: 2 March 2021; Accepted: 24 March 2021

*Correspondence to: Dr. Angela Li, Department of Cardiology, Sandra Atlas Bass Heart Hospital, North Shore University Hospital, Donald and Barbara Zucker School of Medicine at Hofstra/Northwell, 300 Community Drive, 1 Cohen, Manhasset, NY 11030, USA. Tel: 201-486-0920; Fax: 516-562-1684. Email: ali10@northwell.edu

Introduction

The aetiology of syncope in patients with continuous-flow left ventricular assist device (CF-LVAD) may be difficult to determine in the absence of a pacemaker or defibrillator. Orthostatic hypotension or dysautonomia may account for 12–30% of severe dizziness/syncope in such patients.^{1,2} While bradyarrhythmia or tachyarrhythmia are generally tolerated, associated haemodynamic instability has been noted to occur in some studies in up to 10–13% of patients with LVAD.^{3,4} Current management guidelines for patients with LVAD without pre-existing implantable cardioverter defibrillator recommend observation without device therapy if there is no history of pre-operative ventricular arrhythmia.⁵ An implantable loop recorder (ILR) is an effective long-term continuous monitoring tool for the detection of arrhythmogenic syncope.⁶ The degree of noise interference from a CF-LVAD on an ILR is unknown. We present a case of implantation of an ILR for recurrent syncope in a patient with CF-LVAD with a priori assessment of noise interference using surface mapping.

Case report

A 64-year-old male with dilated non-ischaemic cardiomyopathy and a HeartMate II CF-LVAD, paroxysmal atrial fibrillation, non-sustained ventricular tachycardia (NSVT), and chronic kidney disease presented with traumatic fall in the setting of sudden syncope. He denied chest pain, palpitations, or lightheadedness prior to event and remained neurologically intact after regaining consciousness. This was his second admission in the last 3 months for unwitnessed syncope. Physical exam demonstrated asymmetric facial swelling and moderate bleeding in the left external auditory canal. He otherwise appeared well and was afebrile, rhythm was sinus at 91 b.p.m., and blood pressure was 84/60 (mean arterial pressure of 68). He had recovered from COVID-19 6 months prior and had not required intubation. His medications included warfarin, amiodarone 200 mg daily, and metoprolol succinate 25 mg daily.

Orthostatic vital signs were checked upon admission and were within normal limits. Complete blood count revealed a haemoglobin of 6.3 g/dL (8.0 one month prior).

Internationalized normalized ratio (INR) was supra-therapeutic at 5.14. There were no electrolyte abnormalities, and high-sensitivity troponin was not elevated. Electrocardiogram (ECG) revealed a narrow QRS with normal intervals. Echocardiogram revealed expected laminar LVAD inflow cannula flow, a decompressed left ventricle with midline inter-ventricular septum, and mildly decreased right ventricular function.

Pan computerized tomography scan revealed acute fracture of left external auditory canal with haemorrhage without evidence of bleeding elsewhere. A recent extensive workup by the gastroenterology service revealed no active source of bleeding.

Left ventricular assist device interrogation showed the following settings: speed of 8800 RPM, flow of 4.4 L/min, pulse index of 6.7, and pump power of 4.7. There was record of prior low flow alarms with speed drop changes, lowest to 8500 RPM coinciding with day of syncope. On telemetry, he was noted to have multiple episodes of asymptomatic NSVT up to 10 beats at 220 b.p.m. but no bradycardia (Figure 1).

The auditory canal fracture was medically managed after cauterization of bleeding sites and packing. Antibiotics were also administered. Given worsening of his chronic anaemia and elevated INR, he was given blood products including 2 units packed red blood cells, which raised the haemoglobin to 9.9 g/dL. No further bleeding was noted after the INR decreased to therapeutic levels (2.0–3.0). The patient was otherwise asymptomatic.

Given the lack of a clear aetiology for recurrent syncope and frequent NSVT noted on telemetry, the patient was evaluated for ILR placement for long-term monitoring of

Figure 2 Picture of left chest with paediatric electrodes placed in different orientations: 'standard' parasternal position along the fourth intercostal space (A), vertically 3 cm lateral of left sternal border (B), vertically directly lateral of left sternal border (C), laterally along the fifth intercostal space (D), left upper chest (E), and right upper chest (F).

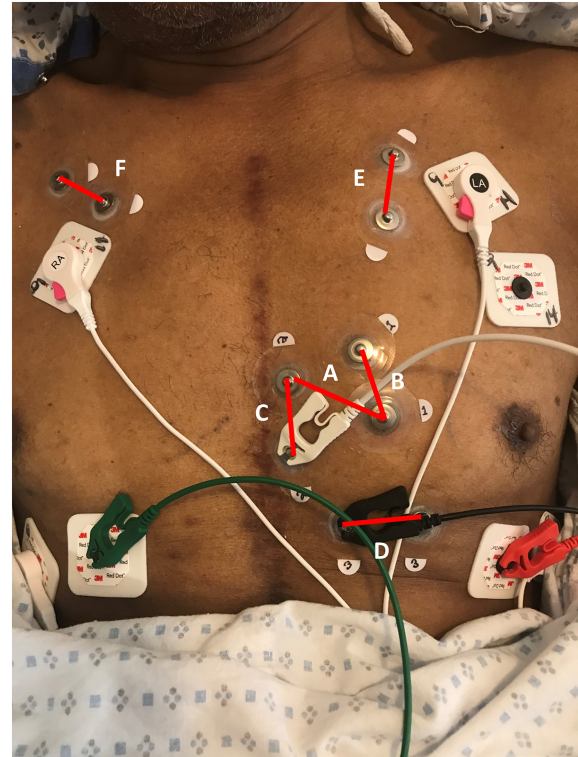
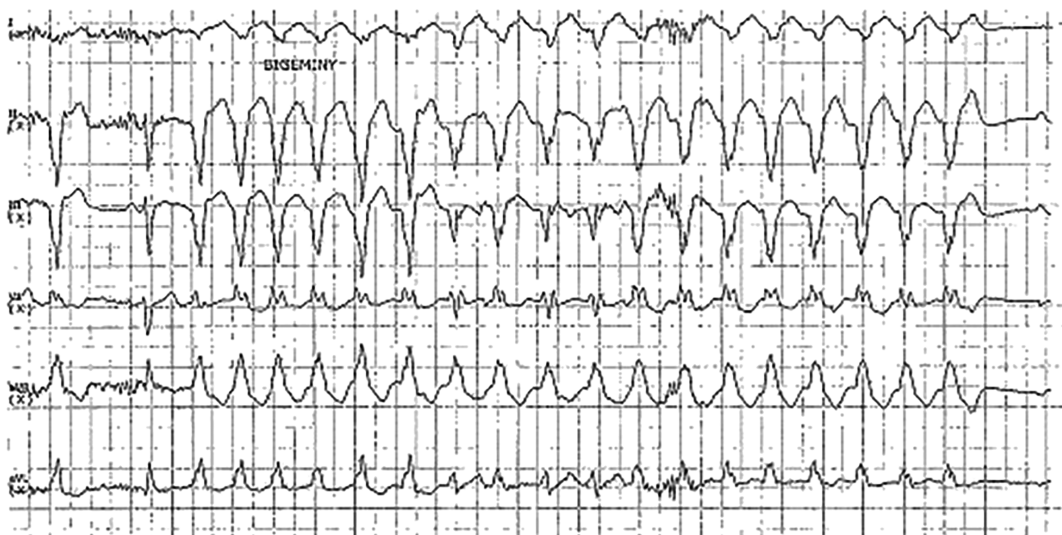


Figure 1 Telemetry strip shows 18 beats of non-sustained ventricular tachycardia at 150 b.p.m.



arrhythmia as the patient did not have an implanted implantable cardioverter defibrillator. Concerns of noise interference from CF-LVAD that might interfere with ILR signal acquisition were raised. There are no reports of ILRs used in patients with a CF-LVAD. In order to determine a priori whether there would be noise interference, paediatric electrodes were placed flush adjacent to each other in five different orientations on the left anterior chest for surface mapping (Figure 2), with support from a Medtronic clinical field specialist. Each pair of surface electrodes was connected to the right arm and left arm ECG cables of a pacemaker programmer (Medtronic model 2090, Minneapolis, MN), with left leg and right leg electrodes in standard

position to measure R wave amplitude in each position (Figure 3). The ECG acquisition of the programmer uses similar filtering for signal processing as the Medtronic ILR. It was determined that optimal R wave amplitude was detected along the fourth intercostal space, in the standard position as recommended by the manufacturer for placement of ILR.⁷ Based on these results, a Medtronic ILR (model LINQ II) was implanted in the pre-determined position. Post implant interrogation revealed sensed R waves of 0.89 mV with good P wave discrimination (Figure 4). No noise artefact from LVAD was noted.

The patient was seen in heart failure and device clinic after discharge. Device interrogation showed stable P and R wave

Figure 3 Measurement of electrical potential amplitude in corresponding orientations as visualized in Figure 2: along the fourth intercostal space (A), vertical position 3 cm lateral of the left sternal border (B), vertical position directly lateral of the left sternal border (C), lateral position along the fifth intercostal space (D), left upper chest (E), and right upper chest (F). ECG, electrocardiogram.

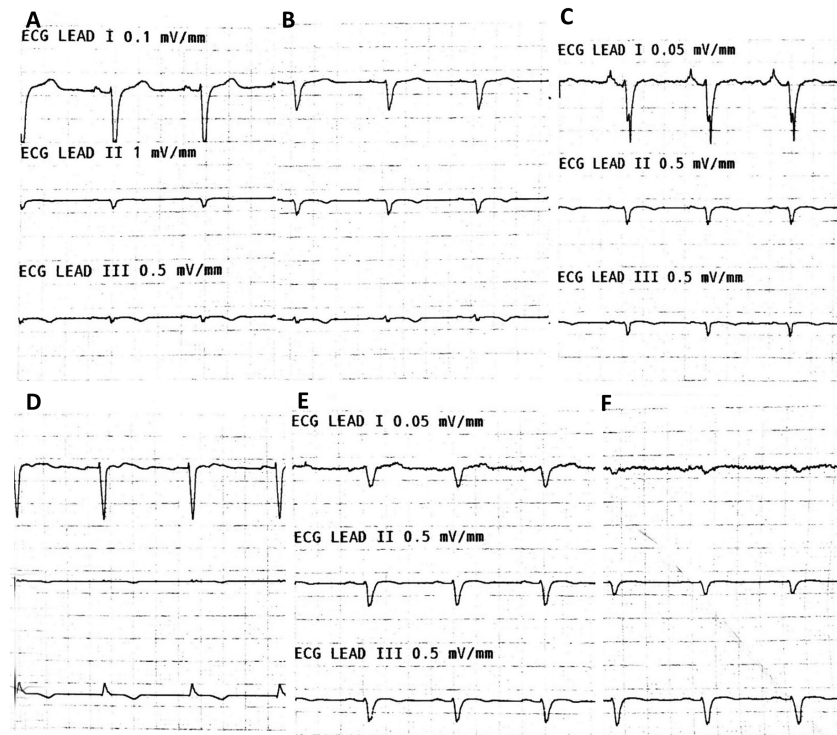
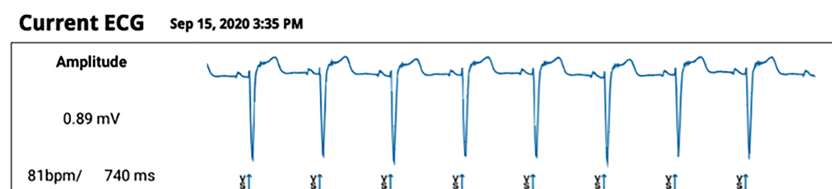


Figure 4 Post implant interrogation report shows R wave sensing of 0.89 mV with good P wave discrimination. ECG, electrocardiogram.



sensing with no noise interference from the LVAD and no bradyarrhythmia or tachyarrhythmia 5 months post implantation. There have been no changes to his medication doses, and haemoglobin has remained in the 7.0–8.0 g/dL range. Despite his chronic anaemia, no further syncope or arrhythmia was noted during follow-up.

Discussion

Ventricular arrhythmias are common in patients with heart failure with reduced ejection fraction, and the incidence may increase after LVAD implantation.⁸ It remains unclear, however, the extent to which ventricular tachycardia (VT) or ventricular fibrillation (VF) cause haemodynamic compromise in the setting of a CF-LVAD. There are reports of syncope and haemodynamic compromise in patients with LVAD during VT/VF, while others describe patients tolerating hours to days of VT/VF without defibrillation.⁸ It is thought that patients post LVAD are better able to tolerate malignant ventricular arrhythmias because they are no longer dependent on native left ventricular function to provide cardiac output⁹; however, compromise of left ventricular filling due to loss of right ventricular output may result in hypotension and even left atrial collapse.¹⁰

For patients that remain symptomatic, one study noted correlation of hypotension and syncope with decreased LVAD flows,¹¹ as was seen in our patient's LVAD interrogation. Case reports have looked into the pathophysiology of syncope and orthostatic hypotension in CF-LVAD and have postulated that increased autonomic dysfunction in LVAD patients likely contributes to an exaggerated response to changes in preload or an acute decrease in pump flow,^{10,12} increasing the likelihood of haemodynamic consequences.

To further assess unexplained syncope in our patient with CF-LVAD, the decision was made to place an ILR to better

ascertain a diagnosis. Although electrophysiology studies were considered, the likelihood of syncope due to a sustained bradyarrhythmia or tachyarrhythmia was considered lower with the associated findings of anaemia and low flow alarms. On the other hand, with a history of NSVT despite amiodarone therapy, the benefit to risk ratio of an ILR was considered high in the setting of recurrent syncope. The LINQ II algorithm relies on accurate sensing of P and R waves to detect atrial or ventricular arrhythmias. There have been no previous publications to our knowledge on its use for evaluation of syncope in the setting of a CF-LVAD, which is known to generate potential electrical artefact on 12-lead ECGs as a result of oscillating frequencies from the pump rotational speed.¹³ This theoretical interaction may discourage its appropriate use. Surface mapping may be used to determine the best vector for P and R wave signal detection and assess for noise interference.^{14,15} We demonstrate here the successful use of surface mapping for placement of a LINQ II without noise interference post implant in the setting of a CF-LVAD. Future prospective randomized studies evaluating the role of an ILR in patients with LVAD with syncope may be beneficial.

Conflict of interest

All authors have no conflicts of interest to disclose.

Funding

No grant or institutional funding was involved in this case report.

References

- Campbell P, Krim S, Dornelles A, Mandras S, Desai S, Patel H, Ventura HO. Does etiology of heart failure predict orthostatic hypotension in patients with left ventricular assist device? *J Card Fail* 2014; **20**: S33.
- Fudim M, Rogers JG, Frazier-Mills C, Patel CB. Orthostatic hypotension in patients with left ventricular assist devices: acquired autonomic dysfunction. *ASAIO J* 2018; **64**: e40–e42.
- Refaat M, Chemaly E, Lebeche D, Gwathmey JK, Hajjar RJ. Ventricular arrhythmias after left ventricular assist device implantation. *Pacing Clin Electrophysiol* 2008; **31**: 1246–1252.
- Andersen M, Videbaek R, Boesgaard S, Sander K, Hansen PB, Gustafsson F. Incidence of ventricular arrhythmias in patients on long-term support with a continuous-flow assist device (HeartMate II). *J Heart Lung Transplant* 2009; **28**: 733–735.
- Parikh V, Sauer A, Friedman PA, Sheldon SH. Management of cardiac implantable electronic devices in the presence of left ventricular assist devices. *Heart Rhythm* 2018; **15**: 1089–1096.
- Nielsen JC, Lin Y-J, de Oliveira Figueiredo MJ, Sepehri Shamloo A, Alfie A, Boveda S, Dagues N, di Toro D, Eckhardt LL, Ellenbogen K, Hardy C, Ikeda T, Jaswal A, Kaufman E, Krahn A, Kusano K, Kutuyifa V, S Lim H, Lip GYH, Nava-Townsend S, Pak H-N, Rodríguez Diez G, Sauer W, Saxena A, Svendsen JH, Vanegas D, Vaseghi M, Wilde A, Bunch TJ, Buxton AE, Calvimontes G, Chao T-F, Eckardt L, Estner H, Gillis AM, Isa R, Kautzner J, Maury P, Moss JD, Nam G-B, Olshansky B, Molano LFP, Pimentel M, Prabhu M, Tzou WS, Sommer P, Swampillai J, Vidal A, Deneke T, Hindricks G, Leclercq C. European Heart Rhythm Association (EHRA)/Heart Rhythm Society (HRS)/Asia Pacific Heart Rhythm Society (APHRS)/Latin American Heart Rhythm

- Society (LAHRS) expert consensus on risk assessment in cardiac arrhythmias: use the right tool for the right outcome, in the right population. *J Arrhythm* 2020; **36**: 553–607.
7. Krahn AD, Pickett RA, Sakaguchi S, Shaik N, Cao J, Norman HS, Guerrero P. R-wave sensing in an implantable cardiac monitor without ECG-based preimplant mapping: results from a multicenter clinical trial. *Pacing Clin Electrophysiol* 2014; **37**: 505–511.
 8. Pettit SJ, Petrie MC, Connelly DT, Japp AG, Payne JR, Haj-Yahia S, Gardner RS. Use of implantable cardioverter defibrillators in patients with left ventricular assist devices. *Eur J Heart Fail* 2012; **14**: 696–702.
 9. Oz MC, Rose EA, Slater J, Kuiper JJ, Catanese KA, Levin HR. Malignant ventricular arrhythmias are well tolerated in patients receiving long-term left ventricular assist devices. *J Am Coll Cardiol* 1994; **24**: 1688–1691.
 10. Chandra A, Pradhan R, Kim FY, Frisch DR, Bogar LJ, Bonita R, Cavarocchi NC, Greenspon AJ, Hirose H, Pitcher HT, Rubin S, Mather PJ. Recurrent orthostatic syncope due to left atrial and left ventricular collapse after a continuous-flow left ventricular assist device implantation. *J Heart Lung Transplant* 2013; **32**: 129–133.
 11. Enriquez AD, Calenda B, Miller MA, Anyanwu AC, Pinney SP. The role of implantable cardioverter-defibrillators in patients with continuous flow left ventricular assist devices. *Circ Arrhythm Electrophysiol* 2013; **6**: 668–674.
 12. Money JE, Al Danaf J, Nelson M, Mckellar SH, Drakos SG, Kemeyou L. Loss of pulsatility: another cause of syncope in patients with left ventricular assist devices. *ASAIO J* 2020; **66**: e128–e130.
 13. Loring Z, Sen S, Black-Maier E, Atwater BD, Russell SD, DeVore AD, Piccini JP. Reducing ECG artifact from left ventricular assist device electromagnetic interference. *J Am Heart Assoc* 2020; **9**: e017563.
 14. Tada S, Shibata M, Ohno S, Haruki Y, Murakami H, Hotta D, Nojima M, Ruhnke GW. Investigation on the optimal implantation site and setting of Reveal LINQ® avoiding interference with performance of transthoracic echocardiography. *J Arrhythm* 2018; **34**: 261–266.
 15. Kawashima A, Tanimoto F, Nagao T, Toyoshima T, Okuyama Y. Investigation of optimal position for implantable loop recorders by potential mapping with Reveal DX. *J Arrhythm* 2015; **31**: 130–136.