

This is an Open Access article licensed under the terms of the Creative Commons Attribution-NonCommercial-NoDerivs 3.0 License ([www.karger.com/OA-license](http://www.karger.com/OA-license)), applicable to the online version of the article only. Distribution for non-commercial purposes only.

# A Patient with Chronic Hepatitis C and a Pancreatic Mass in Endoscopic Ultrasound

Mehdi Ghobakhlou Amir Houshang Mohammad Alizadeh  
Nosratollah Naderi Shirin Haghighi Mahsa Molaei  
Mitra Rafiezadeh Mohammad Reza Zali

Research Center for Gastroenterology and Liver Diseases, Shahid Beheshti  
University of Medical Sciences, Taleghani Hospital, Tehran, Iran

## Key Words

Pancreas lymphoma · Chronic hepatitis C

## Abstract

We report a rare case of pancreas tumor (lymphoma) in a patient with a history of chronic hepatitis C virus (HCV) infection without treatment, with a high viral load (20,199,805 IU/ml). He presented with abdominal pain, jaundice, weight loss and sweating. Computed tomography showed a hypodense mass located in the head of the pancreas, and immunohistochemistry of a specimen obtained by endoscopic ultrasound-guided fine needle aspiration revealed non-Hodgkin's lymphoma of the pancreas, B cell type. An association of HCV infection with pancreatic lymphoma has only been reported rarely in the literature and its clinical significance is uncertain.

## Introduction

Primary pancreatic lymphoma (PPL) is extremely rare, comprising 2.2% of non-Hodgkin's lymphomas (NHLs) and 4.9% of all pancreatic malignancies [1]. Clinical manifestations and imaging findings of PPL are similar to adenocarcinoma, but PPL must be distinguished from it because unlike pancreatic adenocarcinoma, PPL is potentially treatable [2–4]. Hepatitis C virus (HCV) infection has been associated with the development of B cell NHL (including diffuse large B cell lymphoma, marginal zone lymphoma and extranodal marginal zone B cell lymphoma of mucosa-associated lymphoid tissue) [5–9]. An association of hepatitis C and hepatic and splenic marginal zone lymphoma has been reported [7, 10], however its association with pancreatic lymphomas is unknown. We report a case of pancreatic lymphoma with HCV infection.

## Case Report

The patient was a 49-year-old man admitted to the hospital with the complaint of epigastric abdominal pain, icterus, significant weight loss, fever and sweating since 1.5 months prior to admission. He had a history of chronic HCV infection without treatment. He had no history of smoking or alcohol consumption.

On admission, blood pressure was 120/80 mm Hg, pulse rate was 88 bpm and temperature was 37.9°C. Physical examination revealed icteric sclera and mild tenderness in the epigastric abdomen. Hemoglobin level was 14 g/dl with a leukocyte count of 5,400/mm<sup>3</sup> (neutrophils 57%, lymphocytes 35%) and a platelet count of 245,000/mm<sup>3</sup>. Aspartate aminotransferase was 85 U/l, alanine aminotransferase 105 U/l, total bilirubin 12 mg/dl, direct bilirubin 8 mg/dl, alkaline phosphatase 735 U/l, serum lactate dehydrogenase (LDH) 725 IU/l and serum carbohydrate antigen 19-9 (CA19-9) 25 U/ml. HCV genotype was 1a and viral load was 20,199,805 IU/ml.

Abdominal ultrasound showed a hypoechoic mass adjacent to the head of the pancreas and the common bile duct was dilated with a diameter of 12 mm. Computed tomography (CT) of the abdomen showed a hypodense mass located in the head of the pancreas (fig. 1). Chest X-ray was normal. Endoscopic ultrasound (EUS) showed a 3 × 3 cm mass in the head of the pancreas with portal invasion, and fine needle aspiration (FNA) was performed (fig. 2). Endoscopic retrograde cholangiopancreatography was performed and showed dilated common and hepatic bile ducts, thus a metallic biliary stent was placed. Bone marrow aspiration and biopsy was performed and its pathologic examination was normal.

Microscopic pathologic examination was done on cell block specimen and reported a malignant undifferentiated tumor (fig. 3a); immunohistochemistry of the specimen revealed positive leukocyte common antigen in tumor cells (fig. 3b), diffuse and strong membrane staining for the B cell marker protein CD20 (fig. 3c), scattered CD3 in nontumoral lymphocytes and negative cytokeratin in tumoral cells (fig. 3d), compatible with NHL of the pancreas, B cell type. We started Peg-interferon plus ribavirin and the patient was referred to radiotherapy.

## Discussion

PPL is extremely rare, comprising 2.2% of NHLs and 4.9% of all pancreatic malignancies [1]. PPL can be confounded with pancreatic adenocarcinoma [2, 3]. In a study by Mishra et al. [11] based on the Surveillance, Epidemiology, and End Results database, 523 cases of PPL were identified. The median age range at diagnosis was 65–69 years. The most common histologic type was diffuse large B cell lymphoma. The head of the pancreas is the most common location. T cell lymphomas are very uncommon [3, 12, 13]. Presenting symptoms are nonspecific, including abdominal pain, weight loss, jaundice, nausea and vomiting [1, 4, 13, 14]. This 49-year-old man presented with abdominal pain, weight loss, jaundice, fever and sweating. Systemic B symptoms are uncommon in pancreatic lymphoma [4, 13], but this patient had B symptoms.

CT is the most common imaging method for the detection of PPL. The combination of a bulky localized tumor in the pancreatic head without significant dilatation of the main pancreatic duct strengthens a diagnosis of pancreatic lymphoma over adenocarcinoma. The presence of calcification or necrosis is a reliable finding for ruling out NHL [15, 16]. Our reported case had none of the above-mentioned imaging findings.

EUS can visualize pancreatic tumor dimension and anatomic location in relation to surrounding structures. EUS-guided fine needle biopsy of tumors can also be performed and provide a histological diagnosis of PPL in some cases [17]. EUS-guided

FNA (EUS-FNA) of pancreatic masses is as accurate as CT/ultrasound-guided sampling and surgical biopsies [18], and immunocytochemistry examination of the specimen can improve the accuracy of EUS-FNA cytology [19].

In this case, microscopic examination of EUS-FNA of the pancreas mass did not provide a definite diagnosis, but immunohistochemistry was compatible with B cell NHL. CA19-9 is usually normal and sometimes slightly elevated [20, 21]. LDH is a useful marker for the diagnosis of PPL and also an important prognostic factor. PPL should be suspected in a patient with pancreatic mass and elevated LDH and b2 microglobulin serum markers [13, 22]. In this case serum CA19-9 was normal and serum LDH was high.

This case met the criteria for the definition of PPL as used by Dawson et al. [23]. These criteria include: (1) neither superficial lymphadenopathy nor enlargement of mediastinal lymph nodes on chest radiography; (2) a normal leukocyte count in peripheral blood; (3) main mass in the pancreas with lymph node involvement confined to the peripancreatic region; (4) no hepatic or splenic involvement.

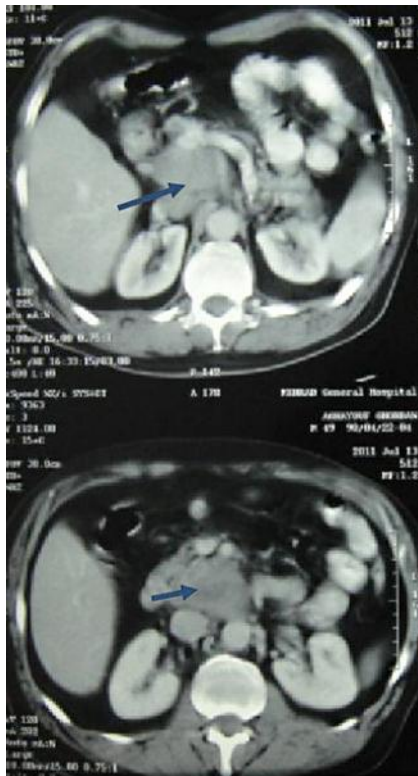
The etiology of PPL is unknown. Epstein-Barr virus can contribute to the development of lymphomas. Stomach mucosa-associated lymphoid tissue lymphoma is known to be caused by *Helicobacter pylori*; no such association with PPL is known to date. Familial pancreatic lymphoma has also been reported to be associated with pancreatic lymphoma [13, 24, 25]. A causative role of HCV in B cell lymphoproliferative disorders has been suggested by several reports [5–9]. In a study by Mizorogi et al. [26], among 123 patients with B cell lymphoproliferative disorders, 38 patients with non-B cell lymphoproliferative disorders and 516 patients with miscellaneous diseases, the prevalence of HCV infection was higher in patients with B cell NHL than in those with non-B cell NHL and the control group.

Despite these strong associations, an association of HCV infection with pancreatic lymphoma has only been shown by few reports. Takagi et al. [9] in Japan reported a case of pancreas lymphoma with chronic hepatitis C. Visco et al. [27] in Italy analyzed 156 previously untreated consecutive HCV-positive patients with diffuse large B cell lymphoma observed from 1994 to 2004. The spleen was the most frequently involved extranodal site, followed by liver and stomach. They observed one case of pancreas lymphoma.

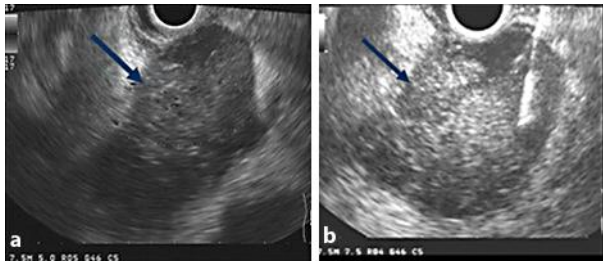
The reason of association between HCV and lymphomas is uncertain. Lymphoproliferation induced by HCV may occur due to binding of the virion to receptors on the surface of B lymphocytes, which might lower their threshold for antigen response or induce DNA mutations [28]. In patients with HCV infection and splenic marginal zone NHL, treatment of HCV infection leads to regression of NHL [10]. Moreover, HCV infection can directly drive lymphoproliferation [29].

In a large study by Giordano et al. [30] among military veterans infected with HCV, they found a 20–30% increased overall risk of NHL. HCV infection was associated with an increased risk of cryoglobulinemia, supporting the hypothesis that chronic HCV infection serves as an immunological stimulus for progression to hematological malignancy.

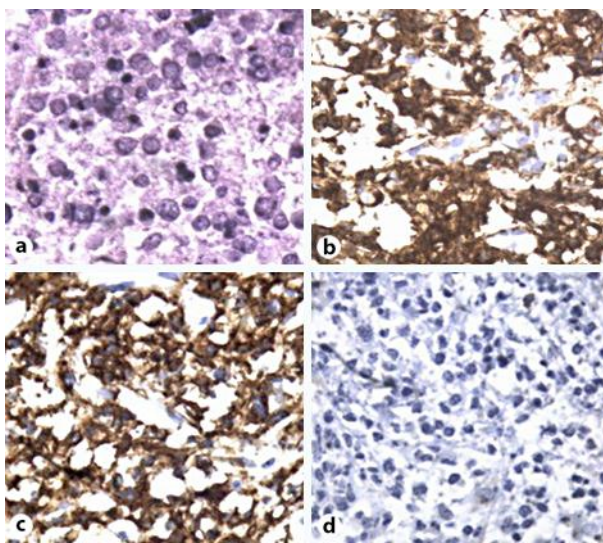
Our patient had a high HCV viral load and he did not have other risk factors for lymphoma, therefore HCV infection may have played a role in the pathogenesis of lymphoma. Because of the patient's high viral load and probability of hepatitis exacerbation after chemotherapy initiation, we started Peg-interferon plus ribavirin and he was initially referred to radiotherapy and then chemotherapy was started. More research is needed to clarify the relationship between HCV and PPL.



**Fig. 1.** Contrast-enhanced CT of the abdomen showing a heterogeneous mass in the head of the pancreas (arrows).



**Fig. 2.** **a** EUS showing a mass in the head of the pancreas with portal invasion (arrow). **b** EUS-FNA of the pancreas tumor (arrow).



**Fig. 3.** Microscopic pathologic examination and immunohistochemistry of the pancreas tumor specimen (magnification  $\times 400$ ): **a** EUS-FNA cytology showing malignant undifferentiated tumor. **b** Positive leukocyte common antigen in tumor cells. **c** Diffuse and strong membrane staining for the B cell marker protein CD20. **d** Scattered CD3 in nontumoral lymphocytes and negative cytokeratin in tumor cells compatible with NHL of the pancreas, B cell type.

## References

- 1 Webb TH, Lillemoe KD, Pitt HA, Jones RJ, Cameron JL: Pancreatic lymphoma. Is surgery mandatory for diagnosis or treatment? *Ann Surg* 1989;209:25–30.
- 2 Grimison PS, Chin MT, Harrison ML, Goldstein D: Primary pancreatic lymphoma – pancreatic tumours that are potentially curable without resection, a retrospective review of four cases. *BMC Cancer* 2006;6:117.
- 3 Salvatore JR, Cooper B, Shah I, Kummet T: Primary pancreatic lymphoma: a case report, literature review, and proposal for nomenclature. *Med Oncol* 2000;17:237–247.
- 4 Arcari A, Anselmi E, Bernuzzi P, Berta R, Lazzaro A, Moroni CF, Trabacchi E, Vallisa D, Vercelli A, Cavanna L: Primary pancreatic lymphoma: report of five cases. *Haematologica* 2005;90:ECR09.
- 5 Gisbert JP, García-Buey L, Pajares JM, Moreno-Otero R: Prevalence of hepatitis C virus infection in B-cell non-Hodgkin's lymphoma: systematic review and meta-analysis. *Gastroenterology* 2003;125:1723–1732.
- 6 de Sanjose S, Benavente Y, Vajdic CM, et al: Hepatitis C and non-Hodgkin lymphoma among 4,784 cases and 6,269 controls from the International Lymphoma Epidemiology Consortium. *Clin Gastroenterol Hepatol* 2008;6:451–458.
- 7 Bronowicki JP, Bineau C, Feugier P, Hermine O, Brousse N, Oberti F, Rousselet MC, Dharancy S, Gaulard P, Flejou JF, Cazals-Hatem D, Labouyrie E: Primary lymphoma of the liver: clinical-pathological features and relationship with HCV infection in French patients. *Hepatology* 2003;37:781–787.
- 8 Rasul I, Shepherd FA, Kamel-Reid S, Krajden M, Pantalony D, Heathcote EJ: Detection of occult low-grade B-cell non-Hodgkin's lymphoma in patients with chronic hepatitis C infection and mixed cryoglobulinemia. *Hepatology* 1999;29:543–547.
- 9 Takagi K, Nishikawa S, Nagasaka A, Higuchi A, Satoh H: Malignant lymphoma of the pancreas with chronic hepatitis C. *Nippon Shokakibyo Gakkai Zasshi* 2004;101:1227–1231.
- 10 Hermine O, Lefrere F, Bronowicki JP, et al: Regression of splenic lymphoma with villous lymphocytes after treatment of hepatitis C virus infection. *N Engl J Med* 2002;347:89–94.
- 11 Mishra MV, Keith SW, Shen X, Biswas T: Primary pancreatic lymphoma: a population-based analysis using the Surveillance, Epidemiology, and End Results database. *J Clin Oncol* 2011;29(suppl 4):abstr 303.
- 12 Lin H, Li SD, Hu XG, Li ZS: Primary pancreatic lymphoma: report of six cases. *World J Gastroenterol* 2006;12:5064–5067.
- 13 Saif MW: Primary pancreatic lymphomas. *JOP* 2006;7:262–273.
- 14 Battula N, Srinivasan P, Prachalias A, Rela M, Heaton N: Primary pancreatic lymphoma: diagnostic and therapeutic dilemma. *Pancreas* 2006;33:192–194.
- 15 Prayer L, Schurawitzki H, Mallek R, Mostbeck G: CT in pancreatic involvement of non-Hodgkin lymphoma. *Acta Radiol* 1992;33:123–127.
- 16 Merkle EM, Bender GN, Brambs HJ: Imaging findings in pancreatic lymphoma: differential aspects. *AJR Am J Roentgenol* 2000;174:671–675.
- 17 Harrison JL, Millikan KW, Prinz RA, Zaidi S: Endoscopic ultrasound for diagnosis and staging of pancreatic tumors. *Am Surg* 1999;65:659–664.
- 18 Mallery JS, Centeno BA, Hahn PF, Chang Y, Warshaw AL, Brugge WR: Pancreatic tissue sampling guided by EUS, CT/US, and surgery: a comparison of sensitivity and specificity. *Gastrointest Endosc* 2002;56:218–224.
- 19 Naito Y, Okabe Y, Kawahara A, Taira T, Yamaguchi T, Abe H, Arikawa S, Nakayama M, Yasumoto M, Eriguchi N, Naito H, Kage M, Yano H: Guide to diagnosing primary pancreatic lymphoma, B-cell type: immunocytochemistry improves the diagnostic accuracy of endoscopic ultrasonography-guided fine needle aspiration cytology. *Diagn Cytopathol* 2011, Epub ahead of print.
- 20 Tucheck JM, De Jong SA, Pickleman J: Diagnosis, surgical intervention, and prognosis of primary pancreatic lymphoma. *Am Surg* 1993;59:513–518.
- 21 Mann DV, Edwards R, Ho S, Lau WY, Glazer G: Elevated tumour marker CA19-9: clinical interpretation and influence of obstructive jaundice. *Eur J Surg Oncol* 2000;26:474–479.
- 22 Savopoulos CG, Tsepmeli NE, Kaiafa GD, Zantidis AT, Bobos MT, Hatzitolios AI, Papavramidis ST, Kostopoulos IS: Primary pancreatic anaplastic large cell lymphoma, ALK negative: a case report. *World J Gastroenterol* 2005;11:6221–6224.
- 23 Dawson IM, Cornes JS, Morson BC: Primary malignant lymphoid tumours of the intestinal tract. Report of 37 cases with a study of factors influencing prognosis. *Br J Surg* 1961;4:80–89.

- 24 Nayer H, Weir EG, Sheth S, Ali SZ: Primary pancreatic lymphoma. *Cancer* 2004;102:315–321.
- 25 James JA, Milligan DW, Morgan GJ, Crocker J: Familial pancreatic lymphoma. *J Clin Pathol* 1998;51:80–82.
- 26 Mizorogi F, Hiramoto J, Nozato A, Takekuma Y, Nagayama K, Tanaka T, Takagi K: Hepatitis C virus infection in patients with B-cell non-Hodgkin's lymphoma. *Intern Med* 2000;39:112–117.
- 27 Visco C, Arcaini L, Brusamolino E, Burcheri S, Ambrosetti A, Merli M, Bonoldi E, Chilosi M, Viglio A, Lazzarino M, Pizzolo G, Rodeghiero F: Distinctive natural history in hepatitis C virus positive diffuse large B-cell lymphoma: analysis of 156 patients from northern Italy. *Ann Oncol* 2006;17:1434–1440.
- 28 Machida K, Cheng KT, Pavio N, Sung VM, Lai MM: Hepatitis C virus E2-CD81 interaction induces hypermutation of the immunoglobulin gene in B cells. *J Virol* 2005;79:8079–8089.
- 29 Duberg AS, Nordstrom M, Torner A, et al: Non-Hodgkin's lymphoma and other nonhepatic malignancies in Swedish patients with hepatitis C virus infection. *Hepatology* 2005;41:652–659.
- 30 Giordano TP, Henderson L, Landgren O, Chiao EY, Kramer JR, El-Serag H, Engels EA: Risk of non-Hodgkin lymphoma and lymphoproliferative precursor diseases in US veterans with hepatitis C virus. *JAMA* 2007;297:2010–2017.