



Educational video

Aortic utero-ovarian sentinel nodes and left infrarenal aortic lymph node dissection by ICG supported navigation



Rainer Kimmig*, Peter Rusch, Paul Buderath, Bahriye Aktas

West-German Cancer Center, Dpt. Gynaecology and Obstetrics, University of Duisburg-Essen, Germany

ARTICLE INFO

Article history:

Received 14 December 2016

Accepted 6 February 2017

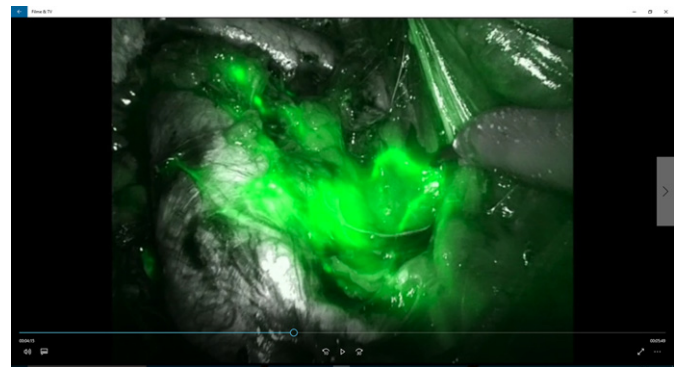
Available online 9 February 2017

1. Abstract

Lymphatic spread in endometrial cancer occurs along two major pathways: the uterine vascular mesometrium to the pelvic iliac lymph compartment and via the ovarian mesonephric pathway (infundibulopelvic ligament) to the paraaortic nodes visualized in (Kimmig et al., 2016a,b). However, it could be shown that in pelvic negative nodes following pelvic lymphadenectomy and even pelvic sentinel node excision the incidence of positive paraaortics is as low as 1–2% (Abu-Rustum et al., 2009; Kim et al., 2016; Holloway et al., 2016; Zahl Eriksson et al., 2016). Thus, it could be reasonable to omit paraaortic and even pelvic systematic lymphadenectomy in patients with negative sentinels to reduce morbidity (Tschernichovsky et al., 2016). However, in patients with pT1b/G2 and 3 tumors percentage of isolated positive paraaortic nodes may be significantly higher (Kumar et al., 2014): paraaortic sentinel node resection may be useful to identify their risk correctly. In addition, ICG-guided navigation could also support the resection of the complete paraaortic compartment in case of proven positive nodes. In this video, the visualization of the lymphatic paraaortic drainage of the uterine corpus has been achieved by application of 4 × 0.5 ml of a 1.66 mg/ml solution of indocyanine green (ICG Pulsion®) intracorporal into the uterine fundus and midcorporal, right and left. It was injected via an Iowa-trumpet transcervically in about 0.5 cm myometrial depth, each.

The video defines the technique of “*en bloc*” resection of paraaortic nodes together with the connecting ovarian lymph vessels isolated from their attachment to the colonic mesentery and preserving the inferior mesenteric plexus. It will also be basis for identification of paraaortic sentinel nodes in an international multicenter study under consideration (Kimmig et al., unpublished data).

* Corresponding author at: West German Cancer Center, University Hospital Essen, Dpt. Obstetrics and Gynaecology, Hufelandstr. 55, D-45133 Essen, Germany.
E-mail address: rainer.kimmig@uk-essen.de (R. Kimmig).



Appendix A. Supplementary data

Supplementary data to this article can be found online at <http://dx.doi.org/10.1016/j.gore.2017.02.003>.

References

- Abu-Rustum, N.R., Gomez, J.D., Alektiar, K.M., Soslow, R.A., Hensley, M.L., Leita Jr., M.M., Gardner, G.J., Sonoda, Y., Chi, D.S., Barakat, R.R., Nov 2009. The incidence of isolated paraaortic nodal metastasis in surgically staged endometrial cancer patients with negative pelvic lymph nodes. *Gynecol. Oncol.* 115 (2):236–238. <http://dx.doi.org/10.1016/j.ygyno.2009.07.016>.
- Holloway, R.W., Gupta, S., Stavitzki, N.M., Zhu, X., Takimoto, E.L., Gubbi, A., Bigsby, G.E., Brudie, L.A., Kendrick, J.E., Ahmad, S., May 2016. Sentinel lymph node mapping with staging lymphadenectomy for patients with endometrial cancer increases the detection of metastasis. *Gynecol. Oncol.* 141 (2):206–210. <http://dx.doi.org/10.1016/j.ygyno.2016.02.018>.
- Kim, T.H., Kim, H.S., Kim, T.J., Chang, S.J., Kim, D.Y., Ryu, S.Y., Kim, B.G., Kim, Y.T., Bae, D.S., Ryu, H.S., Nam, J.H., Jun 2016. Survival impact based on the thoroughness of pelvic lymphadenectomy in intermediate- or high-risk groups of endometrioid-type endometrial cancer: a multi-center retrospective cohort analysis. *Gynecol. Oncol.* 141 (3): 440–446. <http://dx.doi.org/10.1016/j.ygyno.2016.03.031>.
- Kimmig, R., Aktas, B., Buderath, P., Rusch, P., Heubner, M., 2016a. Intraoperative navigation in robotically assisted compartmental surgery of uterine cancer by visualisation of embryologically derived lymphatic networks with Indocyanine-green (ICG). *J. Surg. Oncol.* 113 (5):554–559. <http://dx.doi.org/10.1002/jso.24174> (Apr).
- Kimmig, R., Aktas, B., Buderath, P., Heubner, M., 2016b. Robotically assisted peritoneal mesometrial resection (PMMR) in endometrial cancer supported by ICG labeling of the compartmental lymphatic system. *Gynecol. Oncol. Rep.* 16:24. <http://dx.doi.org/10.1016/j.gore.2016.03.004> (Mar).
- Kumar, S., Podratz, K.C., Bakkum-Gamez, J.N., Dowdy, S.C., Weaver, A.L., McGree, M.E., Cliby, W.A., Keeney, G.L., Thomas, G., Mariani, A., Jan 2014. Prospective assessment

- of the prevalence of pelvic, paraaortic and high paraaortic lymph node metastasis in endometrial cancer. *Gynecol. Oncol.* 132 (1):38–43. <http://dx.doi.org/10.1016/j.ygyno.2013.10.002>.
- Tschernichovsky, R., Diver, E.J., Schorge, J.O., Goodman, A., Oct 2016. The role of lymphadenectomy versus sentinel lymph node biopsy in early-stage endometrial cancer: a review of the literature. *Am. J. Clin. Oncol.* 39 (5):516–521. <http://dx.doi.org/10.1097/COC.000000000000302>.
- Zahl Eriksson, A.G., Ducie, J., Ali, N., McGree, M.E., Weaver, A.L., Bogani, G., Cliby, W.A., Dowdy, S.C., Bakkum-Gamez, J.N., Abu-Rustum, N.R., Mariani, A., Leitao Jr., M.M., Mar 2016. Comparison of a sentinel lymph node and a selective lymphadenectomy algorithm in patients with endometrioid endometrial carcinoma and limited myometrial invasion. *Gynecol. Oncol.* 140 (3):394–399. <http://dx.doi.org/10.1016/j.ygyno.2015.12.028>.