

Review Article

Selective Amygdalohippocampectomy

David Spencer¹ and Kim Burchiel²

¹Department of Neurology, Oregon Health & Science University, Portland, OR 9739, USA

²Department of Neurological Surgery, Oregon Health & Science University, Portland, OR 97239, USA

Correspondence should be addressed to David Spencer, spencerd@ohsu.edu

Received 8 November 2010; Revised 22 February 2011; Accepted 25 March 2011

Academic Editor: Seyed M. Mirsattari

Copyright © 2012 D. Spencer and K. Burchiel. This is an open access article distributed under the Creative Commons Attribution License, which permits unrestricted use, distribution, and reproduction in any medium, provided the original work is properly cited.

Epilepsy surgery can be an effective epilepsy treatment for patients whose seizures do not respond to best medical therapy. For patients with temporal lobe epilepsy, selective amygdalohippocampectomy (SAH) has emerged as a viable alternative to standard anterior temporal lobectomy. This paper reviews the indications for SAH, the technical advances that have led to greater adoption of the procedure, the expectations for seizure control, and the risks of morbidity.

1. Introduction

Epilepsy is a common condition that affects nearly 1% of the world's population. The World Health Organization reports that neurological disease outranks HIV, cancer, and coronary artery disease in years of life lost to disability, and among neurological conditions, epilepsy ranks 4th [1]. While nearly 2/3 of patients with epilepsy achieve good control of seizures using antiepileptic medications, the remaining 1/3 have seizures that are resistant to medications and may be considered as candidates for epilepsy surgery. The benefit of epilepsy surgery in treatment-resistant epilepsy has been demonstrated in numerous case series as well as by a recent randomized clinical trial which demonstrated that surgery is clearly superior to best medical therapy in patients with temporal lobe epilepsy (TLE) [2].

Most people with TLE have seizures that originate from the mesial-basal temporal lobe structures, including the hippocampus, amygdala, and parahippocampal gyrus. The traditional surgical approach has been en bloc anterior temporal lobectomy (ATL). In this procedure, approximately 3–6 cm of anterior temporal neocortex is resected (depending on hemispheric language dominance), permitting access to resection of mesial structures. A modification popularized by the Yale group limits neocortical resection to 3.5 cm from the temporal pole and spares the superior temporal gyrus, obviating the need for language mapping in most cases [3, 4].

ATL offers advantages of good surgical exposure to allow complete resection of mesial structures, relatively low morbidity, and permits pathological examination of en bloc specimens. This procedure is still commonly employed today.

The central epileptogenic role of mesial temporal structures in TLE has been demonstrated in animal models of TLE and in pathological, electrophysiological, and structural and functional imaging studies. Thus, more targeted mesial temporal resections that spared temporal neocortex (selective amygdalohippocampectomy) were envisioned as possible means of providing equivalent seizure control with fewer neuropsychological sequelae (Figure 1).

2. Historical Background

Paulo Niemeyer reported selective resection of mesial temporal structures for intractable epilepsy in 1958 [5]. In a letter to his colleague Henri Gastaut, he related "because the focus of this epilepsy is usually in the nucleus amygdalae, in Ammon's horn, or in the hippocampus of gyrus, I resected these 3 structures via a transventricular approach, almost without touching the temporal cortex" [6]. The fascinating history of his pioneering work in neurosurgery in Brazil is related in a recent historical article by Cavalcanti et al. [6]. It is notable that the procedure was developed well in advance of the advent of image-guided neuronavigation systems. Subsequently Wieser and Yasargil popularized a transylvian

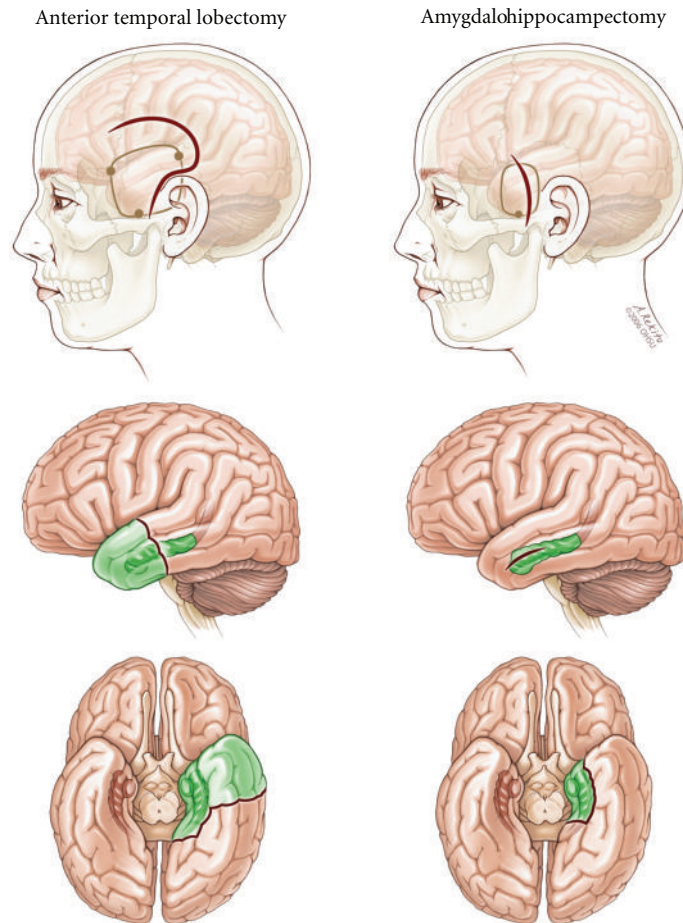


FIGURE 1: Comparison of anterior temporal lobectomy and selective amygdalohippocampectomy.

approach to SAH and reported outcomes of large numbers of patients who underwent this procedure [7, 8]. Other approaches including subtemporal [9] and variants of the transcortical approach have been described [10, 11]. Use of SAH became more widespread in the 1990s in tandem with increased utilization of intraoperative neuronavigation systems.

3. Indications

Selective amygdalohippocampectomy is employed in cases of medically refractory temporal lobe epilepsy of mesial temporal origin. There is no universally agreed upon definition of medically refractory or treatment-resistant epilepsy. Many authorities use a working definition of failure of at least two trials of antiepileptic drug monotherapy and one combination therapy when used at therapeutic levels over 1-2 years; however, a variety of definitions have been employed [12, 13]. In practice, many patients have failed much more extensive medication trials over much more extended time periods.

Most commonly, suitable candidates are selected based on convergent lines of evidence implicating unilateral mesial temporal structures as the epileptogenic region [14]. Central to this decision is a compatible ictal semiology and

neurological history. Video-EEG monitoring should confirm ictal semiology and stereotyped ictal onset on scalp EEG consistent with mesial temporal origin. Interictal EEG may show concordant unilateral or bilateral (usually ipsilateral predominant) epileptiform discharges. MRI often demonstrates an abnormality in the mesial temporal structures: most commonly hippocampal atrophy with or without mesial temporal signal change on T2-weighted or FLAIR sequences. Patients with exclusively mesial temporal foreign tissue lesions (e.g., low grade tumor) or neurodevelopmental abnormalities may also be good candidates for this procedure.

For patients in whom these lines of evidence fail to converge or for whom some data points are lacking (e.g., absence of MRI lesion, poorly localized ictal onsets on EEG), additional studies may be required, including PET, MEG, or Ictal SPECT. Particularly in nonlesional cases, if standard evaluation supplemented by specialized imaging studies defines a unilateral temporal lobe onset, intracranial EEG monitoring may be required to distinguish mesial from temporal neocortical onset and determine whether selective amygdalohippocampectomy is appropriate. Experience has shown that surgical failure rates are higher if strict criteria for unilateral mesial temporal onset are not applied [15].

Occasional patients with well-defined mesial temporal onset seizures should be excluded from consideration for SAH. These include most patients with documented independent bitemporal onset seizures [15] and those at risk for severe global memory impairment as a result of surgery. Patients with dominant temporal lobe foci are at greatest risk for postoperative functional decline in verbal memory, especially patients with high preoperative verbal memory performance, normal hippocampal volume, and later onset of seizures in adulthood [16]. Patients with a similar pattern in the nondominant temporal lobe can also experience clinically important deficits, but these are usually less prominent than in dominant temporal lobe resections [16]. While not always contraindications for surgery, this is important information that must be weighed carefully in presurgical decision making. Finally, patients with severe bilateral hippocampal atrophy who fail to demonstrate support of memory function contralateral to the proposed surgical side on intracarotid amytal procedure (Wada test) may be at risk for disabling global memory impairment, although there are few documented cases [17–19]. Clearly patients with idiopathic (primary) generalized epilepsies, extratemporal focal epilepsy, and temporal neocortical foci or temporal lobe epilepsy not clearly localized to mesial temporal structures are not candidates for SAH. Patients with exclusively psychogenic nonepileptic seizures (PNES) are not candidates; those with concurrent PNES and mTLE must be assessed very carefully, but the presence of PNES should not exclude patients *a priori* [20].

4. Surgical Procedure

Here we describe in detail the commonly employed transcortical approach to SAH via the middle temporal gyrus. This is the preferred procedure at our center; however, alternative approaches including transsylvian and subtemporal methods are also commonly employed and will also be briefly discussed.

The procedure is accomplished with the assistance of an image-based frameless intraoperative guidance system (Figure 2). An MRI with placement of fiducial markers is performed just prior to surgery. The procedure is performed under routine general anesthesia with endotracheal intubation.

In the operating room, the patient is positioned supine with the head held in position in 3-pin fixation, rotated 90 degrees to the opposite side, and parallel to the floor.

Following registration of scalp fiducials, the planned entry point is marked on the scalp and the scalp is prepared by infiltration with lidocaine, bupivacaine, and epinephrine. After scalp and temporalis fascia incision and retraction, the neuronavigation system is used to locate the temporal craniotomy. Craniotomy is performed and dura opened and flapped inferiorly. The neuronavigation system is used to identify the location of the cortical incision in the middle temporal gyrus that is 2.5–3.0 cm behind the tip of the temporal lobe and in an area free of cortical vessels (Figures 2 and 3). The corticectomy is generally 2–2.5 cm in length. Guided by neuronavigation, dissection is performed toward the

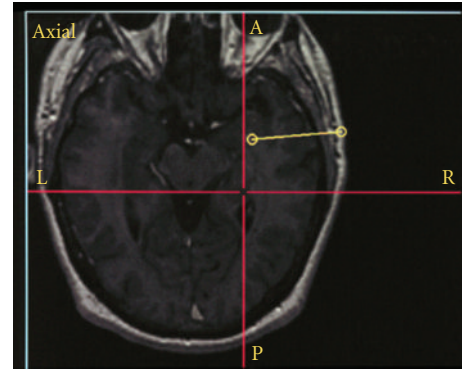


FIGURE 2: Intraoperative neuronavigation showing the entry point (lateral open circle), trajectory (yellow line), and target (medial open circle).

temporal horn until the temporal horn is entered (Figure 3). Two self-retaining brain retractors are placed to provide an optimal view of the intraventricular anatomy, and key anatomical structures are identified. The parahippocampal gyrus is resected beginning with subpial resection of the uncus and then advancing medially and posteriorly, with frequent confirmation of location using neuronavigation and care to preserve the mesial pial border. With resection of the anterior uncus, the incisura is visualized, and superiorly the internal carotid artery and third nerve can be seen through the pia. The choroidal fissure is identified. Care must be taken to insure that the dissection is not carried superior to the choroidal fissure. The hippocampus is then mobilized laterally and resected beginning anteriorly, with care to preserve the anterior choroidal artery, and carried posteriorly to the level of the tectal plate. Once the hippocampal resection is completed, the cerebral peduncle and anterior choroidal artery are visualized through the pia. Neuronavigation is used to confirm the completeness of the resection, and careful hemostasis is obtained.

In stepwise fashion the dura is closed, bone flap plated, temporalis muscle reapproximated, and scalp closed in layers to the skin. A postoperative neurological exam and head CT are performed, and care is taken to continue antiepileptic medications. Following overnight observation in a neurological intensive care unit, the patient completes a typically 3–4-day postoperative hospital stay before discharge to home.

Several alternatives to this middle temporal gyrus transcortical approach have been used. A minor variation with approach via the superior temporal sulcus was employed at the Montreal Neurological Institute [10].

Wieser and Yasargil [8] popularized a transsylvian approach and reported a large number of patients treated with this approach. The transsylvian approach avoids injury to the temporal neocortex and underlying white matter that is traversed in the transcortical approach and allows en bloc resections of the mesial temporal structures. However, it is generally regarded as being more technically difficult, allows limited surgical exposure, results in transection of the temporal stem, and poses a greater potential risk of

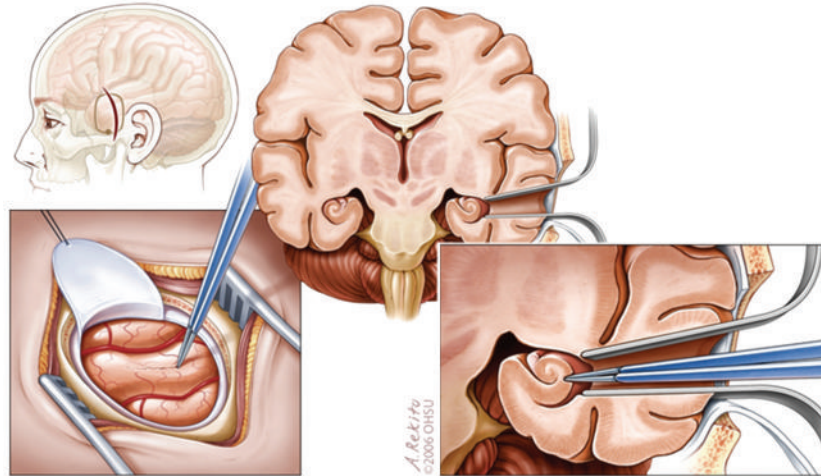


FIGURE 3: Transcortical amygdalohippocampectomy: position of craniotomy, position of cortical incision, surgical trajectory.

vascular injury or vasospasm [21], though this has rarely been reported in large surgical series [22].

A subtemporal approach has also been advocated [9, 23]. This largely avoids injury to Meyer's loop and resultant visual field defects that can occur with other approaches. There have been reports of fewer neuropsychological sequelae, but data are limited [24, 25]. This strategy carries disadvantages of potentially requiring excessive retraction of the temporal lobe, possible injury to the vein of Labbe, and may require removal of the zygomatic process.

5. Seizure Outcome

The ability of SAH to render patients seizure-free has been reported extensively in case series [15, 26–28], nonrandomized comparator trials with ATL [29–36], and comparator studies with historical controls [37].

Many centers exclusively employ one technique (ATL or SAH), making comparisons difficult. The existing nonrandomized comparator trials have a variety of methodological concerns, including comparison of noncontemporary groups as one procedure (ATL) was abandoned in favor of another (SAH), substantial risk of selection bias since patients were not randomized to procedure, and different neurosurgeons performing each procedure, or procedures being performed at different centers.

Overall, few differences in seizure-free outcomes based on choice of surgical procedure (ATL, SAH) have been demonstrated. Arruda and coworkers provided one of the earliest comparator trials of ATL and SAH [30]. They reported 74 patients, 37 of whom underwent each procedure. The groups were not randomized; however, different neurosurgeons preferred each procedure and selection of patients did not appear to be biased by clinical features. Both groups had equivalent seizure-free rates, and they concluded that the choice of procedure did not determine outcome; seizure freedom was better predicted by preoperative imaging findings and underlying pathology. More recent larger series have largely supported this conclusion. Clusmann et al.

reported 321 patients with TLE who underwent surgery, including ATL and SAH, and concluded that seizure outcome mainly correlated with diagnosis and clinical factors rather than resection type, and reaffirmed the strong correlation of MRI findings and underlying pathology with outcome [32]. Paglioli et al. compared a large non-contemporaneous group of 80 patients who underwent ATL and 81 who were treated with SAH with a mean followup of 5.8 years [34]. There were no significant group differences in outcome, except that fewer patients undergoing SAH were left with isolated auras. An early study by Mackenzie and coworkers was the exception: this study showed poorer outcomes following SAH [31]. Closer examination of patient selection reveals probable substantial selection bias. Patients with concordant findings on noninvasive evaluations underwent ATL, while SAH was performed only in a subset of more complex cases that underwent intracranial monitoring and that were more likely to have normal MRI findings.

Abosch and coworkers reported factors that might be predictive of failure to control seizures with SAH [15]. Many of the signs predictive of higher risk of surgical failure following SAH (bitemporal EEG findings, normal hippocampal volumes, use of intracranial monitoring) are not unique to this procedure and also predict lower success rates following ATL. In fact, those who underwent a second resection to extend the initial selective procedure largely continued to fare poorly [15].

There is little evidence to suggest that different approaches to SAH result in different seizure-free outcomes [38].

There are some small reports suggesting that seizure-free outcomes following SAH are less robust in children compared with adults [39, 40].

6. Neuropsychological Outcome

Neuropsychological outcome following SAH has been extensively reported in the literature. Often, the approach has been to report change scores before and after SAH [16, 41–43]. In some cases, attempts were made to compare to

cognitive outcomes following the “gold standard” procedure: ATL [19, 29, 32–34, 36, 44, 45]. Most of these direct comparator trials share similar methodological concerns with the seizure outcome comparator trials discussed above (noncontemporary cohorts, risk of selection bias, etc.). Further complexity is introduced by the nonuniform choice of cognitive assessments. Some studies focused on measures specifically targeted at anticipated deficits (e.g., verbal memory tests), others used extensive batteries of tests that run the risk of type I error, while others used general measures that may be insensitive to changes caused by surgery (e.g., IQ scores). It is important to keep in mind that an absence of demonstrated superior cognitive outcomes with the more selective procedure does not mean that it does not produce cognitive sparing; an alternative explanation is that the cognitive tests may be too insensitive to detect differences. Recent work has identified some previously unrecognized language areas in anterior temporal neocortex that could be at risk with a standard ATL procedure [46, 47], though the extent of functional sparing following SAH has been debated [48].

Many studies reported superiority of SAH compared with ATL in some aspects of postoperative cognitive performance [7, 8, 32, 49–51], but some showed substantially mixed findings or lack of superiority of more limited resection [36, 44, 52, 53]. Most of these studies still recognize the potential for meaningful cognitive declines following the more selective procedure, although there are exceptions [50, 54].

Some of the largest and most careful studies of cognitive outcome following SAH have come from the group in Bonn, Germany. Gleissner reported first 3-month and then 1-year findings in 140 patients who underwent SAH [16, 42]. They noted that the more selective procedure can have important cognitive consequences: at the 3-month time point, nearly half of the left SAH patients showed substantial loss of verbal memory; functional declines were less common with right-sided operations. Of the 115 who were studied at one year, there was no substantial recovery of verbal memory from the earlier time point. Preoperative performance was the primary predictor of postoperative performance at 1 year. Paglioli and coworkers’ study of 80 patients who underwent ATL and 81 submitted to SAH (nonrandomized, noncontemporaneous) similarly found that patients who underwent either procedure were at risk of verbal memory decline if surgery was carried out in the dominant temporal lobe; however, a greater proportion of left SAH patients had improved verbal memory after surgery compared with the left ATL procedure [34]. The large study of Clusmann reported better outcome following SAH for attention, verbal memory, and a composite of total neuropsychological performance [32]. Tanriverdi and coworkers compared a large number of SAH ($n = 133$) and ATL ($n = 123$) patients, found mixed cognitive results, and concluded that, although both surgeries are effective, they both have the potential to cause cognitive deficits [36].

Although accumulated evidence reviewed above suggests a potential cognitive benefit of the more selective procedure (SAH), it also provides ample evidence that the more

selective approach does not obviate the need for careful preoperative cognitive assessment, particularly with respect to risk of verbal memory worsening following dominant temporal lobe SAH. An important conclusion from a large series reporting neuropsychological outcomes following SAH was “Our data clearly show that this does not mean no or only very mild memory declines after SAH” [42]. Much as with ATL, the risk to verbal memory probably depends largely on the functional adequacy of the resected tissue, the cognitive reserve (perhaps related in part to age and duration of epilepsy), and the success in obtaining seizure freedom.

There have been some attempts to discern differential cognitive outcomes with different SAH surgical approaches [24, 25, 27, 38]. In theory, transcortical SAH can disrupt and disconnect fiber tracts, as demonstrated on diffusion tensor imaging by studying the path of a “virtual SAH” [55]. However, in most reports, methodological concerns and small numbers of patients limit the conclusions that can be drawn. The report of Lutz et al. is an exception [38]. This is a relatively large ($N = 140$) randomized prospective trial of transylvian versus transcortical SAH in a uniform population of patients with presumed mesial temporal sclerosis. Few differences were found in the proportions of patients in each group with neuropsychological improvement or worsening on postoperative neuropsychological tests, and left-sided surgeries resulted in worsening of verbal memory regardless of approach. The exception was word fluency, which improved in the transcortical but not transylvian group.

7. Surgical Complications

The visual field deficits seen following ATL can also be seen with SAH, depending on the surgical approach, though they may be less severe following the more selective procedure [56, 57].

Potential complications include the following:

- (i) hemorrhage,
- (ii) infarction (commonly of deep penetrating vessels leading to lacunar stroke),
- (iii) infection,
- (iv) incomplete resection,
- (v) variable contralateral homonymous superior quadrant visual field defect from injury to Meyer’s loop (usually asymptomatic),
- (vi) memory impairment,
- (vii) transient dysnomia,
- (viii) mood changes.

Strict adherence to time out procedures, careful patient positioning, and careful visual identification of landmarks and repeated reconfirmation of stereotactic findings can minimize intraoperative complications. Detailed knowledge of the mesial temporal anatomy is critical, and such understanding will avoid the potential perils of overreliance on imagingbased neuronavigation systems. Attention to careful

patient selection and preoperative testing can minimize risk to memory and risk of mood disturbances and can maximize efficacy by excluding inappropriate patients.

8. Conclusions

Selective amygdalohippocampectomy has emerged as a viable alternative to standard anterior temporal lobectomy in patients with refractory TLE of mesial temporal origin. Success rates are highest if strict criteria are employed to determine suitable candidates. Progress in surgical technology including image-guided stereotactic surgery has made SAH more accessible and effective. In carefully selected candidates, seizure-free outcomes following SAH are comparable to ATL. While attention needs to be paid to risk of neuropsychological morbidity, particularly with respect to verbal memory, most studies suggest that there is benefit to sparing temporal neocortex in the surgical treatment of mTLE.

Acknowledgment

The authors would like to thank Andy Rekito for permission to use the illustrations included in this paper.

References

- [1] World Health Organization, *Neurological Disorders: Public Health Challenges*, WHO Press, Geneva, Switzerland, 2006.
- [2] S. Wiebe, W. T. Blume, J. P. Girvin, and M. Eliasziw, "A randomized, controlled trial of surgery for temporal-lobe epilepsy," *New England Journal of Medicine*, vol. 345, no. 5, pp. 311–318, 2001.
- [3] D. D. Spencer, S. S. Spencer, and R. H. Mattson, "Access to the posterior medial temporal lobe structures in the surgical treatment of temporal lobe epilepsy," *Neurosurgery*, vol. 15, no. 5, pp. 667–671, 1984.
- [4] D. D. I. J. Spencer, "Temporal lobectomy," in *Epilepsy Surgery*, H. Luders, Ed., pp. 533–545, Raven Press, New York, NY, USA, 1991.
- [5] P. Niemeyer, "The transventricular amygdalohippocampectomy in temporal lobe epilepsy," in *Temporal Lobe Epilepsy*, M. Baldwin and P. Bailey, Eds., pp. 461–482, Charles Thomas, Springfield, Mass, USA, 1958.
- [6] D. D. Cavalcanti, J. A. D. Guasti, and M. C. Preul, "Neurological and architectural sinuities: the niemeyer brothers," *Neurosurgery*, vol. 67, no. 5, pp. 1167–1179, 2010.
- [7] H. G. Wieser and M. G. Yasargil, "Selective amygdalohippocampectomy as a surgical treatment of mesiobasal limbic epilepsy," *Surgical Neurology*, vol. 17, no. 6, pp. 445–457, 1982.
- [8] M. G. Yaşargil, H. G. Wieser, A. Valavanis, K. von Ammon, and P. Roth, "Surgery and results of selective amygdalohippocampectomy in one hundred patients with nonlesional limbic epilepsy," *Neurosurgery Clinics of North America*, vol. 4, no. 2, pp. 243–261, 1993.
- [9] T. S. Park, B. F. D. Bourgeois, D. L. Silbergeld, and W. E. Dodson, "Subtemporal transparahippocampal amygdalohippocampectomy for surgical treatment of mesial temporal lobe epilepsy: technical note," *Journal of Neurosurgery*, vol. 85, no. 6, pp. 1172–1176, 1996.
- [10] A. Olivier, "Relevance of removal of limbic structures in surgery for temporal lobe epilepsy," *Canadian Journal of Neurological Sciences*, vol. 18, no. 4, supplement, pp. 628–635, 1991.
- [11] A. S. Little, K. A. Smith, K. Kirlin et al., "Modifications to the subtemporal selective amygdalohippocampectomy using a minimal-access technique: seizure and neuropsychological outcomes," *Journal of Neurosurgery*, vol. 111, no. 6, pp. 1263–1274, 2009.
- [12] P. Kwan and M. J. Brodie, "Early identification of refractory epilepsy," *New England Journal of Medicine*, vol. 342, no. 5, pp. 314–319, 2000.
- [13] A. T. Berg and M. M. Kelly, "Defining intractability: comparisons among published definitions," *Epilepsia*, vol. 47, no. 2, pp. 431–436, 2006.
- [14] J. S. Duncan, "Epilepsy surgery," *Clinical Medicine, Journal of the Royal College of Physicians of London*, vol. 7, no. 2, pp. 137–142, 2007.
- [15] A. Abosch, N. Bernasconi, W. Boling et al., "Factors predictive of suboptimal seizure control following selective amygdalohippocampectomy," *Journal of Neurosurgery*, vol. 97, no. 5, pp. 1142–1151, 2002.
- [16] U. Gleissner, C. Helmstaedter, J. Schramm, and C. E. Elger, "Memory outcome after selective amygdalohippocampectomy: a study in 140 patients with temporal lobe epilepsy," *Epilepsia*, vol. 43, no. 1, pp. 87–95, 2002.
- [17] D. W. Loring, G. P. Lee, K. J. Meador et al., "The intracarotid amobarbital procedure as a predictor of memory failure following unilateral temporal lobectomy," *Neurology*, vol. 40, no. 4, pp. 605–610, 1990.
- [18] J. N. Acharya and D. S. Dinner, "Use of the intracarotid amobarbital procedure in the evaluation of memory," *Journal of Clinical Neurophysiology*, vol. 14, no. 4, pp. 311–325, 1997.
- [19] M. E. Lacruz, G. Alarcón, N. Akanuma et al., "Neuropsychological effects associated with temporal lobectomy and amygdalohippocampectomy depending on Wada test failure," *Journal of Neurology, Neurosurgery and Psychiatry*, vol. 75, no. 4, pp. 600–607, 2004.
- [20] M. Reuber, M. Kurthen, G. Fernández, J. Schramm, and C. E. Elger, "Epilepsy surgery in patients with additional psychogenic seizures," *Archives of Neurology*, vol. 59, no. 1, pp. 82–86, 2002.
- [21] C. Schaller, A. Jung, H. Clusmann, J. Schramm, and B. Meyer, "Rate of vasospasm following the transylvian versus transcortical approach for selective amygdalohippocampectomy," *Neurological Research*, vol. 26, no. 6, pp. 666–670, 2004.
- [22] M. G. Yaşargil, N. Kraysenbühl, P. Roth, S. P. C. Hsu, and D. C. H. Yaşargil, "The selective amygdalohippocampectomy for intractable temporal limbic seizures: historical vignette," *Journal of Neurosurgery*, vol. 112, no. 1, pp. 168–185, 2010.
- [23] T. Hori, S. Tabuchi, M. Kurosaki et al., "Subtemporal amygdalohippocampectomy for treating medically intractable temporal lobe epilepsy," *Neurosurgery*, vol. 33, no. 1, pp. 50–57, 1993.
- [24] T. Hori, F. Yamane, T. Ochiai, M. Hayashi, and T. Taira, "Subtemporal amygdalohippocampectomy prevents verbal memory impairment in the language-dominant hemisphere," *Stereotactic and Functional Neurosurgery*, vol. 80, no. 1–4, pp. 18–21, 2003.
- [25] S. Takaya, N. Mikuni, T. Mitsueda et al., "Improved cerebral function in mesial temporal lobe epilepsy after subtemporal amygdalohippocampectomy," *Brain*, vol. 132, no. 1, pp. 185–194, 2009.
- [26] H. G. Wieser and A. Häne, "Antiepileptic drug treatment before and after selective amygdalohippocampectomy," *Epilepsy Research*, vol. 55, no. 3, pp. 211–223, 2003.

- [27] T. Hori, F. Yamane, T. Ochiai et al., "Selective subtemporal amygdalohippocampectomy for refractory temporal lobe epilepsy: operative and neuropsychological outcomes," *Journal of Neurosurgery*, vol. 106, no. 1, pp. 134–141, 2007.
- [28] G. Acar, F. Acar, J. Miller, D. C. Spencer, and K. J. Burchiel, "Seizure outcome following transcortical selective amygdalohippocampectomy in mesial temporal lobe epilepsy," *Stereotactic and Functional Neurosurgery*, vol. 86, no. 5, pp. 314–319, 2008.
- [29] S. A. Renowden, Z. Matkovic, C. B. T. Adams et al., "Selective amygdalohippocampectomy for hippocampal sclerosis: post-operative MR appearance," *American Journal of Neuroradiology*, vol. 16, no. 9, pp. 1855–1861, 1995.
- [30] F. Arruda, F. Cendes, F. Andermann et al., "Mesial atrophy and outcome after amygdalohippocampectomy or temporal lobe removal," *Annals of Neurology*, vol. 40, no. 3, pp. 446–450, 1996.
- [31] R. A. Mackenzie, J. Matheson, M. Ellis, and J. Klamus, "Selective versus non-selective temporal lobe surgery for epilepsy," *Journal of Clinical Neuroscience*, vol. 4, no. 2, pp. 152–154, 1997.
- [32] H. Clusmann, J. Schramm, T. Kral et al., "Prognostic factors and outcome after different types of resection for temporal lobe epilepsy," *Journal of Neurosurgery*, vol. 97, no. 5, pp. 1131–1141, 2002.
- [33] M. Morino, T. Uda, K. Naito et al., "Comparison of neuropsychological outcomes after selective amygdalohippocampectomy versus anterior temporal lobectomy," *Epilepsy and Behavior*, vol. 9, no. 1, pp. 95–100, 2006.
- [34] E. Paglioli, A. Palmi, M. Portuguez et al., "Seizure and memory outcome following temporal lobe surgery: selective compared with nonselective approaches for hippocampal sclerosis," *Journal of Neurosurgery*, vol. 104, no. 1, pp. 70–78, 2006.
- [35] T. Tanriverdi, A. Olivier, N. Poulin, F. Andermann, and F. Dubeau, "Long-term seizure outcome after mesial temporal lobe epilepsy surgery: corticoamygdalohippocampectomy versus selective amygdalohippocampectomy," *Journal of Neurosurgery*, vol. 108, no. 3, pp. 517–524, 2008.
- [36] T. Tanriverdi, R. W. R. Dudley, A. Hasan et al., "Memory outcome after temporal lobe epilepsy surgery: corticoamygdalohippocampectomy versus selective amygdalohippocampectomy—clinical article," *Journal of Neurosurgery*, vol. 113, no. 6, pp. 1164–1175, 2010.
- [37] H. G. Wieser, M. Ortega, A. Friedman, and Y. Yonekawa, "Long-term seizure outcomes following amygdalohippocampectomy," *Journal of Neurosurgery*, vol. 98, no. 4, pp. 751–763, 2003.
- [38] M. T. Lutz, H. Clusmann, C. E. Elger, J. Schramm, and C. Helmstaedter, "Neuropsychological outcome after selective amygdalohippocampectomy with transylvian versus transcortical approach: a randomized prospective clinical trial of surgery for temporal lobe epilepsy," *Epilepsia*, vol. 45, no. 7, pp. 809–816, 2004.
- [39] H. Clusmann, T. Kral, U. Gleissner et al., "Analysis of different types of resection for pediatric patients with temporal lobe epilepsy," *Neurosurgery*, vol. 54, no. 4, pp. 847–860, 2004.
- [40] A. Datta, D. B. Sinclair, M. Wheatley et al., "Selective amygdalohippocampectomy: surgical outcome in children versus adults," *Canadian Journal of Neurological Sciences*, vol. 36, no. 2, pp. 187–191, 2009.
- [41] L. Bartha, E. Trinka, M. Ortler et al., "Linguistic deficits following left selective amygdalohippocampectomy: a prospective study," *Epilepsy and Behavior*, vol. 5, no. 3, pp. 348–357, 2004.
- [42] U. Gleissner, C. Helmstaedter, J. Schramm, and C. E. Elger, "Memory outcome after selective amygdalohippocampectomy in patients with temporal lobe epilepsy: one-year follow-up," *Epilepsia*, vol. 45, no. 8, pp. 960–962, 2004.
- [43] M. Morino, T. Ichinose, T. Uda, K. Kondo, S. Ohfuji, and K. Ohata, "Memory outcome following transylvian selective amygdalohippocampectomy in 62 patients with hippocampal sclerosis: clinical article," *Journal of Neurosurgery*, vol. 110, no. 6, pp. 1164–1169, 2009.
- [44] L. H. Goldstein and C. E. Polkey, "Short-term cognitive changes after unilateral temporal lobectomy or unilateral amygdalo-hippocampectomy for the relief of temporal lobe epilepsy," *Journal of Neurology Neurosurgery and Psychiatry*, vol. 56, no. 2, pp. 135–140, 1993.
- [45] C. Helmstaedter, S. Richter, S. Röske, F. Oltmanns, J. Schramm, and T. N. Lehmann, "Differential effects of temporal pole resection with amygdalohippocampectomy versus selective amygdalohippocampectomy on material-specific memory in patients with mesial temporal lobe epilepsy," *Epilepsia*, vol. 49, no. 1, pp. 88–97, 2008.
- [46] M. J. Hamberger, W. T. Seidel, R. R. Goodman, K. Perrine, and G. M. McKhann, "Temporal lobe stimulation reveals anatomic distinction between auditory naming processes," *Neurology*, vol. 60, no. 9, pp. 1478–1483, 2003.
- [47] M. J. Hamberger, S. McClelland, G. M. McKhann, A. C. Williams, and R. R. Goodman, "Distribution of auditory and visual naming sites in nonlesional temporal lobe epilepsy patients and patients with space-occupying temporal lobe lesions," *Epilepsia*, vol. 48, no. 3, pp. 531–538, 2007.
- [48] S. Dupont, A. C. Croizé, F. Semah et al., "Is amygdalohippocampectomy really selective in medial temporal lobe epilepsy? A study using positron emission tomography with fluorodeoxyglucose," *Epilepsia*, vol. 42, no. 6, pp. 731–740, 2001.
- [49] C. Helmstaedter, T. Grunwald, K. Lehnertz, U. Gleißner, and C. E. Elger, "Differential involvement of left temporolateral and temporomesial structures in verbal declarative learning and memory: evidence from temporal lobe epilepsy," *Brain and Cognition*, vol. 35, no. 1, pp. 110–131, 1997.
- [50] E. Pauli, S. Pickel, H. Schülemann, M. Buchfelder, and H. Stefan, "Neuropsychologic findings depending on the type of the resection in temporal lobe epilepsy," *Advances in Neurology*, vol. 81, pp. 371–377, 1999.
- [51] C. Helmstaedter, M. Reuber, and C. C. E. Elger, "Interaction of cognitive aging and memory deficits related to epilepsy surgery," *Annals of Neurology*, vol. 52, no. 1, pp. 89–94, 2002.
- [52] R. L. Wolf, R. J. Ivnik, K. A. Hirschorn, F. W. Sharbrough, G. D. Cascino, and W. R. Marsh, "Neurocognitive efficiency following left temporal lobectomy: standard versus limited resection," *Journal of Neurosurgery*, vol. 79, no. 1, pp. 76–83, 1993.
- [53] M. Jones-Gotman, R. J. Zatorre, A. Olivier et al., "Learning and retention of words and designs following excision from medial or lateral temporal lobe structures," *Neuropsychologia*, vol. 35, no. 7, pp. 963–973, 1997.
- [54] H. G. Wieser, "Selective amygdalo-hippocampectomy for temporal lobe epilepsy," *Epilepsia*, vol. 29, supplement 2, pp. S100–S113, 1988.

- [55] S. Colnat-Coulbois, K. Mok, D. Klein, S. Pénicaud, T. Tanriverdi, and A. Olivier, “Tractography of the amygdala and hippocampus: anatomical study and application to selective amygdalohippocampectomy—laboratory investigation,” *Journal of Neurosurgery*, vol. 113, no. 6, pp. 1135–1143, 2010.
- [56] R. A. Egan, W. T. Shults, N. So, K. Burchiel, J. X. Kellogg, and M. Salinsky, “Visual field deficits in conventional anterior temporal lobectomy versus amygdalohippocampectomy,” *Neurology*, vol. 55, no. 12, pp. 1818–1822, 2000.
- [57] T. Mengesha, M. Abu-Ata, K. F. Haas et al., “Visual field defects after selective amygdalohippocampectomy and standard temporal lobectomy,” *Journal of Neuro-Ophthalmology*, vol. 29, no. 3, pp. 208–213, 2009.