

CASE REPORT

Oral hyperpigmentation associated with hydroxyurea in a patient with polycythemia vera: A case report

Baneen Alshammasi¹ | Zainab Albasry² | Fatimah Meshikhes³ ¹Private Practice, Khobar, Saudi Arabia²College of Dentistry, Imam Abdulrahman Bin Faisal University, Dammam, Saudi Arabia³Dental Section, King Fahad Specialist Hospital, Dammam, Saudi Arabia**Correspondence**Fatimah Meshikhes, Dental Section, King Fahad Specialist Hospital, Dammam, 32253, Saudi Arabia.
Email: f.meshikhes@gmail.com**Abstract**

Patients may report to health practitioners with unusual symptoms that necessitate a thorough examination and review of underlying medical conditions and medications for rare side effects. Hence, it is crucial to report such rare cases to raise awareness and increase the related body of knowledge. Hydroxyurea-associated oral hyperpigmentation has been reported.

KEY WORDS

hydroxyurea, oral hyperpigmentation, polycythemia vera, side effects

1 | INTRODUCTION

Polycythemia vera (PV) is the most common type of myeloproliferative neoplasms (MPNs), accounting for approximately 45% of cases.¹ It is associated with erythrocytosis, leukocytosis, and increased hematocrit, which can increase the risk of thrombosis.² Hydroxyurea (HU) was first approved by the FDA in December 1967.³ Over the next several decades, and owing to its efficacy as an antineoplastic agent, HU use expanded to include the management of PV.^{4,5} According to European Leukemia Net guidelines, HU and recombinant interferon alpha (rIFN α) are the recommended first-line cytoreductive therapies for patients with high-risk PV.⁶

Hydroxyurea is an antimetabolite drug that is used for the management of multiple diseases, but mainly myeloproliferative disorders, such as PV and chronic myeloid leukemia.⁶ It acts by inactivating ribonucleotide reductase and inhibiting DNA synthesis, thereby slowing cell division, causing a reduction in the overall production of blood cells in the bone marrow, hence minimizing the incidence of thrombosis.⁷

Several mucocutaneous lesions have been reported as side effects of HU, mainly noted as skin and mucosal atrophies,

as well as dark hyperpigmentation of skin folds, mucosa, and nails.⁸ Oral manifestations are generally rare, predominantly manifesting as ulcers, erythema, and depapillation of the tongue.⁸ Oral pigmentation is rare and infrequently reported; only 9 cases have been reported to date, and the majority (89%) occurred following HU treatment for conditions other than PV.⁹

Herein, we have described the case of a woman who developed oral hyperpigmentation 6 months after starting HU treatment for PV. The aim of this report was to increase healthcare professionals' awareness of this rare side effect.

2 | CASE HISTORY

A 67-year-old Saudi female patient presented to the periodontics dental clinic complaining of gingival enlargement and bleeding, as well as multiple areas of oral hyperpigmentation. The patient was known to have JAK 2 +ve PV in addition to hypertension and type II diabetes mellitus. She reported that she noticed the oral changes 6 months after starting HU therapy (hydroxyurea, 500 mg capsule). The patient was also

This is an open access article under the terms of the Creative Commons Attribution-NonCommercial License, which permits use, distribution and reproduction in any medium, provided the original work is properly cited and is not used for commercial purposes.

© 2020 The Authors. *Clinical Case Reports* published by John Wiley & Sons Ltd.

on the following medications: aspirin 100 mg, metformin 500 mg, glimepiride 2 mg, rosuvastatin 20 mg, valsartan 80 mg, and amlodipine 5 mg tablets. She had never smoked and had no known allergies. Her family and psychosocial history were noncontributory. In the past, she had attended the dental clinic for multiple restorative, endodontic treatments, and some uncomplicated extractions; oral pigmented lesions were not reported in her medical records.

Clinical examination revealed brown patches on the hands, arm, and the dorsal surface of feet and hyperpigmented longitudinal bands on the fingernails, while toenails were almost completely blackened (Figures 1 and 2). Multiple rounded perioral lesions of <0.5 cm were observed on her facial skin.

Intraorally, light brown pigmentations were noted bilaterally on the buccal mucosa, as well as multiple asymptomatic brown hyperpigmented patches that involved both the buccal mucosa and gingiva (Figure 3). Pigmentations were also observed on the mid-hard palate and dorsal surface of the tongue (Figure 4). Moreover, localized gingival enlargement was visible, mostly in the maxillary and mandibular anterior areas (Figure 5). The intraoral findings are detailed in Table 1. All routine blood investigations, including red blood cell and platelet counts, were normal.

An initial clinical diagnosis of drug-induced oral hyperpigmentation was made. A review of the currently used medications and their side effects was performed to determine whether any of the medications contributed to the patient's condition. Only HU was identified as related to oral hyperpigmentation.

The oral findings, except gingival enlargement, were all attributed to HU therapy. As they were completely asymptomatic, the patient was reassured and was placed on regular

follow-up. The gingival enlargement, which was attributed to the antihypertensive drug amlodipine, was treated by routine periodontal therapy, which comprised nonsurgical mechanical debridement, oral home-care instructions, and prescription mouthwash. Contact was made with the patient's physician to consider using an alternative antihypertensive medication. During follow-up, there was no noticeable progression or change in the status of the pigmentations over a 12-month period.

3 | DISCUSSION

Although HU therapy is considered safe, it could be associated with many side effects, such as nail changes mainly noted as melanonychia, skin hyperpigmentation, and mucocutaneous ulcerations of the oral cavity.^{9,10} The prevalence of melanonychia is reported to be 1% in the general population,¹⁰ whereas the estimated risk in patients receiving HU is 3.4%, with the condition more often observed in female patients.¹¹ The reported occurrence of HU-associated skin hyperpigmentation and melanonychia ranged from 7 weeks to 5 years after the initiation of HU therapy.¹² However, these manifestations were neither dose-dependent nor related to the duration of therapy.¹³

Although HU-associated oral hyperpigmentation is extremely rare, a systematic review showed that patients receiving imatinib mesylate therapy and HU for >30 days had a 1.43-fold higher total oral hyperpigmentation score compared with those receiving HU for <30 days. The results of this cross-sectional study supported that hyperpigmentation extent and intensity were related to IM use especially when

FIGURE 1 The right and left hands show hyperpigmented longitudinal bands in the nails (white arrows)

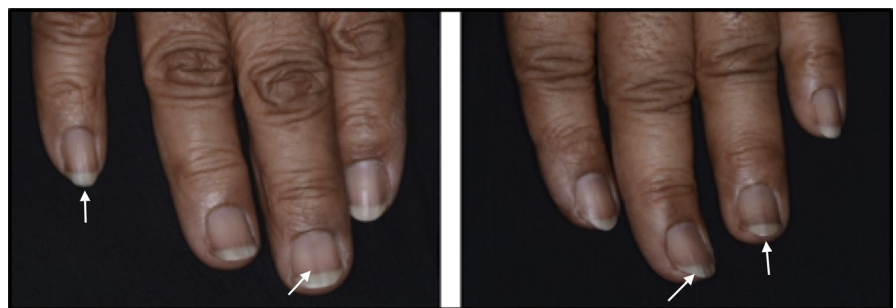
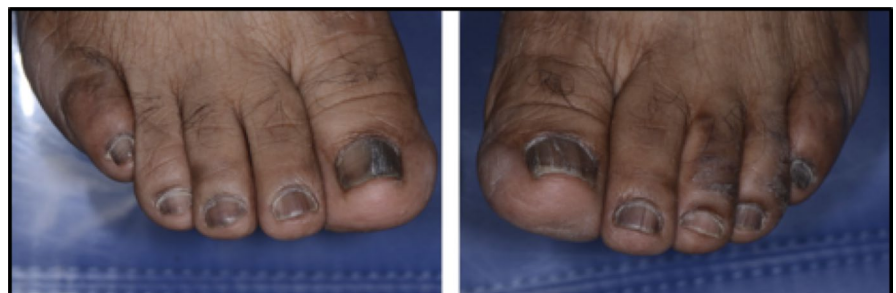
FIGURE 2 The right and left feet show hyperpigmentation of the toenails; the nail beds are almost completely blackened



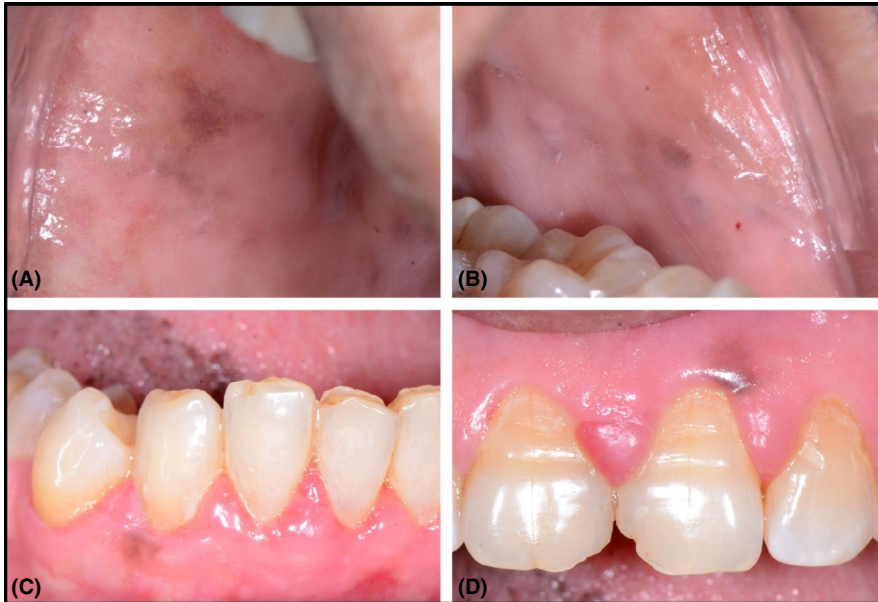

FIGURE 3 Intraoral hyperpigmentation: (A) right buccal mucosa; (B) left buccal mucosal (C) at the site of mandibular right canine; (D) at the site of maxillary left central incisor

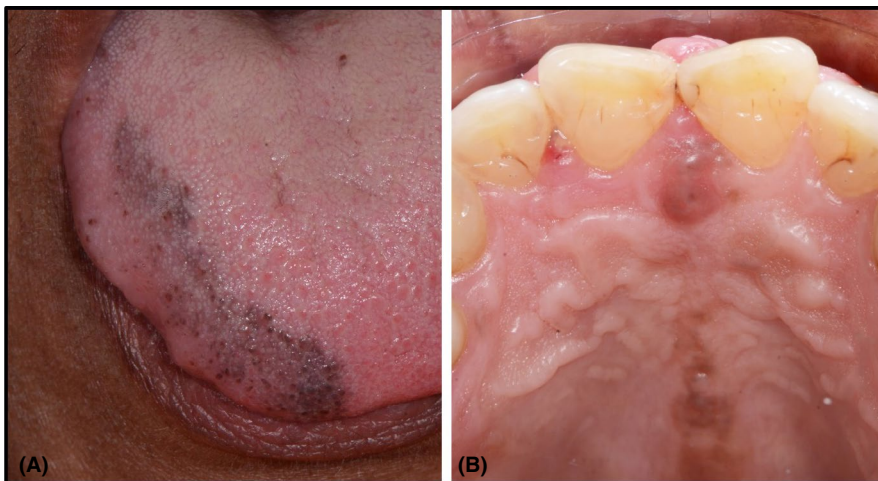


FIGURE 4 Intraoral hyperpigmentation: (A) tongue, (B) median palatine raphe, and incisive papilla

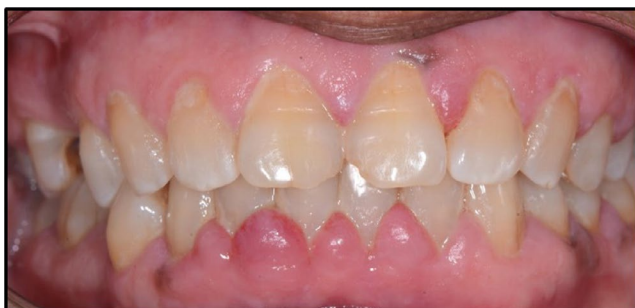

FIGURE 5 Gingival enlargement

combined with HU. However, the exact duration of use and dosage of both drugs were not determined in the study.¹⁴

Our literature search revealed only nine reports of HU-associated oral pigmentation (four female patients and five male patients; eight adults and one child).^{9,15-22} The age of the affected individuals ranged between 10 and 68 years (mean, 50.6 years of age). HU was administered for a variety of clinical conditions: leukemia (n = 3), essential

thrombocythemia (n = 3), psoriasis (n = 1), PV (n = 1), and HIV (n = 1). Similar to our case, all patients developed concomitant cutaneous changes and oral pigmentations that appeared in different intraoral sites, mainly the buccal mucosa and tongue (Table 2). The appearance of oral hyperpigmentation after starting HU therapy was variable, ranging from 1 month to 4.5 years.^{9,15-22} Our case exhibited a variety of oral hyperpigmentation, affecting not only the buccal mucosa and tongue, but also the gingiva and hard palate. These were noted 6 months after the start of HU therapy.

To the best of our knowledge, no histopathological studies have explained the site predilection of oral hyperpigmentation induced by HU. Although two reports disclosed that hyperpigmentation was noted on the buccal mucosa, seven previous cases, in addition to the current clinical report, showed that mucosal pigmentation occurred mostly on the tongue.^{9,15-22} One study postulated that pigmentation on the tongue due to HU reflected postinflammatory hypermelanosis after the resolution of mucositis.²³ Furthermore, this is the

TABLE 1 Detailed description of intraoral hyperpigmentation

Site	Description
Gingiva	<ul style="list-style-type: none"> • Brown oval patch on the marginal gingival tissue extending to the attached gingiva at the area of maxillary left central incisor measuring approximately 2 × 4 mm. • Brownish well-circumscribed patch on the marginal gingiva of the right mandibular canine measuring approximately 2 mm in diameter. • Brown grayish patch located on the interdental papilla between the mandibular left first and second premolars.
Tongue	Brown grayish patch on the right dorsal surface of the tongue not crossing the midline.
Hard palate	Brown patch on the incisive papilla extending along the median palatine raphe.
Buccal mucosa	Bilateral brownish patches involving both anterior and posterior mucosal tissues.

first case report of HU-associated hyperpigmentation affecting the palatal mucosa and gingiva.

Unfortunately, the exact mechanism is not fully understood, although genetic predisposition is implicated as a factor.²⁴ Multiple hypotheses have been proposed for the pathogenesis of skin pigmentations: photosensitivity, direct toxic effects, deposition of HU at the matrix level, or focal stimulation of melanocytes.^{25,26}

It is worth noting that several other drugs cause oral hyperpigmentation. Such drugs include chemotherapeutic agents, such as cyclophosphamide, busulfan, bleomycin, and fluorouracil; oral contraceptives; antimicrobial agents, such as minocycline; antifungals, such as ketoconazole; hormones; and tranquilizers.²⁷

Hyperpigmentation in the oral cavity has been also attributed to many reasons other than medication, such as physiologic pigmentation and various reactive, inflammatory, and

TABLE 2 List of nine reported cases of hydroxyurea-associated oral hyperpigmentation

Author	Age	Gender	Dosage	Duration	Indication for HU	Sites of hyperpigmentation
Majumdar et al ⁶	61	Male	9 g/d	4 y	CGL	Skin mainly over the palmar creases and the forehead, and the buccal mucosa
Gropper et al ⁷	63	Female	500 mg–1.5 g/d	8 mo	PV	Nails, skin, and buccal mucosa.
Laughon et al ⁸	51	Female	Not mentioned	1 mo	HIV	Nails, hands, feet, tongue, and the buccal mucosa
Nofal and El-Din ¹¹	68	Female	1-1.5 g/d	9 y	CML	Skin, nails, and tongue
Issaivanan et al ¹⁰	10	Male	40 mg/kg/d	3 mo	CML	Skin, nails, and tongue
Kumar et al ⁹	24-75	24 Males, 6 Females	1-1.5 g/d	6-120 wks	Psoriasis	Skin, nails, and gray patches on the tongue
Murray et al ¹²	63	Male	Not mentioned	2 y for skin lesions 4.5 y for oral lesions	ET	Skin, nails, mainly as longitudinal melanonychia, and brown macules of the tongue
Calleja Algarra et al ¹³	45	Male	Not mentioned	1 y	ET	Skin, nails, and tongue
Veillet-Lemay and Haber ¹⁴	44	Female	1 g/d	1.5 y	ET	Nails and tongue
Current case	67	Female	500 mg/d	1.5 y	PV	Skin, nails, tongue, buccal mucosa, hard palate, and gingiva.

Abbreviations: CGL, chronic granulocytic leukemia; CML, chronic myeloid leukemia; ET, essential thrombocythemia; HIV, human immunodeficiency virus; PV, polycythemia vera.

neoplastic lesions.²⁴ In one case, a biopsy of the pigmented area was performed to exclude melanoma.²¹ The diagnosis of oral pigmentation can be confusing and difficult, especially in cases where the pathogenesis of such an incidence is not yet very well clarified. Thus, a biopsy and histopathological evaluation might be necessary to rule out any serious conditions and confirm the final diagnosis. Having knowledge of the potential rare side effects of current and previous medications and correlating them with clinical history reduce the need for the patient to undergo potential uncomfortable procedures.

HU-associated hyperpigmentation does not require specific treatment and does not necessitate HU cessation or commencement of other medications. However, the presence of systemic oral ulcerations may be an indication for discontinuation of therapy and substitution with imatinib mesylate in cases of myeloid leukemia.²⁸ It appears that our case is probably the tenth case of oral hyperpigmentation due to HU therapy and the second case of oral hyperpigmentation in a patient with PV receiving HU therapy reported in the literature.

This case report aimed to increase physicians' and dentists' awareness of rare HU-associated side effects such as oral hyperpigmentation. This pigmentation may appear weeks or even years after treatment is started. It is asymptomatic, but may often cause undue anxiety in patients and is alarming to unwary healthcare practitioners. Awareness of this presentation allays the patient's anxiety and averts the cessation of treatment and potential unnecessary investigations.

Physicians must be aware that HU-associated oral hyperpigmentation is usually benign and asymptomatic; hence, cessation of HU is unnecessary as long as the patient's underlying condition is well-controlled by HU therapy.

ACKNOWLEDGMENTS

The authors would like to acknowledge Dr Abdulwahed Meshikhes for his valuable help and advice in the preparation of this report.

CONFLICT OF INTEREST

The authors declare no conflicts of interest.

AUTHOR CONTRIBUTIONS

BA: contributed to this manuscript by participating in the initial diagnosis of the patient, researching the background, and collecting information for the case report. ZA: contributed to this manuscript by researching other cases of hyperpigmentation due to hydroxyurea and drafting the discussion. FM: (corresponding author) is in charge of the patient's care; initially diagnosed the patient and has been performing the follow-up care; collected the clinical data and obtained clinical images; contributed to the formatting of the manuscript; and had overall supervision of the process. All authors: reviewed and approved the final manuscript.

ETHICAL APPROVAL

Written consent to participate and for publication was obtained from the patient as per King Fahad Specialist Hospital regulations by using the institute's form and is available upon request. The final manuscript was reviewed by the IRB of King Fahad Specialist Hospital, and written approval for publication was obtained.

ORCID

Fatimah Meshikhes  <https://orcid.org/0000-0003-4715-1538>

REFERENCES

1. Rollison DE, Howlader N, Smith MT, et al. Epidemiology of myelodysplastic syndromes and chronic myeloproliferative disorders in the United States, 2001–2004, using data from the NAACCR and SEER programs. *Blood*. 2008;112(1):45-52.
2. Barbui T, Finazzi G, Falanga A. Myeloproliferative neoplasms and thrombosis. *Blood*. 2013;122(13):2176-2184.
3. Drugs@FDA: FDA-Approved Drugs. 1967. <https://www.accessdata.fda.gov/scripts/cder/daf/index.cfm?event=reportsSearch.process&rptName=0&reportSelectMonth=12&reportSelectYear=1967&nav>. Accessed March, 21 2020.
4. McGann PT, Ware RE. Hydroxyurea therapy for sickle cell anemia. *Expert Opin Drug Saf*. 2015;14(11):1749-1758.
5. West WO. Hydroxyurea in the treatment of polycythemia vera: A prospective study of 100 patients over a 20-year period. *South Med J*. 1987;80(3):323-327.
6. Barbui T, Barosi G, Birgegard G, et al. Philadelphia-negative classical myeloproliferative neoplasms: critical concepts and management recommendations from European LeukemiaNet. *J Clin Oncol*. 2011;29(6):761-770.
7. Yarbrow JW. Mechanism of action of hydroxyurea. *Semin Oncol*. 1992;19(3 Suppl 9):1-10.
8. Vassallo C, Passamonti F, Merante S, et al. Mucocutaneous changes during long-term therapy with hydroxyurea in chronic myeloid leukaemia. *Clin Exp Dermatol*. 2001;26(2):141-148.
9. Veillet-Lemay G, Haber RM. Hydroxyurea-induced oral hyperpigmentation: a case report and review of the literature. *J Cutan Med Surg*. 2019;23(1):111-113.
10. Murray NP, Tapia P, Porcell J, Echavarría M, Suazo H. Acquired melanonychia in Chilean patients with essential thrombocythemia treated with hydroxyurea: a report of 7 clinical cases and review of the literature. *ISRN Dermatol*. 2013;2013:325246.
11. Nguyen AL, Körver JE, Theunissen CCW. Longitudinal melanonychia on multiple nails induced by hydroxyurea. *BMJ Case Rep*. 2017;2017:bcr2016218644.
12. Karanth SS, Gupta A, Prabhu MM. Melanonychia and mucocutaneous hyperpigmentation from hydroxyurea use for the treatment of essential thrombocytosis. *Singapore Med J*. 2014;55(01):e7-e8.
13. Reculé F. Acquired hyperpigmentation of the tongue associated with hydroxyurea: case report of a very rare location of a rare adverse effect. *Global J Dermatol Venereol*. 2016;4(1):12-13.
14. Oliveira SR, Branco LGdA, Rocha AL, et al. Association of oral mucosa hyperpigmentation with imatinib mesylate use: a cross-sectional study and a systematic literature review. *Clin Oral Invest*. 2019;23(12):4371-4382.

15. Majumdar G, Heard SE, Slater NG. Reversible hyperpigmentation associated with high dose hydroxyurea. *BMJ*. 1990;300(6737):1468.
16. Gropper CA, Don PC, Sadjadi MM. Nail and skin hyperpigmentation associated with hydroxyurea therapy for polycythemia vera. *Int J Dermatol*. 1993;32(10):731-733.
17. Laughon SK, Shinn LL, Nunley JR. Melanonychia and mucocutaneous hyperpigmentation due to hydroxyurea use in an HIV-infected patient. *Int J Dermatol*. 2000;39(12):928-931.
18. Kumar B, Saraswat A, Kaur I. Mucocutaneous adverse effects of hydroxyurea: a prospective study of 30 psoriasis patients. *Clin Exp Dermatol*. 2002;27(1):8-13.
19. Issaivanan M, Mitu PS, Manisha C, Praveen K. Cutaneous manifestations of hydroxyurea therapy in childhood: case report and review. *Pediatr Dermatol*. 2004;21(2):124-127.
20. Nofal A, El-Din ES. Hydroxyurea-induced dermatomyositis: true amyopathic dermatomyositis or dermatomyositis-like eruption? *Int J Dermatol*. 2012;51(5):535-541.
21. Murray NP, Echavarría M, Reculé F, Miranda M, Ferres Á. Acquired hyperpigmentation of the tongue associated with hydroxyurea: case report of a very rare location of a rare adverse effect. 2016.
22. Calleja Algarra A, Miguel RA, Tous Romero F, Maroñas JL. Mucocutaneous lesions and nail pigmentation in a patient with essential thrombocytosis. *Aust Fam Physician*. 2017;46(4):222-224.
23. Li C-C, Malik SM, Blaeser BF, et al. Mucosal pigmentation caused by imatinib: report of three cases. *Head Neck Pathol*. 2011;6(2):290-295.
24. Alawi F. Pigmented lesions of the oral cavity: an update. *Dent Clin North Am*. 2013;57(4):699-710.
25. Kelsey PR. Multiple longitudinal pigmented nail bands during hydroxyurea therapy. *Clin Lab Haematol*. 2008;14(4):337-338.
26. Cakir B, Sucak G, Haznedar R. Longitudinal pigmented nail bands during hydroxyurea therapy. *Int J Dermatol*. 2008;36(3):236-237.
27. Sreeja C, Ramakrishnan K, Vijayalakshmi D, Devi M, Aesha I, Vijayabanu B. Oral pigmentation: a review. *J Pharm Bioallied Sci*. 2015;7(Suppl 2):S403-S408.
28. Mendonça R, Gueiros LA, Capellaro K, Pinheiro VR, Lopes MA. Oral lesions associated with hydroxyurea treatment. *Indian J Dent Res*. 2011;22(6):869-870.

How to cite this article: Alshammasi B, Albasry Z, Meshikhes F. Oral hyperpigmentation associated with hydroxyurea in a patient with polycythemia vera: A case report. *Clin Case Rep*. 2020;8:1904–1909. <https://doi.org/10.1002/ccr3.3012>