

Original article:

HEPATOPROTECTIVE EFFECTS OF PANTOTHENIC ACID ON CARBON TETRACHLORIDE-INDUCED TOXICITY IN RATS

Akram Eidi^{1*}, Pejman Mortazavi², Masoud Ebrahim Tehrani¹, Ali Haeri Rohani¹, Shahabaldin Safi³

¹ Department of Biology, Science and Research Branch, Islamic Azad University, Tehran, Iran

² Department of Pathology, Faculty of Specialized Veterinary Sciences, Science and Research Branch, Islamic Azad University, Tehran, Iran

³ Department of Clinical Pathology, Faculty of Specialized Veterinary Sciences, Science and Research Branch, Islamic Azad University, Tehran, Iran

* corresponding author: Department of Biology, Science and Research Branch, Islamic Azad University, Tehran, Iran, E-mail: eidi@srbiau.ac.ir, akram_eidi@yahoo.com, Tel: +98 9123380064, Fax: +9821 44865939

ABSTRACT

The present study was undertaken to investigate the hepatoprotective effect of pantothenic acid on CCl₄-induced liver damage. Male Wistar rats were orally treated with pantothenic acid (0.005, 0.01, 0.025, 0.05 and 0.1 g/kg) daily, with administration of CCl₄ (1 mL/kg, 50 % CCl₄ in olive oil) twice a week for 28 days. The effect of pantothenic acid on serum markers (alanine aminotransferase, aspartate aminotransferase, alkaline phosphatase and γ -glutamyl-transferase) was measured in CCl₄-induced hepatotoxicity in rat. Further, the effects on enzymatic antioxidant (superoxide dismutase) were estimated in the liver samples. CCl₄ challenge not only elevated the serum marker enzyme activities but also suppressed hepatic antioxidative defense system including superoxide dismutase. The biochemical observations were supplemented with histopathological examination of rat liver sections. Histopathological examination of livers showed that pantothenic acid reduced fatty degeneration, cytoplasmic vacuolization and necrosis in CCl₄-treated rats. Therefore, pantothenic acid may be an effective hepatoprotective agent and viable candidate for treating hepatic disorders and other oxidative stress-related diseases.

Keywords: Antioxidant, carbon tetrachloride, hepatoprotective effects, pantothenic acid, rats

INTRODUCTION

Pantothenic acid (also called vitamin B₅), a member of the B-vitamin family, is an essential nutrient to all forms of life (Plesofsky-Vig, 1999). Its name originates from the Greek word pantothen (Pantoyen), meaning “from everywhere,” because small quantities of pantothen are found in nearly every form of food, with high

amounts in whole-grain cereals, legumes, eggs, and meat. Pantothenic acid was described first as *Lactobacillus bulgaricus* growth factor (Williams et al., 1949). Pantothenic acid is involved in a number of biological reactions, including the production of energy, the catabolism of fatty acids and amino acids, the synthesis of fatty acids, phospholipids, sphingolipids, choles-

terol, synthesis of amino acids such as leucine, arginine and methionine, steroid hormones, and the synthesis of heme and the neurotransmitter acetylcholine (Plesofsky-Vig, 1996). Pantothenic acid is a component of coenzyme A (CoA), an essential coenzyme in a variety of reactions that sustain life. It is also involved in the synthesis of adrenal cortical hormones (Hurley and Morgan, 1952; Jaroenporn et al., 2008; Schultz et al., 1952a, b; Winters et al., 1952) and growth of skin, hair and nerves (Fidanza, 1983; Kuo et al., 2007). On the other hand, the serum triglyceride and free fatty acid levels were significantly elevated in dietary pantothenic acid-deficient rats (Wittwer et al., 1990). Pantothenic acid was reported to protect cells and organs against peroxidative damage by increasing the content of cell glutathione (Slyshenkov et al., 2004).

The liver regulates several important functions including metabolism, and is an important organ for detoxification of hepatotoxicants which can cause hepatic injury during metabolic reaction. The pathogenesis of this damage involves all cell types in the liver via death and regeneration processes and progress to chronic hepatitis, fibrosis, cirrhosis and hepatocellular carcinoma (Giannelli et al., 2003). Oxidative stress has been regarded as a major contributor to the development of various hepatic disorders (Albano, 2008; Aram et al., 2009; Ferret et al., 2001; Nagata et al., 2007; Sakurai et al., 2008). The reactive oxygen species (ROS) are known to play a major role in either the initiation or progression of carcinogenesis by inducing oxidative stress (Sun, 1990; Gulcin, 2006). Oxidative stress plays a crucial role in the development of carbon tetrachloride (CCl₄) - induced hepatotoxicity (Sureshkumar and Mishra, 2006), and a connection between oxidative stress and lipid peroxidation has been reported (Kota et al., 2008). Numerous studies noted that CCl₄ is widely used to induce liver damage because it is metabolized in hepatocytes by cytochrome P₄₅₀, generating a highly reactive carbon-centered tri-

chloromethyl radical, leading to initiating a chain of lipid peroxidation and thereby causing liver fibrosis (Fang et al., 2008; Weber et al., 2003).

The aim of the present study was to examine the effects of pantothenic acid on CCl₄-induced acute hepatic injury in rats.

MATERIALS AND METHODS

Chemicals

Pantothenic acid was obtained from Sigma-Aldrich; St. Louis, MO. Carbon tetrachloride was purchased from Merck, Germany. The kits for alanine aminotransferase (ALT), aspartate aminotransferase (AST) and alkaline phosphatase (ALP) were purchased from Parsazmoon Company of Iran. The kit for γ -glutamyltransferase (GGT) was obtained from Bionik of Italy. The kit for superoxide dismutase (SOD) was purchased from Randox Company of England. All the other chemicals and reagents used were of analytical grade.

Animals

Adult male Wistar rats with body weights of 180-230 g were used in the study. The animals were maintained under standard environmental conditions (23-25 °C, 12 h/12 h light/dark cycle) and had free access to standard rodent pellet diet and water ad libitum. The animals were acclimatized in the laboratory conditions for a week before the commencement of the study. The experimental procedures adopted in this study were in strict compliance with the United States National Institutes of Health Guidelines for Care and Use of Laboratory Animals in Biomedical Research (1985, no. 85-23).

Experimental design

The method of Habbu et al. (2008) was used in this study. Rats were divided into 9 groups of 9 animals each. Treatment was then carried out according to the group allotment below:

- Group I received olive oil and saline served as vehicle control animals.

- Groups II-III were administrated pantothenic acid dissolved in distilled water daily using an intragastric tube (gavage) at dose levels of 0.01 and 0.025g/kg b.w., respectively.
- Group IV was the hepatotoxicity group that was given carbon tetrachloride (i.p., 0.5 mL/kg b.w., 50 % CCl₄ in olive oil) twice a week.
- Groups V-IX were administrated pantothenic acid dissolved in distilled water daily using an intragastric tube (gavage) at dose levels of 0.005, 0.01, 0.025, 0.05, 0.1 g/kg b.w., respectively, with CCl₄ (i.p., 0.5 mL/kg b.w., 50 % CCl₄ in olive oil) twice a week.

After 28 days of treatment period, the animals were deprived of food overnight and anesthetized by exposing to diethyl ether and then sacrificed by cervical decapitation. Blood was collected from jugular vein and serum was separated and used for liver marker assays. The liver tissue was dissected out, washed in ice-cold saline, and patted dry and weighed.

Tissue sample was taken from hepatic lobes and was stored in 10 % formalin buffer solution for histopathological examination. From the remaining tissue, about 100 mg tissue from liver was weighed and homogenized in chilled 0.1 M Tris-HCl buffer in Potter-Elvehjem Teflon homogenizer. The homogenates were used for biochemical investigation.

Analytical procedure

The serum was used for the estimation of hepatic marker enzymes namely serum ALT, AST (Reitman and Frankel, 1957), ALP (Anderch and Szczypinski, 1947) and GGT (Szasz, 1969). The liver tissue homogenates were used for the assay of SOD (Sun et al., 1988).

Histopathological examination

Formalin fixed samples were routinely embedded in paraffin blocks, sectioned at 4 µm and stained with Haematoxylin and Eosin for microscopic examination. Liver sections were graded numerically to assess

the degree of histological features in acute hepatic injury. Hepatocyte necrosis, fatty change, hyaline degeneration, ballooning degeneration, infiltration of Kupffer cells and lymphocytes were prominent in the histological findings (Valeer, 2003). The liver pathology was scored as described by French et al., 2000 as follows:

- Score 0 = no visible cell damage;
- Score 1 = focal hepatocyte damage on less than 25 % of the tissue;
- Score 2 = focal hepatocyte damage on 25-50 % of the tissue;
- Score 3 = extensive, but focal, hepatocyte lesions;
- Score 4 = global hepatocyte necrosis.

The morphology of any lesions observed was classified and registered (Gray, 1958).

Statistical analysis

The calculations and statistical analysis were carried out using the Statistical Package for Social Sciences (SPSS) for Windows version 12.0 software. All data were represented as mean ± S.E.M. Data were subjected to one-way analysis of variance (ANOVA) followed by Tukey post hoc test. Statistical probability of $P < 0.05$ was considered to be significant.

RESULTS

Body weight and weight of liver

Organ weight decrease is an indication of organ injury. Table 1 shows the effects of pantothenic acid on organ weight changes observed in rats in response to CCl₄ administration. Body and liver weights differed significantly between the CCl₄-treated group and the normal control group. However, pantothenic acid administration ameliorated the reduction in liver weight in CCl₄-treated rats.

Serum biochemical parameters

ALT, AST and ALP are the important hepatic metabolic enzymes. When liver is damaged, these enzymes will be released from liver into serum. Thus, the activities of

these enzymes in serum can reflect the degree of liver injury (Zhang et al., 2005). The experiments showed that CCl₄ markedly increased the activities of serum ALT, AST, ALP and GGT from rats of toxic control group as compared with the normal control group. But pantothenic acid effectively reduced the activities of these enzymes. Treatment with pantothenic acid also reduced all measured serum biochemical activities towards normalization. There was no significant alteration in control rats treated solely with pantothenic acid (Table 2).

Hepatic biochemical parameters

SOD and GGT were measured as an index of antioxidant status of tissues. Significantly lower activities of liver SOD was observed in CCl₄-treated group as compared to the normal control group (Table 2). There were significant increases in SOD activities in the pantothenic acid-treated groups compared to the CCl₄-treated control group ($p < 0.05$).

Table 1: Body weight and liver weight of acute CCl₄ (50% CCl₄/olive oil)-treated rats with or without pantothenic acid

Groups	Initial body weight (g)	Final body weight (g)	Weight gain (g)	Liver weight (g)	Relative liver weight (g liver/100 g body)
Control	207.14 ± 6.35	243.42 ± 5.48	36.28 ± 3.7	4.04 ± 0.14	1.66 ± 0.03
Pantothenic acid (0.01 g/kg)	227.85 ± 6.81	265.71 ± 8.05	37.86 ± 3.9	3.06 ± 0.05	1.15 ± 0.03
Pantothenic acid (0.025 g/kg)	221.57 ± 2.42	253.71 ± 8.08	32.14 ± 3.1	3.17 ± 0.06	1.25 ± 0.04
CCl ₄	217.42 ± 5.03	219.23 ± 8.05***	1.81 ± 0.5***	5.18 ± 0.14***	2.36 ± 0.05***
Pantothenic acid + CCl ₄					
0.005 g/kg + CCl ₄	197.57 ± 5.62	214.87 ± 8.83	17.3 ± 1.5	4.65 ± 0.12	2.16 ± 0.04
0.01 g/kg + CCl ₄	205.8 ± 5.42	226.37 ± 5.85 ⁺	20.57 ± 2.1 ⁺	4.45 ± 0.08 ⁺	1.97 ± 0.03 ⁺
0.025 g/kg + CCl ₄	208.78 ± 5.11	234.75 ± 3.34 ⁺⁺⁺	25.97 ± 2.6 ⁺⁺⁺	4.48 ± 0.13 ⁺⁺	1.91 ± 0.05 ⁺⁺
0.05 g/kg + CCl ₄	208.42 ± 4.41	235.01 ± 3.78 ⁺⁺⁺	26.59 ± 2.6 ⁺⁺⁺	4.13 ± 0.11 ⁺⁺	1.76 ± 0.03 ⁺⁺⁺
0.1 g/kg + CCl ₄	211.27 ± 6.32	238.11 ± 4.78 ⁺⁺⁺	26.84 ± 2.7 ⁺⁺⁺	3.99 ± 0.16 ⁺⁺⁺	1.68 ± 0.04 ⁺⁺⁺

Values are mean ± S.E.M. of 9 rats; *** $p < 0.001$ significantly different from the control; ⁺ $p < 0.05$, ⁺⁺ $p < 0.01$, ⁺⁺⁺ $p < 0.001$ significantly different from the group treated with CCl₄

Table 2: Effects of pantothenic acid on serum and liver biochemical indices in CCl₄-induced hepatotoxicity in rats

Groups	ALT (IU/L)	AST (IU/L)	ALP (IU/L)	GGT (IU/L)	SOD (IU/mg protein)
Control	59.71 ± 3.44	191.6 ± 20.27	348.6 ± 18.43	2.83 ± 0.54	10.2 ± 2.7
Pantothenic acid (0.01 g/kg)	51.83 ± 3.32	97.0 ± 4.81	321 ± 38.35	1.83 ± 0.31	10.7 ± 2.4
Pantothenic acid (0.025 g/kg)	49.5 ± 3.77	141.0 ± 23.71	281 ± 26.62	2.16 ± 0.41	10.9 ± 2.6
CCl ₄	1018.2 ± 41.6***	923.0 ± 10.11***	1013 ± 13***	8.14 ± 1.56**	6.2 ± 1.7***
Pantothenic acid + CCl ₄					
0.005 g/kg + CCl ₄	850.6 ± 72.04	671.75 ± 76.96	701.33 ± 61.33	4.5 ± 1.38	7.8 ± 2.3
0.01 g/kg + CCl ₄	614.66 ± 128.8 ⁺	594.2 ± 75.48 ⁺⁺	467.2 ± 48.91 ⁺⁺⁺	3.33 ± 0.98 ⁺⁺	8.2 ± 1.9 ⁺
0.025 g/kg + CCl ₄	608.25 ± 122.8 ⁺⁺	447.5 ± 101.84 ⁺⁺⁺	402.5 ± 75.86 ⁺⁺⁺	3.12 ± 1.12 ⁺⁺	8.5 ± 1.5 ⁺⁺
0.05 g/kg + CCl ₄	585.25 ± 122.8 ⁺⁺	370.2 ± 53.14 ⁺⁺⁺	363.33 ± 24.13 ⁺⁺⁺	3.05 ± 0.86 ⁺⁺	8.7 ± 2.1 ⁺⁺
0.1 g/kg + CCl ₄	537 ± 81.75 ⁺⁺⁺	319.66 ± 26.19 ⁺⁺⁺	338.12 ± 48.63 ⁺⁺⁺	2.85 ± 0.55 ⁺⁺⁺	9.1 ± 1.6 ⁺⁺⁺

Values are mean ± S.E.M. of 9 rats; ** $p < 0.01$, *** $p < 0.001$ significantly different from the control; ⁺ $p < 0.05$, ⁺⁺ $p < 0.01$, ⁺⁺⁺ $p < 0.0001$ significantly different from the group treated with CCl₄

Table 3: Histological injury score of liver under different doses of pantothenic acid in rats treated with CCl₄ (50 % CCl₄/Olive oil)

Index Groups	Injury of score ^a				
	Fatty degeneration	Necrosis	Cell swelling	Inflammation	Total scores
Control	0	0	0	0	0
Pantothenic acid (0.01 g/kg)	0	0	0	0	0
Pantothenic acid (0.025 g/kg)	0	0	0	0	0
CCl ₄	4	4	3	3	14
Pantothenic acid + CCl ₄					
0.005 g/kg + CCl ₄	4	4	3	3	14
0.01 g/kg + CCl ₄	4	4	3	2	13
0.025 g/kg + CCl ₄	4	4	3	2	13
0.05 g/kg + CCl ₄	3	3	1	1	8
0.1 g/kg + CCl ₄	3	2	1	1	7

^a Livers were scored for hepatic injury via light microscopy with score 0 = no visible cell damage; score 1 = focal hepatocyte damage on less than 25 % of the tissue; score 2 = focal hepatocyte damage on 25-50 % of the tissue; score 3 = extensive, but focal, hepatocyte lesions; score 4 = global hepatocyte necrosis

Histopathological findings

The severity of the liver morphological changes and fibrosis induced by CCl₄ treatment were scored and summarized. Our results showed that administration of pantothenic acid greatly improved liver morphological changes, fibrosis and necrosis. The average severity scores of pantothenic acid-treated rats were markedly reduced in a dose-dependent manner (Table 3). The livers of the rats from control group had no noticeable histological changes (Figure 1A). Severe histopathological changes were consistently observed in livers of all the rats from CCl₄-treated group. The predominant lesions were extensive hydropic degeneration, necrosis and infiltration of inflammatory cells (Figure 1D). These changes were seen in almost all lobules, and were more pronounced in centrilobular and intermediate areas. Most hepatocytes in the degenerative and necrotic regions had pykneotic nuclei, and were so swollen that several cells had ruptured. In addition, some hepatocytes in the periportal regions had moderate to severe cytoplasmic vacuolation, indicating fatty change. However, the livers of all animals showed no cirrhotic changes with the regenerative nodules or fibrous bands extend-

ing to parenchyma. The histological appearance of the pantothenic acid group was quite similar to that of the control group (Figures 1B and 1C). Administration of pantothenic acid ameliorated or reversed the changes induced by CCl₄ in part. The lesions in the liver of rats that received CCl₄+ pantothenic acid were conspicuously less than those in the rats that received CCl₄ only. The livers from the rats in this group showed occasional apoptotic and dysplastic hepatocytes, most of which were not abnormal, but no extensive hydropic degeneration and necrotic changes were seen in any of the livers. Moreover, the architecture of lobules was not disrupted and the hepatocytes mostly had normal appearance (Figures 1E-1I). However, only few lobules of livers showed a focus of degenerative cells, most of which had normal nuclear appearance and mild cytoplasmic degeneration. Morphological findings in all groups of this study were consistent with observations of serum enzymes of AST, ALT and ALP values.

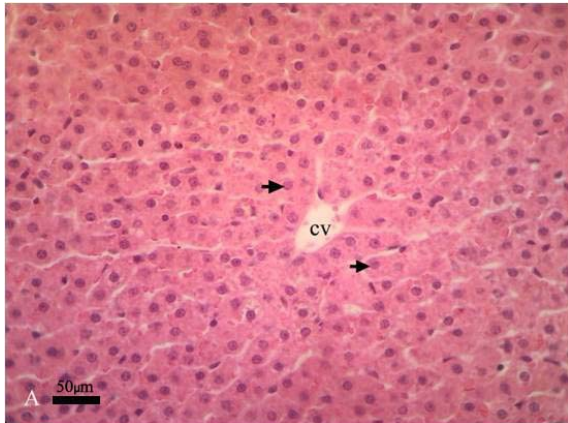


Figure 1A

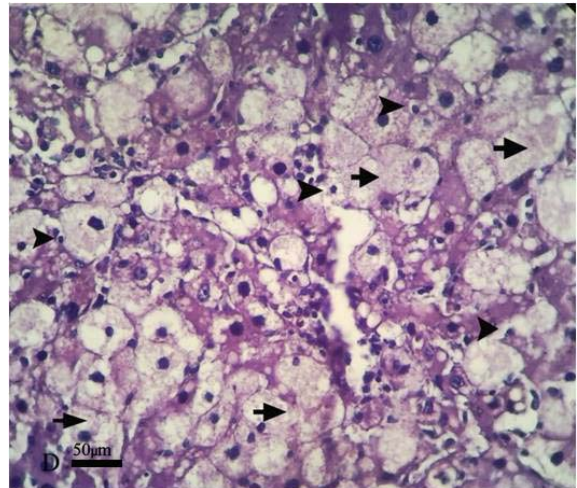


Figure 1D

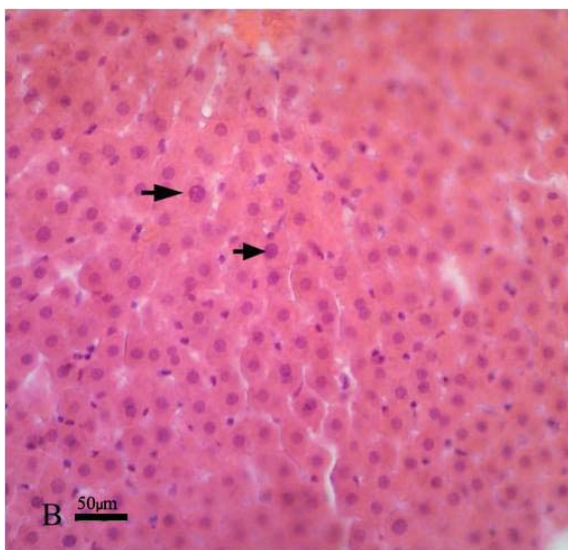


Figure 1B

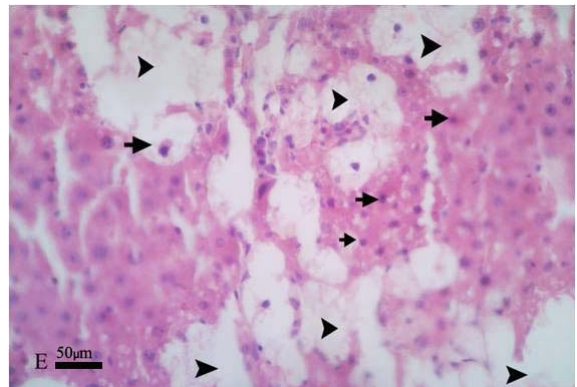


Figure 1E

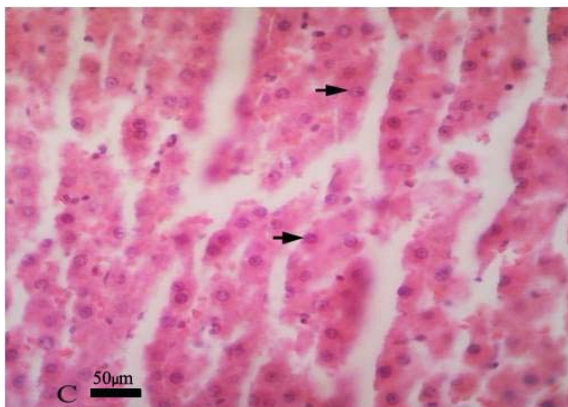

Figure 1C

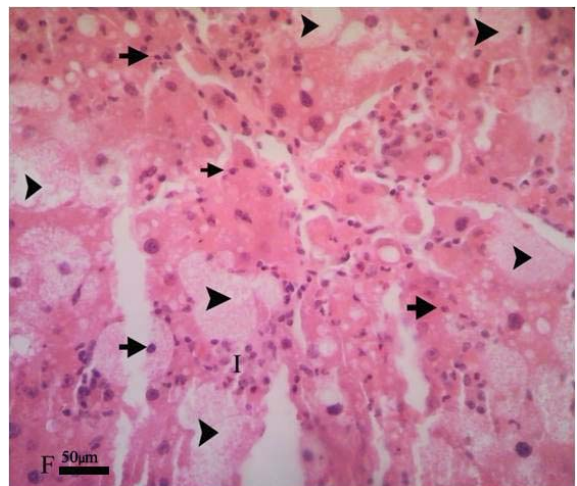


Figure 1F

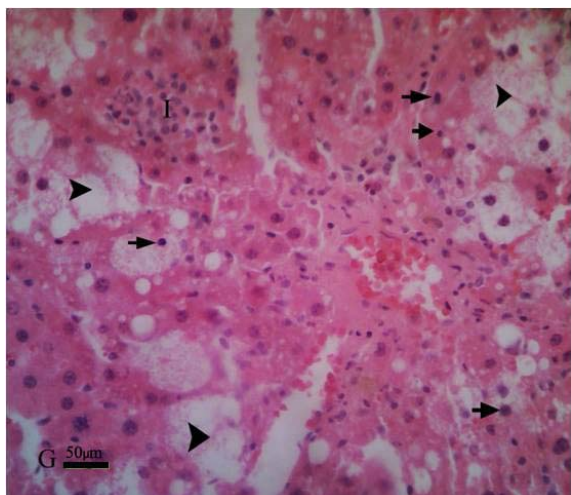


Figure 1G

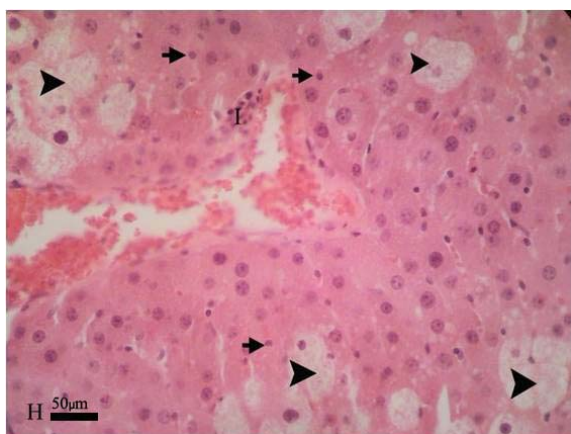


Figure 1H

DISCUSSION

CCl_4 is a well-known hepatotoxin that is widely used to induce toxic liver injury in a range of laboratory animals. CCl_4 -induced hepatotoxicity is believed to involve two phases. The initial phase involves the metabolism of CCl_4 by cytochrome P_{450} to the trichloromethyl radicals (CCl_3^\bullet and/or $\text{CCl}_3\text{OO}^\bullet$), which lead to membrane lipid peroxidation and finally to cell necrosis (Basu, 2003; Manibusan et al., 2007). The second phase of CCl_4 -induced hepatotoxicity involves the activation of Kupffer cells, which is accompanied by the production of proinflammatory mediators (Planaguma et al., 2005). Several microarray studies have been reported describing gene expression changes caused by acute CCl_4 toxicity (Harries et al., 2001), although the signifi-

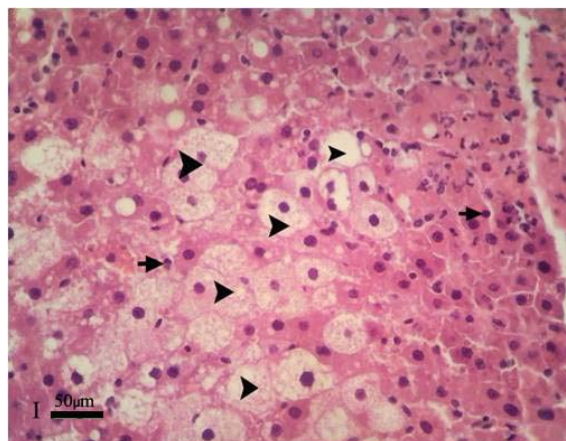


Figure 1I

Figure 1: Effect of pantothenic acid on CCl_4 -induced liver damage in Wistar rats. **(A)** liver of normal untreated control showing intact basic liver structures like central vein (CV) and hepatocytes (arrow), **(B, C)** liver in group II **(B)** and group III **(C)**, showing normal structure and hepatocytes (arrow), separated line is artifact, **(D)** liver of group IV, showing hepatocytes necrosis (arrow head), fatty degeneration (arrow) and infiltration of inflammatory cells, **(E-I)** liver in group V **(E)**, VI **(F)**, VII **(G)**, VIII **(H)** and IX **(I)**, show that hepatocyte necrosis (arrow), fatty degeneration (arrow head) and infiltration of inflammatory cells (H&E *640).

cance of these changes has not been fully understood.

In the present study, the capability of pantothenic acid to protect against CCl_4 -induced hepatotoxicity and oxidative stress was investigated. Results indicated that pantothenic acid was able to suppress the hepatotoxicity of CCl_4 and the hepatoprotective effect. Levels of some important biochemical parameters in serum are used as diagnostic markers of hepatic injury. One of the most sensitive and dramatic indicators of hepatocyte injury is the release of intracellular enzymes, such as transaminases and serum alkaline phosphatase in the circulation after CCl_4 administration. The elevated activities of these enzymes are indicative of cellular leakage and loss of the functional integrity of the cell membranes in liver which is always associated with

hepatonecrosis (Naik and Panda, 2008; Rajesh and Latha, 2004). With the treatment of pantothenic acid, the levels of these marker enzymes were near normal or only slightly elevated, indicating protection against liver damage. ALP activity is related to the functioning of hepatocytes. Suppression of increased ALP activity suggests the stability of biliary dysfunction in rat liver during chronic hepatic injury with CCl_4 (Mukherjee, 2002). ALP is a membrane associated enzyme and an increased activity of ALP is an indication of liver damage (Giannini et al., 2005). GGT is a microsomal enzyme present in hepatocytes and its primary role is to metabolize extracellular glutathione allowing for precursor amino acids to be assimilated and reutilized for intracellular glutathione synthesis. An increase in serum GGT is a defense mechanism reflecting the induction of cellular GGT, when there is oxidative stress (Lee et al., 2004). Diminution of total protein and albumin induced by CCl_4 is a further indication of liver damage (Navarro and Senior, 2006). Stimulation of protein synthesis has been advanced as a contributory hepatoprotective mechanism which accelerates the regeneration process and the production of liver cells (Rip et al., 1985; Tadeusz et al., 2001).

SOD and CAT are two important enzymatic antioxidants that act against toxic oxygen free radicals such as superoxide (O_2^-) and hydroxyl ions (OH^-) in biological systems (Burton et al., 1983). It is reported that antioxidant enzymes, such as SOD, CAT and the glutathione system, have been known to play important roles in alleviating oxidative damage, since they are involved in the direct elimination of reactive oxygen species (Fang et al., 2002; Ravid et al., 1999). CAT prevents oxidative hazards by catalyzing the formation of H_2O and O_2 from H_2O_2 (Kumar and Kuttan, 2003). In our present study we observed a decrease in the SOD activities of the liver tissues on CCl_4 administration. Pantothenic acid administration to CCl_4 -treated rats significantly increased the SOD activities. Our find-

ings are in line with the observations by other authors on radioprotective and antioxidative effects of pantothenic acid and pantothenol (Nagiel-Ostaszewski and Lau-Cam, 1990; Utno, 1991; Kumerova et al., 1991, 1992). It is reported that pantothenic acid alleviated the ultraviolet-induced decrease of glutathione content, diminished lipid peroxidation, and partly protected the cells against apoptosis produced by ultraviolet irradiation (Slyshenkov et al., 2001). In all these experiments pantothenic acid presumably helped to remove ROS and protects against apoptosis. Thus, pantothenic acid and some of its derivatives may be a valuable tool in treatment of impairments related to oxidative stress. It is suggested that an increase of total glutathione observed after treatment of the cells or whole animals with pantothenic acid or pantothenol might arise from reductive breakage of disulfide bonds in protein-bound glutathione and liberation of glutathione (Slyshenkov et al., 2001, 1998). It is reported that pantothenic acid and its related compounds protect the plasma membrane of Ehrlich ascites tumor cells against the damage by oxygen free radicals due to increasing cellular level of CoA. The latter compound may act by diminishing propagation of lipid peroxidation and promoting repair mechanisms, mainly the synthesis of phospholipids (Slyshenkov et al., 1996).

The histological results reported in the current study confirmed the biochemical results and indicated that CCl_4 induced severe histological changes in the hepatic tissues. Similar histological changes in the liver have been documented previously (Bilgin et al., 2011; Çetin et al., 2011). The acute hepatotoxic effects induced by CCl_4 administration were confirmed histopathologically, revealing extensive hepatocellular degeneration and necrosis, fatty changes, inflammatory cell infiltration, congestion, and sinusoidal dilatation. We also observed thickening portal tract with cellular debris and periportal fibrosis. The hepatocytes showed vacuolar degeneration and nuclear pleomorphism. In contrast, our histological

results showed that treatment with pantothenic acid effectively protected rats against CCl₄-induced hepatic toxicity. Treatment with pantothenic acid prevented the necrosis and the other histopathological changes induced by CCl₄ treatment.

In summary, this study demonstrates that pantothenic acid had a protective effect against CCl₄-induced acute hepatic damage in rats. The hepatoprotective effect of pantothenic acid is likely due to its ability to the inflammatory responses, in combination with the ability to scavenge free radicals.

ACKNOWLEDGMENTS

We would like to thank Deputy Research, Science and Research Branch, Islamic Azad University, for financial support of the project.

REFERENCES

- Albano E. Oxidative mechanisms in the pathogenesis of alcoholic liver disease. *Mol Aspects Med* 2008;29:9-16.
- Anderch MA, Szczypinski AJ. Drug toxicity and hormonal dysfunction. *Am J Clin Pathol* 1947;17:571-4.
- Aram G, Potter JJ, Liu X, Wang L, Torbenson MS, Mezey E. Deficiency of nicotinamide adenine dinucleotide phosphate, reduced form oxidase enhances hepatocellular injury but attenuates fibrosis after chronic carbon tetrachloride administration. *Hepatology* 2009;49:911-9.
- Basu S. Carbon tetrachloride-induced lipid peroxidation: Eicosanoid formation and their regulation by antioxidant nutrients. *Toxicology* 2003;189:113-27.
- Bilgin HM, Atmaca M, Obay BD, Özekinci S, Tas-demir E, Ketani A. Protective effects of coumarin and coumarin derivatives against carbon tetrachloride-induced acute hepatotoxicity in rats. *Exp Toxicol Pathol* 2011;63:325-30.
- Burton GW, Cheesman HN, Ingold KV, Seater TF. Lipid antioxidants and products of lipid peroxidation as potential tumor protective agents. *Biochem Soc Trans* 1983;11:261-2.
- Çetin E, Kanbur M, Çetin N, Eraslan G, Ataserver A. Hepatoprotective effect of ghrelin on carbon tetrachloride-induced acute liver injury in rats. *Reg Peptides* 2011;171:1-5.
- Fang YZ, Yang S, Wu G. Free radicals, antioxidant, and nutrition. *Nutrition* 2002;18:872-9.
- Fang HL, Lai JT, Lin WC. Inhibitory effect of olive oil on fibrosis induced by carbon tetrachloride in rat liver. *Clin Nutr* 2008;27:900-7.
- Ferret PJ, Hammoud R, Tulliez M, Tran A, Trébédén H, Jaffray P et al. Detoxification of reactive oxygen species by a nonpeptidyl mimic of superoxide dismutase cures acetaminophen-induced acute liver failure in the mouse. *Hepatology* 2001;33:1173-80.
- Fidanza A. Therapeutic action of pantothenic acid. *Int J Vitam Nutr Res (Suppl.)* 1983;24:53-67.
- French SW, Miyamoto K, Ohta Y, Geofrion Y. Pathogenesis of experimental alcoholic liver disease in the rat. *Methods Achiev Exp Pathol* 2000;13:181-207.
- Giannelli G, Quaranta V, Antonaci S. Tissue remodelling in liver diseases. *Histol Histopathol* 2003;18:1267-74.
- Giannini EG, Testa R, Savarino V. Liver enzyme alteration: a guide for clinicians. *CMAJ* 2005;172:367-79.
- Gray P. Handbook of basic microtechnique. 3rd ed. (pp 45-85). New York: McGraw-Hill, 1958.

- Gulcin I. Antioxidant activity of caffeic acid (3,4-dihydroxycinnamic acid). *Toxicology* 2006; 217:213-20.
- Habbu PV, Shastry RA, Mahadevan KM, Joshi H, Das SK. Hepatoprotective and antioxidant effects of *Argyrea speciosa* in rats. *Afr J Tradit Complement Altern Med* 2008;5:158-64.
- Harries HM, Fletcher ST, Duggan CM, Baker VA. The use of genomics technology to investigate gene expression changes in cultured human liver cells. *Toxicol In Vitro* 2001;15:399-405.
- Hurley LS, Morgan AF. Carbohydrate metabolism and adrenal cortical function in the pantothenic acid-deficient rat. *J Biol Chem* 1952;195:583-90.
- Jaroenporn S, Yamamoto T, Itabashi A, Nakamura K, Watanabe G, Taya K. Effects of pantothenic acid supplementation on adrenal steroid secretion from male rats. *Biol Pharm Bull* 2008;31:1205-8.
- Kota N, Krishna P, Polasa K. Alternations in antioxidant status of rats following intake of ginger through diet. *Food Chem* 2008;106:991-6.
- Kumar NVR, Kuttan R. Modulation of carcinogenic response and antioxidant enzymes of rats administered with 1,2-dimethylhydrazine by picroliv. *Cancer Lett* 2003;191:137-43.
- Kumerova AO, Silova AA, Utno LY. Effect of pantethine on post-heparin lipolytic activity and lipid peroxidation in the myocardium. *Biull Eksp Biol Med* 1991;111:33-5.
- Kumerova AO, Utno LY, Lipsberga ZE, Shekestere IY. Myocardial protection by derivatives of pantothenic acid in heart model with experimental ischemia and reperfusion. *Biull Eksp Biol Med* 1992;113:373-5.
- Kuo YM, Hayflick SJ, Gitschier J. Deprivation of pantothenic acid elicits a movement disorder and azoospermia in a mouse model of pantothenate kinase-associated neurodegeneration. *J Inherit Metab Dis* 2007;30:310-7.
- Lee DH, Blomhoff R, Jacobs DR. Serum gamma glutamyltransferase a marker of oxidative stress. *Free Radical Res* 2004;38:535-9.
- Manibusan MK, Odin M, Eastmond DA. Postulated carbon tetrachloride mode of action: a review. *J Environ Sci Health C Environ Carcinog Ecotoxicol Rev* 2007;25:185-209.
- Mukherjee PK. Quality control of herbal drugs, 1st ed. (p 531). New Delhi: Business Horizons Pharmaceutical Publication, 2002.
- Nagata K, Suzuki H, Sakaguchi S. Common pathogenic mechanism in development progression of liver injury caused by non-alcoholic or alcoholic steatohepatitis. *J Toxicol Sci* 2007;32:453-68.
- Nagiel-Ostaszewski I, Lau-Cam CA. Protection by pantethine, pantothenic acid and cystamine against carbon tetrachloride-induced hepatotoxicity in the rat. *Res Commun Chem Pathol Pharmacol* 1990;67:289-92.
- Naik SR, Panda VS. Hepatoprotective effect of Ginkgoselect phytosome in rifampicin induced liver injury in rats: evidence of antioxidant activity. *Fitoterapia* 2008;79:439-45.
- Navarro VJ, Senior JR. Drug-related hepatotoxicity. *N Engl J Med* 2006;354:731-9.

- Planaguma A, Claria J, Miquel R, Lopez-Parra M, Titos E, Masferrer JL et al. The selective cyclooxygenase-2 inhibitor SC-236 reduces liver fibrosis by mechanisms involving non-parenchymal cell apoptosis and PPARgamma activation. *FASEB J* 2005;19:1120-2.
- Plesofsky-Vig N. Pantothenic acid. In: Zeigler EE, Filer LJ (eds). *Present knowledge in nutrition* (pp 236-44). Washington, DC: ILSI Press, 1996.
- Plesofsky-Vig N. Pantothenic acid. In: Shils ME, Olson JA, Shike M, Ross AC (eds). *Modern nutrition in health and disease*. 9th ed. (pp 423-32). Philadelphia: Lippincott Williams & Wilkins, 1999.
- Rajesh MG, Latha MS. Preliminary evaluations of the antihepatotoxic effect of Kamilari, a polyherbal formulation. *J Ethnopharmacol* 2004;91:99-104.
- Ravid A, Rucker D, Machlenkin A, Rotem C, Hochman A, Kessler-Icekson G et al. 1,25-Dihydroxyvitamin D3 enhances the susceptibility of breast cancer cells to doxorubicin-induced oxidative damage. *Cancer Res* 1999;59:862-7.
- Reitman S, Frankel S. A colorimetric method for the determination of serum glutamic oxaloacetic and glutamic pyruvic transaminases. *Am J Clin Pathol* 1957;28:56-63.
- Rip JW, Rupa CA, Ravi K, Carroll KK. Distribution, metabolism and function of dolichol and polyprenols. *Prog Lipid Res* 1985;24:269-309.
- Sakurai T, He G, Matsuzawa A, Yu G, Maeda S, Hardiman G et al. Hepatocyte necrosis induced by oxidative stress and il-1a release mediate carcinogen induced compensatory proliferation and liver tumorigenesis. *Cancer Cell* 2008;14:156-65.
- Schultz RB, Winters RW, Krehl WA. Studies on adrenal cortex of pantothenic acid-deficient rat. IV Adrenal and serum cholesterol levels. *Proc Soc Exp Biol Med* 1952a;79:695-6.
- Schultz RB, Winters RW, Krehl WA. The adrenal cortex of the pantothenic acid deficient rat: modification of the lesion by ACTH and cortisone treatment. *Endocrinology* 1952b;51:336-43.
- Slyshenkov VS, Rakowska M, Wojtczak L. Protective effect of pantothenic acid and related compounds against permeabilization of Ehrlich ascites tumor cells by digitonin. *Acta Biochim Polon* 1996;43:407-10.
- Slyshenkov VS, Omelyanchik SN, Moiseenok AG, Trebukhina RV, Wojtczak L. Pantothenol protects rats against some deleterious effects of gamma radiation. *Free Radic Biol Med* 1998;24:894-9.
- Slyshenkov VS, Piwocka K, Sikora E, Wojtczak L. Pantothenic acid protects Jurkat cells against ultraviolet light-induced apoptosis. *Free Radic Biol Med* 2001;30:1303-10.
- Slyshenkov VS, Dymkowska D, Wojtczak L. Pantothenic acid and pantothenol increase biosynthesis of glutathione by boosting cell energetics. *FEBS Lett* 2004;569:169-72.
- Sun Y, Oberley LW, Li Y. Simple method for clinical assay of superoxide dismutase. *Clin Chem* 1988;34:497-500.
- Sun Y. Free radicals, antioxidant enzymes and carcinogenesis. *Free Radic Biol Med* 1990;8:583-99.
- Sureshkumar SV, Mishra SH. Hepatoprotective effect of extracts from *Pergularia-daemia* Forsk. *J Ethnopharmacol* 2006;107:164-8.

Szasz G. A kinetic photometric method serum gamma glutamyl transpeptidase. Clin Chem 1969;24:124-35.

Tadeusz J, Teresa J, Krzysztof N. The role of polyphenol in modulation of physical properties of model membranes. Curr Top Biophys 2001;25:33-8.

Utno LY. Effects of pantethine on metabolism in myocardial mitochondria under the conditions of deep hypothermia. Biull Eksp Biol Med 1991;111:577-8.

Valeer JD. Liver tissue examination. J Hepatol 2003;39:S43-9.

Weber LW, Boll M, Stampfl A. Hepatotoxicity and mechanism of action of haloalkanes: carbon tetrachlorides as a toxicological model. Crit Rev Toxicol 2003;33:105-36.

Williams WL, Hoff-Jorgensen WE, Snell EE. Determination and properties of an unidentified growth factor required by *Lactobacillus bulgaricus*. J Biol Chem 1949;177:933-40.

Winters RW, Schultz RB, Krehl WA. The adrenal cortex of the pantothenic acid-deficient rat; carbohydrate metabolism. Endocrinology 1952;50:388-98.

Wittwer CT, Beck S, Peterson M, Davidson R, Wilson RE, Hansen RG. Mild pantothenate deficiency in rats elevates serum triglyceride and free fatty acid levels. J Nutr 1990;120:719-25.

Zhang JS, Wang HL, Yan XX, Zhang LD. Comparison of short-term toxicity between nano-Se and selenite in mice. Life Sci 2005;76:1099-109.