

ORIGINAL ARTICLE

5-Aminolevulinic acid patch (Alacare) photodynamic therapy for actinic cheilitis: data from a prospective 12-month follow-up study on 21 patients

S. Radakovic,^{1,*}  M. Dangl,² A. Tanew¹¹Department of Dermatology, Medical University of Vienna, Vienna, Austria²Landeskrankenhaus Gmünd, Gmünd, Austria

*Correspondence: S. Radakovic. E-mail: sonja.radakovic@meduniwien.ac.at

Abstract

Background Actinic cheilitis (AC) is a variant of actinic keratosis (AK) affecting the lips and caused by chronic ultraviolet exposure.

Objective Alacare is a self-adhesive, skin-coloured 5-aminolaevulinic acid patch that has been developed for use in photodynamic therapy (PDT) of mild-to-moderate AK. Based on promising preliminary results in the treatment of AC with Alacare patch PDT, we decided to extend our previous investigation to gain more data on the efficacy, tolerability, safety and cosmetic outcome of Alacare patch PDT for AC.

Methods Twenty-one patients with a clinical diagnosis of mild-to-moderate AC were included in the study and subjected to one single session of PDT. After occlusion with the Alacare patch for 4 h, the AC lesions were illuminated for 10 min with red light at a dose of 37 J/cm². All patients received local anaesthesia prior to illumination. Additionally, all lesions were cooled during PDT with a cold air blower. PDT-induced pain and skin phototoxicity were monitored during and up to 7 days after PDT. Clinical assessment of efficacy, cosmetic outcome and global patient satisfaction was performed at 3, 6 and 12 months after treatment.

Results Nineteen patients completed the study. Three months after PDT, 17 patients (89.5%) had achieved complete remission. Of these, one patient presented with recurrence of AC at the 6-month follow-up, whereas all other patients remained in remission until the end of the observation period. The complete clinical cure rate at 1 year after a single Alacare patch PDT thus was 84.2%. Pain during illumination and the phototoxic skin reaction were in general mild to moderate. The cosmetic outcome was excellent.

Conclusion The present prospective study on Alacare patch PDT for AC confirms its high clinical efficacy, good tolerability and favourable cosmetic effects. Alacare patch PDT should be considered as a valid treatment option for patients with AC.

Received: 20 October 2019; Accepted: 8 January 2020

Conflicts of interest

None.

Funding source

Spirig Pharma, Linz, Austria.

Introduction

Actinic cheilitis (AC), also known as solar or actinic keratosis (AK) of the lip, is a preinvasive, malignant skin condition that can progress into squamous cell carcinoma (SCC) with a high tendency to metastasize. AC is mostly caused by chronic sun exposure, and the lower lip is affected more frequently than the upper lip because of its more direct exposure to sunlight.¹

The global prevalence of AC lies between 0.45% and 2.4%. In population groups engaged in outdoor activities, prevalence

rates between 4.2% and 43.2% are reported.² The risk of transformation into SCC of the lips was estimated to be 10–30%,^{2,3} and 95% of all SCC of the lips originate from AC.³ In a retrospective study, over 10 years on AC in 65 patients, 11 patients (16.9%) already had SCC at the initial examination, and in two patients (3.2%), AC progressed into SCC over a period of 2.4 and 2.8 years, respectively.¹ The anatomical location and the biological characteristics of the vermilion (thin, lightly keratinized epithelium with little melanin and fewer secretion from

sebaceous and sweat glands) render the lips sensitive to damage by solar radiation.⁴ AC is clinically characterized by atrophy, dryness, desquamation, mottled pigmentation and erosion of the lips. Histopathology of AC includes acanthosis or atrophy of the epithelium, thickening of the keratin layer and various degrees of dysplasia. A basophilic degeneration of elastotic fibres, called solar elastosis, is present in the upper dermis.²

Photodynamic therapy (PDT) has evolved in recent years as an emerging treatment for AC although the results so far have been inconsistent and inferior to those obtained in the treatment of AK.^{5–10} Using Alacare patch PDT, we have previously obtained very promising results in a retrospective analysis of 11 patients with 15 AC lesions on the lower and/or upper lip.¹¹ Alacare is a self-adhesive, skin-coloured medicated patch containing a standardized amount of 2 mg 5 ALA per cm². Based on our encouraging preliminary results, we initiated a prospective study and recruited 21 further patients with mild-to-moderate AC. All patients received one single treatment with Alacare patch PDT and were subsequently followed over 12 months to assess short- and long-term efficacy, tolerability safety, cosmetic outcome and patients' satisfaction.

Patients and methods

Patients

Inclusion criteria were a clinical diagnosis of mild-to-moderate AC affecting the lower and/or upper lip, an age over 18 years and the ability to attend for follow-up examinations up to 1 year after PDT. Exclusion criteria were intolerance against aminolevulinic acid, any other dermatological lip affection that could affect the skin assessment after PDT, abnormal light sensitivity in the visible light range, any topical treatment within the previous 3 months and chronic immunosuppression. The study was approved by our local ethics committee, and informed consent to participation was obtained from all patients.

Methods

No pretreatment of the lesions was performed. The Alacare patches (photonamic GmbH und Co. KG, Pinneberg, Germany) were applied directly on the whole lip, including areas that were visibly normal and left there for 4 h. If required, the patches were fixed with additional medical tapes to achieve a tight contact with the lips. The patch was then removed, and the lip was cleaned with a 0.9% saline solution. The amount of accumulated protoporphyrin IX was evaluated by examination of the treated lip under a black-light-emitting Wood lamp and visual assessment of the fluorescence intensity. To minimize PDT-induced pain, all patients then received local anaesthesia by oral mucosal injection of 1% mepivacaine. Ten minutes later, illumination was performed with red light at a wavelength of 635 ± 9 nm (BF-Rhodo LED; Biofrontera Pharma GmbH, Leverkusen, Germany). The applied light dose was 37 J/cm² at a light

intensity of 61.7 mW/cm². The illumination time was 10 min. During PDT, the lips were cooled by a cold air blower (-30°C ; CRIOjet Air Mini; Linde Gas Therapeutics GmbH, Unterschleißheim, Germany). Control visits were scheduled at 2 and 7 days and 3, 6 and 12 months after PDT. The patients additionally received a prescription for valaciclovir and were advised to start treatment immediately in case of signs or symptoms of herpes simplex reactivation. Photographs were taken under standardized conditions at each clinical visit.

The intensity of PDT-induced pain was graded by the patients on a visual analogue scale (VAS) between 0 (no pain) and 10 (worst pain imaginable) at 1, 5 and 10 min after initiation of treatment. The intensity of the phototoxic reaction was assessed at 10 and 30 min after PDT. To this purpose, erythema, oedema and blistering was graded on a scale between 0 and 4 (0 = absent, 1 = slight, 2 = moderate, 3 = strong and 4 = very strong). The response to PDT, recurrence rates and cosmetic outcome were determined at 3, 6 and 12 months after PDT by clinical inspection and comparison with baseline photographs. The patients' satisfaction with the treatment was recorded at the end of the study.

In case of incomplete response or recurrence of AC, a biopsy was taken for histopathological examination. AC lesions that were not cleared at the 3-month follow-up visit or recurred thereafter were treated with imiquimod or a KTP laser according to the patient's preference.

Results

Twenty-one patients (13 women and eight men) were included into the trial. Their age ranged from 47 to 90 (mean, 68.5) years. The lower lip was affected in 18 patients and the upper lip in three patients. In eight patients, the clinical diagnosis had previously been confirmed by histopathology. Nineteen patients completed the trial according to the protocol. One patient was excluded from evaluation because the Alacare patch had detached from the lip before illumination. Another patient was unable to attend to the follow-up visits because of medical problems unrelated to the PDT treatment. A flow chart diagram of the study population is shown in Fig. 1.

Complete clinical response at the 3-month follow-up was achieved in 17 (89.5%) of the remaining 19 patients (Fig. 2). Two patients with AC on the lower lip only showed partial improvement and were referred to laser treatment. Within the further follow-up period, one recurrence was observed at 6 months after PDT, and all other 16 patients remained in remission until the last visit at 12 months after treatment. The complete clearance rate of AC after one Alacare patch PDT session thus was 84.2% (16/19).

Biopsies were performed in patients with incomplete cure of AC at 3 months after PDT or in cases of suspected relapse at the further follow-up visits up to 12 months of treatment. In two patients with clinically partial response at the 3-month visit,

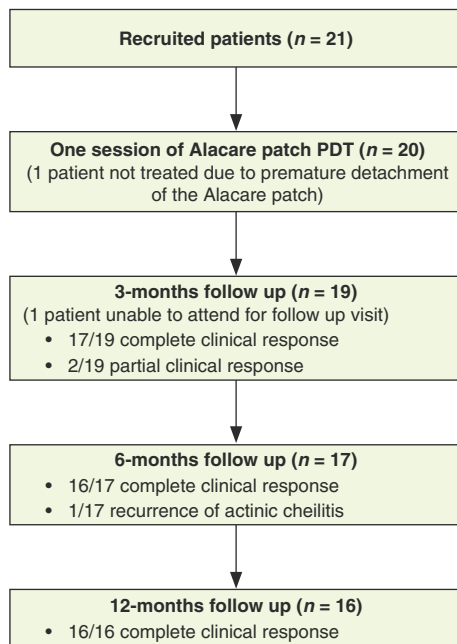


Figure 1 Flow chart diagram of the study population.

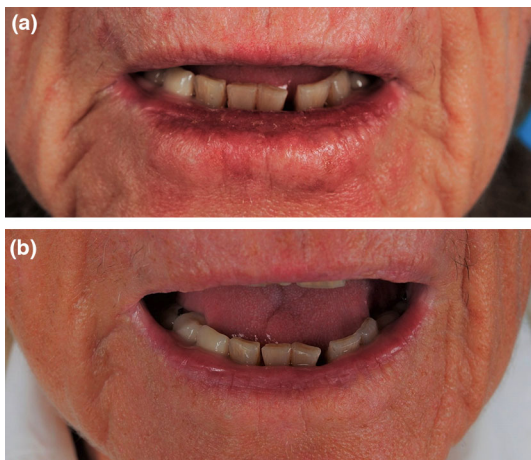

Figure 2 80-year-old lady with actinic cheilitis of the lower lip before (a) and 12 months after one single ALA patch photodynamic therapy treatment (b). Note the complete clinical cure and excellent cosmetic result.

histopathology confirmed the persistence of AC. In three further patients with a suspected relapse of AC at 6 and 9 months after PDT, respectively, histopathology was normal in two patients and positive for AC in one patient.

Moderate PDT-induced pain was the major side-effect of treatment. The mean VAS score at the beginning, in the middle and at the end of treatment was 3.4 (range 1–8), 4.5 (range 1–7)

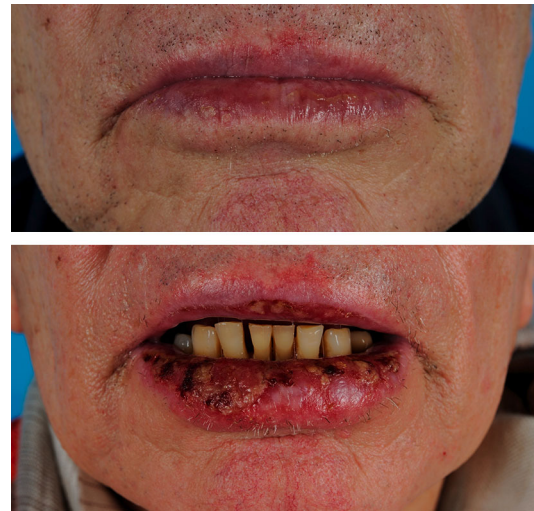

Figure 3 Severe phototoxic reaction with the swelling, blistering, erosions and crusts on the lower lip 1 week after Alacare patch photodynamic therapy.

and 3.5 (range 1–7), respectively. PDT induced a mild-to-moderate phototoxic skin reaction with oedema, blistering and erosions in all but four patients in whom the reaction was severe (Fig. 3). All signs of phototoxicity resolved completely within 14 days after PDT. Three patients experienced reactivation of herpes virus infection at 3 ($n = 2$) and 5 days ($n = 1$) after PDT that was well controlled by immediate administration of valacyclovir.

The cosmetic outcome in 16 out of 19 patients (84%) was excellent with complete clinical clearing of the affected lip and a total absence of scarring. Accordingly, responders were extremely satisfied with the treatment, whereas the three patients with partial response or recurrence of AC rated Alacare patch PDT as not satisfactory.

Discussion

Actinic cheilitis is a common premalignant condition of mostly the lower lips whose incidence is associated with advancing age, skin phototype and cumulative UV exposure. Given its propensity to progress into SCC, AC needs to be treated. A broad variety of therapeutic measures are available for AC including cryotherapy, electrodesiccation, carbon dioxide or Er:YAG laser ablation, trichloroacetic acid chemical peel, surgical excision (vermillionectomy), 5-fluorouracil, imiquimod, ingenol mebutate, diclofenac 3% gel with hyaluronic acid 2.5% and photodynamic therapy.^{3,6} A recent review analysed the outcome of surgical ($n = 122$) vs. non-surgical ($n = 161$) treatments in 283 patients with AC who were included in 10 studies. Remission and recurrence rates were 92.8% and 8.4% in patients who received surgical treatment and 65.9% and 19.2% in patients

who received non-surgical interventions, respectively.³ However, these findings were challenged due to the small number of included patients, lacking assessment of bias risk and the fact that all but one study had a low level of evidence.¹²

In conventional PDT, the topical photosensitizer (5-aminolevulinic acid or methyl aminolevulinate) is applied under an occlusive foil. In contrast, Alacare patch PDT uses self-adhesive, skin-coloured medicated plasters of 4 cm² containing 8 mg 5-aminolevulinic acid (2 mg/cm²) that can be applied directly on lesional skin without additional occlusive dressing.

In an earlier retrospective evaluation of 11 patients with 15 AC lesions who were treated once or twice with Alacare patch PDT and followed for 1 year, we found a complete response rate of 80%.¹¹ Encouraged by these favourable results, we extended our previous work by means of a prospective study on another 21 patients. Besides being prospective rather than retrospective, the present study differs from the earlier trial in two further respects. Firstly, all patients received only one PDT since we previously found no difference in clinical cure rate after one or two PDT exposures. Secondly, local anaesthesia by oral mucosal injection of 1% mepivacaine and a cold air blower were used in all patients to attenuate PDT-induced pain during illumination. A complete clearance of AC up to 12 months after Alacare patch PDT was achieved in 84% (16/19) of the patients, which is almost identical to the response rate found in our first study.

Patch application of ALA presumably allows for improved penetration into lesional skin resulting in enhanced protoporphyrin IX synthesis and subsequent phototoxic destruction of dysplastic cells. In support of this assumption is the fact that Wood lamp examination consistently revealed a marked bright red fluorescence in the lesional skin after removal of the Alacare patches indicating high levels of accumulated protoporphyrin IX. Accordingly, we observed a severe phototoxic reaction in some of our patients after PDT.

A limiting factor of our study is the fact that clearance of AC was determined by clinical assessment but not confirmed by histopathology. Given that the concept of field cancerization also applies to AC, we always treated also the whole lip, including areas without visible signs of AC. At the follow-up visits, we only took biopsies in case of visually incomplete cure at 3 months after PDT or in case of suspected relapse of AC at 6 or 12 months after PDT. In a previous study on PDT for AC with an 18-month follow-up period, the clinically diagnosed recurrence rate was 15.4% (4/26) opposed to a histological recurrence rate of 34.6% (9/26).⁸ Thus, the accordance rate between the clinical and histopathological diagnosis was 77% (17/22), whereas 23% (5/22) of clinically cured patients still had signs of AC in histopathology. The implication of this finding is, however, unknown. As yet it has not been investigated whether histologically residual disease is associated with a poorer long-term outcome or a higher rate of progression into SCC of the lip. Given the fact that in AK neither the clinical manifestation nor

the histopathological features allow to predict the likelihood of malignant transformation,^{13–15} it seems reasonable to assume that the same may hold true for AC.¹⁶ In patients with complete clinical cure, we therefore took a real-life approach and only performed regular clinical follow-up examinations.

One of the major limiting factors of PDT is the frequent occurrence of severe pain during illumination. In our study, the average pain was only moderate and all but one patient had a maximum VAS score lower than 8. The good tolerability is likely due to the fact that we employed local anaesthesia in conjunction with a cold air blower as two measures to alleviate PDT-induced pain. This allowed us to perform PDT in all patients at the predetermined light intensity and dose without the need for interruption or modification of the illumination. Oral mucosal injection of 1% mepivacaine was found to be simple and well tolerated by all patients. Another possible adverse reaction when performing PDT of the lips is herpes simplex reactivation that occurred in 15% (3/20) of our patients. The flare resolved quickly in all patients under valaciclovir treatment.

Besides showing a very high response rate after only one single treatment session, Alacare patch PDT also resulted in an excellent cosmetic outcome. Resolution of AC occurred without scarring and was associated with an apparent improvement of photodamaged skin. Effects of PDT on photodamaged skin have been increasingly investigated in the last decade and opened up an entirely new field of PDT usage termed photorejuvenation.¹⁷ Reduction of the subepidermal low-echogenic band (SLEB) thickness and an increase in diffuse echogenicity have been shown in photodamaged skin after PDT suggesting dermal reshaping by new deposition of collagen fibres.¹⁸

To summarize, the present prospective study on Alacare patch PDT for AC is in support of earlier data demonstrating high clinical efficacy, good tolerability and a favourable cosmetic outcome. Alacare patch PDT has evolved as a rewarding routine procedure for patients with AC at our institution. Our approach is to perform one single PDT session of the whole affected lip followed by regular clinical follow-up examinations. In cases with suspicion of recurrence, biopsies are taken for validation of the clinical diagnosis.

Acknowledgement

The study was supported by a scientific grant from Spirig Pharma, Linz, Austria.

References

- 1 Markopoulos A, Albanidou-Farmaki E, Kayavis I. Actinic cheilitis: clinical and pathological characteristics in 65 cases. *Oral Dis* 2004; **10**: 212–216.
- 2 de Santana Sarmento DJ, da Costa Miguel MC, Queiroz LM *et al.* Actinic cheilitis: clinicopathologic profile and association with degree of dysplasia. *Int J Dermatol* 2014; **53**: 466–472.
- 3 Carvalho MVE, de Moraes SLD, Lemos CAA. Surgical versus non-surgical treatment of actinic cheilitis: a systematic review and meta-analysis. *Oral Dis* 2019; **25**: 972–981.

- 4 Rodriguez-Blanco I, Florez A, Paredes-Suarez C *et al*. Actinic cheilitis and risk factors: a cross-sectional multicentre study in a population aged 45 years and over in north-west Spain. *Acta Derm Venereol* 2018; **98**: 970–974.
- 5 Shah AY, Doherty SD, Rosen T. Actinic cheilitis: a treatment review. *Int J Dermatol* 2010; **49**: 1225–1234.
- 6 Salguero AP, de Jesus LH, de Souza IF *et al*. Treatment of actinic cheilitis: a systemic review. *Clin Oral Invest* 2019; **23**: 2041–2053.
- 7 Abyaneh M-AY, Falto-Aizpurua L, Griffith RD, Nouri K. Photodynamic therapy for actinic cheilitis: a systemic review. *Dermatol Surg* 2015; **41**: 189–198.
- 8 Sotirou E, Apalla Z, Chovarda E, Panagiotidou D, Ioannides D. Photodynamic therapy with 5-aminolevulinic acid in actinic cheilitis: an 18-month clinical and histological follow up. *J Eur Acad Dermatol Venereol* 2010; **24**: 916–920.
- 9 Chaves YN, Torezan LA, Lourenco S, Neto CF. Evaluation of the efficacy of photodynamic therapy for the treatment of actinic cheilitis. *Photodermatol Photoimmunol Photomed* 2017; **33**: 14–21.
- 10 Berking C, Herzinger T, Flaig MJ, Brenner M, Borelli C, Degitz C. The efficacy of photodynamic therapy in actinic cheilitis of the lower lip: a prospective study of 15 patients. *Dermatol Surg* 2007; **33**: 825–830.
- 11 Radakovic S, Tanew A. 5-Aminolevulinic acid patch PDT in the treatment of actinic cheilitis. *Photodermatol Photoimmunol Photomed* 2017; **33**: 306–310.
- 12 Brignardello-Petersen R. Evidence regarding how surgical treatment of actinic cheilitis compares with nonsurgical treatment is not trustworthy and does not consider all important outcomes. *J Am Dent Assoc* 2019; **150**: e6.
- 13 Schmitz L, Kahl P, Majores M *et al*. Actinic keratosis: correlation between clinical and histological classification systems. *J Eur Acad Dermatol Venereol* 2016; **30**: 1303–1307.
- 14 Fernandez-Figueras MT. From actinic keratosis to squamous cell carcinoma: pathophysiology revisited. *J Eur Acad Dermatol Venereol* 2017; **31**: 5–7.
- 15 Fernandez-Figueras MT, Carrato C, Saenz C *et al*. Actinic keratosis with atypical basal cells (AK I) is the most common lesion associated with invasive squamous cell carcinoma of the skin. *J Eur Acad Dermatol Venereol* 2015; **29**: 991–997.
- 16 Nagata G, Santana T, Queiroz A *et al*. Evaluation of epithelial dysplasia adjacent to lip squamous cell carcinoma indicated that the degree of dysplasia is not associated with occurrence of invasive carcinoma in this site. *J Cutan Pathol* 2018; **45**: 647–651.
- 17 Karrer S, Kohl E, Feise K *et al*. Photodynamic therapy for skin rejuvenation: review and summary of the literature-results of a consensus conference of an expert group for aesthetic photodynamic therapy. *J Dtsch Dermatol Ges* 2013; **11**: 137–148.
- 18 Zane C, Capezzer R, Sala R, Venturini M, Calzavara-Pinton P. Clinical and echographic analysis of photodynamic therapy using methylaminolevulinic acid as sensitizer in the treatment of photodamaged facial skin. *Lasers Surg Med* 2007; **39**: 203–209.