



Congenital unilateral diaphragmatic eventration in an adult: A rare case presentation



Johann Paulo S. Guzman (MD)*, Nilo C. Delos Santos (MD), Edgar A. Baltazar (MD), Allan Troy D. Baquir (MD)

Department of Surgery, 4th Floor, East Avenue Medical Center, East Avenue, Diliman, Quezon City, Philippines

ARTICLE INFO

Article history:

Received 7 March 2017

Received in revised form 16 April 2017

Accepted 16 April 2017

Available online 18 April 2017

Keywords:

Diaphragmatic plication

Diaphragmatic eventration

Atelectasis

ABSTRACT

We present a rare case of 32 year old female with congenital diaphragmatic eventration female presenting in an adult. She had symptoms of intermittent dyspnea and occasional epigastric discomfort. Patient had no previous history of trauma. Physical examination showed bowel sound involving the left hemithorax. Imaging modalities confirmed the diagnosis of a congenital left diaphragmatic eventration. Patient underwent plication of the diaphragm using the abdominal approach. Intra-operatively, the left diaphragm was attenuated. Plication was done with 1st layer of imbricating silk heavy sutures buttressed by a second layer of interrupted absorbable sutures. She post-operatively had atelectasis on the left lung. Incentive spirometry and deep breathing exercises were started with resolution of the atelectasis after 1 week post-operatively. Patient had an unremarkable post-operative stay with resolution of symptoms. There are reports that diaphragmatic eventration diagnosed even as late 70 years old, highlighting the dogma that this is an asymptomatic disorder does not need all the time surgical therapy. But we still recommend surgical therapy as soon as diagnosis is confirmed. In this patient, there was no recurrence of symptoms after a follow-up of 2 years. Whether surgery indeed improved lung functions in these vastly asymptomatic patients, these questions could be an active area of research in the long term outcomes of these patients.

© 2017 Published by Elsevier Ltd on behalf of IJS Publishing Group Ltd. This is an open access article under the CC BY-NC-ND license (<http://creativecommons.org/licenses/by-nc-nd/4.0/>).

1. Introduction

Diaphragmatic eventration is largely diagnosed in the pediatric age group. The difference between eventration and hernia was recorded by Bisgard in 1947, who describes eventration as an abnormally high, or elevated position of one leaf of the diaphragm as a result of paralysis, or atrophy of varying degree of the muscle fibers. Its unbroken continuity differentiates it from diaphragmatic hernia [1].

Diaphragmatic eventration is a congenital developmental defect of the muscular portion of the diaphragm. It has been attributed to abnormal myoblast migration to the septum transversum and the pleuroperitoneal membrane. Diaphragmatic eventration is rare (incidence <0.05%), being more common in males. It can be unilateral or bilateral, but it usually involves the left hemidiaphragm [2]. Macroscopically, the affected diaphragm is attenuated, abundant, and membranous without muscular appearance. Microscopically, there is paucity or absence of muscular fibers and diffuse fibro elastic changes. Eventration results in diaphragmatic elevation and cephalad displacement if the underlying abdominal viscera [2,3].

Diaphragmatic plication is a well-established treatment for the condition and several studies have demonstrated it to be a safe procedure with good long term results. Plication can be done through the abdominal or thoracic route [4].

It is rare that congenital diaphragmatic eventration can present among adults. Most adult patients with diaphragmatic eventration remain asymptomatic, and the diagnosis is made incidentally after chest radiography. Among symptomatic patients, the most common symptom is dyspnea. Gastrointestinal symptoms may be present including epigastric discomfort, heartburn, bloating constipation and weight loss. There is indication for surgical intervention only in the presence of symptoms [2,5].

2. Case report

We report a case of a 32 year old female who presented with intermittent dyspnea and occasional mild epigastric discomfort. On physical examination there were decreased breath sounds in the left thorax with note of gurgling bowel sounds. The cardiac examination was unremarkable with regular cardiac rate, rhythm and no murmurs were noted. Chest X-ray showed the presence of bowel loops in the left thorax and the cardiac shadow shifted to the right. (Fig. 1). Impression was diaphragmatic hernia versus eventration. Chest Ct-scan with IV and oral contrast was requested to

* Corresponding author.

E-mail address: yooohannn@yahoo.com (J.P.S. Guzman).

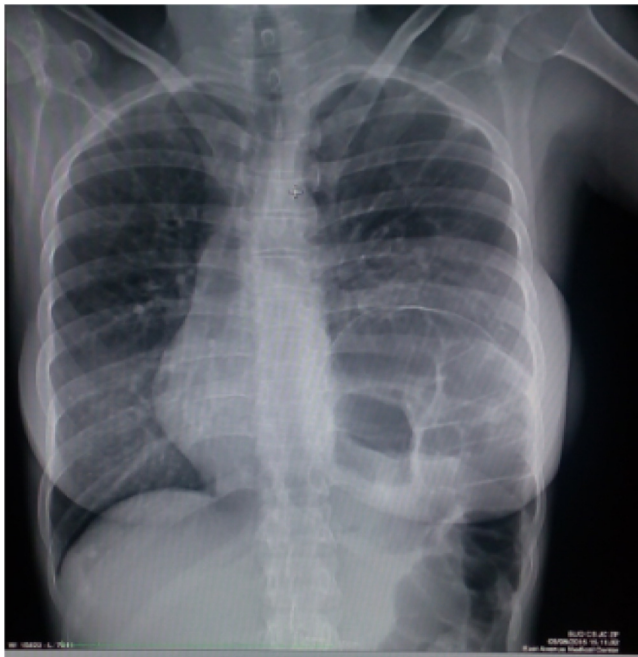

Fig. 1. Chest Xray AP view showing shift of the cardiac shadow to the right with note of bowel loops in the left thorax.

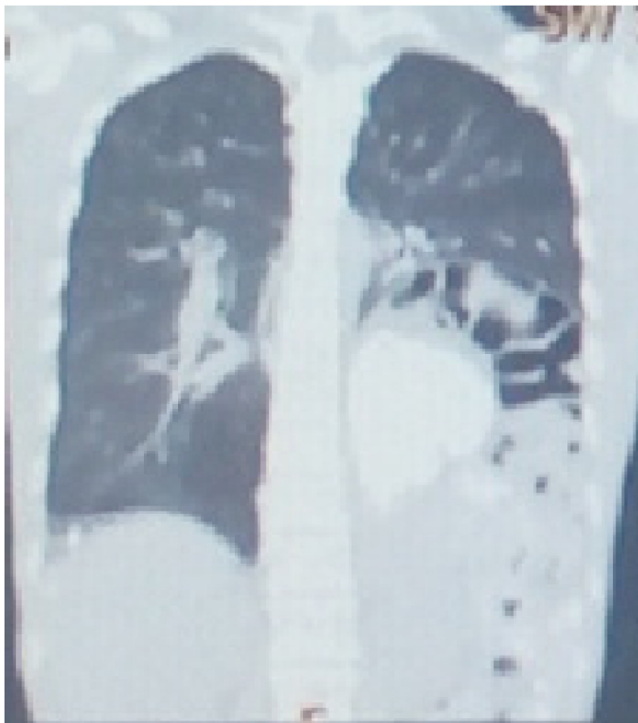

Fig. 2. Coronal view of the Chest CT-scan IV and oral contrast showing gastric and bowel contents in the left hemithorax.

further outline the anatomy. The scan showed bowel loops in the left hemithorax with no masses noted in the chest (Figs. 2 and 3).

A barium swallow was done clearly showing gastric contents located in the left hemithorax and no defects were noted in the left diaphragm. No radiologic evidence of gastric volvulus was noted (Figs. 4 and 5)

The patient underwent plication of the left diaphragm though the abdominal approach. Intra-operatively, the diaphragm was

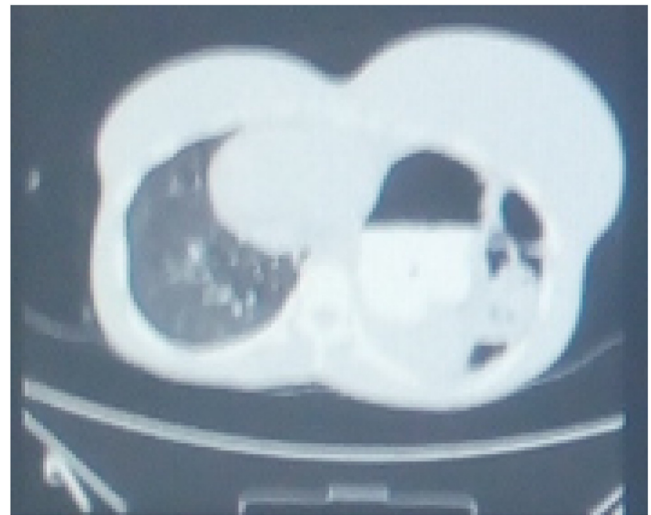


Fig. 3. Axial view of the Chest CT-scan IV and oral contrast showing gastric and bowel contents in the left hemithorax.

Dye outlining gastric fundus, cardia and body

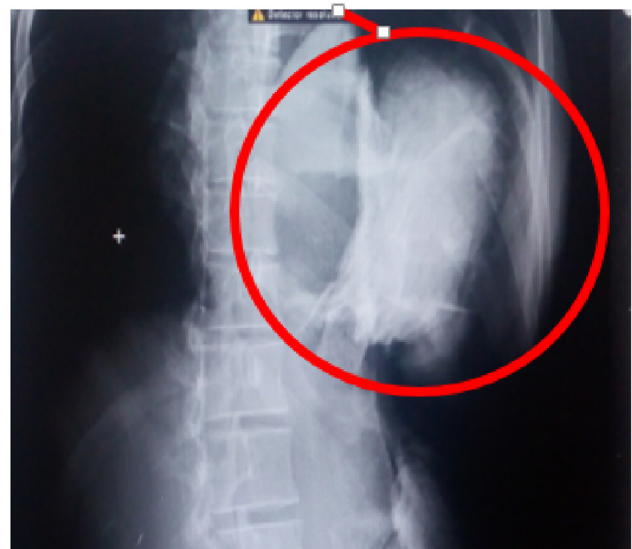

Fig. 4. Barium swallow outlining the gastric fundus, cardia and body which was located in the left hemithorax.

noted to be thinned out with the central portion of the left diaphragm attenuated and membranous (Fig. 6).

Plication was done using 2 layered imbricated vertical mattress sutures. The first layer was composed of heavy non absorbable silk sutures and the 2nd layer was a composed buttress suture of polyglycolic absorbable heavy sutures. (Figs. 7 and 8)

Post-operatively Chest x-ray of the patient showed atelectasis of the left lung. The patient was started on incentive spirometry and deep breathing exercises (Fig. 9). Patient was started of feeding and was discharged 1 week post-operatively with the lungs fully expanded. Patient has an unremarkable post-operative course. (Fig. 10)

After 2 years, patient had followed-up with us and reported no dyspnea, no epigastric pain with full return to activities. Baseline arterial blood gases taken were within normal limits.

Diaphragm noted without any defects

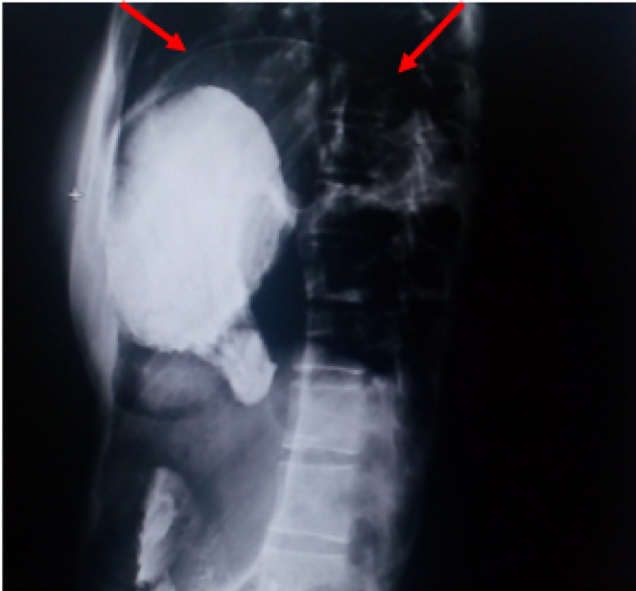


Fig. 5. Clear delineation of the left diaphragm outline with no defects noted.

Left Diaphragm appears to be thinned out

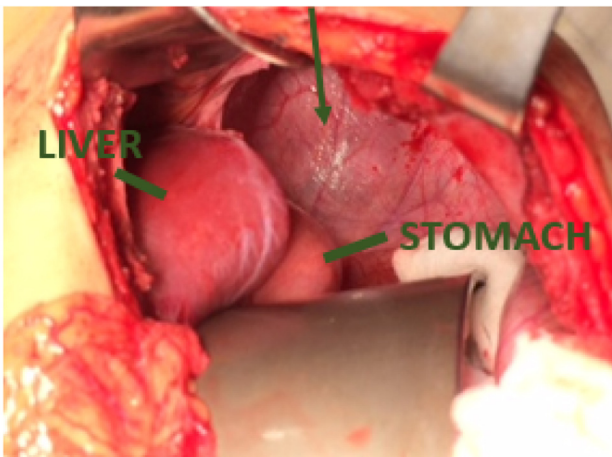


Fig. 6. Diaphragm appears to be thinned out and attenuated intra-operatively.

3. Discussion

Management of diaphragmatic eventration varies greatly on the symptoms of the patients. Simple cases of diaphragmatic eventration may not require intervention when not associated with adverse symptoms. Plication is indicated if there are symptoms of dyspnea which can be due to decrease ventilation and oxygenation because of paradoxical motion of the affected diaphragm during inspiration and expiration. The abdominal approach is widely accepted approach because this allows ready access to both diaphragms and it permits abdominal exploration for evaluation of other gastrointestinal symptoms experienced by the patient [6]. We did an abdominal approach to evaluate the abdomen because the patient had epigastric discomfort. Epigastric pain, bloatedness, early satiety and poor intake are signs of gastric volvulus. Intra-operatively, there was no note of gastric volvulus only that the fundus was elongated with the cardia reaching high up to the left quadrant of the abdomen. The stretching of the stomach was probably the cause of the epigastric discomfort in this patient.

Imbricating sutures to in fold the diaphragm

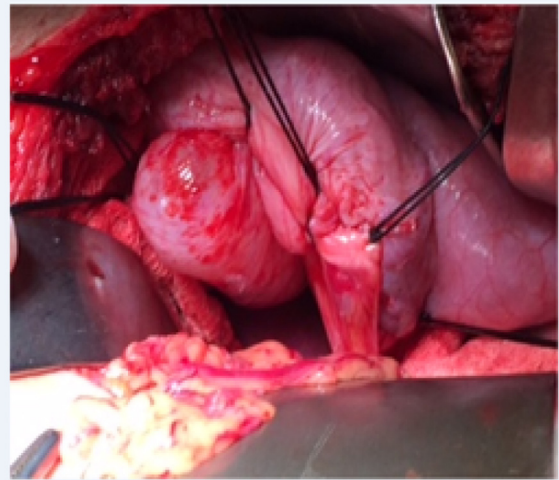


Fig. 7. 1st layer of imbricating sutures to the diaphragm.

Buttress sutures to reinforce the 1st layer of sutures (2nd layer)

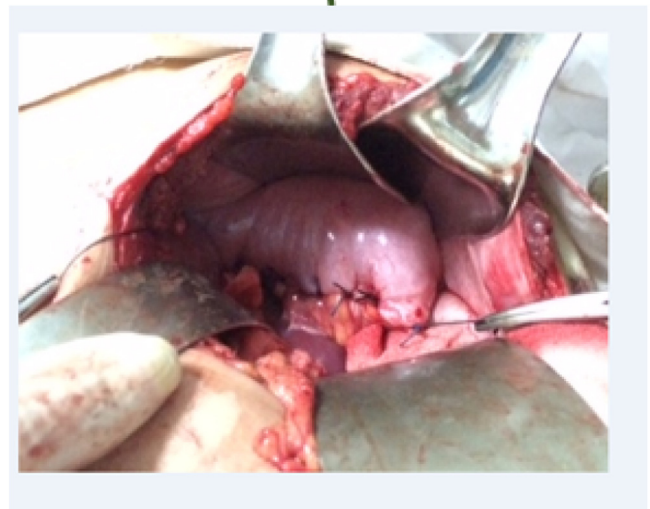

Fig. 8. 2nd layer of buttress sutures to reinforce the 1st layer.

Multiple imaging modalities are available for the pre-operative diagnosis of diaphragmatic problems. Chest radiographs are the initial and most commonly performed imaging to evaluate the diaphragm. When chest radiographs are indeterminate to differentiate between eventration and hernia. A Ct-scan with thin sections can evaluate the diaphragm and oral contrast swallow can clearly outline upper abdominal organs that were visualized in plain radiographs [7]. It is important to differentiate diaphragmatic hernia and eventration to be able to plan surgical management pre-operatively. In this patient, she presented with symptoms similar to diaphragmatic hernia, thus a combination of imaging modalities help in the diagnosis in this patient. We highlight the importance of good physical examination and judicious use of imaging modalities among patients suspected of diaphragmatic eventration.

Complications after abdominal plication of a diaphragmatic eventration commonly include atelectasis and rarely, abdominal compartment syndrome and splenic injury after mobilization of

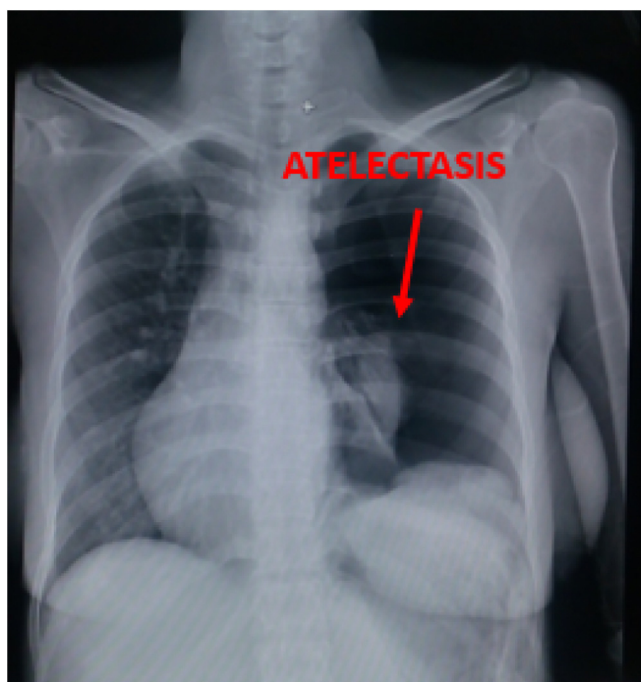


Fig. 9. Chest Xray taken on the first operative day showing atelectasis on the left lung.

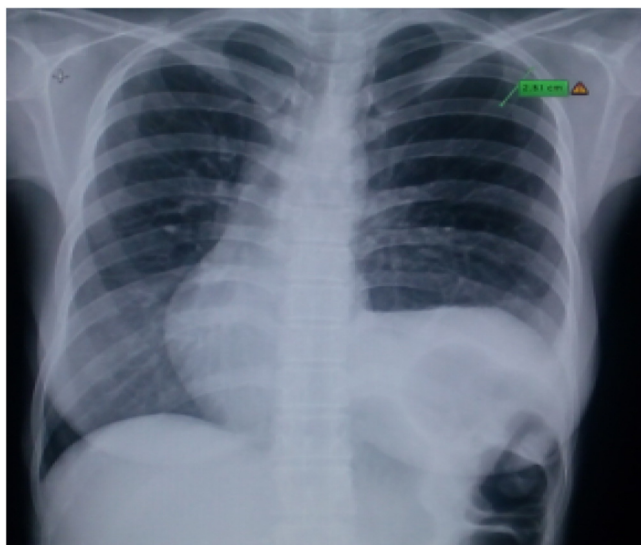


Fig. 10. Chest Xray taken 1 week post-operatively showing left lung expansion and elevated left hemidiaphragm.

the left upper quadrant abdominal structures. [4,8] Atelectasis seen in our patient may be explained by the hypo-ventilated lung secondary to relatively immobile left diaphragm. Thus incentive spirometry, adequate analgesia and deep breathing exercises are usually recommended after plication.

The aim of surgical repair is to place the diaphragm in a position of maximum inspiration which relieves compression on the lung parenchyma and allows its re-expansion. Literature states that the plicated diaphragm is still immobile and even though elevated, plication prevents paradoxical motion during breathing [9]. This explains how the elevated diaphragm in this patient after surgical plication afforded symptomatic relief even if radiological studies showed significant elevation of the affected diaphragm compared to the contralateral side. Potential benefits of diaphragmatic pli-

cation are still uncertain in the long term period. But several case reports describe patients to return to a more or less normal way of life with significant improvement of pulmonary function status [10]. Thus, follow-up is important in patients who underwent plication of diaphragmatic eventration to assess recurrences and its long term complications. Although the patient had follow-up up until 2 years, long term benefits in these patients are yet still to be determined. While others argue that since these are cases diagnosed incidentally, the value of surgical repair done in eventration may be limited. But we still recommend surgery once diagnosis is confirmed if not for better lung mechanics but to prevent other complications such as gastric volvulus. While the incidence of gastric volvulus in the setting of eventration has yet to be widely determined, the repair of eventration to prevent this complication theoretically will benefit the patient.

This manuscript is reported in line with the SCARE criteria [11].

Conflict of interest

I have no conflict of interest, this paper was not funded and all of the contents and expenses in the making of this paper is purely voluntary in nature.

Source of funding

This paper was not funded and it has no study sponsors.

Ethical approval

This paper did not require an ethical approval since it is retrospective case report in nature.

Consent

Although, this is a case report, the patient consented to this publication. No identifying characteristics are presented in this paper that could compromise the patient's anonymity.

Authors contribution

Johann Paulo S. Guzman MD – concept, collection, data analysis, writing of the paper.

Nilo C. Delos Santons MD– data analysis and interpretation.

Allan Troy D. Baquir MD – data analysis and interpretation.

Edgar A Baltazar MD – data analysis and interpretation.

Registration of research studies

This is case report and was not registered with a UIN.

Guarantor

I am the guarantor, Johann Paulo Guzman.

References

- [1] F. Paris, E. Blasco, A. Canto, V. Tarazona, M. Casillas, Diaphragmatic eventration in infants, *Thorax* 28 (1) (1973) 66–72.
- [2] A.N. Visouli, A. Mpakas, P. Zarogoulidis, N. Machairiotis, A. Stylianaki, N. Katsikogiannis, K. Zarogoulidis, et al., Video assisted thoracoscopic plication of the left hemidiaphragm in symptomatic eventration in adulthood, *J. Thorac. Dis.* 4 (1) (2012) 6–16.
- [3] P.D. Sinwar, Gastric mesenteroaxial volvulus with partial eventration of left hemidiaphragm: a rare case report, *Int. J. Surg. Case Rep.* 9 (2015) 51–53.
- [4] S. Pathak, R. Page, Splenic injury following diaphragmatic plication; an avoidable life threatening complication, *Interact. Cardiovasc. Thorac. Surg.* (2009) 1045–1046, Retrieved from <http://icvts.oxfordjournals.org/content/9/6/1045.full.pdf>.

- [5] M.R. Srikrishna, N.R. Ravishankar, J. Raghavan, M.K. Natarajan, Surgical repair of congenital diaphragmatic eventration in a septuagenarian lady, *Braz. J. Cardiovasc. Surg.* 25 (1) (2010) 115–117.
- [6] N.N. Shah, M. Mohsin, S.Q. Khursheed, S.S.A. Farooq, A.A. Buchh, A.Q. Quraishi, Eventration of diaphragm with gastric volvulus; a case report, *Cases J.* (online) 1 (404) (2008) 1–3, Retrieved from <http://www.casesjournal.com/content/1/1/404>.
- [7] S.K. Mantoo, K. Mak, Congenital diaphragmatic eventration in an adult: a diagnostic dilemma, *Singap. Med. J.* 48 (5) (2007) 137–139.
- [8] J. Phadnis, J.E. Pilling, T.W. Evans, P. Goldstraw, Abdominal compartment syndrome: a rare complication of plication of the diaphragm, *Ann. Thorac. Surg.* 82 (2006) 334–336.
- [9] S. Celik, M. Celik, B. Aydemir, C. Tunckaya, T. Okay, I. Dogusoy, Long-term results of diaphragmatic plication in adults with unilateral diaphragm paralysis, *J. Cardiothorac. Surg.* 5 (1) (2010) 1–7, 111; Retrieved from <http://www.cardiothoracicsurgery.org/content/5/1/11>.
- [10] M.I. Versteegh, J. Braun, P.G. Voigt, D.B. Bosman, J. Stolk, K.F. Rabe, R.A. Dion, Diaphragm plication in adult patients with diaphragm paralysis leads to long-term improvement of pulmonary function and level of dyspnea, *Eur. J. Cardiothorac. Surg.* 32 (2007) 449–456.
- [11] R.A. Agha, A.J. Fowler, A. Saetta, I. Barai, S. Rajmohan, D.P. Orgill, the SCARE Group, The SCARE Statement: consensus-based surgical case report guidelines, *Int. J. Surg.* 34 (2016) 180–186.

Open Access

This article is published Open Access at sciedirect.com. It is distributed under the [IJSCR Supplemental terms and conditions](#), which permits unrestricted non commercial use, distribution, and reproduction in any medium, provided the original authors and source are credited.