

CASE REPORT

Epigastric heteropagus conjoined twins: two case studies and associated DNA analysis

Jun-tao Xie,¹ Li Zhou,¹ Zhi-lin Yang,¹ Hong-yu Sun^{II}^ISun Yat-sen University, The First Affiliated Hospital of Guangzhou, Department of Pediatric Surgery, People's Republic of China. ^{II}Sun Yat-sen University, Zhongshan School of Medicine, Department of Forensic Medicine, Guangzhou, People's Republic of China.Email: lizhou18@hotmail.com
Tel.: 86-020-87335396

Conjoined twins are rarely observed, but heteropagus conjoined twins occur even less frequently. Heteropagus conjoined twins are asymmetrically conjoined twins, in which one twin is nearly anatomically normal (autosite), and the other twin remains anatomically incomplete (parasite) but physically attached to the autosite. Epigastric heteropagus conjoined twins (EHTs), referring to a parasitic twin who is attached to the epigastrium of the autosite, are extremely rare (1).

Due to the rare incidence of EHTs, there are few publications on this subject, which has resulted in a general lack of knowledge among surgeons with respect to how to approach the management of EHTs. Furthermore, EHTs generally manifest as more medically complex situations than typical conjoined twins. Therefore, the etiology, manifestation, and therapeutic outcomes of EHTs remain controversial. In this article, we report two cases of EHTs encountered in our department between May 2007 and October 2007. One EHT case involved a large ventral hernia near the omphalocele, which has not been previously reported. Moreover, DNA analysis of case number 2 suggested a monozygotic origin of the EHTs.

CASE DESCRIPTION

Case 1: The first patient was a 1-day-old, full-term normal delivery (FTND) male. The parasite was attached to the epigastrium of the autosite. The parasite possessed two upper limbs, two lower limbs, a pelvis, and a well-developed scrotum and penis, which produced urine discharge (Figure 1-A). However, the limbs of the parasite had neither active movement nor response to tactile stimulus. Surgery to separate the twins was performed during the third month after birth. The parasitic twin was connected to the sternum of the autosite by a tract of cartilage. Furthermore, the liver of the parasite was connected to the liver of the autosite such that the extrahepatic bile duct system was absent (Figure 1-B). The main vascular pedicle of the parasite originated from the falciform ligament of the autosite. The pelvis of the parasite contained two functioning kidneys (Figure 1-C), a urinary bladder, and a small intestine but lacked a large intestine and

anus. The small intestine of the parasite displayed proximal atresia and opened distal to the urethra. Skeletal muscle was absent in the limbs of the parasite. On the fourteenth day after surgery to remove the parasitic twin, the autosite was discharged from the hospital without complications and was followed up for 52 months. Figure 1-D shows a representative image of the autosite in case 1 at 12 months after the operation.

Case 2: The second patient was also a 1-day-old FTND male. The total weight of the autosite and parasite was 3.4 kg. The parasitic twin consisted of 2 immobile lower limbs, buttocks, perineum, and masculine genitalia. The parasitic twin was attached to the epigastrium of the autosite, in whom an infected omphalocele and a large ventral hernia were found (Figure 2-A). The autosite was generally stable, and no respiratory distress was observed. The omphalocele was repaired on the eighth day after birth, and the parasitic twin was successfully removed on the twentieth day after birth (Figure 2-B). Similar to case 1, the parasite was attached to the sternum of the autosite through a tract of cartilage. The pelvis of the parasite contained one small kidney and a cyst (Figure 2-C). Skeletal muscle in the limbs of the parasitic twin was absent. The large hernia was not repaired during the separation of the twins to avoid "intra-abdominal compartment syndrome" (ICS) (2). The hernia was eventually repaired using Ethicon VYPRO II mesh (Ethicon, Somerville, N.J., USA) (Figure 2-D) when the autosite reached 20 months of age. The patient recovered from the hernia surgery without complications (Figure 2-E). DNA analysis was performed on the patient in case 2. DNA samples from the skin and hair of the autosite and from the skin and kidney of the parasitic twin were extracted using the rapid Chelex-100 method. A sex locus (amelogenin gene) and 15 STR loci were amplified using the PowerplexTM 16 system (Promega). PCR products were separated using an ABI3100 genetic analyzer (Applied Biosystems Inc.) and were genotyped using GeneMapper[®] 3.7 (Applied Biosystems Inc.). DNA analysis revealed that the parasitic twin in the second case had an identical genotype to the autosite, which indicated that they were of monozygotic origin (Figure 3). The autosite was followed up for 30 months, and Figure 2-F shows the patient in case 2 at 23 months after the surgical removal of the parasitic twin. The omphalocele and large hernia of the abdominal wall were closed completely in the patient in case 2.

In both of the case studies reported in this manuscript, the parasites were separated successfully, and both of the autosites have developed normally to date.

Copyright © 2012 CLINICS – This is an Open Access article distributed under the terms of the Creative Commons Attribution Non-Commercial License (<http://creativecommons.org/licenses/by-nc/3.0/>) which permits unrestricted non-commercial use, distribution, and reproduction in any medium, provided the original work is properly cited.

No potential conflict of interest was reported.

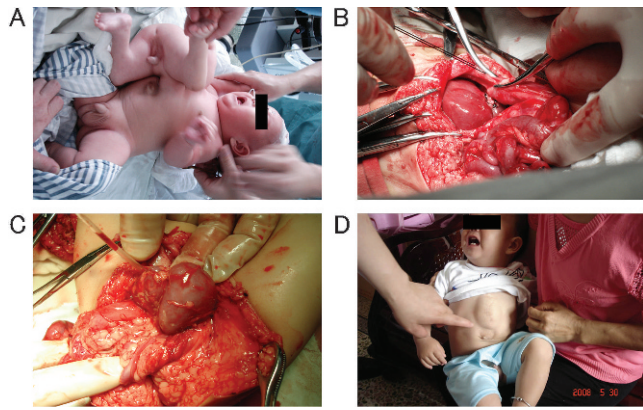


Figure 1 - (A) The parasitic twin in case 1 had a fully developed pelvis, two pairs of limbs, and a well-developed penis, which produced urine discharge. (B) The livers of the parasite and autosite were physically attached in case 1. (C) The parasitic twin in case 1 contained a pair of well-developed kidneys. (D) The autosite in case 1 during the twelfth month after the operation to remove the parasitic twin.

The reported incidence of conjoined twins varies between studies. Kallen et al. reported that the incidence of conjoined twins was 1 in 88,000 in Sweden based on 875,000 births between 1965 and 1974 (3). However, Edmonds et al. reported that the incidence of conjoined twins was 1 in 97,500 in the USA based on 7,903,000 births between 1970 and 1977 (4). Moreover, in China, Liang et al. reported that the incidence of conjoined twins was 3 in 100,000 based on 3,246,408 births from nearly 500 hospitals (5). The incidence

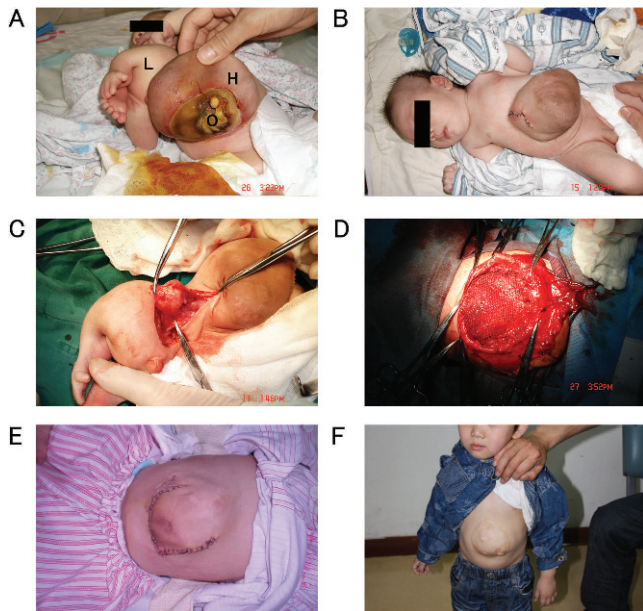


Figure 2 - (A) Large hernia of the abdominal wall (H), omphalocele (O) and limbs (L) of the parasitic twin in case 2. (B) View of the hernia in case 2. The parasitic twin was excised, and the omphalocele was repaired. (C) The pelvis of the parasitic twin in case 2 contained one small kidney and a cyst. (D) The hernia in case 2 was repaired using VYPRO II mesh. (E) Condition of the repaired ventral hernia in case 2 at 14 days after surgery. (F) The autosite in case 2 during the twenty-third month after the operation to remove the parasitic twin.

of conjoined twins is generally considered to be 1 in 50,000 to 200,000 births worldwide; however, only 10% of conjoined twins are heteropagus. Because of the low incidence of heteropagus conjoined twins, statistics on these twins are generally lacking.

The etiology of conjoined twins is complicated. Although monozygotic twins may be induced experimentally following the administration of a variety of teratogenic agents, the mechanism of induction of spontaneous twins remains unknown. The mechanism of the spontaneous generation of monozygotic twins is generally considered to derive from an error in blastogenesis by the incomplete fission of a single zygote, which occurs nearly 14 days after fertilization in humans (6). However, Roberto et al. reported a case of heteropagus conjoined twins that originated from the fusion of two embryos (7), and, along the same lines, Ratan et al. advocated a "fusion theory" (8). The parents of the patient in case 1 refused permission to perform DNA analysis on the twins, but in case 2, the DNA analysis of the patient indicated that the parasite had a genotype identical to the autosite, which suggested a monozygotic origin.

In contrast to the female predominance of symmetrically conjoined twins, a male predominance is observed in EHTs, accounting for approximately 78% of total EHT cases (9). This is consistent with our report, in which both of the patients were male. Skeletal muscle could not be found in any of the limbs of the parasitic twins, which could be the result of the absence of proper innervation. The absence of innervation results in the failure of myoblast differentiation and, therefore, causes skeletal muscle atrophy (10).

We identified cartilage connections to the sternum of the autosite in both of the parasitic twins. Both of the parasitic twins also had pelvises. Because the cartilages of the sternum, cutis, and pelvis are active centers of cell proliferation, we hypothesize that the parasitic twins originated from the stem cells of these tissues. Omphaloceles were present below the cartilage by which the twins were attached in both of our cases. Many studies have considered omphaloceles to be commonly associated anomalies in EHTs. Tongsin et al. reported four cases of EHTs, three of which were associated with omphaloceles (11). Manish et al. reported on two of three EHT cases that coincided with an omphalocele (1). Statistics have shown that omphaloceles exist in approximately 50% of all EHT cases (1). Regarding the mechanism of omphalocele development, Chadha et al. suggested that the presence of the connecting cartilage bridge could interfere with closure of the abdominal wall during the latter stages of gestation (12).

In our study, the patient in case 2 presented with a large hernia of the abdominal wall, which had not been previously reported. The large hernia rendered the repair of the abdominal wall particularly difficult because the simultaneous repair of the hernia and removal of the parasitic twin would have significantly increased the intra-abdominal pressure and could have caused ICS (2). Therefore, we delayed the hernia repair until the twentieth month after birth. VYPRO II mesh (Ethicon) was used to successfully repair the hernia.

Despite the unusual clinical appearance and pathogenesis associated with EHTs, EHT patients usually have a good prognosis following a successful separation surgery. However, early diagnosis, diligent prenatal management, and selection of the proper route of delivery are critical to the success in treating EHT patients (1).

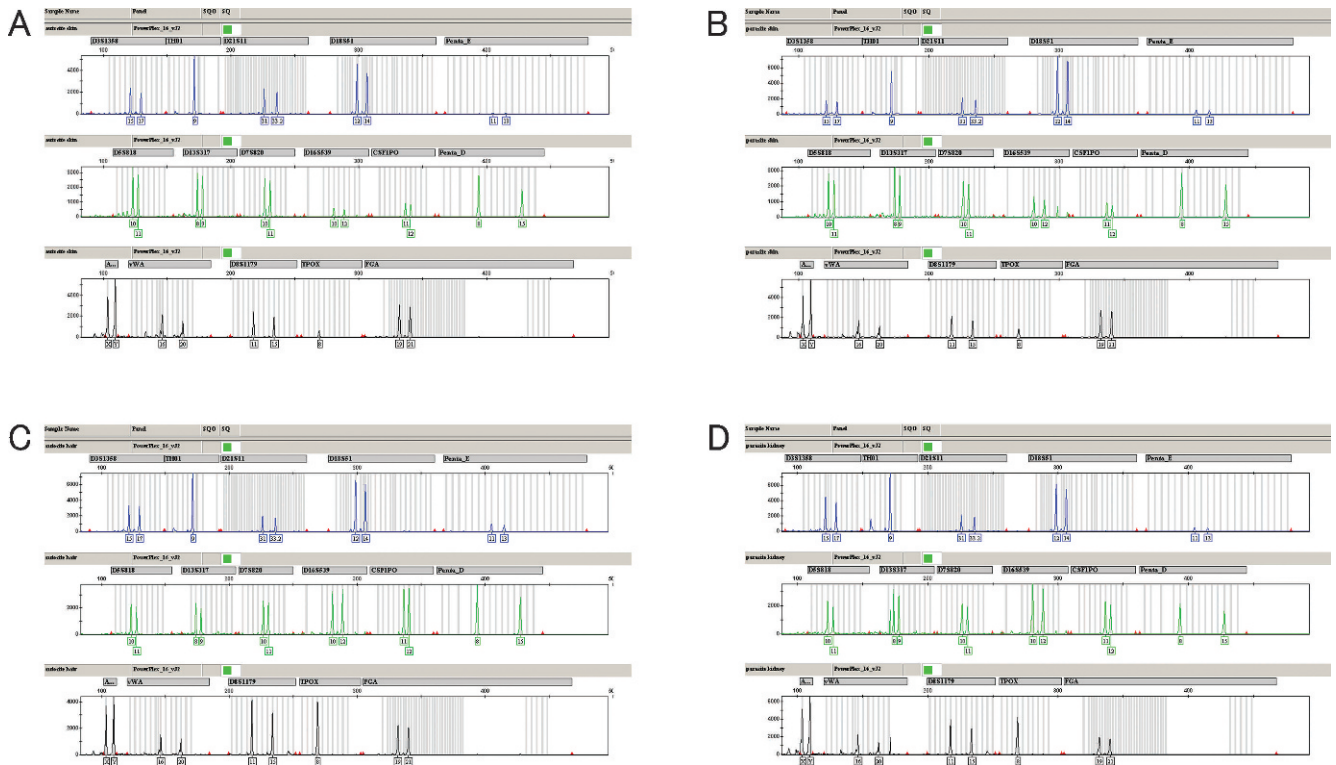


Figure 3 - Case 2. Results of the DNA analysis of the twins in case 2. (A) Skin from the autosite. (B) Skin from the parasite. (C) Hair from the autosite. (D) Kidney from the parasite.

AUTHOR CONTRIBUTIONS

JT Xie and Zhou L conducted the separation surgery in both cases, drafted the manuscript and reviewed the literature. Zhou L critically reviewed and revised the manuscript. Yang ZL was a joint surgeon in both cases. Sun HY conducted the DNA analysis of case 2. All authors read and approved the final manuscript.

REFERENCES

1. Bhansali M, Sharma DB, Raina VK. Epigastric heteropagus twins: 3 cases reports with review of literature. *Journal of Pediatric Surgery.* (2005);40(7):1204-8, <http://dx.doi.org/10.1016/j.jpedsurg.2005.03.105>.
2. Hillingsø J. Intraabdominal hypertension and abdominal compartment syndrome. *Ugeskr Laeger.* 2008;170(7):527-31.
3. Kallen B, Rybo G. Conjoined twins in Sweden. *Acta Obstet Gynecol Stand.* 1978;57(3):257-9, <http://dx.doi.org/10.3109/00016347809154894>.
4. Edmonds LD, Layde Conjoined twins in the United States, 1970-1977. *Teratology.* 1982;25(3):301-8.
5. Liang J, Xu CL, Wang YP. The epidemiological investigation of conjoined twins in China from 1992 to 1998. *Journal of West China University of Medical Sciences.* 1999;30(1):56-8.

6. O'Neil JA Jr. *Conjoined twin, Pediatric surgery.* 5th ed. St Louis, MO: Mosby-year book. 1998;1925-37.
7. Logrona R, Garcia-Lithgow C, Harris C, Kent M, Meisner L. Heteropagus Conjoined twins due to fusion of two embryos: report and review. *American Journal of Medical Genetics.* 1997;73(3): 239-43.
8. Ratan SK, Rattan KN, Magu S, Gupta S, Narang R, Arora B. Thoracopagus parasites in two sets of twins: evidence of the fusion theory. *Pediatr Surg Int.* 2008;24(11):1255-9, <http://dx.doi.org/10.1007/s00383-008-2248-z>.
9. Hager J, Sanal M, Trawogger R, Gassner J, Oswald E, Rudisch A, et al. Conjoined epigastric heteropagus twins: excision of a parasitic twin from the anterior abdominal wall of her sibling. *Eur J Pediatr Surg.* 2007;17(1):66-71.
10. Abubakar AM, Ahidjo A, Chinda JY, Tahir C, Abubakar S, Adamu SA, et al. The epigastric heteropagus conjoined twins. *J Pediatr Surg.* 2011;46(2):417-29, <http://dx.doi.org/10.1016/j.jpedsurg.2010.09.045>.
11. Tongsin A, Niramis R, Rattanasuwan T. Epigastric heteropagus twins: a report of four cases. *J Med Assoc Thai.* 2003;86(Suppl 3):S605-9.
12. Chadha R, Bagga D, Dhar A, Mohita A, Malhotra CJ, Taneja SB. Epigastric heteropagus. *J Pediatr Surg.* 1993;28(5):723-72, [http://dx.doi.org/10.1016/0022-3468\(93\)90042-J](http://dx.doi.org/10.1016/0022-3468(93)90042-J).