

Digital necrosis with squamous cell carcinoma of the tonsil

Vinod Warriar¹
Ali Ahmad¹
Yaqoub Alshatti¹
Ali Jafar²

¹Department of Internal Medicine, Mubarak Al-Kabeer Hospital, Jabriya, Kuwait; ²Department of Surgical and Interventional Sciences, University College London, Royal Free Hospital, London, UK

Background: Digital necrosis is a rare phenomenon of paraneoplastic syndrome associated with squamous cell carcinoma of the tonsil. Since 1965, more than 70 cases have been reported worldwide in the literature.

Case report: A 54-year-old male smoker presented with Raynaud's phenomenon, proceeding to frank gangrene of the fingers. Working up the case finally pointed toward carcinoma of the tonsil as the underlying cause – a rare paraneoplastic manifestation.

Conclusion: No definite etiology has been found to be the cause of Raynaud's phenomenon in this case of the squamous cell carcinoma of the tonsil. A brief discussion of the literature is also presented.

Keywords: acronecrosis, digital necrosis, paraneoplastic manifestations, Raynaud's phenomenon, squamous cell carcinoma of the tonsil

Case presentation

A 54-year-old male smoker (20 pack-years) presented with bluish discoloration of the fingers of both hands, associated with pain of 1 month's duration. He also had halitosis at the time of presentation. Examination showed a firm 2–3 cm jugulodigastric node on the right side and an enlarged ulcerated right tonsil. Distal pulses, including the radial and dorsalis pedis, were normal. The patient was not taking any medication, and the family history was unremarkable. Clinically, acrocyanosis was a possibility, and so the causes were searched for. Fine-needle aspiration cytology from the node and a biopsy from the tonsil were arranged. Meanwhile, ischemic symptoms in the hand progressed and developed into frank gangrene and necrosis. By this time the node had increased in size and developed into a fungating growth (Figures 1 and 2).

The diagnostic investigations (ie, laboratory, radiology, etc) have been summarized in Tables 1–6 and Figure 3.

A bronchoscopy was carried out and showed nonspecific inflammatory cells. The biopsy from the tonsil showed squamous cell carcinoma of the spindle cell variety. Fine needle aspiration cytology and the impression smear showed metastasis from the squamous cell carcinoma (Figure 4). Radiological evidence of metastasis in the lungs shown in figure 5. The present case report was approved by Mubarak Al-Kabeer Hospital ethical board. Verbal informed consent was obtained from the patient for publication of this case report and accompanying images.

Correspondence: Ali Ahmad
Department of Internal Medicine,
Mubarak Al-Kabeer Hospital, Jabriya,
Kuwait
Email ali_ashkanani5@hotmail.com

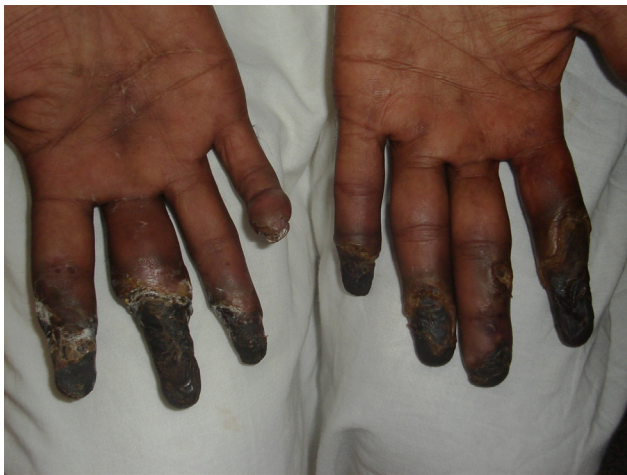

Figure 1 Gangrenous digits of the patient.

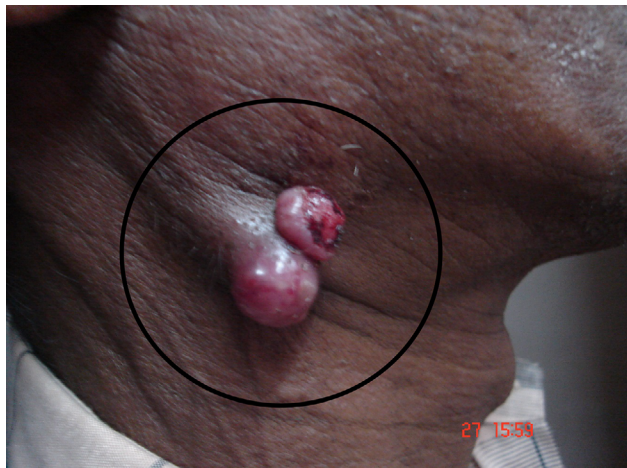

Figure 2 Ulcerated jugulodigastric node.

Table 1 Routine blood investigations

Test	Result (normal range)
Complete blood count	
Hemoglobin	14.6 g/dL (13.5–17.5 g/dL)
Total white blood cell count	18,600 cells/ μ L (3,500–10,500 cells/ μ L)
Differential count	Neutrophils 77% (40%–80%)
Platelets	Lymphocytes 19% (20%–40%)
Erythrocyte sedimentation rate	Eosinophils 4% (1%–6%) 230,000 μ L (150,000–450,000/ μ L) 80 mm/h (<20 mm/h)
Liver function test	Within normal range
Renal function test	Within normal range

Table 2 Immunology screening

Test	Result
Antinuclear antibody	Negative
Rheumatoid factor	Negative
P-ANCA	Negative
C-ANCA	Negative
Antiphospholipid antibodies	
Anticardiolipin antibodies	Negative
Anti- β_2 glycoprotein	Negative
Lupus anticoagulant	Negative
Complements	
C3	Normal
C4	Normal

Abbreviations: P-ANCA, perinuclear anti-neutrophil cytoplasmic antibody; C-ANCA, cytoplasmic anti-neutrophil cytoplasmic antibody.

Table 3 Immunoglobulin screening

Test	Result
Immunoglobulin A, G	Normal
Cryoglobulin	Negative

Table 4 Virology screening

Test	Result
HBsAg	Negative
Anti-HCV antibodies	Negative
HIV	Negative

Abbreviations: HbsAg, hepatitis b surface antigen; HCV, hepatitis C virus; HIV, human immunodeficiency virus.

Table 5 Other tests

Test	Result
Thyroid profile	Normal
Mantoux test	Negative

Table 6 Imaging studies

Imaging modality	Result
Chest X-ray	Right lower zone consolidation
Doppler study of the upper limb	Normal

Discussion

Acronecrosis is a rare manifestation of malignant neoplasms such as neoplasm of the gastrointestinal tract, lung, and breast; ovarian and uterine carcinomas; renal adenocarcinoma; multiple myeloma; leukemia; and Hodgkin lymphoma, with the underlying mechanism still not being fully understood.^{1–4} The clinical presentation can range from splinter hemorrhages with pulp atrophy to digital necrosis. Raynaud's syndrome is unlikely in our patient, because the presentation was rapidly progressive over a short period of time and with no aggravating factors. Raynaud's syndrome, however, has been reported as an initial manifestation of an ovarian

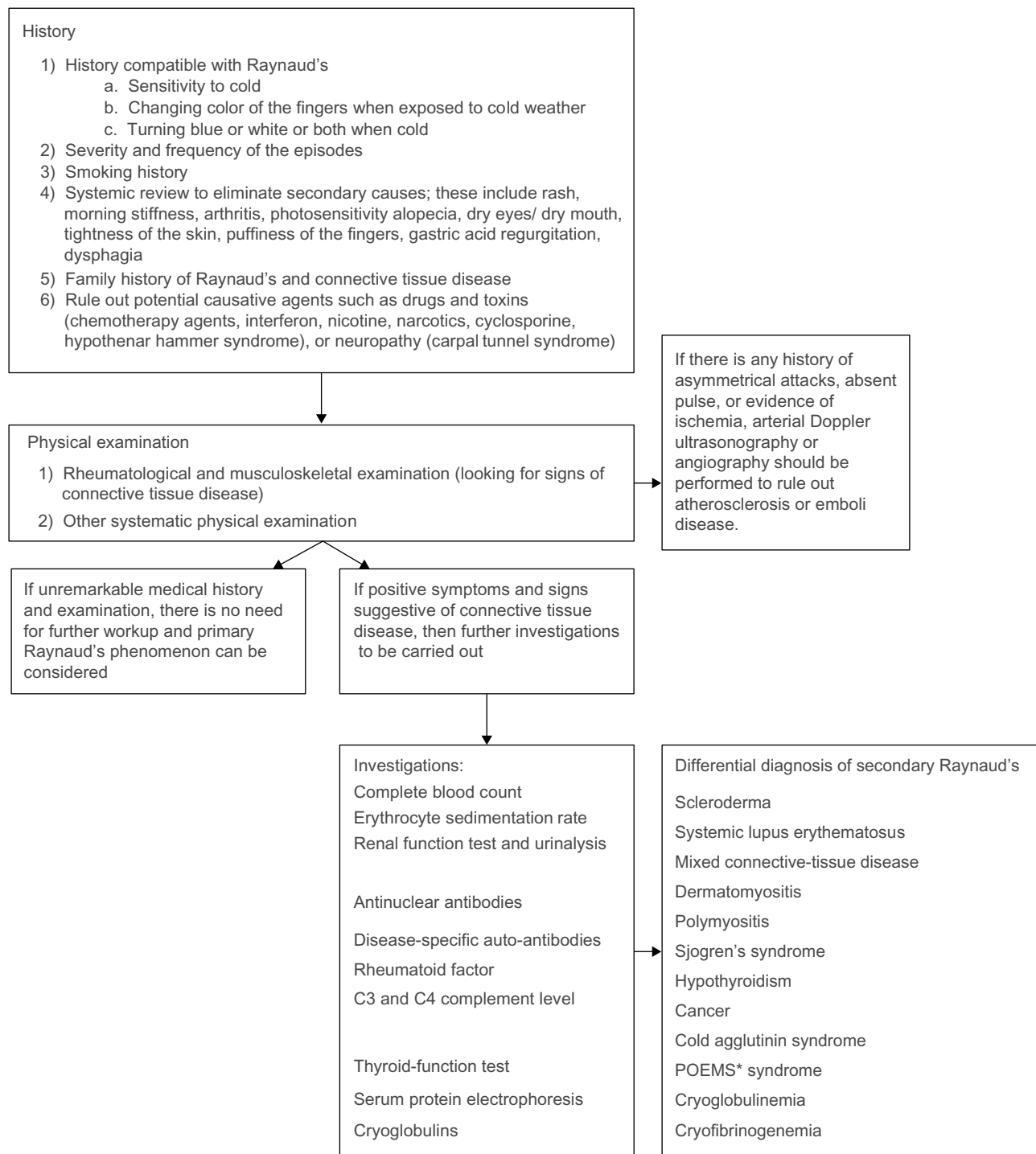


Figure 3 Diagnostic flowchart for Raynaud's Phenomenon.

Notes: * Refers to polyneuropathy, organomegaly, endocrinopathy, monoclonal gammopathy, and Skin changes. It is a rare multisystemic disease that occurs in the setting of a plasma cell dyscrasia.

carcinoma.⁵ Over the last 45 years, more than 70 cases⁶ have been reported in the medical literature worldwide, describing the association of digital necrosis with different types of malignant neoplasms.⁷

The suggested possible underlying mechanisms of the digital ischemia include arterial vasospasm mediated by

immune complexes, blood hypercoagulability secondary to vascular occlusions, cryoglobulinemia, and necrotizing vasculitis. In our patient, cryoglobulins and immune complexes were not detected, and the thrombophilia screen was negative. Since the Doppler study of the hand was normal, there was unlikely to be a significant proximal (large) vessel component.

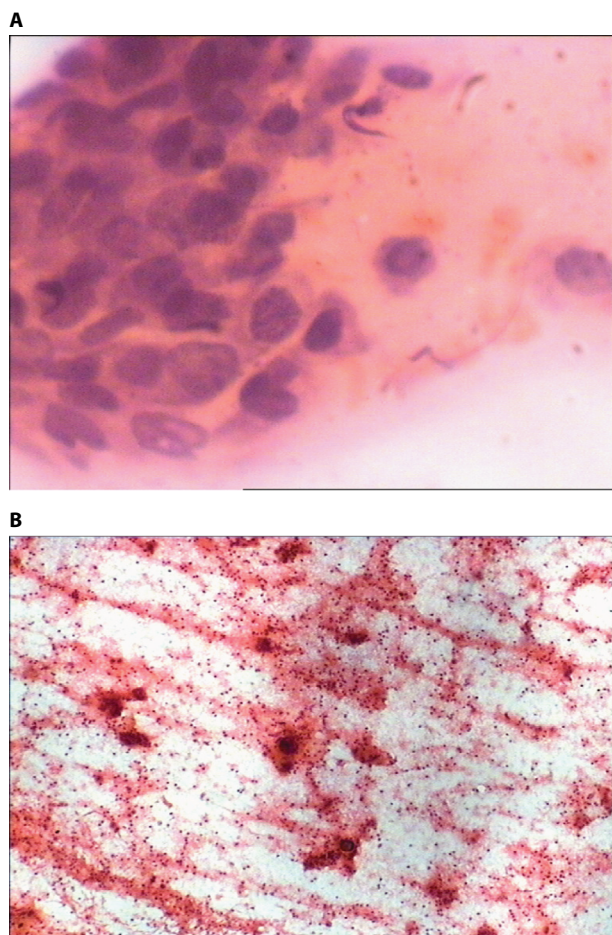


Figure 4 Histological specimen of jugulodigastric lymph node
Notes: (A) Biopsy from the ulcerated jugulodigastric node showing spindle cell carcinoma. (B) Cytology smear from the ulcerated jugulodigastric node showing spindle cell carcinoma.

There is one reported case of digital necrosis resulting from squamous cell carcinoma of the tonsil in 2002;⁸ therefore, it could be inferred that squamous cell carcinoma of the upper aerodigestive tract could be associated with acronecrosis.

The size of the primary tumor reduced following radiotherapy. The radiotherapy regimen given to the patient included intensity-modulated radiotherapy and weekly cisplatin (50 mg/m²). The hand function failed to show any improvement, and the patient eventually succumbed to the advanced disease.

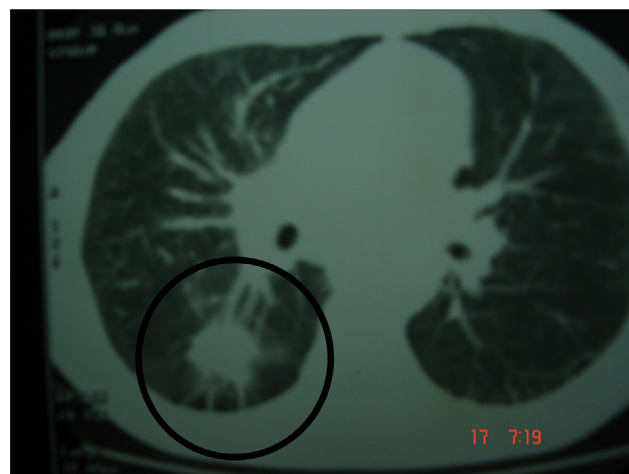


Figure 5 Lymphangitis carcinomatosa involving the right lobe and mediastinal adenopathy.

Conclusion

To date, acronecrosis as a paraneoplastic manifestation has been rarely reported. We report this case so as to highlight the association of acronecrosis as a paraneoplastic manifestation of a squamous cell carcinoma of the tonsil.

Disclosure

The authors report no conflicts of interest in this work.

References

1. Petrie M, Fye H. Digital necrosis: a paraneoplastic syndrome. *J Rheumatol.* 1985;12:800–802.
2. Taillan B, Castanet J, Garnier G, et al. Paraneoplastic Raynaud's phenomenon. *Clin Rheumatol.* 1993;12(2):281–282.
3. Iamandi C, Dietemann A, Grosshans E, Pauli G, Quoix E. Paraneoplastic digital necrosis in a patient with small-cell lung cancer. *J Clin Oncol.* 2002;20(23):4600–4601.
4. Chow SF, McKenna CH. Ovarian cancer and gangrene of the digits: case report and review of the literature. *Mayo Clin Proc.* 1996;71(3):253–258.
5. Kohli M, Bennett RM. Raynaud's phenomenon as a presenting sign of ovarian adenocarcinoma. *J Rheumatol.* 1995;22:1393–1394.
6. Wigley FM, Herrick A, Flavahan N, eds. *Raynaud's Phenomenon – A Guide to Pathogenesis and Treatment.* New York, NY: Springer Science + Business Media, LLC; 2015:141–162.
7. Hawley PR, Johnston AW, Rankin, JT. Association between digital ischemia and malignant diseases. *Br Med J.* 1967;22(3):208–212.
8. Wright JR, Gudelis S. Digital necrosis associated with squamous cell carcinoma of the tonsil. *Head Neck.* 2002;24(11):1019–1021.

International Medical Case Reports Journal

Publish your work in this journal

The International Medical Case Reports Journal is an international, peer-reviewed open-access journal publishing original case reports from all medical specialties. Previously unpublished medical posters are also accepted relating to any area of clinical or preclinical science. Submissions should not normally exceed 2,000 words or

Submit your manuscript here: <https://www.dovepress.com/international-medical-case-reports-journal-journal>

Dovepress

4 published pages including figures, diagrams and references. The manuscript management system is completely online and includes a very quick and fair peer-review system, which is all easy to use. Visit <http://www.dovepress.com/testimonials.php> to read real quotes from published authors.