



Received: 2014.08.04  
Accepted: 2014.09.05  
Published: 2015.01.28

Authors' Contribution:

- A** Study Design
- B** Data Collection
- C** Statistical Analysis
- D** Data Interpretation
- E** Manuscript Preparation
- F** Literature Search
- G** Funds Collection

## Vertebroplasty of Cervical Vertebra

Kazimierz Kordecki<sup>1ADE</sup>, Andrzej Lewszuk<sup>1ADE</sup>, Magdalena Puławska-Stalmach<sup>1ABDEF</sup>,  
Paweł Michalak<sup>1ABEF</sup>, Adam Łukasiewicz<sup>1ADE</sup>, Izabela Sackiewicz<sup>1ABEF</sup>, Piotr Polaków<sup>1BEF</sup>,  
Katarzyna Rutka<sup>1BEF</sup>, Wojciech Łebkowski<sup>2ADE</sup>, Urszula Łebkowska<sup>1ADE</sup>

<sup>1</sup> Department of Radiology, Medical University of Białystok, Białystok, Poland

<sup>2</sup> Department of Neurosurgery, Medical University of Białystok, Białystok, Poland

Author's address: Kazimierz Kordecki, Department of Radiology, Medical University of Białystok, Białystok, Poland,  
e-mail: k.kordecki@tlen.pl

**Background:**

The first vertebroplasty was performed by Harve Deramond in France in 1984 due to a hemangioma of cervical vertebral body. Procedure technique consisted of inserting a needle through the bony palate of the oral cavity. Bone cement injected under pressure not only fills the areas of bone loss. The heat released in the process of crystallization causes denaturation of pathological tissue proteins (metastasis) and disrupts blood supply (hemangiomas). The aim of this study was to evaluate the method of treatment from anterolateral access.

**Material/Methods:**

In the years 2007–2012 the procedure was performed in 6 men and 9 women aged from 42 to 71 years (mean age: 56.3 years). In 10 cases the reason for vertebroplasty was the vertebral hemangioma, in another 4 – pathological vertebral fractures due to metastases, and in one case – multiple myeloma. Procedures were performed from anterolateral access, under local anesthesia, under x-ray guidance (fluoroscopy). Bone needle was inserted into the vertebral body, followed by injection of PMMA cement.

**Results:**

In 100% cases pain relief was observed immediately after the procedure and beneficial therapeutic effect was obtained. No life-threatening complications and clinical symptoms were observed. Average length hospital stay amounted to 2.9 days.

**Conclusions:**

Cervical spine vertebroplasty from anterolateral access seems to be a safe, effective and beneficial method of treatment. It reduces the risk of infection in comparison to the transoral method.

**MeSH Keywords:**

**Bone Cement • Hemangioma, Cavernous, Central Nervous System • Magnetic Resonance Imaging • Spinal Interventional Radiology • Vertebroplasty**

**PDF file:**

<http://www.polradiol.com/abstract/index/idArt/892165>

### Background

Vertebroplasty involves percutaneous, transpedicular injection of PMMA (polymethyl methacrylate) bone cement into pathologically changed vertebral body [1]. The essential goal of the procedure is to relieve pain caused by vertebral compression fractures and to improve patient's quality of life [2]. Another goals of vertebroplasty include, among other things, reduction of the amount of administered painkillers, improvement of vertebral biomechanics, halting progression of deformations, vertebral stabilization [3]. This method is particularly indicated in cases of vertebral fractures due to osteoporosis, cancer metastases, hyperparathyroidism,

trauma or hemangiomas [4,5]. Therapeutic effect of percutaneous vertebroplasty is due to permanent filling of intertrabecular spaces at the sites of bone loss by administered bone cement. It is a minimally invasive and highly effective procedure [6]. The first vertebroplasty procedure performed by Harve Deramond at the Radiology and Neurology Clinic of Amiens University Hospital in France in 1984 was conducted due to pain caused by vertebral body hemangioma in cervical spine region [7]. Procedure technique consisted of introducing a bone needle through bony palate into the vertebral body using typical vertebroplasty sets and bone cement characterized by high crystallization temperature.

Currently, due to its texture resembling toothpaste or play dough it is possible to inject bone cement under pressure through a small-diameter needle. It thickens after several dozen minutes. Change of the state of matter is a highly exothermic process, exhibiting an additional healing effect (coagulation). High binding temperature and cement toxicity induces denaturation of proteins in pathological tissues (metastases). Neoplastic focus becomes filled and its vascular supply becomes disrupted due to high binding temperature of the cement [8]. The advantage of vertebroplasty is such, that therapeutic effect is immediate [9]. Patient may get up from bed after several hours and sometimes can be discharged home on the same day.

## Material and Methods

### Material

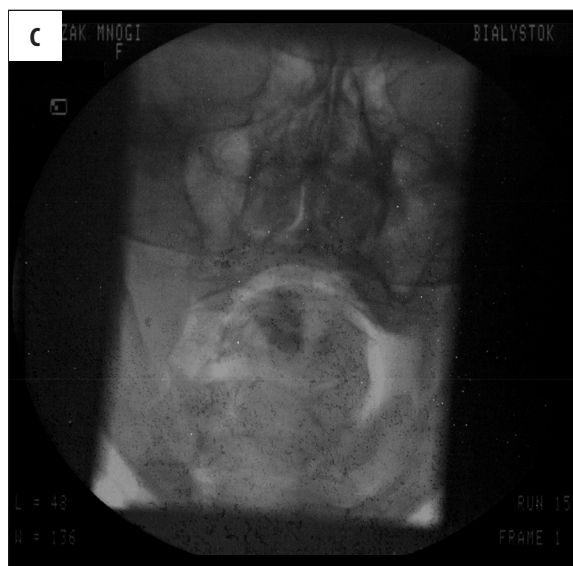
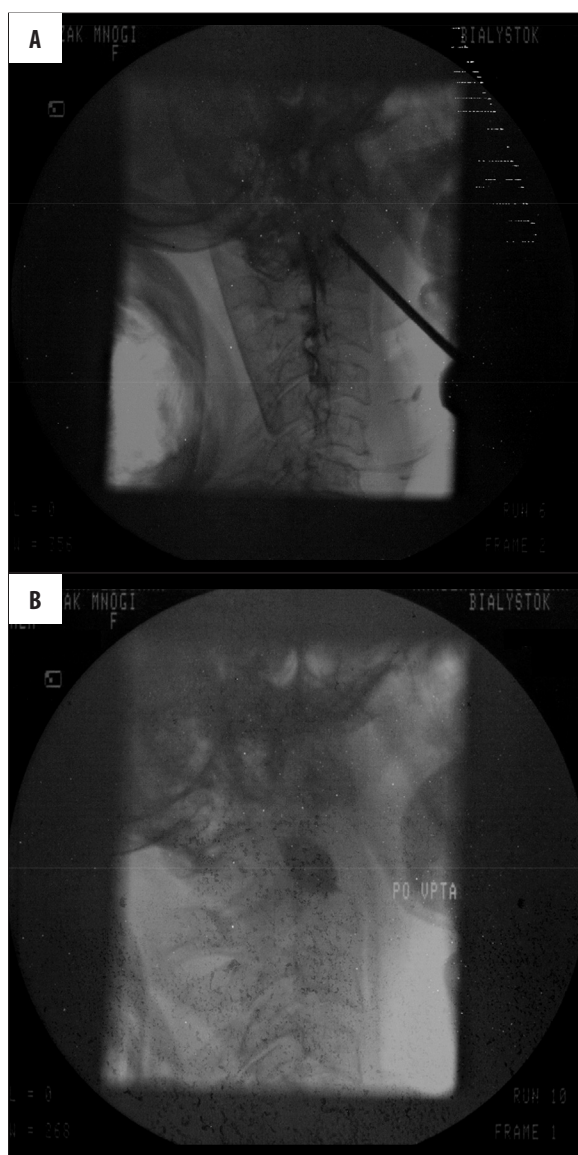
Cervical spine vertebroplasties were performed in 15 patients between 2007 and 2012. Eleven patients were treated at the Department of Neurosurgery of the Medical

University of Bialystok and four at the Endovascular Surgery Facility of the Military Hospital in Elk. Before the procedure patients complained of pain in cervical spine region appearing during movement, periodic upper extremity pain, bone pain, numbness of the 4<sup>th</sup> and the 5<sup>th</sup> finger of the hand. Following thorough neurological examination, results of imaging studies of the spine, i.e. PA and lateral x-ray or computed tomography, patients were diagnosed with vertebral hemangiomas accompanied by discopathy or malignant tumor metastases clinically manifesting as brachialgia, slight upper extremity paresis and muscle wasting.

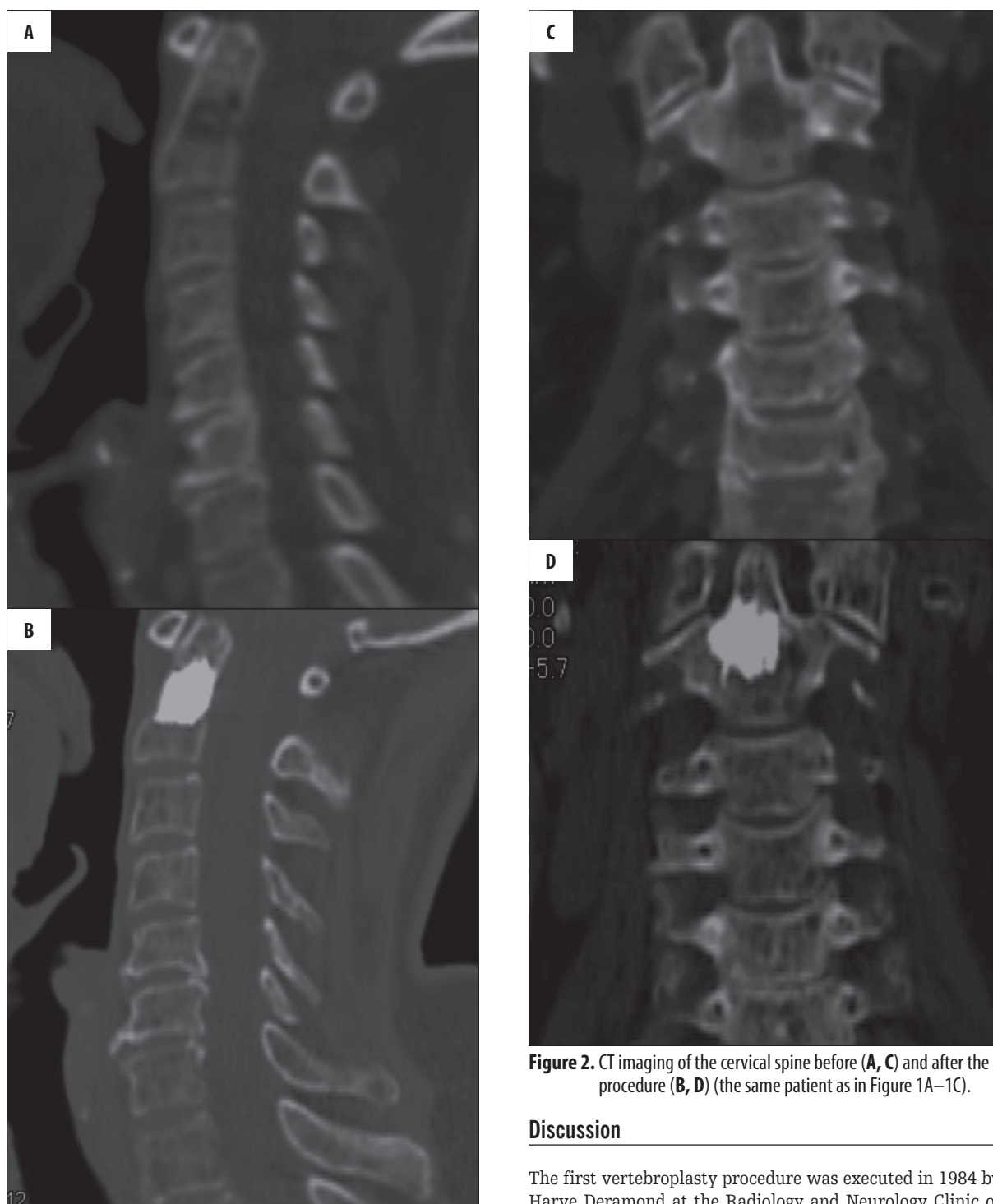
The procedure was performed on 6 men and 9 women aged 42 to 71 years (mean age: 56.3). In 10 cases (66.7%) procedure was performed due to vertebral hemangiomas, while another 4 patients presented with pathological fractures caused by malignant metastases (26.7%). In only one case C2 vertebra was treated due to a focus of multiple myeloma (6.6%).

### Methods

Procedure was performed in local anesthesia, under x-ray (fluoroscopy) guidance from anterolateral approach. Following identification of the vertebrae of interest the area was infiltrated with anesthetic. As common carotid artery pulse was identified through palpation, percutaneous injection was performed at the level of C4–C5 intervertebral disc at the level of C4 vertebral body. The needle was either directed medially to common carotid artery, superiorly and laterally to the vertebral body of interest or it was pointed toward the base of odontoid process of the



**Figure 1.** (A) C2 vertebroplasty under fluoroscopic guidance – during the procedure. (B) After the procedure. (C) After the procedure. A 71-year-old patient diagnosed with IgA multiple myeloma, with progressive symptoms during lower limb movements. Computed tomography (CT) examination showed osteolytic vertebral lesions and damage to odontoid process at a very high risk of fracture. Lower limb function recovered completely after the procedure.



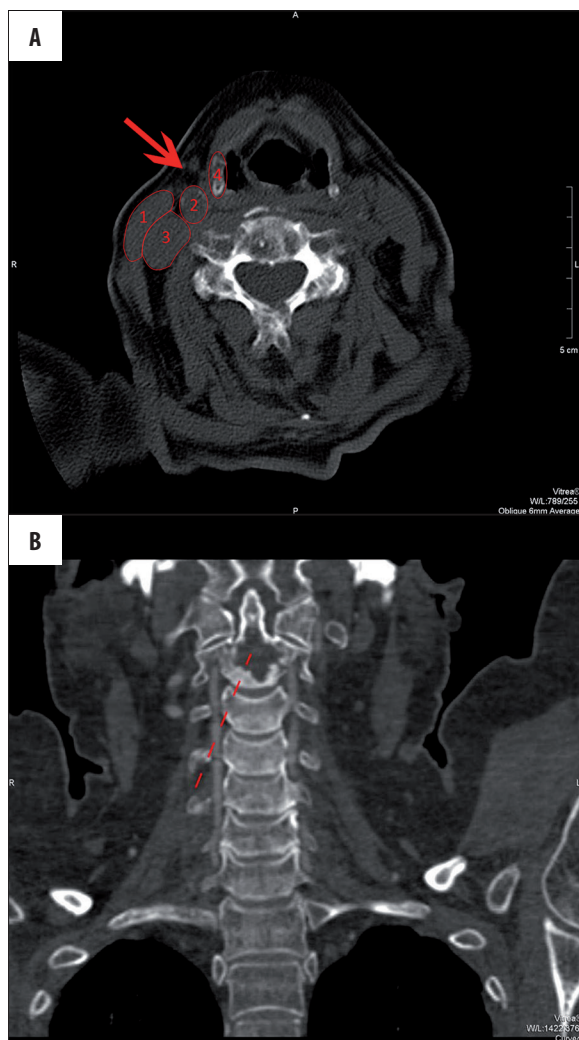
**Figure 2.** CT imaging of the cervical spine before (A, C) and after the procedure (B, D) (the same patient as in Figure 1A–1C).

## Discussion

The first vertebroplasty procedure was executed in 1984 by Harve Deramond at the Radiology and Neurology Clinic of Amiens University Hospital in France [7]. It was performed in order to treat pain due to a hemangioma of cervical vertebra, which is one of the indications to the procedure. Remaining indications include pain due to vertebral body tumor as well as osteoporosis and its complications [10]. It is contraindicated in patients with bleeding diathesis, infection or diffuse metastases [10].

Vertebroplasty procedure stabilizes vertebral body and prevents further progression of its pathology. Bone cement maintains semi-fluid consistency, enabling its injection

axis, bypassing the vessel and puncturing through the muscle only (m. longus coli and m. longus capitis). Bone needle was introduced into the vertebral body and subsequently PMMA cement was administered under careful fluoroscopic guidance. In 86.7% (13) of our procedures we used Cinvidience Spinal Cement Radopaque sets with hydraulic applicator and high-density cement. Osteofirm Cook Radiopaque Bone Cement and Vertebroplastic Radiopaque Bone Cement were used in 6.6% (1) of cases each. Mean time of the procedure was 67 minutes (Figures 1–4).

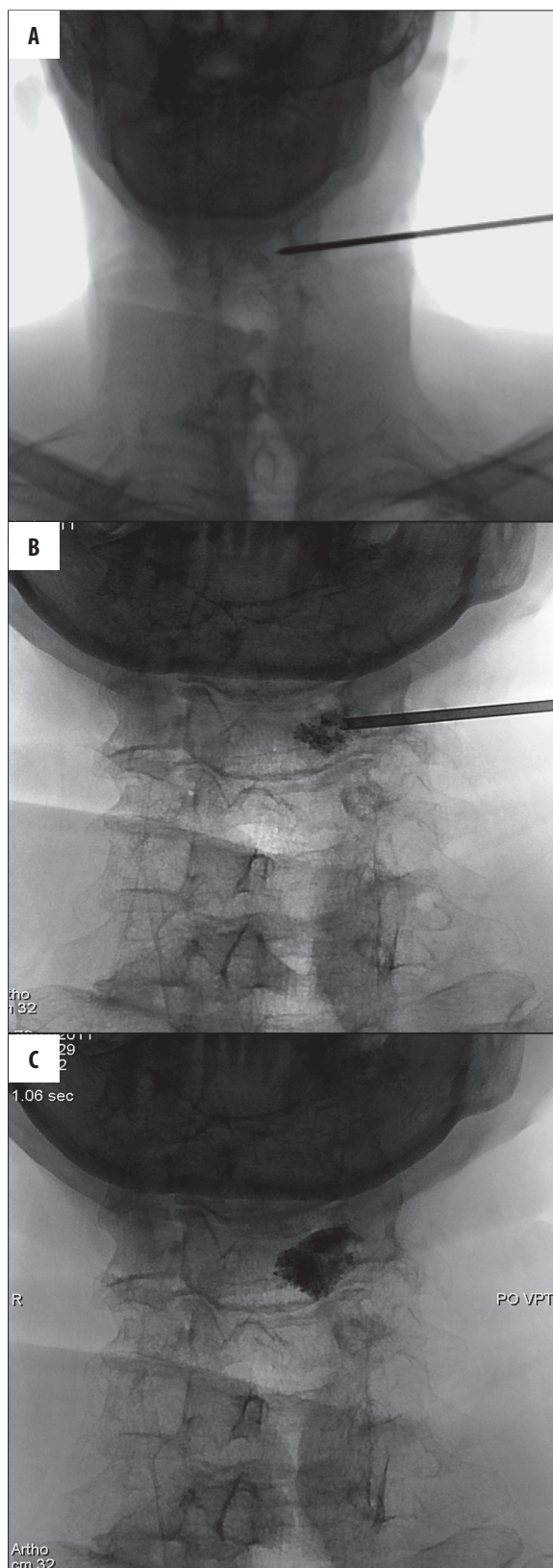


**Figure 3.** (A, B) CT examination (same patient as in Figures 1A–2D) before the procedure. Site of needle puncture and course of the needle are marked. Puncture was performed at the level of C4–C5 intervertebral disc at the level of C4 body after palpating common carotid artery pulse. The needle was directed medially to common carotid artery, toward the base of odontoid process, bypassing the vessels and penetrating through the muscles only (m. longus coli, m. longus capitis). Bone needle was introduced into the vertebral body followed by PMMA cement administration under careful x-ray guidance.

into the area of interest. It solidifies after several dozen minutes. Change of state is an exothermic reaction and released heat exerts additional therapeutic effect (coagulation) in cases of hemangiomas and metastases [8,11].

Transoral vertebroplasty is an alternative method of reconstructing vertebral bodies. In this technique bone needle penetrates through the posterior wall of the palate and throat and subsequently placed in the central part of C2 body under fluoroscopic guidance. Filling of the body with bone cement is also performed under fluoroscopic guidance [12].

In their publication, Peh W.C.G. et al. described 310 vertebroplasties performed over 25 months in 155 patients



**Figure 4.** (A) X-ray-guided C4 vertebroplasty – during the procedure. (B) During the procedure – administration of PMMA cement. (C) After the procedure. Pathological fracture of C4 vertebral body due to nonresectable, malignant tumor of piriform recess.

with fractures of thoracic vertebrae, mainly due to osteoporosis. The most common complications of vertebroplasty included cement leakage (48%). Despite such large group of patients no other complications were noted. None of the patients required reoperation [13].

Farrokhi M. et al. describes 25 cases of patients with pathological fractures of vertebral bodies in a course of malignancy. Level of pain was assessed using VAS (Visual Analogue Scale) and amounted to 8.23 before the procedure and 2.12 after 24 hours from the procedure, 1 after one month and 0 after three months, indicating that pain subsided completely. Cement leakage occurred in 44% of patients and no other complications were noted [11].

Miriam Rodriguez-Catarino et al. described a case of a 47-year-old woman with C2 body fracture in the course of multiple myeloma, treated with chemo- and radiotherapy without any effect. This woman with a 6-week-long history of neck pain was subjected to percutaneous vertebroplasty using PMMA cement. Follow-up CT examination showed no cement leakage. Patient was discharged home on the second day after the procedure free of pain [14].

For a patient undergoing the procedure resolution of pain and thus, improvement of mobility, is the best indicator of treatment effectiveness. Vertebroplasty stabilizes pathological fractures of vertebral bodies, eliminates pain and provides patients with independence with regard to basic life functions [2,15]. Immediate therapeutic effect is the advantage of vertebroplasty. The procedure is minimally invasive, safe and well tolerated by patients, which contributes to shortening of hospitalization time [16]. Percutaneous vertebroplasty relieves pain symptoms, which enables elimination of analgetic drugs from therapy [9]. Another advantages include increased physical activity and improved quality of patient life [17]. Despite so many advantages one should also remember about possible complications of the procedure, which include: cement leakage, infections, allergic reactions, hypertension, transient pain persisting usually for 24 hours after the procedure [10]. Vertebroplasty is considered an effective method of treatment of symptomatic vertebral compression fractures due

to osteoporosis, particularly in cases resistant to conventional therapy [18].

## Results

Immediately after the procedure resolution of pain and good therapeutic effect was observed in 100% of cases. Two hours after the procedure 2 patients reported slight pain in cervical spine region, which subsided after application of analgetics. Moreover, one patient complained of transient dizziness and local neck pain at the site of puncture. We did not observe any clinical symptoms, including neurological signs, which could pose a threat to patient life or wellbeing.

Mean hospitalization time was 4.2 days, and time from vertebroplasty to discharge amounted to 2.5 days. Few patients were discharged home on the day of the procedure due to the fact that no complications or complaints were noted.

In one patient a C7 hemangioma was diagnosed in a course of diagnostics performed after a communication accident. Due to multiorgan trauma and severe clinical state of this patient total hospitalization time amounted to 17 days, including 14 days after the procedure (no complications of vertebroplasty were noted). After excluding this patient from our statistics, total hospitalization time of the remaining 14 patients amounted to 2.9 days.

## Conclusions

1. Vertebroplasty of cervical vertebra using anterolateral approach seems to be a safe and effective method of treatment of hemangiomas and osteolytic vertebral lesions due to malignancy.
2. It is a minimally invasive method that eliminates the risk of complications, mainly infections, associated with the transoral technique.
3. Due to a short hospitalization time and almost immediate clinical improvement this procedure appears to be very beneficial for the patient.

## References:

1. Deramond H, Depriester C, Galibert P et al: Percutaneous vertebroplasty with polymethylmethacrylate. Technique, indications, and results. *Radiol Clin North Am*, 1998; 36(3): 533-46
2. Gerling MC, Eubanks JD, Patel R et al: Cement augmentation of refractory osteoporotic vertebral compression fractures: survivorship analysis. *Spine (Phila Pa 1976)*, 2011 Sep 1; 36(19): E1266-9
3. Anderson PA, Froysheter AB, Tontz WL: Meta-analysis of vertebral augmentation compared to conservative treatment for osteoporotic spinal fractures. *J Bone Miner Res*, 2013; 28(2): 372-82
4. Alexandru D, So W: Evaluation and management of vertebral compression fractures. *Perm J*, 2012; 16(4): 46-51
5. Muto M, Muto E, Izzo R et al: Vertebroplasty in the treatment of back pain. *Radiol Med*, 2005; 109(3): 208-19
6. Masala S, Massari F, Fiori R et al: Future directions in percutaneous vertebroplasty. *Radiol med*, 2009; 114: 976-83
7. Deramond H, Depriester C, Toussaint P et al: Percutaneous Vertebroplasty. *Semin Musculoskelet Radiol*, 1997; 1(2): 285-96
8. Chen LH, Hsieh MK, Niu CC et al: Percutaneous vertebroplasty for pathological vertebral compression fractures secondary to multiple myeloma. *Arch Orthop Trauma Surg*, 2012; 132(6): 759-64
9. Mont'Alverne F, Vallée JN, Guillevin R et al: Percutaneous vertebroplasty for multiple myeloma of the cervical spine. *Neuroradiology*, 2009; 51(4): 237-42
10. Gangi A, Guth S, Imbert JP et al: Percutaneous Vertebroplasty: Indications, Technique, and Results. 2001 RSNA scientific assembly. Received April 15, 2002
11. Farrokhi M, Nouraei H, Kiani A: The Efficacy of Percutaneous Vertebroplasty in Pain Relief in Patients with Pathological Vertebral Fractures due to Metastatic Spinal Tumors. *Iran Red Crescent Med J*, 2012; 14(9): 523-30
12. Gangi A, Guth S, Imbert JP: Percutaneous vertebroplasty: indications, technique, and results. *Radiographic*, 2003; 23(2): e10
13. Peh WCG, Gilula LA, Peck DD: Percutaneous Vertebroplasty for Severe Osteoporotic Vertebral Body Compression Fractures. 2000 RSNA scientific assembly. Received December 29, 2000

14. Rodriguez-Catarino M, Blimark C, Jan Willén J et al: Percutaneous vertebroplasty at C2: case report of a patient with multiple myeloma and a literature review. Springer-Verlag, 2006
15. Xu BS, Hu YC, Yang Q et al: Long-term results and radiographic findings of percutaneous vertebroplasties with polymethylmethacrylate for vertebral osteoporotic fractures. *Chin Med J (Engl)*, 2012; 125(16): 2832-36
16. Barbero S, Casorzo I, Durando M et al: Percutaneous vertebroplasty: the follow-up. *Radiol Med*, 2008; 113(1): 101-13
17. Köse KC, Cebesoy O, Akan B et al: Functional results of vertebral augmentation techniques in pathological vertebral fractures of myelomatous patients. *J Natl Med Assoc*, 2006; 98(10): 1654-58
18. Taylor RS, Taylor RJ, Fritzell P: Balloon kyphoplasty and vertebroplasty for vertebral compression fractures: a comparative systematic review of efficacy and safety. *Spine (Phila Pa 1976)*, 2006; 31(23): 2747-55