

IMAGES

Unusual presentations of philtrum of the lip

Jaideep Singh Chauhan, Sarwpriya Sharma

Department of Maxillofacial Surgery, Smile Train Cleft Centre, CHL Hospitals, Indore, India

Correspondence: Sarwpriya Sharma
Department of Maxillofacial Surgery, Smile Train Cleft Centre, CHL Hospitals, AB Road, LIG Square, Indore 452008, India
Tel: +91-9926400077, Fax: +91-7312549095
E-mail: drsarwpriyasharma@gmail.com

Received: August 20, 2019 • Revised: April 3, 2020 •

Accepted: April 4, 2020

pISSN: 2234-6163 • eISSN: 2234-6171

<https://doi.org/10.5999/aps.2019.01116>

Arch Plast Surg 2020;47:488-489

Copyright © 2020 The Korean Society of Plastic and Reconstructive Surgeons
This is an Open Access article distributed under the terms of the Creative Commons Attribution Non-Commercial License (<https://creativecommons.org/licenses/by-nc/4.0/>) which permits unrestricted non-commercial use, distribution, and reproduction in any medium, provided the original work is properly cited.

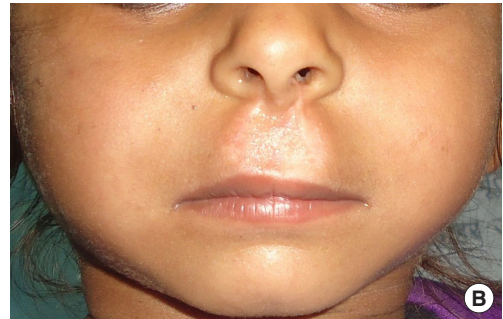
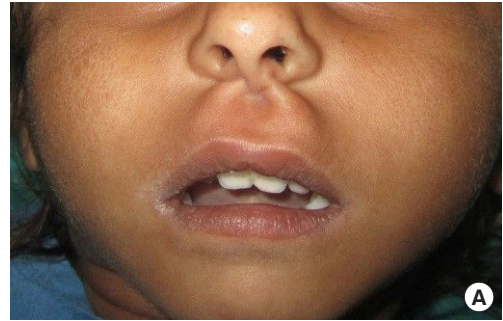
Fig. 1.

A 6-year-old girl, who had thick ridges on both sides of the philtrum since birth. (A) Preoperative image. (B) Postoperative image.

The philtrum is the most characteristic feature of the upper lip. Variations in its morphology can be seen amongst different individuals and races, but unusual presentations of the philtrum are relatively uncommon except in cases of orofacial defects, malformations, certain syndromes, trauma, and pathologies [1-3]. In our clinical practice, we encountered two cases involving an abnormal presentation of the philtrum, which were non-cleft, non-syndromic, non-traumatic, and non-pathological in nature. The first patient was a 6-year-old girl, who had thick ridges on both sides of the philtrum since birth (Fig. 1A). On gross examination, the height of the upper lip appeared relatively tall, the cupid's bow was not distinct, and the philtrum was flat near the vermilion border. On palpation, the bands were firm and non-tender. We performed aesthetic correction of the bands with a satisfactory outcome (Fig. 1B). The second case was a 22-year-old woman, who had a philtral bulge at the base of the columella (Fig. 2A). This bulge was congenital and proportionately increased in size with her facial growth. She had no history of any infection or trauma. The philtral ridges, philtral depression, and cupid's bow were indistinct. On palpation, the bulge was soft, non-tender, fixed to the overlying skin, and non-displaceable. On percussion, the fluid thrill test was negative. There was a small transverse scar near the base of the nose that was secondary to an incision made for drainage purposes when the child was 10 years old. We performed cosmetic reduction of the bulge and the results were acceptable (Fig. 2B).

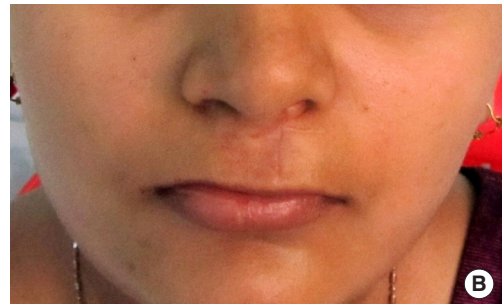
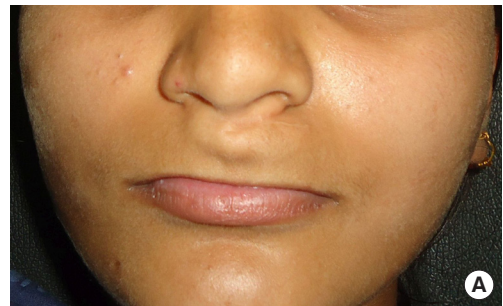

Fig. 2.

A 22-year-old woman, who had a philtral bulge at the base of the columella. (A) Preoperative image. (B) Postoperative image.

Notes

Conflict of interest

No potential conflict of interest relevant to this article was reported.

Ethical approval

The study was approved by the Integrity Ethics Committee of CHL Hospital (approval No. CHL/DEN/JSC/JUN-2019/02) performed in accordance with the principles of the Declaration of Helsinki. Written informed consents were obtained.

Patient consent

The patients provided written informed consent for the publication and the use of their images.

Author contribution

Conceptualization, data curation, formal analysis, methodology, project administration, visualization: JS Chauhan, S Sharma. Writing - original draft, review, & editing: JS Chauhan, S Sharma. Approval of final manuscript: all authors.

ORCID

Jaideep Singh Chauhan

<https://orcid.org/0000-0002-1558-6505>

Sarwipriya Sharma

<https://orcid.org/0000-0001-9565-3490>

References

1. Latham RA, Deaton TG. The structural basis of the philtrum and the contour of the vermilion border: a study of the musculature of the upper lip. *J Anat* 1976;121(Pt 1):151-60.
2. Briedis J, Jackson IT. The anatomy of the philtrum: observations made on dissections in the normal lip. *Br J Plast Surg* 1981;34:128-32.
3. Martin RA, Jones KL, Benirschke K. Absence of the lateral philtral ridges: a clue to the structural basis of the philtrum. *Am J Med Genet* 1996;65:117-23.