

A Modified Osteotomy for Anteromedialization of the Tibial Tubercle



Michael G. Saper, D.O., Benjamin A. Cox, D.O., and David A. Shneider, M.D.

Abstract: Tibial tubercle osteotomy is a common treatment option for a number of patellofemoral joint disorders including chondromalacia, “anterior knee pain” syndromes, patellofemoral arthritis, and patellar instability. Tibial tubercle osteotomy can modify tracking and/or patellofemoral contact forces to effect the unloading of chondral defects of the patella or trochlea, correct multiplanar suboptimal alignment, and be used in conjunction with soft-tissue stabilization procedures for instability. The purpose of this Technical Note is to describe, in detail, a modified osteotomy for anteromedialization of the tibial tubercle. The technique combines the concepts of Elmslie-Trillat and Fulkerson and modifies their techniques to produce an osteotomy that decreases lateral patellar pressure and centers the patella correctly in the trochlear groove.

Patellar pain and instability can be disabling conditions that limit daily functional activities. Surgical options include lateral retinacular release or lengthening, medial soft-tissue imbrication or reconstruction, cartilage restoration techniques, and distal realignment procedures. Tibial tubercle osteotomy (TTO) is a common treatment option for a number of patellofemoral joint disorders including chondromalacia, “anterior knee pain” syndromes, patellofemoral arthritis, and patellar instability. TTO can modify tracking and/or patellofemoral contact forces to effect the unloading of chondral defects of the patella or trochlea, correct multiplanar suboptimal alignment, or be used in conjunction with soft-tissue stabilization procedures for instability.¹ Transfer of the tibial tubercle is often necessary in patients with abnormal bony anatomy in which soft tissue procedures alone have been shown to be ineffective at improving patellofemoral kinematics.²

Many TTO techniques and modifications have been described in the literature. Surgical options include anteromedialization, anteriorization, and/or distalization depending on the diagnosis and treatment goals. In patients with an excessive lateral position of the tubercle associated with the lateral position of the patella in the trochlea in the setting of patellofemoral instability or pain due to a lateral chondral lesion, the combination of anteriorization and medialization can decrease lateral facet pressure, decrease overall patellofemoral contact stress by shifting the contact area proximally and medially, and improve patellofemoral tracking.³⁻⁶ However, current options for anteromedialization involve a large osteotomy with significant trauma to the tibia, overcorrection anteriorly, and failure to allow the tibial tubercle to be moved proximally or distally to allow correction of concomitant patella baja or alta if necessary.⁷

This technique combines the concepts of Elmslie-Trillat and Fulkerson and modifies their techniques to produce an osteotomy that decreases lateral patellar pressure and centers the patella correctly in the trochlear groove. The purpose of this Technical Note is to describe, in detail, a modified osteotomy for anteromedialization of the tibial tubercle. Advantages of this technique are that it is dependable, reproducible, and can be universally used in cases of patellar malalignment, pressure, and/or instability.

Surgical Procedure

A demonstration of the repair technique in a left knee is provided in [Video 1](#). The indications and advantages

From the Department of Orthopedics and Sports Medicine, Seattle Children's (M.G.S.), Seattle, Washington; Department of Osteopathic Surgical Specialties, Michigan State University (B.A.C.); and Mid-Michigan Orthopaedic Institute (D.A.S.), East Lansing, Michigan, U.S.A.

The authors report that they have no conflicts of interest in the authorship and publication of this article.

Received January 23, 2017; accepted March 22, 2017.

Address correspondence to Michael G. Saper, D.O., Department of Orthopedics and Sports Medicine, Seattle Children's, 4800 Sand Point Way NE, Seattle, WA 98105, U.S.A. E-mail: michael.saper@seattlechildrens.org

© 2017 by the Arthroscopy Association of North America

2212-6287/17101/\$36.00

<http://dx.doi.org/10.1016/j.eats.2017.03.028>

Table 1. Indications and Advantages for Modified Tibial Tubercle Osteotomy

| | |
|-------------|--|
| Indications | <ul style="list-style-type: none"> • Recurrent patellar instability in the setting of malalignment or an increased TT-TG distance • Lateral patellar pressure in flexion • Patella alta or baja • Congenital or fixed patella dislocation • Skeletal maturity |
| Advantages | <ul style="list-style-type: none"> • Reproducible • Can be universally used in cases of patellar malalignment, pressure, and/or instability • Can correct patella alta/baja at the same time |

TT-TG, tibial tubercle-trochlear groove.

of the procedure are presented in [Table 1](#). The contraindications and limitations are summarized in [Table 2](#). Pearls and pitfalls of each step are presented in [Table 3](#).

Patient Positioning and Preparation

Preoperatively, the patient receives a single-shot femoral nerve block. After the induction of general anesthesia, an examination under anesthesia is performed to assess patellar stability. A single dose of antibiotic is administered for infection prophylaxis. Next, a tourniquet is placed high on the thigh, and the patient is positioned supine with the surgical limb secured in an arthroscopic leg holder. The surgical area is prepped in a standard fashion and sterile drapes are applied.

Diagnostic Arthroscopy

Diagnostic arthroscopy is routinely performed and intra-articular findings are noted. Patellar alignment and position, the shape of the patella and the femoral trochlea, laxity on both medial and lateral sides, and the degree of lateral side tightness are all evaluated. These findings determine the surgical plan that is required. Excessive lateralization of the tibial tubercle is manifested arthroscopically by lateral patellar maltracking with the patella riding over the lateral femoral condyle with knee flexion. In this case, the TTO is performed to move the tubercle anteriorly and medially. If patella alta is noted, that is, where the patella fails to engage the trochlea by 30° of knee flexion, the tubercle is moved distally. If the patella engages the trochlea too soon in the case of patella baja, the tubercle is recessed proximally. In addition, the patellofemoral, medial, and lateral compartments are evaluated for the presence of chondral injuries. Chondroplasty is performed as needed and loose bodies are removed. Associated meniscal pathology is addressed as indicated.

Surgical Approach

A midline longitudinal skin incision is made and dissection is carried sharply down to the patellar tendon, tibial tubercle, and patella. Skin flaps are developed and meticulous hemostasis is obtained with

electrocautery. The patellar tendon and tibial tubercle are sharply isolated. A fasciotomy is performed releasing the proximal portion of the anterior tibial fascia. The next step is to free the lateral side of the patellar tendon ([Fig 1](#)). The lateral retinaculum is then carefully opened at the inferior lateral tip of the patella. This allows the patella to move to the center of the femoral trochlea. This release is carried only far enough to allow the patella to the center. It is usually not necessary for the release to extend past the superior pole of the patella.

Osteotomy

The tubercle needs to move medially just enough to align the patellar tendon with the bony tibial tubercle with the knee in flexion. Small corrections are often all that is necessary to correct alignment and over-correction can be detrimental. The patellar tendon is freed on the medial side and boundaries of the tibial tubercle are identified and marked. Aiming parallel to the posterior tibial slope of the proximal tibia, the near cortex is drilled with a 4.5-mm drill in the desired positions for the 2 screws that will be used to secure the osteotomy ([Fig 2A](#)). Care is taken not to penetrate the far cortex and the screw holes are slightly offset to prevent formation of a stress concentrator. A Sabo saw (Stryker, Kalamazoo, MI) with microsagittal blade (Stryker, 13 × 0.51 × 41 mm) is then used to score the cortex, outlining an approximately 1.5 cm wide by 3 cm long bone block, making sure to preserve enough bone on either side of the screw holes to prevent the block from splitting when the screws are placed ([Fig 2B](#)). The tibial tubercle is then undercut to a depth of 1 cm with the saw, and then completely freed from its bed in the tibia, allowing the tubercle to rotate medial and anterior. The anterior position is created by an oblique undercutting of the tibial tubercle to allow for a combination of medial and anterior translation to the desired degree. If the patient has patella alta, the tubercle can be moved downward because it is completely freed from the tibia. This is done by cutting an appropriate-sized gap below the tubercle for the bone block to fit into it. Likewise, if the patient has patellar baja, the tubercle can be moved superiorly for the desired amount of correction.

Table 2. Contraindications and Limitations of Modified Tibial Tubercle Osteotomy

| | |
|-------------------|---|
| Contraindications | <ul style="list-style-type: none"> • Skeletally immature tibial tubercle apophysis • Patients with large proximal patellar chondral lesions |
| Limitations | <ul style="list-style-type: none"> • Osteotomy of the tibial tubercle alone may not be sufficient to restore patellar stability |

Table 3. Pearls and Pitfalls of Modified Tibial Tubercle Osteotomy

| Step | Pearls | Pitfalls |
|------------------------|---|---|
| Patient positioning | <ul style="list-style-type: none"> • The TTO should be performed with the knee in flexion with the assistance of an arthroscopic leg holder | <ul style="list-style-type: none"> • Performing the procedure in extension |
| Diagnostic arthroscopy | <ul style="list-style-type: none"> • Assess patellar position/tracking, trochlear morphology, medial and lateral subluxation/dislocation | <ul style="list-style-type: none"> • To appreciate lateral-sided tightness in flexion, the patellofemoral articulation is viewed from the inferomedial portal |
| Surgical approach | <ul style="list-style-type: none"> • Ensure balanced tracking of the patella in the femoral trochlea first using a lateral release • Ensure a long enough incision with adequate skin flaps to visualize the patella tendon | <ul style="list-style-type: none"> • Take care to avoid injuring the underlying meniscus |
| Osteotomy | <ul style="list-style-type: none"> • Preserve the distal-medial soft-tissue attachments of the tubercle fragment in cases of normal patella height | <ul style="list-style-type: none"> • Incise the anterior compartment fascia to prevent compartment syndrome • Excessive medialization and/or anteriorization |
| Fixation | <ul style="list-style-type: none"> • Only the near cortex should be drilled by the 4.5-mm drill to achieve screw compression | <ul style="list-style-type: none"> • When drilling the far cortex, stay within the superomedial safe zone of the tibia |
| Closure | <ul style="list-style-type: none"> • Consider MPFL or LPFL reconstruction in cases with lateral or medial instability after repair of the lateral release | <ul style="list-style-type: none"> • Overtensioning the repair using the iliotibial band rotation flap • Obtain meticulous hemostasis to avoid hematoma formation |
| Postoperative rehab | <ul style="list-style-type: none"> • Encourage early passive knee range of motion to prevent stiffness | <ul style="list-style-type: none"> • Protect weight bearing postoperatively to prevent fractures |

LPFL, lateral patellofemoral ligament; MPFL, medial patellofemoral ligament; TTO, tibial tubercle osteotomy.

Fixation

An osteotome is then used to lever the tubercle into the desired position and a K-wire is used to temporarily hold the bone block in place (Fig 2C). Through the 2 previously made drill holes, the far cortex of the tibia in the superomedial “safe zone”⁸ is drilled with a 3.2-mm drill and two 4.5-mm cortical screws (Synthes, West Chester, PA) are placed, thereby securing the tubercle in the desired position with compression. In cases of soft bone or the fixation is questionable, 6.5-mm cancellous screws (Synthes) may be substituted for the 4.5-mm screws or a small plate can be used to prevent migration of the bony fragment. Because the patellar tendon is attached to the tibial tubercle, by fixing the tubercle in the desired position, the alignment and pressure on the patellar tendon can be corrected. The bony defect created on the lateral side of the tibial tubercle is filled with DBX bone putty (Synthes) artificial bone graft for the best healing.

Closure

Once the tibial tubercle is secured in the corrected position, the defect created by the prior lateral release is closed by rotating a flap of tissue from the adjacent iliotibial band according the technique of Saper and Shneider⁹ (Fig 3). A wide strip of iliotibial band starting at the patellar margin and distally near the joint line is carefully developed leaving the synovium intact. This strip of tissue is mobilized enough to allow it to be rotated up to the lateral side of the patella and prevent the development of lateral side laxity and medial subluxation. Flap closure is performed with interrupted

sutures using No. 0 Vicryl (Ethicon, Somerville, NJ) (Fig 4). If possible the synovium is mobilized and brought up to close any remaining defect. Care is taken

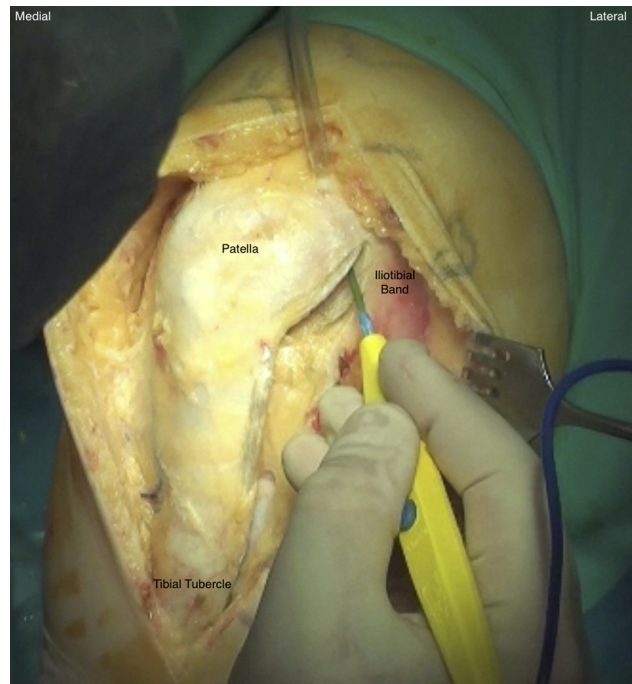


Fig 1. Intraoperative photograph of a left knee secured in a leg holder after a midline skin incision. Electrocautery is used to free the lateral side of the patellar tendon. The lateral retinaculum is carefully opened at the inferior lateral tip of the patella and carried only far enough proximally to allow the patella to center in the trochlear groove.

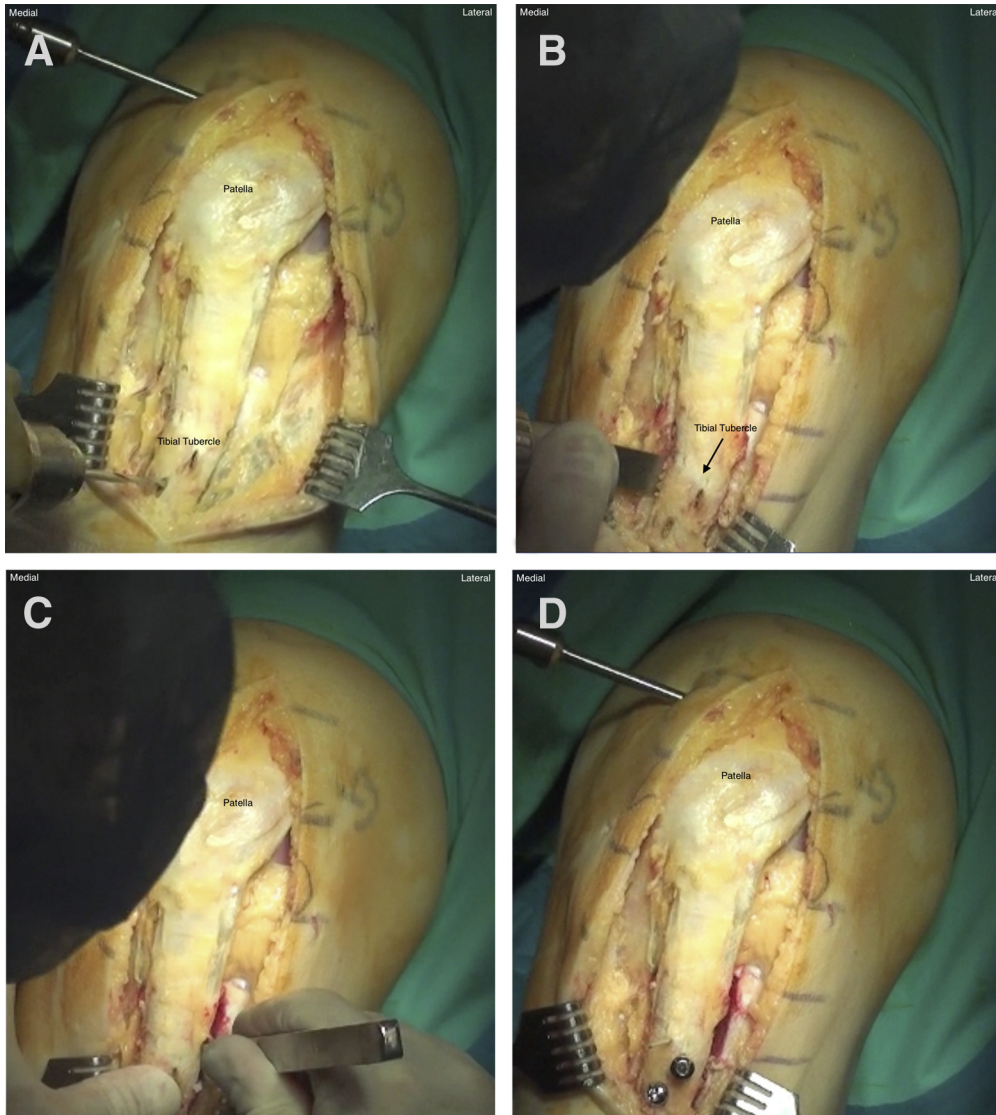


Fig 2. Intraoperative photograph sequence of a left knee undergoing anteromedialization of the tibial tubercle. (A) The boundaries of the tibial tubercle are identified and marked. Aiming parallel to the posterior tibial slope of the proximal tibia, the near cortex is drilled with a 4.5-mm drill. (B) The osteotomy is performed using an oscillating saw. (C) An osteotome is used to lever the tubercle fragment into the desired position. (D) The tibial tubercle is secured with two 4.5-mm cortical screws.

not to overtighten the synovium and thus block full excursion of the patella and patellar tendon.

Repeat arthroscopy is performed showing the patella to be centered within the femoral trochlea. At this point, the patella is examined for stability. Medial and lateral forces are applied to the patella in full extension and 30° of flexion to assess for medial and lateral patellar instability. If indicated, soft tissue reconstructions are performed at this time. The fascial and skin incisions are closed, a sterile dressing is applied, and the patient is placed in a knee immobilizer.

Postoperative Rehabilitation

Postoperatively, most patients are admitted for observation. Patients are educated on passive range of motion and quadriceps exercise, and discharged from the hospital the next day when independent and comfortable. Patients are encouraged to be partially

weight bearing with crutches for 6 weeks and gradually return to their prior activities. The knee immobilizer is discontinued when the patient has gained good quadriceps control. They are cleared for unrestricted activity once adequate bone healing of the osteotomy has occurred to prevent risk of fracture.

Discussion

The effects of TTO on patellofemoral biomechanics must be considered. As the tubercle is moved anteriorly, patellofemoral forces decrease, which can relieve pressure but may also decrease stability.^{3,10} Conversely, as the tubercle is moved posteriorly, patellofemoral forces increase, creating more stability but possibly resulting in excess pressures. As the tubercle is moved superiorly, again this may also relieve pressure but create instability. As the tubercle is moved inferiorly,

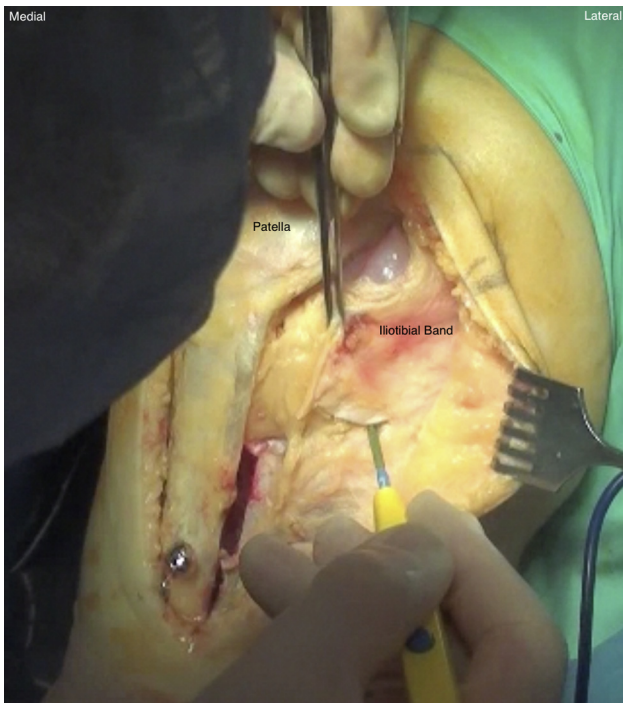


Fig 3. Intraoperative photograph of a left knee after fixation of the tibial tubercle. Rotating a flap of the adjacent iliotibial band to close the defect repairs the lateral release.

this may improve stability but create excessive pressure. These scenarios illustrate the challenge when addressing patellofemoral mechanics, as there is a delicate balance between relieving symptoms while avoiding overcorrection and the creation of new problems. The technique described above has been distilled to provide the surgeon with the most freedom to realign the tibial tubercle while creating the least amount of trauma to the tissues, and minimizing complications.

As our understanding of the biomechanics of the patellofemoral joint has evolved, so have the surgical techniques for TTO. Hauser¹¹ first described distal and medial transfer of the tibial tuberosity for recurrent patellar dislocation in 1938. Although this procedure was initially effective in resolving instability, with good or excellent results reported in 67% to 74% of cases, several studies have reported a high incidence of patellofemoral arthritis caused by the posterior translation of the tuberosity. In 1963, Maquet¹² modified the technique by displacing the tibial tuberosity anteriorly with bone graft to reduce the joint reactive force in the patellofemoral articulation. Maquet later recommended a 2.0- to 2.5-cm advancement based on geometrical calculations that suggested that a 50% decrease in the compressive patellofemoral force could be achieved. He reported 36 good or excellent results in 37 cases at a mean follow-up period of 4.7 years. The single failure in his series was due to skin necrosis over the elevated

tubercle. Cox¹³ modified Hauser's technique by transferring the tuberosity medially without translating it posteriorly with the Roux-Elmslie-Trillat procedure. Ten- to 15-year follow-up showed 62.5% good or excellent results, with osteoarthritis occurring more frequently in patients who had higher-grade chondral damage at the time of surgery. In 1983, Fulkerson¹⁴ introduced the anteromedialization technique and, later, straight anteriorization without bone grafts.

The Elmslie-Trillat procedure is one of the most common TTOs performed.¹ It moves the tibial tubercle only medial.¹⁵ Without moving the tubercle anteriorly, pressure is often increased. In addition, scar formation, adhering the patellar tendon to the underlying tibia, restricts motion and increases pressure. If a small incision is used, overcorrection often occurs and can produce secondary medial side patellar or femoral groove arthritic change. The Maquet procedure primarily moves the tubercle anteriorly and not medially.¹⁶ This procedure is also disfiguring to the tibia and often produces skin-healing problems. This technique produces overcorrection of the tibial tubercle in the wrong direction. The procedure developed by Fulkerson¹⁴ moves the tibial tubercle both anterior and medial and is much better. However, the recommended correction is mostly anterior and not medial. Desired correction is at least 10 mm anterior, which in many cases is in excess of what is required. In addition, the technique does not allow the tibial tubercle to easily move upward or downward to allow correction of patella alta or patella baja if required.

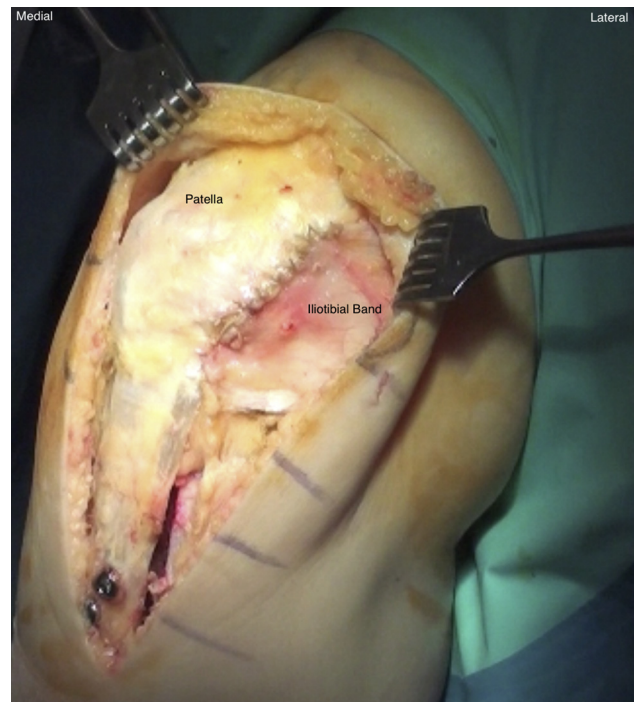

Fig 4. Intraoperative photograph of a left knee after lateral release, anteromedial tibial tubercle transfer, and repair of the lateral retinaculum.

The described technique combines the concepts of Elmslie-Trillat and Fulkerson and modified their techniques to produce a TTO that provides appropriate correction with less trauma to the tibia. Advantages of this technique are that it is dependable, reproducible, and can be universally used in cases of patellar malalignment, pressure, and/or instability. It has been found to be successful at preventing recurrence of symptoms and re-establishing the functional capacity of the knee joint with minimal risk to the patient and a short period of immobilization.

References

1. Longo UG, Rizzello G, Ciuffreda M, et al. Elmslie-Trillat, Maquet, Fulkerson, Roux Goldthwait, and other distal realignment procedures for the management of patellar dislocation: Systematic review and quantitative synthesis of the literature. *Arthroscopy* 2016;32:929-943.
2. Stephen JM, Dodds AL, Lumpaopong P, Kader D, Williams A, Amis AA. The ability of medial patellofemoral ligament reconstruction to correct patellar kinematics and contact mechanics in the presence of a lateralized tibial tubercle. *Am J Sports Med* 2015;43:2198-2207.
3. Rue LJ-PH, Colton A, Zare SM, et al. Trochlear contact pressures after straight anteriorization of the tibial tuberosity. *Am J Sports Med* 2008;36:1953-1959.
4. Ramappa AJ, Apreleva M, Harrold FR, Fitzgibbons PG, Wilson DR, Gill TJ. The effects of medialization and anteromedialization of the tibial tubercle on patellofemoral mechanics and kinematics. *Am J Sports Med* 2006;34:749-756.
5. Beck PR, Thomas AL, Farr J, Lewis PB, Cole BJ. Trochlear contact pressures after anteromedialization of the tibial tubercle. *Am J Sports Med* 2005;33:1710-1715.
6. Stephen JM, Lumpaopong P, Dodds AL, Williams A, Amis AA. The effect of tibial tuberosity medialization and lateralization on patellofemoral joint kinematics, contact mechanics, and stability. *Am J Sports Med* 2015;43:186-194.
7. Mayer C, Magnussen RA, Servien E, et al. Patellar tendon tenodesis in association with tibial tubercle distalization for the treatment of episodic patellar dislocation with patella alta. *Am J Sports Med* 2012;40:346-351.
8. Shetty AA, Tindall AJ, Nickolaou N, James KD, Igunotus P. A safe zone for the passage of screws through the posterior tibial cortex in tibial tubercle transfer. *Knee* 2005;12:99-101.
9. Saper MG, Shneider DA. Diagnosis and treatment of lateral patellar compression syndrome. *Arthrosc Tech* 2014;3:e633-e638.
10. Chrisman OD, Snook GA, Wilson TC. A long-term prospective study of the Hauser and Roux-Goldthwait procedures for recurrent patellar dislocation. *Clin Orthop* 1979;144:27-30.
11. Hauser EDW. Total tendon transplant for slipping patella: A new operation for recurrent dislocation of the patella. *Surg Gynec Obstet* 1938;66:199-214.
12. Maquet P. A biomechanical treatment of femoro-patellar arthrosis: Advancement of the patellar tendon. *Rev Rhum Mal Osteoartic* 1963;30:779-783.
13. Cox JS. Evaluation of the Roux-Elmslie-Trillat procedure for knee extensor realignment. *Am J Sports Med* 1982;10:303-310.
14. Fulkerson JP. Anteromedialization of the tibial tuberosity for patellofemoral malalignment. *Clin Orthop* 1983;177:176-181.
15. Cox JS. An evaluation of the Elmslie-Trillat procedure for management of patellar dislocations and subluxations: A preliminary report. *Am J Sports Med* 1976;4:72-77.
16. Maquet P. Advancement of the tibial tuberosity. *Clin Orthop* 1976;115:225-230.