

# Perioperative management of a patient with Coffin–Lowry syndrome complicated by severe obesity

## A case report and literature review

Mikako Hirakawa, MD<sup>a</sup>, Tasuku Nishihara, MD, PhD<sup>a,\*</sup>, Kazuo Nakanishi, MD<sup>a</sup>, Sakiko Kitamura, MD<sup>a</sup>, Sonoko Fujii, MD<sup>b</sup>, Keizo Ikemune, MD, PhD<sup>c</sup>, Kentaro Dote, MD<sup>c</sup>, Yasushi Takasaki, MD<sup>b</sup>, Toshihiro Yorozyua, MD<sup>b</sup>

### Abstract

**Rationale:** Coffin–Lowry syndrome (CLS) is a rare inherited disease with specific clinical features, such as mental retardation, facial dysmorphism, and cardiac abnormality. In particular, the characteristic facial features of CLS, including retrognathia and large tongue, are associated with difficult ventilation and/or intubation, which is a serious problem of anesthesia management. However, case reports on anesthesia management of CLS are very limited as there are only two published English reports till date. In this case report, we discuss anesthetic and postoperative considerations in patients with CLS, focusing on difficult airway management, and summarize past reports including some Japanese articles.

**Patient concerns:** A 25-year-old man with CLS was planning to undergo laminectomy because of progressive quadriplegia caused by calcification of the yellow ligament. We suspected difficulty in airway management because of several factors in his facial features, short thyromental and sternomental distances in computed tomography, severe obesity, and sleep apnea syndrome.

**Diagnoses:** Difficult airway was suspected. However, because of mental retardation, awake intubation was considered difficult.

**Interventions:** We selected bronchofiberscope-guided nasotracheal intubation, maintaining spontaneous breathing under moderate sedation with a propofol target-controlled infusion.

**Outcomes:** Airway management was safely performed during anesthesia induction.

**Lessons:** In many patients with CLS, difficult intubation was reported, and sedation or slow induction maintaining spontaneous breathing was mainly selected for anesthesia induction. Spontaneous breathing should be maintained during anesthesia induction in case of CLS patients.

**Abbreviations:** AWS = Airwayscope, CLS = Coffin–Lowry syndrome, CT = computed tomography, DAS = Difficult Airway Society, ICU = intensive care unit, POD = postoperative day, SAS = sleep apnea syndrome, SMD = sternomental distance, TCI = target-controlled infusion, TMD = thyromental distance.

**Keywords:** anesthesia management, Coffin–Lowry syndrome, difficult airway management, spontaneous breathing

## 1. Introduction

Coffin–Lowry syndrome (CLS; OMIM 303600) is a rare inherited disease caused by a mutation in the RPS6KA3 gene

Editor: Joho Tokumine.

The authors have no conflicts of interest to disclose.

<sup>a</sup> Department of Anesthesiology and Resuscitology, Ehime University Hospital, Shitsukawa, Toon, <sup>b</sup> Department of Anesthesia and Perioperative Medicine, Ehime University Graduate School of Medicine, <sup>c</sup> Intensive Care Unit, Ehime University Hospital, Shitsukawa, Toon, Ehime, Japan.

\* Correspondence: Tasuku Nishihara, Department of Anesthesiology and Resuscitology, Ehime University Hospital, Shitsukawa, Toon, Ehime 791-0295, Japan (e-mail: ntasukuk@yahoo.co.jp).

Copyright © 2017 the Author(s). Published by Wolters Kluwer Health, Inc. This is an open access article distributed under the terms of the Creative Commons Attribution-Non Commercial-ShareAlike 4.0 License, which allows others to remix, tweak, and build upon the work non-commercially, as long as the author is credited and the new creations are licensed under the identical terms.

Medicine (2017) 96:49(e9026)

Received: 14 September 2017 / Received in final form: 9 November 2017 /

Accepted: 10 November 2017

<http://dx.doi.org/10.1097/MD.0000000000009026>

on chromosome Xp22. The typical clinical features are intellectual disability, growth retardation, dysmorphic facial features, skeletal anomalies, and occasionally cardiac abnormalities.<sup>[1–3]</sup> The characteristic facial features of CLS, including retrognathia and tongue enlargement,<sup>[3,4]</sup> may cause difficulty with mask ventilation and tracheal intubation, which are serious problems in anesthesia management. Case reports on anesthesia management of CLS are sparse as there are only 2 published English reports.<sup>[4,5]</sup> In this report, we discuss the anesthetic and postoperative management of CLS patients and include reviews from 2 previous English reports and 4 Japanese reports.<sup>[6–9]</sup>

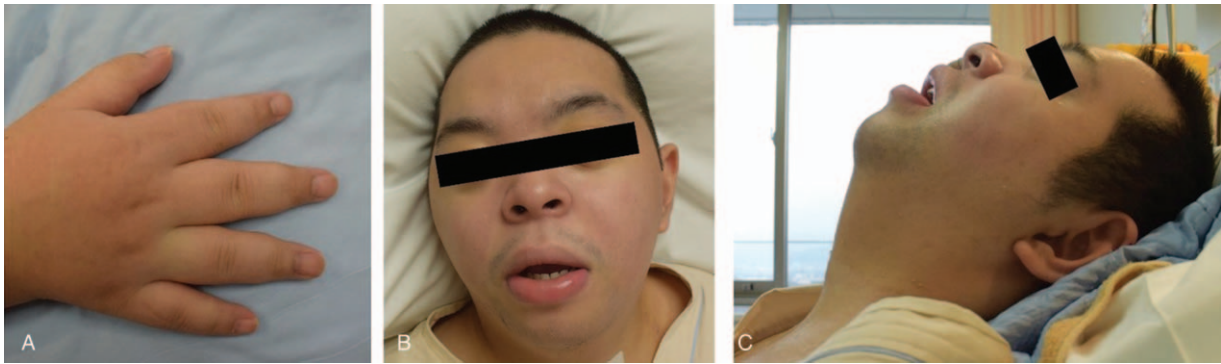
## 2. Patient consent

We obtained informed consent for publishing this case report and for using related images from patient's parents.

## 3. Case report

### 3.1. History

A 25-year-old man was scheduled to undergo laminectomy and decompression because of progressive quadriplegia. The patient



**Figure 1.** Characteristic findings of the Coffin–Lowry syndrome. (A) Puffy tapered finger. (B) Broad nose and thick everted lips. (C) A side view of the patient’s face.

exhibited no abnormality during prenatal growth. At the age of 1 year, CLS was suspected based on his facial features, such as a broad nose and thick everted lips, and he was diagnosed with CLS via genetic analysis at the age of 3 years. At the age of 14 years, the patient gradually developed quadriplegia because of cervical cord compression induced by the forward shift of the atlas and calcification of the yellow ligament, and he experienced difficulty in walking. The patient underwent laminectomy of the 1st–7th cervical vertebrae under general anesthesia at the age of 15 years<sup>[10]</sup>; however, laminectomy did not resolve his symptoms consistently, that is, his symptoms relapsed and remitted.

### 3.2. Presentation

At the age of 24 years, the patient could no longer maintain a standing position without assistance. He was scheduled for laminectomy because of exacerbation due to recalcification of the yellow ligament.

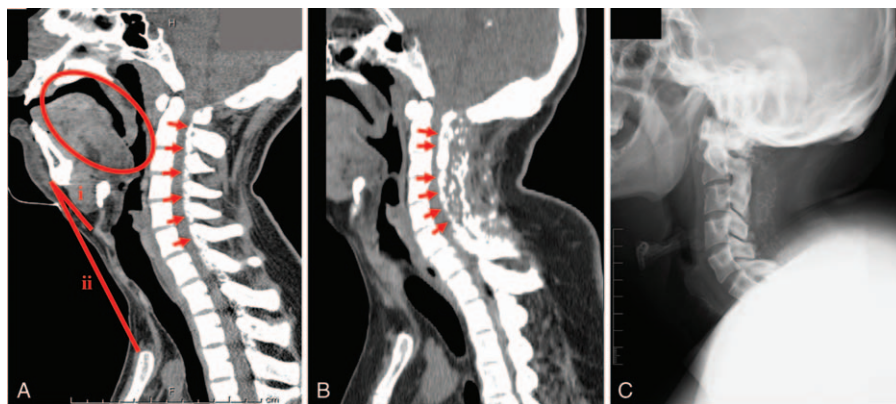
During preoperative examination, the patient exhibited puffy tapered fingers, a broad nose, and thick everted lips, which are characteristic of CLS (Fig. 1) and severe obesity (height, 145 cm; weight, 80 kg; BMI, 38 kg/m<sup>2</sup>). Cardiac comorbidities such as anomaly or valvular disease and respiratory comorbidities such as respiratory dysfunction caused by skeletal abnormality were not found. Computed tomography (CT) revealed calcification of the yellow ligament, macroglossia, upper airway narrowing, and

short thyromental distance (TMD; 40 mm) and sternomental distance (SMD; 118 mm) (Fig. 2). The patient snored while sleeping, and sleep apnea syndrome (SAS) was suspected. Airway assessments could not be performed because the patient struggled to follow instructions because of mental retardation. We noted that the following comment was made in the patient’s anesthetic record at the age of 15 years: “Difficult mask ventilation. Two-person mask ventilation was required. Cormack grade III with Macintosh laryngoscope. Easy intubation with Airwayscope (AWS).”

Based on these findings and information, we expected difficulty with mask ventilation and intubation as well as awake intubation because of mental retardation. Therefore, we planned bronchofiberscope-guided nasotracheal intubation, maintaining spontaneous breathing under moderate sedation with propofol.

### 3.3. Anesthesia and operation

The patient’s blood oxygen saturation (SpO<sub>2</sub>) was 98% when he entered the operation room, and the value increased to 100% under 10 L/min O<sub>2</sub> flow using a mask before anesthesia induction. After 60 mg of lidocaine was administered to prevent propofol injection pain,<sup>[11]</sup> sedation was initiated via target-controlled infusion (TCI) of 1.5 μg/ml propofol. We could successfully maintain the patient’s spontaneous breathing and reach sedation while gradually decreasing his consciousness level.



**Figure 2.** Cervical computed tomography (CT) and x-ray images. (A) Cervical CT image taken before the first operation 9 years ago. A narrow upper airway (circle), calcification of the yellow ligament (arrows), and short thyromental (i, 40 mm) and sternomental distances (ii, 118 mm) are noted; (B) Cervical CT image taken before the operation. Recalcification of the yellow ligament (arrows) was found. (C) Cervical x-ray photograph. CT=computed tomography.

After confirmation that SpO<sub>2</sub> was maintained at 100%, a basic tracheal tube (internal diameter, 7.0 mm) was inserted through his right nostril and the bronchofiberscope was inserted through the tracheal tube. The vocal folds were easily found, and bronchofiberscope-guided intubation was performed. Spontaneous breathing was maintained during these processes. After appropriate intubation into the trachea was confirmed using a capnometer, 50 mg propofol and 50 mg rocuronium were additionally administered. These processes were smoothly performed. As O<sub>2</sub> was inhaled through the mask during bronchofiberscope-guided intubation, SpO<sub>2</sub> was maintained at >98%. After intubation, the upper airway and larynx were observed using AWS. In general, a regular-sized intlock would be applied for this procedure. However, in this case, a thin intlock was needed because of large tongue and narrow airway. His epiglottis and vocal folds were confirmed. Anesthesia was maintained using propofol (TCI, 2.5–3.5 µg/mL) and remifentanyl (0.1–0.3 µg/kg/min). The surgery was performed without any complications. The duration of surgery was 315 minutes and that of anesthesia was 455 minutes. Postoperatively, the patient was admitted to the intensive care unit (ICU) under intubation to keep the surgical wound at rest.

### 3.4. Postoperative course

The patient was managed under sedation and analgesia with propofol, dexmedetomidine, and fentanyl in the ICU. On postoperative day (POD) 4, awakening and extubation were planned. We considered the possibility of reintubation due to obstruction or aspiration because his oral secretion increased as he awoke; therefore, we extubated the patient by inserting a tube exchanger into the trachea. He neither struggled nor disliked the tube exchanger. However, as we suspected, SpO<sub>2</sub> decreased to 90% because he could not discharge oral secretion by himself. Assist ventilation was performed, but it was inadequate. Although assisted ventilation became possible after insertion of a nasal airway and SpO<sub>2</sub> improved to 99%, we decided to reintubate because of the accumulation of CO<sub>2</sub> (PaCO<sub>2</sub>, 55.4 mmHg). Reintubation was performed using a GlideScope under

tube exchanger guidance. On POD 8, tracheotomy was performed. After tracheotomy, weaning from mechanical ventilation was smoothly performed, and ventilation was discontinued on POD 11. The patient was discharged from the ICU on POD 14. On POD 21, deglutition training was started, and aspiration was gradually decreased. The tracheotomy aperture was gradually closed spontaneously and completely closed on POD 26. He was discharged to his home on POD 55.

## 4. Discussion

CLS is a rare disease that was first reported by Coffin et al.<sup>[12]</sup> and Lowry et al.<sup>[13]</sup> Its estimated incidence is reported as 1 per 50,000 to 100,000 people.<sup>[2]</sup> Only 2 case reports in English related to anesthesia management of patients with this disease have been published.

In anesthesia management, patients with this syndrome exhibit the following problems: (1) difficulty in communication because of mental retardation that is severe in males, (2) risks of difficult airway management caused by a large tongue and retrognathia, (3) respiratory comorbidities due to skeletal abnormalities such as scoliosis, and (4) cardiac comorbidities such as valvular disease and cardiomyopathy.

We have summarized previous case reports related to anesthesia management in patients with CLS including some Japanese articles,<sup>[6–9]</sup> in Table 1 to provide more information. Although the airway management strategy varied among cases, spontaneous breathing was often maintained. Moreover, Cormack grades III–IV<sup>[5,7,8]</sup> and Mallampati scale 3–4,<sup>[4,14]</sup> indicating difficult intubation, were reported in many cases.

In this case, difficulty with mask ventilation and intubation was anticipated for the following reasons: Cormack grade III, clinical record of previous anesthetic management, airway narrowing caused by retrognathia and a large tongue, short TMD and SMD, severe obesity, and SAS.<sup>[15–18]</sup> Awake fiberoptic intubation is commonly selected when difficult intubation is anticipated, and it has been reported to be successful in >90% of patients with difficult airway management.<sup>[19]</sup> However, in case of CLS, awake intubation is impossible because of the patient's mental

**Table 1**  
Anesthesia induction in previously reported cases of Coffin–Lowry syndrome.

	Case	Operation	Details of anesthesia induction
Singh PM et al. <sup>[4]</sup>	14 years, M unknown cm, 25 kg	Vitreoretinal surgery	Slow induction with O <sub>2</sub> and sevoflurane. Mask ventilation possible. Administration of fentanyl 50 µg and atracurium 10 mg. Insert Proseal laryngeal mask airway (LMA, size 2.5). Maintain with LMA during surgery.
Deguchi et al. <sup>[5]</sup>	31 years, M 161 cm, 60 kg	Posterior spinal fusion	Sedation with fentanyl 50 µg and propofol target-controlled infusion 1.5 µg/ml. Spontaneous breathing maintained. Laryngoscopy with McGRATH. Cormack Grade III. Attempted bronchofiberscope-guided tracheal intubation under the McGRATH monitor. Image was unusable because of the large tongue. Successful bronchofiberscope-guided tracheal intubation under the monitor of the Pentax-AWS Airwayscope with a thin intlock.
Hashiguchi et al. <sup>[6]</sup>	33 years, F 138 cm, 39.5 kg	Cervical cyst resection	Slow induction with propofol 20 mg/kg/h. Mask ventilation possible. Administration of fentanyl 100 µg, vecuronium 6 mg, and midazolam 2.5 mg. Regularly intubated with a Macintosh laryngoscope.
Kaneko et al. <sup>[7]</sup>	10 years, F 120 cm, 20 kg	Chronic subdural hematoma evacuation	Induction with propofol 40 mg, fentanyl 50 µg, and vecuronium 6 mg. Mask ventilation impossible. Intubation attempted (Cormack Grade IV). Success in blind intubation in the third attempt.
Inamura et al. <sup>[8]</sup>	24 years, M 165 cm, 66 kg	Dental treatment	Sedation with fentanyl 50 µg and midazolam 3 mg. Spontaneous breathing maintained. Laryngoscopy with a Macintosh laryngoscope. Cormack Grade IV. Nasotracheal intubation with bronchofiberscope guidance under spontaneous breathing.
Kawana et al. <sup>[9]</sup>	12 years, M 141 cm, 47 kg	Posterior Cervical spinal fusion	Slow induction with O <sub>2</sub> and sevoflurane 3%–5%. Insert LMA Fastrach. Bronchofiberscope-guided intubation through the LMA Fastrach using rocuronium 25 mg.

retardation. Therefore, we selected bronchofiberscope-guided nasotracheal intubation under sedation, maintaining spontaneous breathing, which resulted in a safe anesthetic induction. However, we should simultaneously consider the risks of sedation itself. Intubation under sedation sometimes induces exaggerated laryngeal reflex or regurgitation of gastric contents, leading to desaturation. If the sedation becomes deep and mask ventilation becomes necessary, it may lead to impossible ventilation. In such cases of patients with CLS, it might be better to awaken the patient. Not only mask ventilation but also intubation will be difficult in such cases.

Consequently, we could confirm the vocal folds using AWS with a thin intlock after intubation at the time of anesthesia induction and could complete reintubation using a GlideScope in ICU. However, it was uncertain whether intubation using those devices was successful at the time of anesthesia induction.

Extubation should be managed more carefully. Intubation outside the operation room is sometimes more difficult compared with that in the operation room, which should be considered at the time of extubation and possible reintubation. According to the extubation guideline of the Difficult Airway Society (DAS), awake extubation or advanced techniques (laryngeal mask exchange, remifentanyl technique, and airway exchange catheter) are mentioned in the “at-risk” algorithm for extubation.<sup>[20]</sup> In this case, we extubated the patient using a tube exchanger, but reintubation was needed because of the aspiration of oral secretion. Tube exchanger may itself become the route of aspiration because the vocal folds are maintained in an open position because of the tube exchanger. The guide route for reintubation should be ensured. Indeed, the use of tube exchanger is recommended or useful for successful reintubation in cases of difficult airway management.<sup>[9,19,20]</sup> In this case, it was useful for definite and prompt reintubation with the combined use of GlideScope. Combined use of videolaryngoscopy increases the success of reintubation using the tube exchanger.<sup>[20,21]</sup>

For anesthesia management of patients with CLS, we suggest that it might be better not to begin anesthesia by oneself but to call for help from the beginning if available, spontaneous breathing should be maintained during the anesthesia induction, AWS with thin intlock or GlideScope may be useful if mask ventilation is possible, and we must be careful during extubation considering airway obstruction because of narrow airway and/or aspiration of oral secretion.

## 5. Conclusions

CLS is a rare disease associated with difficulty in anesthesia management including difficult airway management. Therefore, we should consider anesthetic plans for these problems. Maintaining spontaneous breathing during anesthesia induction may be the important key for ensuring the safety of patients with CLS.

## References

- [1] Hanauer A, Young ID. Coffin–Lowry syndrome: clinical and molecular features. *J Med Genet* 2002;39:705–13.
- [2] Pereira PM, Schneider A, Pannetier S, et al. Coffin–Lowry syndrome. *Eur J Hum Genet* 2010;18:627–33.
- [3] Rogers RC, Abidi FE. Coffin–Lowry Syndrome. *GeneReviews™*. 2002; University of Washington, Seattle, WA:1993–2017.
- [4] Singh PM, Baidya DK, Govindarajan S, et al. Ocular surgery in a child with Coffin Lowry syndrome: anesthetic concerns. *J Anaesthesiol Clin Pharmacol* 2013;29:114–6.
- [5] Deguchi S, Komasa N, Morimoto K, et al. Difficult airway management using the Pentax-AWS Airwayscope with a thin Intlock and bronchofiberscope in a patient with Coffin–Lowry syndrome. *J Clin Anesth* 2016;29:1–2.
- [6] Hashiguchi K, O'Higashi T, Sasai S, et al. Anesthetic management of a patient with Coffin–Lowry syndrome (in Japanese with English abstract). *Masui* 1999;48:1027–9.
- [7] Kaneko T, Saito Y, Hikawa Y, et al. Chronic subdural hematoma in a patient with Coffin–Lowry syndrome complicated with idiopathic thrombocytopenic purpura (in Japanese). *Rinsho Masui* 1999;23:825–8.
- [8] Inamura Y, Kaneda K, Sakuma Y, et al. A case of day care anesthesia of Coffin–Lowry syndrome patient with severe obstructive sleep apnea syndrome (in Japanese). *J Jpn Dent Soc Anesthesiol* 2003;36:571–2.
- [9] Kawana Y, Okamura K, Kurahashi K. A boy with Coffin–Lowry syndrome associated with spinal cord injuries (in Japanese with English abstract). *Masui* 2014;63:203–5.
- [10] Morino T, Ogata T, Horiuchi H, et al. Eight years of follow-up after laminectomy of calcium pyrophosphate crystal deposition in the cervical yellow ligament of patient with Coffin–Lowry syndrome: a case report. *Medicine (Baltimore)* 2016;95:e4468.
- [11] Lang BC, Yang CS, Zhang LL, et al. Efficacy of lidocaine on preventing incidence and severity of pain associated with propofol using in pediatric patients: a PRISMA-compliant meta-analysis of randomized controlled trials. *Medicine (Baltimore)* 2017;96:e6320.
- [12] Coffin GS, Siris E, Wegenkia LC. Mental retardation with osteocartilaginous anomalies. *Am J Dis Child* 1966;112:205–13.
- [13] Lowry B, Miller JR, Fraser FC. A new dominant gene mental retardation syndrome. *Am J Dis Child* 1971;121:496–500.
- [14] Moura EB, Moura ÉL, Amorim FF, et al. Mechanical ventilation in Coffin–Lowry syndrome: a case report. *Rev Bras Ter Intensiva* 2016;28:483–7.
- [15] Khan ZH, Mohammadi M, Rasouli MR, et al. The diagnostic value of the upper lip bite test combined with sternomental distance, thyromental distance, and interincisor distance for prediction of easy laryngoscopy and intubation: a prospective study. *Anesth Analg* 2009;109:822–4.
- [16] Shah PN, Sundaram V. Incidence and predictors of difficult mask ventilation and intubation. *J Anaesthesiol Clin Pharmacol* 2012;28:451–5.
- [17] Kheterpal S, Han R, Tremper KK, et al. Incidence and predictors of difficult and impossible mask ventilation. *Anesthesiology* 2006;105:885–91.
- [18] Law JA, Broemling N, Cooper RM, et al. Canadian Airway Focus Group. The difficult airway with recommendations for management—part 2—the anticipated difficult airway. *Can J Anaesth* 2013;60:1119–38.
- [19] Apfelbaum JL, Hagberg CA, Caplan RA, et al. American Society of Anesthesiologists Task Force on Management of the Difficult Airway. Practice guidelines for management of the difficult airway: an updated report by the American society of anesthesiologists task force on management of the difficult airway. *Anesthesiology* 2013;118:251–70.
- [20] Popat M, Mitchell V, et al. Difficult Airway Society Extubation Guidelines Group/Difficult Airway Society Guidelines for the management of tracheal extubation. *Anaesthesia* 2012;67:318–40.
- [21] Mort TC. Tracheal tube exchange: feasibility of continuous glottic viewing with advanced laryngoscopy assistance. *Anesth Analg* 2009;108:1228–31.