



Case report

Chronic epigastric pain associated with gastric anisakidosis

Christine Bookhout*, Kevin Greene

Department of Pathology (Division of Surgical Pathology), Women's and Children's Hospitals, The University of North Carolina at Chapel Hill, 3rd Floor, Room 30149, 101 Manning Drive, Chapel Hill, NC, 27514, USA

ARTICLE INFO

Article history:

Received 26 February 2019

Received in revised form 1 March 2019

Accepted 1 March 2019

Keywords:

Anisakidosis

Anisakis

Nematode

Epigastric pain

Endoscopy

Albendazole

ABSTRACT

Anisakidosis is an acute and, less commonly, chronic gastrointestinal tract disease caused by the ingestion of nematode larvae contained within raw or undercooked seafood. We describe a case of chronic gastric anisakidosis diagnosed by endoscopic resection of submucosal nodules in a patient with a multi-year history of epigastric abdominal pain. This case illustrates the importance of maintaining a high index of suspicion for this diagnosis, even in patients with a remote history of seafood consumption or a chronic presentation of abdominal pain.

© 2019 The Authors. Published by Elsevier Ltd. This is an open access article under the CC BY-NC-ND license (<http://creativecommons.org/licenses/by-nc-nd/4.0/>).

Introduction

Anisakidae is a family of parasitic nematodes that can infect the human gastrointestinal tract after consumption of raw or undercooked fish or squid [1]. Their natural life cycle involves crustaceans, fish or squid, and marine mammals; humans are a dead end host (Fig. 1). Anisakidosis, also known as herring worm or codworm disease, is most commonly caused by *Anisakis simplex* (infection referred to as anisakiasis) and *Pseudoterranova decipiens*, although other members of the family Anisakidae can less commonly be responsible for human infections [2,3]. Most reported cases occur in Japan; however, coastal areas of Europe, the United States, and several other countries also have documented cases [2].

Infection is often related to consumption of raw seafood dishes such as sushi, ceviche, sashimi, and pickled herring, although undercooked seafood can also be a culprit. Non-invasive infection can occur and is characterized by a tingling feeling or motion in the throat related to worm migration into the esophagus or oropharynx after swallowing, and worms may be expelled by coughing or vomiting [4]. Invasive infection occurs when larvae attach to or penetrate host tissues, with worms most commonly found in the gastric and intestinal mucosa and submucosa [4]. Symptoms of

acute infection include epigastric pain, nausea, vomiting, and allergic symptoms such as urticaria, usually starting within hours of ingestion [5]. Computed tomography (CT) scan generally shows edematous wall thickening of involved organs, and can show ascites and inflammation of the mesenteric fat [5]. Penetration through the stomach or intestine with migration into the peritoneal cavity, pleural cavity, mesentery, liver, pancreas, ovary, subcutaneous tissue, and other sites can occur [2,4]. Untreated infections can also become chronic, with ulcer-like symptoms that can last for months or years and cause diagnostic difficulty [2,4,6]. Although the larvae likely only survive in the human host for a matter of weeks, abscesses or granulomatous inflammation can occur in response to degenerating anisakid larvae [2]. Here, we present a case of gastric anisakidosis diagnosed in a patient with a history of long-term, chronic abdominal pain.

Case report

The patient, a Korean-American woman in her early 50s, presented with a history of epigastric abdominal pain for over 10 years. The pain was usually postprandial, and could be triggered by ingestion of caffeine or spicy foods. She moved to the United States from Korea about 30 years prior to presentation, and had returned to Korea a few times, most recently two years earlier. She had eaten sushi in Japanese restaurants locally and had cooked and consumed frozen salmon from grocery stores. Otherwise, she did not usually buy raw fish to prepare and did not report consumption of undercooked or fermented seafood at home.

She was empirically diagnosed with peptic ulcer disease and treated with anti-acid therapy. Her pain continued, however, and

Abbreviations: ELISA, enzyme-linked immunosorbent assay; CT, computed tomography.

* Corresponding author.

E-mail addresses: Christine.Bookhout@unchealth.unc.edu (C. Bookhout), Kevin.Greene@unchealth.unc.edu (K. Greene).

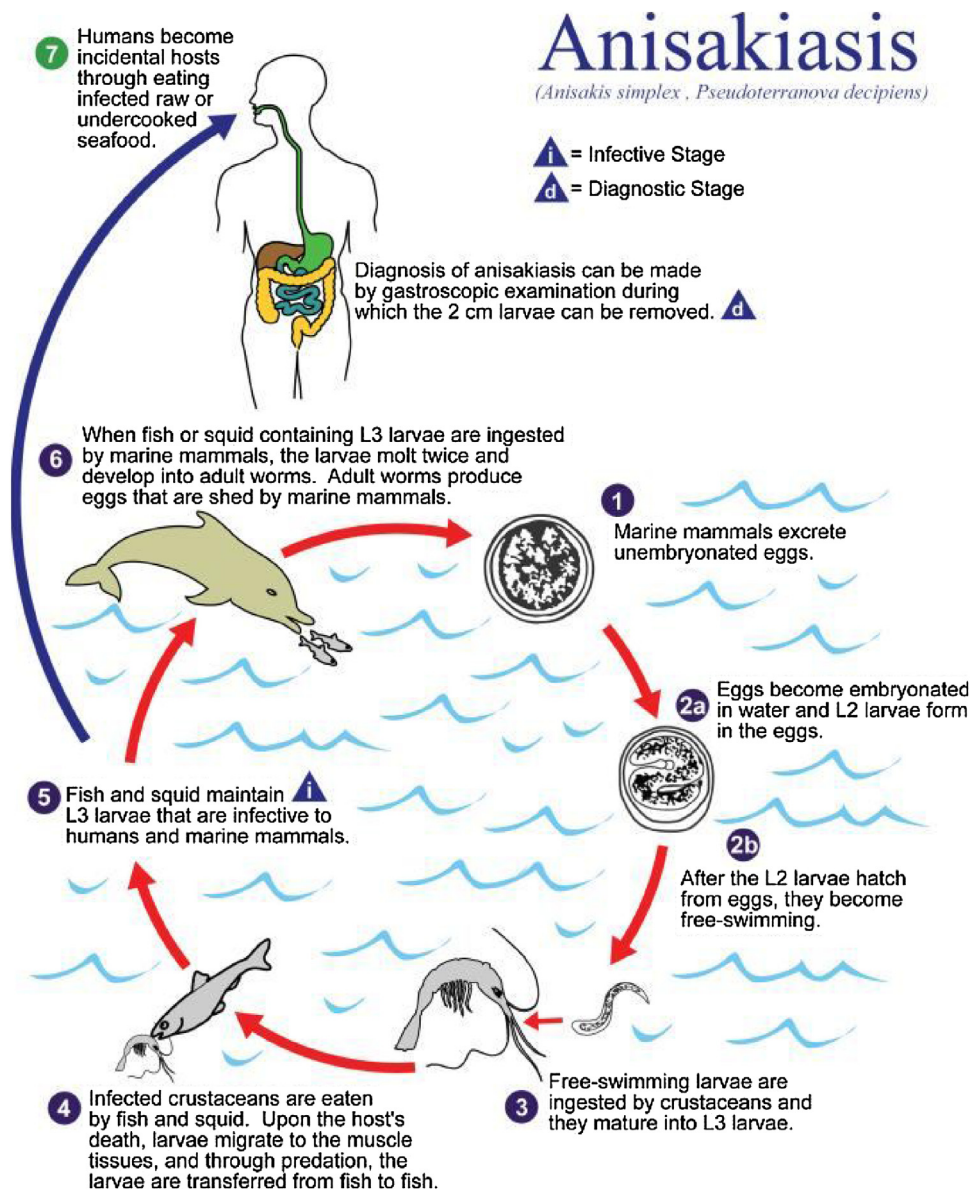


Fig. 1. Life cycle of the nematodes *Anisakis simplex* and *Pseudoterranova decipiens*, the causal agents of anisakiasis. Reproduced with permission from CDC.gov Public Health Image Library (CDC / Alexander J. da Silva, PhD; Melanie Moser).

she experienced approximately 10 pounds of unintentional weight loss prior to presentation. She underwent an upper endoscopy which showed mild inflammation and erosions in the gastric antrum, as well as a nodule on the lesser curvature of the stomach,

which was biopsied. Pathologic examination was unrevealing, however, showing only mild chronic superficial gastritis. Due to continued pain, she underwent a repeat upper endoscopy nine months later. Three small, submucosal, non-circumferential

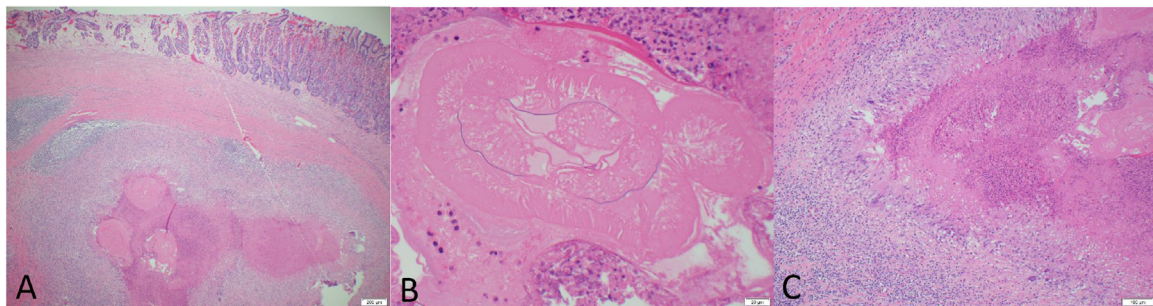


Fig. 2. A. Low power view of submucosal anisakid larvae and associated necrotizing granulomatous inflammation (40×). 2B. High power view of nonviable anisakid larva showing internal structures (400×). 2C. Medium power view of necrotizing granulomatous inflammation with associated eosinophils and foreign body giant cell response (100×).

lesions with no bleeding were noted in the gastric body and antrum, measuring up to approximately 9 mm in diameter. Submucosal resection was performed on two of the lesions. Pathologic examination revealed a submucosal necrotizing granulomatous response associated with numerous eosinophils and foreign body giant cells, surrounding non-viable nematode larvae. Although the larvae showed degenerative changes, the size, morphology, and localization were consistent with anisakidosis (Fig. 2). Laboratory testing revealed a normal white blood cell count (5400 cells / μ L) without an elevated eosinophil count.

Given the otherwise mild gastritis, the degenerated anisakid larvae and associated necrotizing granulomatous response were clinically believed to be the major cause of the patient's chronic epigastric pain. Since one of the three visualized submucosal lesions was not removed, and because concomitant intestinal involvement could not be excluded, the patient was treated with albendazole for 10 days. She was instructed to return if her abdominal pain did not improve for a possible repeat upper endoscopy to extract any remaining lesions; however, she did not subsequently present for follow up.

Discussion

Our patient presented with over 10 years of chronic abdominal pain, and accurate diagnosis of gastric anisakidosis required two endoscopic procedures. Although it cannot be determined with certainty when her initial infection occurred, her pain remained relatively constant for several years, and an initial endoscopy nine months prior to the eventual diagnosis showed a gastric nodule. The biopsy at that time was superficial, however, and did not sample submucosal tissue that could have proven diagnostic.

During her second endoscopic procedure, mucosal resection of gastric nodules was performed, providing a sufficient tissue sample to identify the parasites and associated granulomatous inflammatory response in the gastric submucosa. Although direct visualization of the parasite often confirms the diagnosis in gastric anisakidosis, anti-*Anisakis simplex* antibody detection can be performed by immunoassays such as enzyme-linked immunosorbent assay (ELISA) or latex agglutination, which can be particularly useful in intestinal or extra-intestinal cases [7,8]. PCR-based techniques to amplify the DNA of *Anisakis* species in formalin fixed, paraffin-embedded tissues are also being developed [9,10].

Although our patient's larval excision was delayed, early endoscopic extraction is the preferred treatment of gastric anisakidosis unless the larva is spontaneously regurgitated [2,11,12]. Delayed removal can result in larvae embedding into the submucosa, as in our case, which required a larger procedure (submucosal resection) for removal. Although the larvae in our case were non-viable, the marked associated granulomatous reaction may have been ongoing and resulted in epigastric pain. Anisakidosis can also cause allergic symptoms, including urticaria, angioedema, and even anaphylaxis, often associated with high levels of anti-*Anisakis simplex* IgE antibody [8].

Our patient was treated with albendazole therapy in an attempt to eradicate any possible residual anisakid larvae, although exposure was likely remote and the presence of viable larvae was considered unlikely. This therapy is generally well tolerated, however, and there is some evidence to suggest that medical therapy with albendazole can provide effective treatment [13,14]. While endoscopic treatment is usually performed for gastric anisakidosis, conservative and medical therapy can be attempted for intestinal and extra-intestinal disease, with surgery reserved for complications such as obstruction or appendicitis [2]. Infection can be prevented by adequately cooking or freezing seafood prior to consumption.

Conclusion

In this report, we describe a case of gastric anisakidosis diagnosed in a patient with a several year history of chronic abdominal pain. With the increasing popularity of sushi and other uncooked or lightly cooked seafood dishes in the United States, the prevalence of anisakidosis seems likely to increase. The classic presentation of acute abdominal pain, nausea, and vomiting temporally correlated with the ingestion of raw or undercooked seafood facilitates diagnosis; however, the chronic form of the disease can be diagnostically challenging. Therefore, it is important for clinicians, endoscopists, and pathologists to maintain a high index of suspicion for this diagnosis, even in patients with a remote history of seafood consumption or a presentation of unexplained chronic abdominal pain.

Funding

This research did not receive any specific grant from funding agencies in the public, commercial, or not-for-profit sectors.

Competing interests

None declared.

Ethical approval

Not required.

Acknowledgement

None.

References

- [1] Van Thiel PH. A nematode parasitic to herring, causing acute abdominal syndromes in man. *Trop Geogr Med* 1960;12(2):97–113.
- [2] Hochberg NS, Hamer DH. Anisakidosis: perils of the deep. *Clin Infect Dis* 2010;51(7):806–12.
- [3] Audicana MT, Kennedy MW. *Anisakis simplex*: from obscure infectious worm to inducer of immune hypersensitivity. *Clin Microbiol Rev* 2008;21(2):360–79.
- [4] Sakanari JA, McKerrrow JH. Anisakiasis. *Clin Microbiol Rev* 1989;2(3):278–84.
- [5] Takabayashi T, Mochizuki T, Otani N, Nishiyama K, Ishimatsu S. Anisakiasis presenting to the ED: clinical manifestations, time course, hematologic tests, computed tomographic findings, and treatment. *Am J Emerg Med* 2014;32(12):1485–9.
- [6] Ito Y, Ikematsu Y, Yuzawa H, et al. Chronic gastric anisakiasis presenting as pneumoperitoneum. *Asian J Surg* 2007;30(1):67–71.
- [7] Arilla MC, Ibarrola I, Martinez A, Monteseirin J, Conde J, Asturias JA. An antibody-based ELISA for quantification of *Anisakis simplex*, a major allergen from *Anisakis simplex*. *Parasitology* 2008;135(6):735–40.
- [8] Audicana MT, Ansotegui IJ, de Corres LF, Kennedy MW. *Anisakis simplex*: dangerous—dead and alive? *Trends Parasitol* 2002;18(1):20–5.
- [9] Mattiucci S, Paoletti M, Borriani F, Palumbo M, Palmieri RM, Gomes V, et al. First molecular identification of the zoonotic parasite *Anisakis pegreffii* (Nematoda: Anisakidae) in a paraffin-embedded granuloma taken from a case of human intestinal anisakiasis in Italy. *BMC Infect Dis* 2011;11:82.
- [10] Mattiucci S, Paoletti M, Colantoni A, Carbone A, Gaeta R, Proietti A, et al. Invasive anisakiasis by the parasite *Anisakis pegreffii* (Nematoda: Anisakidae): diagnosis by real-time PCR hydrolysis probe system and immunoblotting assay. *BMC Infect Dis* 2017;17(1):530.
- [11] Kakizoe S, Kakizoe H, Kakizoe K, Kakizoe Y, Maruta M, Kakizoe T, et al. Endoscopic findings and clinical manifestation of gastric anisakiasis. *Am J Gastroenterol* 1995;90:761–3.
- [12] Akasaka Y, Kizu M, Aoi K, Kawai K. Endoscopic management of acute gastric anisakiasis. *Endoscopy* 1979;11(2):158–62.
- [13] Moore DA, Girdwood RW, Chiodini PL. Treatment of anisakiasis with albendazole. *Lancet* 2002;360(9326):54.
- [14] Pacios E, Arias-Diaz J, Zuloaga J, Gonzalez-Armengol J, Villarroel P, Balibrea JL. Albendazole for the treatment of anisakiasis ileus. *Clin Infect Dis* 2005;41:1825–6.