

Case Report

Spontaneous Flexor Tendon Rupture due to Primary Distal Radioulnar Joint Osteoarthritis

Akira Hashimoto,¹ Motoki Sonohata ,¹ Hideyuki Senba,² and Masaaki Mawatari¹

¹Department of Orthopaedic Surgery, Faculty of Medicine, Saga University, Nabeshima 5-1-1, Saga 849-8501, Japan

²Department of Orthopaedic Surgery, Karatsu Red Cross Hospital, Watada 2430, Karatsu, Saga 847-8588, Japan

Correspondence should be addressed to Motoki Sonohata; epc9719@yahoo.co.jp

Received 25 December 2018; Accepted 21 March 2019; Published 9 April 2019

Academic Editor: Paul E. Di Cesare

Copyright © 2019 Akira Hashimoto et al. This is an open access article distributed under the Creative Commons Attribution License, which permits unrestricted use, distribution, and reproduction in any medium, provided the original work is properly cited.

Spontaneous flexor tendon rupture is rare, occurring most commonly in the little finger or flexor pollicis longus. To the best of our knowledge, there have been no reports of spontaneous flexor tendon rupture due to primary distal radioulnar joint (DRUJ) osteoarthritis (OA). We present a case of spontaneous flexor tendon rupture in the index finger due to primary DRUJ OA in a 71-year-old female farmer. Surgical exploration confirmed that, at the wrist joint level, the flexor digitorum profundus of the index finger had undergone degeneration and complete rupture. The flexor digitorum superficialis of the index finger was elongated and thinned. A bony spur toward the volar side was covered with synovial fluid from a pinhole-sized perforation of the capsule. The combination of direct friction from the DRUJ spur and the matrix metalloproteinases in the synovial fluid from the perforation of the DRUJ capsule may have caused the spontaneous flexor tendon rupture. Palmar-side symptoms associated with DRUJ OA should be carefully examined because of the risk of spontaneous flexor tendon rupture.

1. Introduction

Spontaneous flexor tendon rupture is relatively uncommon and is usually caused by trauma, inflammatory disease, steroids (injection or oral therapy), or surgical complications from plate, and carpal bone and joint disorders [1, 2]. There have been reports of unusual causes of spontaneous flexor tendon rupture, scaphoid nonunion, hamate hook nonunion, Kienböck's disease, dorsal intercalated segment instability, and pisotriquetral osteoarthritis (OA) [3–7]. Although there are reports of extensor tendon rupture associated with primary distal radioulnar joint (DRUJ) OA [8, 9], to the best of our knowledge, there have been no reports of spontaneous flexor tendon rupture due to primary DRUJ OA. We report a case of spontaneous flexor tendon rupture in an index finger due to primary DRUJ OA.

The study protocol adhered to the ethical guidelines of the 1975 Declaration of Helsinki, and the study was approved by the institutional review board of our institute. The patient

was informed that this case study would be submitted for publication, and she provided informed consent.

2. Case Presentation

A 71-year-old woman was prescribed analgesics at another orthopedic clinic because of pain and swelling in the right carpal area. Half a month later, she could not flex the index finger of her right hand. She had no past history of trauma, carpal bone and joint disorders, or inflammatory disease and had not taken any steroid injection recently. She has been a farmer for a long time. On clinical examination, she was not able to actively flex the distal interphalangeal joint of her index finger. The proximal interphalangeal joint could be flexed to 40°. The anterior-posterior and lateral plain radiographs showed a bony spur arising from the volar ulnar aspect of the distal radius (Figures 1(a) and 1(b)). Computed tomography revealed that the bony spur from the radius was a part of DRUJ OA (Figure 1(c)).

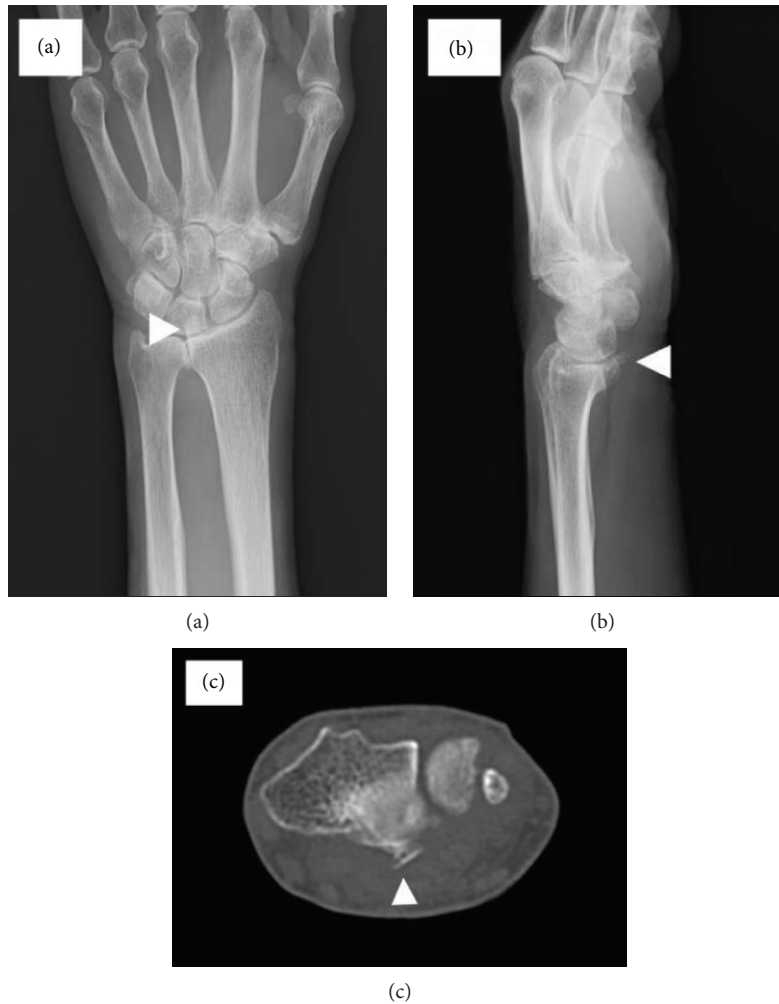

FIGURE 1: Clinical examination. (a) Bony spur on the anterior-posterior plain radiograph of the wrist joint (white arrowhead). (b) Bony spur on the lateral plain radiograph of the wrist joint (white arrowhead). (c) Bony spur on computed tomography (white arrowhead).

During surgery, under general anesthesia and using tourniquet control, a zig-zag incision was made at the level of the DRUJ on the palmar side. Surgical exploration confirmed that at the wrist joint level, the flexor digitorum profundus (FDP) of the index finger had undergone degeneration and complete rupture. The flexor digitorum superficialis (FDS) of the index finger was elongated and thinned. The FDP of the middle finger had undergone slight degeneration; however, tension of the FDP of the middle finger was normal (Figure 2(a)). The bony spur toward the volar side was covered with a joint capsule (Figure 2(b)). The volar capsule of the DRUJ had a pinhole-sized perforation (Figure 2(b)). There was synovial fluid from the pinhole-sized perforation (Figure 2(b)). Resection of the bony spur and the DRUJ capsule repair were performed. Then we performed single-stage reconstruction of the FDP of the index finger with a right palmaris longus bridge graft using interlacing 4-0 nylon sutures.

3. Discussion

DRUJ OA occurs as the result of a variety of mechanisms, including primary lesions, inflammatory arthritis (particularly

rheumatoid arthritis), posttraumatic causes (a malunited Colles' fracture of the distal radius, Galeazzi fracture-dislocation), and congenital or developmental abnormalities of the joint surfaces (spondylometaphyseal dysplasias, ulnar impaction syndrome) [10, 11]. The frequency of primary DRUJ OA was 12.3% in a cross-sectional study [11].

The most common complication of DRUJ OA is extensor tendon rupture [12]. Nevertheless, there are reports of flexor tendon rupture due to DRUJ OA after Galeazzi fracture-dislocation [13, 14]; however, there have been no reports of flexor tendon rupture due to primary DRUJ OA. The flexor tendons are more difficult to rupture than the extensor tendons, for the following reasons: (1) the flexor tendons are protected from direct injury by the pronator quadratus muscle [15], (2) the flexor tendons are not restricted and are not located in the radial compartment, as are the extensor tendons [15, 16], and (3) the flexor tendons are strong components of the musculotendinous junction and are stretched by a hypertension mechanism [15, 17].

Most reports of spontaneous extensor tendon rupture due to DRUJ OA may have involved perforation of the DRUJ capsule [8, 11, 12, 18]. Only Tanaka et al. reported a case of

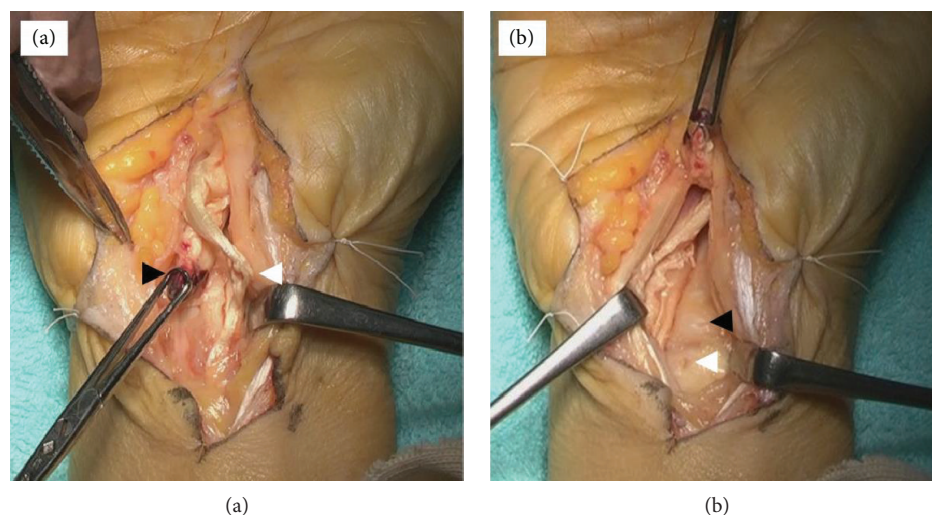


FIGURE 2: Intraoperative findings. (a) Rupture of the flexor digitorum profundus of the index finger (black arrowhead). Degeneration of the flexor digitorum superficialis of the index finger (white arrowhead). (b) A pinhole-sized perforation of the distal radioulnar joint capsule (white arrowhead). The bony spur covered with a joint capsule (black arrowhead).

extensor tendon rupture due to DRUJ OA [9]. There have also been reports on the extensor tendon rupture due to DRUJ OA without perforation of the capsule of the DRUJ. Ohara et al. reported that one of the reasons for flexor tendon rupture with DRUJ OA after Galeazzi fracture-dislocation was capsule perforation [14]. In the past reports, it has been reported that matrix metalloproteinase- (MMP-) 1, MMP-3, MMP-8, and MMP-13 are expressed in synovial fibroblasts of OA [14, 19–21]. MMP-1, MMP-8, and MMP-13 also reportedly degrade type I collagen that is abundant in tendons [13, 22]. In our case as well, a pinhole-sized perforation of the DRUJ capsule was recognized and joint fluid containing MMP leaked out, which led to further degeneration of the flexor tendons. We believe that the combination of direct friction from the DRUJ spur and the MMP that degraded type I collagen resulted in spontaneous flexor tendon rupture.

In conclusion, DRUJ OA is a rare cause of flexor tendon rupture and attrition. Attention should be paid when evaluating a patient with palmar-side symptoms of the wrist joint with DRUJ OA because of a risk of spontaneous flexor tendon rupture.

Conflicts of Interest

The authors declare that they have no conflicts of interest.

References

- [1] D. T. Netscher and J. J. Badal, "Closed flexor tendon ruptures," *The Journal of Hand Surgery*, vol. 39, no. 11, pp. 2315–2323, 2014.
- [2] S. Asadollahi and P. P. A. Keith, "Flexor tendon injuries following plate fixation of distal radius fractures: a systematic review of the literature," *Journal of Orthopaedics and Traumatology*, vol. 14, no. 4, pp. 227–234, 2013.
- [3] J. Pierrart, J.-Y. Rétoré, and C. Leclercq, "A rare complication of scaphoid nonunion: multiple flexor tendon lesions. A case report and review of literature," *Hand Surgery and Rehabilitation*, vol. 35, no. 2, pp. 135–138, 2016.
- [4] T. Hosokawa, R. Oda, S. Toyama et al., "Spontaneous flexor tendon rupture due to an insufficiency fracture of the hamate hook in a patient with systemic lupus erythematosus: a case report," *International Journal of Surgery Case Reports*, vol. 27, pp. 63–65, 2016.
- [5] K. Turner, N. N. Sheppard, and S. E. Norton, "Flexor tendon rupture due to previously undiagnosed Kienböck disease: a case report," *Hand*, vol. 12, no. 3, pp. NP37–NP38, 2017.
- [6] B. Miranda and S. Cerovac, "Spontaneous flexor tendon rupture due to atraumatic chronic carpal instability," *Journal of Wrist Surgery*, vol. 3, no. 2, pp. 143–145, 2014.
- [7] S. Saitoh, E. Kitagawa, and M. Hosaka, "Rupture of flexor tendons due to pisotriquetral osteoarthritis," *Archives of Orthopaedic and Trauma Surgery*, vol. 116, no. 5, pp. 303–306, 1997.
- [8] A. J. Carr and P. D. Burge, "Rupture of extensor tendons due to osteoarthritis of the distal radio-ulnar joint," *Journal of Hand Surgery*, vol. 17, no. 6, pp. 694–696, 1992.
- [9] T. Tanaka, H. Kamada, and N. Ochiai, "Extensor tendon rupture in ring and little fingers with DRUJ osteoarthritis without perforating the DRUJ capsule," *Journal of Orthopaedic Science*, vol. 11, no. 2, pp. 221–223, 2006.
- [10] R. M. Strigel and M. L. Richardson, "Distal radioulnar joint arthroplasty with a Scheker prosthesis," *Radiology Case Reports*, vol. 1, no. 2, pp. 66–68, 2006.
- [11] T. Katayama, H. Ono, D. Suzuki, M. Akahane, S. Omokawa, and Y. Tanaka, "Distribution of primary osteoarthritis in the ulnar aspect of the wrist and the factors that are correlated with ulnar wrist osteoarthritis: a cross-sectional study," *Skeletal Radiology*, vol. 42, no. 9, pp. 1253–1258, 2013.
- [12] C. A. Couturier and J. Y. Alnot, "Non-traumatic osteoarthritis of the distal radio-ulnar joint: a consecutive series of 11 wrists with 42 months follow-up," *Revue de Chirurgie Orthopedique*

- et Reparatrice de l'Appareil Moteur*, vol. 88, no. 6, pp. 573–581, 2002.
- [13] M. T. Nagy, S. Ghosh, B. Shah, and T. Sankar, “Delayed rupture of flexor tendons in zone V complicated by neuritis 18 years following Galeazzi fracture-dislocation,” *BMJ Case Reports*, vol. 2014, 2014.
- [14] M. Ohara, R. Oda, S. Toyama, Y. Katsuyama, H. Fujiwara, and T. Kubo, “Five-decade-delayed closed flexor tendon rupture due to Galeazzi dislocation fracture associated with Behçet syndrome: a case report,” *International Journal of Surgery Case Reports*, vol. 48, pp. 87–91, 2018.
- [15] P.-J. Chen and A. L.-J. Liu, “Concurrent flexor carpi radialis tendon rupture and closed distal radius fracture,” *BMJ Case Reports*, vol. 2014, 2014.
- [16] F. J. Leversedge and R. C. Srinivasan, “Management of soft-tissue injuries in distal radius fractures,” *Hand Clinics*, vol. 28, no. 2, pp. 225–233, 2012.
- [17] S. Imai, M. Kubo, K. Kikuchi, H. Ueba, and Y. Matsusue, “Spontaneous rupture of the flexor digitorum profundus and superficialis of the index finger and the flexor pollicis longus without labor-associated tendon loading,” *The Journal of Hand Surgery*, vol. 29, no. 4, pp. 587–590, 2004.
- [18] I. Ohshio, T. Ogino, A. Minami, H. Kato, and A. Miyake, “Extensor tendon rupture due to osteoarthritis of the distal radio-ulnar joint,” *The Journal of Hand Surgery*, vol. 16, no. 4, pp. 450–453, 1991.
- [19] S. Fuchs, A. Skwara, M. Bloch, and B. Dankbar, “Differential induction and regulation of matrix metalloproteinases in osteoarthritic tissue and fluid synovial fibroblasts,” *Osteoarthritis and Cartilage*, vol. 12, no. 5, pp. 409–418, 2004.
- [20] Y. Okada, M. Shinmei, O. Tanaka et al., “Localization of matrix metalloproteinase 3 (stromelysin) in osteoarthritic cartilage and synovium,” *Laboratory Investigation*, vol. 66, no. 6, pp. 680–690, 1992.
- [21] O. Lindy, Y. T. Konttinen, T. Sorsa et al., “Matrix metalloproteinase 13 (collagenase 3) in human rheumatoid synovium,” *Arthritis & Rheumatism*, vol. 40, no. 8, pp. 1391–1399, 1997.
- [22] P. C. Abhilash, S. Jamil, and N. Singh, “Matrix solid-phase dispersion extraction versus solid-phase extraction in the analysis of combined residues of hexachlorocyclohexane isomers in plant matrices,” *Journal of Chromatography A*, vol. 1176, no. 1-2, pp. 43–47, 2007.