

Correction of Postlaminectomy Cervical Kyphosis in an Operated Case of Cervical Spine Primitive Neuroectodermal Tumor

Abstract

A 14-year-old boy presented with gradually worsening spastic quadriparesis and cervical kyphotic deformity as a consequence of laminectomy for tumor debulking and chemoradiotherapy done 2 years prior for cervical primitive neuroectodermal tumor. Problems to be addressed particularly to the case were a rigid kyphosis of 102.7°, poor soft-tissue coverage, internal gibbus compressing cord, perched facets, and superficial location of cord. The surgery was staged, in that the first anterior release was done with gradually increasing traction to correct the kyphosis progressively. Posterior instrumentation was done in the second stage. Finally, anterior reconstruction with tricortical iliac bone grafting was done. The patient regained full power with complete union at the end of 18 months. Irradiation of tumor along with laminectomy results in loss of posterior tension band which results in progressive kyphotic deformity in children. A staged plan of surgical interventions can help in postoperative correction of deformity with circumferential union and prevention of recurrence. This article describes successful treatment of a patient with postlaminectomy cervical kyphosis with 77° of correction achieved postoperatively and also highlights the importance of anterior and posterior reconstructions to achieve a stable vertebral column.

Keywords: Cervical kyphosis, pediatric population, postlaminectomy

Introduction

An intact spine characteristically does not get destabilized immediately by performing extensive multilevel laminectomies. Removal of the posterior tension band, however, can result in progressively increasing compressive loads on the anterior vertebral body, resulting in anterior wedge compression. The posterior cervical muscles and facet joints undergo denervation and atrophy after surgery. Posterior tension band dysfunction leads to increased force on the anterior vertebral body which worsens the sagittal deformity resulting in kyphotic angulation. With progression, the spinal cord may become increasingly draped over the posterior vertebral body leading to flattening of small feeding vessels to the cord as well as myelopathy.^[1] Patients experience severe mechanical neck pain secondary to facet joint disruption in addition to neurological dysfunction.

There is generous amount of data regarding the incidence of kyphotic deformity following laminectomy for cervical

spondylotic myelopathy. The incidence of postoperative kyphosis after multilevel cervical spine laminectomy is approximately 20%.^[2] The incidence increases significantly in patients with preoperative cervical spine straightening.

The biomechanical features of the cervical spine make it particularly susceptible to a postlaminectomy deformity. Data analysis indicates that the anterior vertebral body supports only 36% of cervical load compared with 64% in the posterior column.^[3] The incidence of postlaminectomy kyphotic spinal deformity is particularly higher in the pediatric population.^[4] Because the incompletely ossified vertebral bodies in children offer poor resistance to compressive forces, they are more prone to developing wedge deformity and progressive loss of sagittal balance.

Preoperative loss of cervical lordosis, facet capsule destruction, tumor, and irradiation are some factors that have been linked with a greater incidence of postoperative kyphosis. The occurrence of postoperative kyphosis is increased 2-fold if preoperative loss of lordosis is present.^[2]

This is an open access journal, and articles are distributed under the terms of the Creative Commons Attribution-NonCommercial-ShareAlike 4.0 License, which allows others to remix, tweak, and build upon the work non-commercially, as long as appropriate credit is given and the new creations are licensed under the identical terms.

For reprints contact: reprints@medknow.com

How to cite this article: Srivastava S, Marathe N, Bhosale S, Gautham S. Correction of postlaminectomy cervical kyphosis in an operated case of cervical spine primitive neuroectodermal tumor. Asian J Neurosurg 2019;14:1017-20.

**Sudhir Srivastava,
Nandan Marathe,
Sunil Bhosale,
Sai Gautham¹**

Departments of Orthopaedics
and ¹Orthopedics, Seth GS
Medical College and KEM
Hospital, Mumbai, Maharashtra,
India

Address for correspondence:
Dr. Nandan Marathe,
Saraswati Prasad, Gaul Wada,
Vasai (West), Palghar - 401 201,
Maharashtra, India.
E-mail: nandanmarathe88@
gmail.com

Access this article online

Website: www.asianjns.org

DOI: 10.4103/ajns.AJNS_52_19

Quick Response Code:



Irradiation has been linked with higher postoperative deformity rates in the pediatric population. Radiation causes bone death and impaired bone growth resulting in delayed deformity in growing children. Mayfield *et al.*^[5] reviewed data obtained in 74 patients who underwent radiotherapy for neuroblastoma in whom survival was >5 years. After a 13-year follow-up, they reported a 76% incidence of spinal deformity. In addition, 20% of the survivors required deformity correction surgery.

Herein, we present a case report of a child who showed postlaminectomy kyphotic deformity after undergoing laminectomy to treat tumor debulking and chemoradiotherapy done 2 years prior for cervical primitive neuroectodermal tumor (PNET).

Case Report

A 14-year-old boy presented with gradually worsening spastic quadriparesis with nonambulatory power and cervical kyphotic deformity as a consequence of laminectomy for tumor debulking and chemoradiotherapy done 2 years prior for cervical PNET.

Problems to be addressed particularly to the case were a rigid kyphosis of 102.7°, poor soft-tissue coverage, internal gibbus compressing cord, perched facets, and superficial location of cord. Figures 1 and 2 show the preoperative X-ray and magnetic resonance imaging of the patient with rigid kyphosis.

The staged plan of management included:

- Stage 1: Anterior release and decompression. Anterior release involving removal of C3, C4 vertebral body, and decompression resulted in partial correction of kyphosis to 70°. The patient was advised strict immobilization, and Gardner-Wells tongs was applied and cervical traction was given with gradual increase in weights from 3 to 9 kg with resultant gradual reduction in the degree of kyphosis [Figures 3-5]
- Stage 2: Posterior instrumentation, reduction, and fusion using C1 lateral mass screw, C2 pedicle screw, C5, C6, and C7 lateral mass screw, and posterior iliac crest bone grafting [Figure 6]
- Stage 3: Anterior reconstruction using anterior iliac crest strut bone grafting [Figure 7].

With meticulous-staged surgeries, we obtained correction of cervical kyphosis from 102.7° to 25.72° amounting to a total correction of 77°. Review of the current literature found that the largest correction of cervical kyphosis averaged 48°. The patient is ambulatory with Grade 5 power in all four limbs. Computed tomography scan at 18-month follow-up showed good bony consolidation.

Discussion

Kyphotic deformity can occur postlaminectomy due to the loss of posterior elements that resist traction forces.

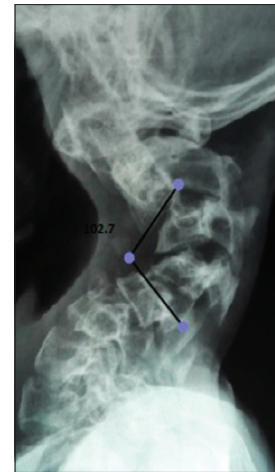

Figure 1: Kyphosis of 102.7° at presentation

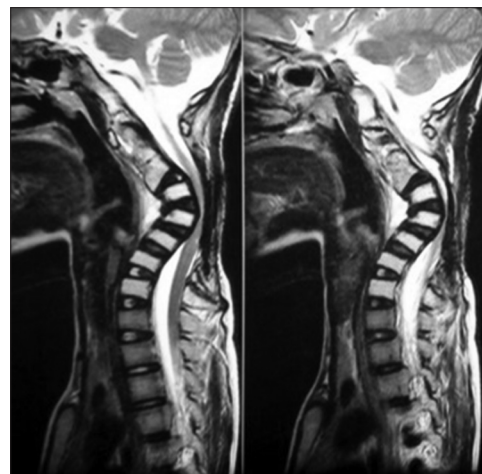


Figure 2: Sagittal magnetic resonance imaging of the patient showing kyphosis

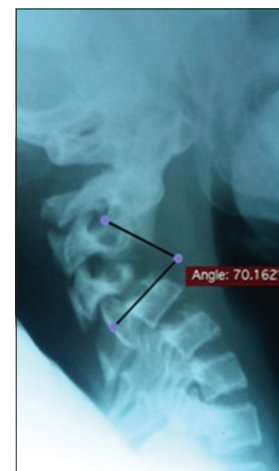

Figure 3: Kyphosis (70°) after anterior release and traction of 3 kg

Postlaminectomy deformity when severe may cause neural compression which in turn would lead to neurological symptoms.^[6] Robert and Bortolussi postulated that as the deformity progresses, the weight-bearing pivot of the

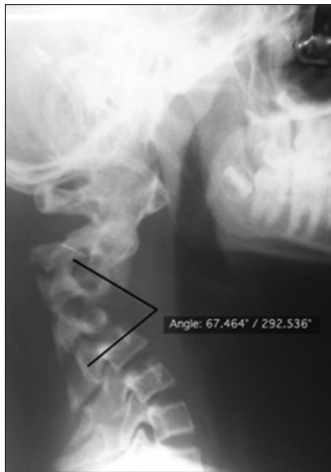

Figure 4: Reduction of kyphosis with an increase in traction (7 kg)

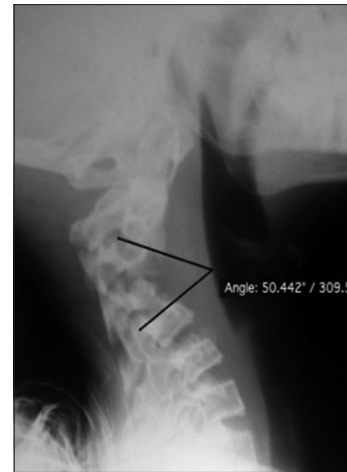


Figure 5: Traction X-ray at 9 kg of traction

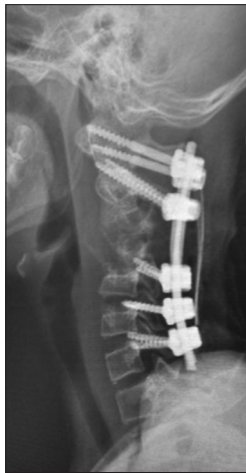

Figure 6: Stage 2: Posterior instrumentation and fusion

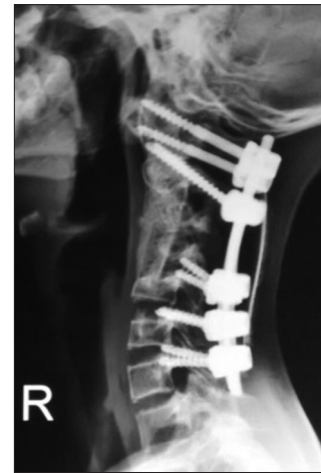


Figure 7: Stage 3: Anterior reconstruction with tricortical iliac bone graft

body moves anteriorly and therefore can only be amended with spinal column sagittal balance reconstruction.^[7] Some theories propose that radiation and posterior muscle inadequacy leading to arrest in vertebral growth are the primary reasons of deformity postlaminectomy.^[8] Baring the cervical region, adults do not show postlaminectomy kyphosis because of maturation of the spine.^[8] This is related to the patient's age, gender, the number of the levels and regions of laminectomy, and the time after surgery. It is not related to the neurologic status of the patient.^[9] The probability of postlaminectomy kyphosis is higher in younger age groups and in higher cephalad levels.^[10]

Delay in the development of kyphotic deformity can be achieved by immobilization after surgery; however, it does not appear to prevent it.^[6] Surgical intervention is indicated in the severity and progression of the deformity and related neurological deficits.^[9] Lutz and Munhoz da Rocha reported that the time between surgery and postsurgery kyphosis was 4 years and 3 months. The mean kyphotic angle improved from 87° to 38°. The mean age at the first

surgery was 3 years and 1 month and for correction surgery was 11 years and 7 months.^[7] Kelley *et al.* described a 4-year-old child who underwent D9 to L3 laminectomy for resection of a tumor. He presented with kyphotic deformity with kyphotic angle of 110 when he was 9 years old. After posterior approach repair surgery, the kyphotic angle decreased to 65° and postoperative imaging confirmed good reconstruction.^[11]

Papagelopoulos *et al.* in another study monitored 36 patients who underwent multilevel thoracolumbar total laminectomy. The mean age of the patients was 11 years, and in them, 12 patients were younger than 17 years. Spinal deformity was identified in 33% of pediatric patients and 8% of adult patients at follow-up of 14 years. These results show that age, clinical condition, and follow-up period can influence the postlaminectomy kyphosis.

The above studies show that postlaminectomy kyphosis mostly arises several years after surgery, is more common following laminectomy concerning the cervical and dorsal spine, and occurs more commonly following laminectomy within the cephalad level or multilevel laminectomy.

Conclusion

Kyphosis after laminectomy can follow soon postsurgery and is a chief concern and complication in children. Minimization of muscle dissection and bone removal during laminectomy, avoiding facet disruption, laminoplasty instead of laminectomy, postoperative immobilization and bracing, and performing regular follow-ups for early detection and treatment of any deformity are a few factors to prevent postlaminectomy kyphosis. A staged plan of surgical interventions can help in postoperative correction of deformity with circumferential union and prevention of recurrence.

Declaration of patient consent

The authors certify that they have obtained all appropriate patient consent forms. In the form the patient(s) has/have given his/her/their consent for his/her/their images and other clinical information to be reported in the journal. The patients understand that their names and initials will not be published and due efforts will be made to conceal their identity, but anonymity cannot be guaranteed.

Financial support and sponsorship

Nil.

Conflicts of interest

There are no conflicts of interest.

References

- Breig A, el-Nadi AF. Biomechanics of the cervical spinal cord. *Acta Radiol Diagn (Stockh)* 1966;4:602-24.
- Kaptain GJ, Simmons NE, Replogle RE, Pobereskin L. Incidence and outcome of kyphotic deformity following laminectomy for cervical spondylotic myelopathy. *J Neurosurg* 2000;93:199-204.
- Pal GP, Sherk HH. The vertical stability of the cervical spine. *Spine (Phila Pa 1976)* 1988;13:447-9.
- Cattell HS, Clark GL Jr. Cervical kyphosis and instability following multiple laminectomies in children. *J Bone Joint Surg Am* 1967;49:713-20.
- Mayfield JK, Riseborough EJ, Jaffe N, Nehme ME. Spinal deformity in children treated for neuroblastoma. *J Bone Joint Surg Am* 1981;63:183-93.
- Lutz FS, Munhoz da Rocha LE. Post-laminectomy deformities. *Coluna Columna* 2014;13:279-81.
- Robert H, Bortolussi C. *In vitro* evolution of the pressure and the geometry of the lumbar disc as a function of the stability of the spine. *J Biophys Med Nucl* 1984;8:243-9.
- Tanaka M, Sugimoto Y, Misawa H, Takigawa T, Kunisada T, Ozaki T, *et al.* Segmental pedicle screw fixation for a scoliosis patient with post-laminectomy and post-irradiation thoracic kyphoscoliosis of spinal astrocytoma. *Acta Med Okayama* 2012;66:363-8.
- Otsuka NY, Hey L, Hall JE. Postlaminectomy and postirradiation kyphosis in children and adolescents. *Clinical Orthopaedics and Related Research* 1998;354:189-94.
- Yasuoka S, Peterson HA, MacCarty CS. Incidence of spinal column deformity after multilevel laminectomy in children and adults. *J Neurosurg* 1982;57:441-5.
- Kelley BJ, Johnson MH, Vortmeyer AO, Smith BG, Abbed KM. Two-level thoracic pedicle subtraction osteotomy for progressive post-laminectomy kyphotic deformity following resection of an unusual thoracolumbar intradural extramedullary tumor. *J Neurosurg Pediatr* 2012;10:334-9.